

## The Use Of Control Suture In Cleft Lip Surgery

Gentur Sudjatmiko, Mohamad Rachadian Ramadan

*Jakarta, Indonesia.*

To achieve an optimal result in cleft surgery, executing the proper designs and precise techniques are mandatory. Several techniques are proposed for the repair of unilateral and bilateral cleft lip. In 1955, Millard first described the techniques of advancing a lateral upper lip flap combined with downward rotation of the medial segment.<sup>1</sup> From experience, the above-mentioned technique may be modified to facilitate better lip rotation and symmetry. Technically, it also provides a more efficient workflow and more accurate results. All efforts in lip repairs have one ultimate goal, which is to achieve corrected lips with minimal scar and as much resemblance to that of the normal lips: by anatomy, symmetry, and muscle function.

In correcting cleft lips, several problems exist that every surgeon must be aware of and focus to alleviate. Unilateral complete cleft lip is characterized by disruptions of the lip, nostrils sill, and alveolus. The most obvious problem is the gap, which must be closed firsthand to achieve a near-normal lip anatomy (Figure 1). On the cleft side, Cupid's bow is not formed and is instead replaced by gaps. The orbicularis oris muscles do not meet each other and inserts abnormally onto a rather laterocranial side. Point 3 is elevated in the normal lip side, making the lip appear asymmetrical (Figure 2). Intraoperative, surgeon is often occupied by the little details of tissues but only to find an end-result of notching or asymmetry due to inappropriate muscle, skin or vermillion distribution. Cleft lip surgery should overcome the problems described above. In a unilateral complete cleft

lip repair, it is necessary to lower the Cupid's bow points, adjusting point 3 to the same level at point 2, and then to advance the lateral side to fill the gap and achieve a symmetrical position.

Good design prior to surgery, careful planning, and precise techniques will mostly cover the goals. However, cleft surgery is not a one-way ticket to destination, it is necessary to have back up plans, especially when the first estimated design does not meet the required goals. Changing plans are plausible and common, being flexible and fully aware of the tissue nature will help to attain good results. Sometimes we have to adjust the incision of the muscle to level point number 4 to point number 3, or point 3 to point 2. To help surgeons determine whether their design is adequate, whether to reduce point 3 to the level of point 1, or to approximate the gap and to attempt downward rotation of the medial or lateral side of the lip during lip surgery, we can place a "control suture" which is being introduced by the author in this article. This method will effectively aid surgeons to precisely execute their design and approximate whether any revision of design is necessary to attain the most favorable aesthetic result.

The definition of control suture as proposed by the author, since its implementation for about 20 years, is the utilization of an untied suture into the lip muscles right between point 3 and 4 under the white skin roll. This suture approximates and adjusts the need of rotation of the medial or lateral sides of the lip used to fill the cleft gap. Control sutures are placed after incision and hemostasis. This suture will help surgeons

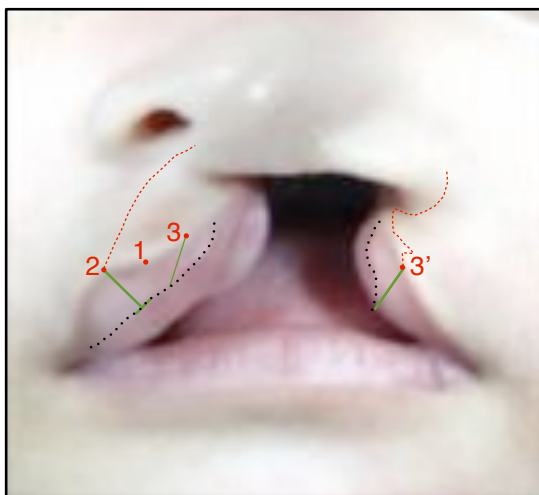
*From The Division of Plastic Reconstructive and Aesthetic Surgery, University of Indonesia, Cipto Mangunkusumo Hospital, Jakarta, Indonesia*

**Disclosure:** *The authors have no financial interest to declare in relation to the content of this article.*

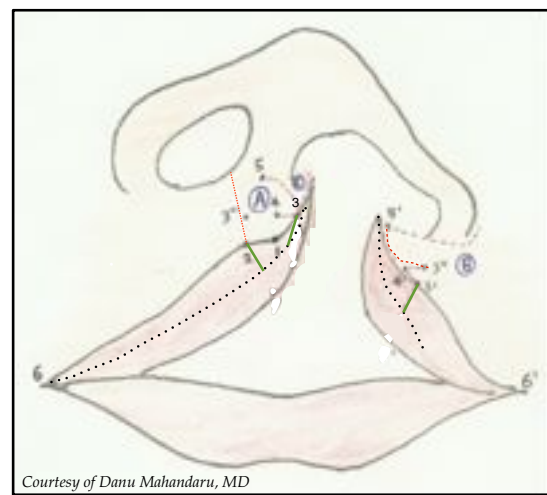
execute surgical design more precisely, especially in approximating the orbicularis oris muscles as the cleft gap is closed. Finally, the control suture is secured in knots after muscles are approximated and other sutures are in place, achieving the perfect lip alignment.

To apply a control suture, pass a thread into the muscle and a part of the dermis directly underneath the white skin roll. The author prefers the use of 5.0 nylon threads. Secure the control suture by clamping both end

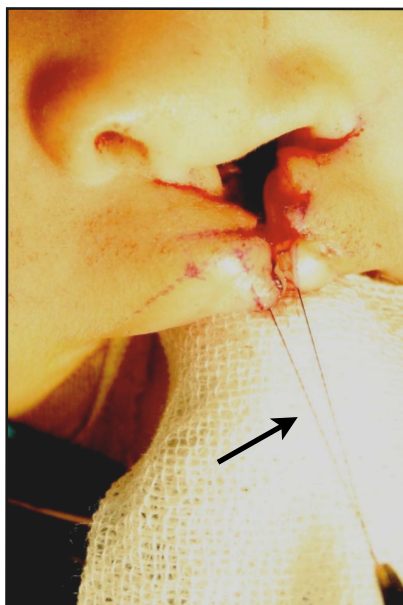
of threads using mosquito clamps (Figure 3). Adjust the tension of the control suture by gentle pulling motion, moving it in any direction to suit the design and approximate which portion of the muscle will meet so that lip symmetry is obtained. Prior to adjoining the muscle, mucosal stitch is also assisted by the control suture so that the mucosa are evenly distributed. Apply gentle downward traction while suturing the muscle (Figure 4). To achieve an adequate muscle alignment, usually three 5.0



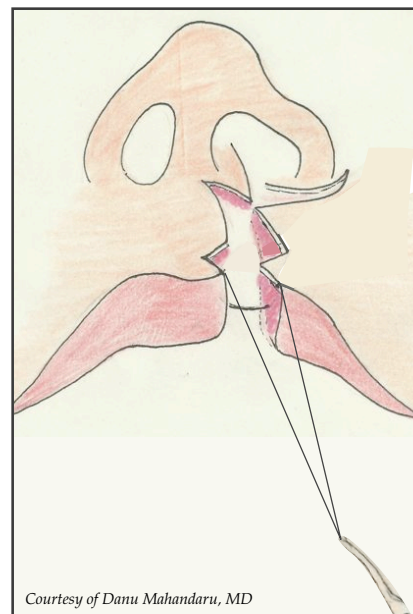
**Figure 1.** The wide cleft shown with important marking and lines to prevent notching and asymmetry.



**Figure 2.** The point 3 is higher in normal lip, have to be rotated downward and same level as point 2 at normal point of cupid bow.



**Figure 3.** Application of control suture in cleft surgery (black arrow).



**Figure 4.** Traction to caudal direction to approximate the puzzle.



nylon sutures are placed. After the last muscular suture, the control suture is held in place by the surgeon, and then securely tied.

Whichever cleft repair design is used, a control suture will benefit the surgeon from several points such as: (i) the freedom to feel and see whether the skin, mucosa, or muscle incisions are adequate to facilitate downward rotation of the medial and lateral lip sides; (ii) to estimate the amount of tissue needed to achieve a symmetrical vermilion as well as to assist the vermilion angles alignment; (iii) to help in the planning of removal of excess mucosa and amount of deliberation of muscle; (iv) to distribute the orbicularis oris muscles evenly and prevent dimpling due to unoccupied tissues under the skin; (v) to fulfill the muscle defect as well as skin around the flap after rotation; and to facilitate the downward traction to reduce spaces while adjoining the orbicularis oris using intradermal suture.

The implementation of control suture does not alter the original surgical design, and does not require the use of extra equipment or materials. It avoids additional trauma subjected to the tissue which is otherwise done when grasping tissue using an Adson forceps. The author propose no limitation for this technique to be performed in any cleft surgery. Normally, surgeons will approximate the gap and revisit the design after the incision simply by grabbing

the tissue using the forceps or their hand. Doing so will not provide the best visualization of the surgical field, as it may be blocked by hands or instrument hence suturing are less easy to perform. It is also harder to precisely measure the tissue excess when using hand compared to control suture. To the author's experience, there is no other techniques that could achieve the benefits that control suture offers.

In summary, control suture is an alternative approach for surgeons to deliver greater precision and symmetry in cleft surgery. It is easy to perform, brings advantages to surgeons and have no obvious limitation. Most importantly, it is applicable to any type of cleft surgery design. It is safe to say that when control sutures are not applied in cleft lip surgery, the surgeon will need more effort to achieve precision, execute good surgical design, and finally deliver good aesthetic results.

**Gentur Sudjatmiko, MD**

*Division of Plastic surgery*

*Cipto Mangunkusumo General Hospital, Jakarta*

*dr\_gentur@yahoo.co.id*

## REFERENCES

1. Millard DR. Refinements in rotation-advancement cleft lip technique. *Plast Reconstr Surg.* 1964;33:26.