

LARGE ABDOMINAL DEFECT CLOSURE: CASE SERIES

Handini NS.

1. Universitas Indonesia, Department of Surgery, Division of Plastic Reconstructive and Aesthetic Surgery, RSUPN Cipto Mangunkusumo, Jakarta, Indonesia
2. Universitas Indonesia, Department of Surgery, Division of Plastic Reconstructive and Aesthetic Surgery, RSUPN Cipto Mangunkusumo, Jakarta, Indonesia
3. Universitas Indonesia, Department of Surgery, Division of Plastic Reconstructive and Aesthetic Surgery, RSUPN Cipto Mangunkusumo, Jakarta, Indonesia

ABSTRACT

Background: We will report some experiences in managing challenging malignant cases on the abdominal wall, including a case of large, irradiated defect. All of those cases were consulted intraoperative immediately following tumor removal. The keystone random perforator flap was chosen among the option of solutions in large abdominal defect closure. This region has natural elasticity, which combines well with the multi-axial tissue recruitment of the flap

Methods: Three cases of complicated abdominal defect were reconstructed using the keystone flaps supplied by non-identified (random) perforators.

Results: All flaps survived without problem of vascularization, despite of its large defect, sequence of radiotherapy following reconstruction, infection, and with its margin unable to be freed from tumor. One out of three cases suffered from contaminated wound from stomal leakage, leading to dehiscence.

Conclusion: The keystone flap is a useful and reliable random perforator-based flap, even in complex and challenging malignant cases of abdominal wall.

Keyword: *keystone flap, malignancy, large abdominal defect closure, radiotherapy*

Latar Belakang : Serial kasus tentang penanganan keganasan pada dinding abdomen, termasuk keganasan dengan defek luas yang telah mendapat terapi radiasi. Semua kasus dikonsul intraoperative saat pengangkatan tumor. Keystone random perforator flap dipilih sebagai solusi untuk menutup defek luas pada abdomen. Daerah ini memiliki jaringan yang elastis dan dapat digabungkan dengan pengambilan flap dari berbagai sudut.

Metodologi : Rekonstruksi tiga buah kasus defek luas di abdomen dengan flap keystone yang diperdarahi perforator yang tidak diidentifikasi (random flap).

Hasil : Semua flap berhasil tanpa mengalami gangguan vaskularisasi walaupun menutupi defek yang luas, telah menjalani terapi radiasi, infeksi, dan batas sayatan tidak bebas tumor. Satu dari tiga kasus mengalami kontaminasi dari kebocoran stoma dan menyebabkan dehisensi.

Kesimpulan : Flap keystone merupakan pilihan flap perforator random yang berguna dan dapat diandalkan, bahkan dalam kasus rekonstruksi keganasan pada dinding abdomen.

Kata Kunci : *keystone flap, malignancy, large abdominal defect closure, radiotherapy*

Received: 4 Juni 2015, Revised: 15 Maret 2016, Accepted: 28 April 2016.

ISSN 2089-6492 ; E-ISSN 2089-9734

This Article can be viewed at www.jprjournal.com

BACKGROUND

Closure of a relatively wide abdominal wall defect is challenging. In our center, we needed a simple but reliable solution.

Keystone flap method, a random perforator flap, was initially applied in 2012 for some of our patients.¹ This method seems to be suitable to manage large abdominal defect closure discussed in this article. Keystone is an architectural term referring to a wedge-shaped material placed on the peak central of the arc, made to support the arch through gravity (Figure 1).² The keystone random perforator flap was first published by Felix C. Behan in 2003. It is described as "a curvilinear-shaped trapezoidal design flap". Keystone concept derived from Behan's earlier work on the angiotome principle in 1975, where each angiotome may be safely raised as a flap, or extended by linkage vessels with an adjacent angiotome.³

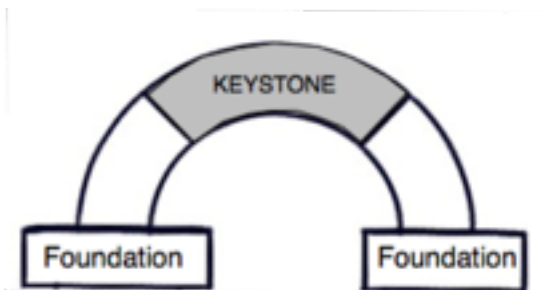


Figure 1. Architectural nomenclature of keystone¹

We present three cases of large abdominal defect reconstructions using the keystone flap, including a case of large, irradiated defect. All of those cases were consulted intraoperative immediately following tumor removal.

PATIENT AND METHOD

From July to August 2014, the keystone flap was performed in three patients with large abdominal defects following tumor removal. Etiology of the defects was malignant tumor. The mean age of the patients is 31 years old. Two patients are male and one is female. The mean size of the defect is 6.75 x 11.5 cm. Patients characteristics are summarized in Table 1.

Surgical technique

After excision, the side of the defect with greater tissue laxity is chosen as flap donor area (figure 2.b). If a single flap seems inadequate, another flap from opposite side of the ellipse is marked and kept ready. An incision at 90 degrees at either end of the defect meets the curvilinear line of

The width of the flap equals the width of the defect. This curvature or Keystone shape is then mobilized. Flap length is governed by the length of the elliptical excision.

The skin incision is deepened toward the fascia, then by blunt dissection the flap is elevated, this preserves the artery and vein. The first step (figure 2.c) in wound closure involves closing the 'V' in the flap defect as a 'Y'. This creates tissue laxity in the center of the flap at right angles to the 'Y' and also narrows the secondary defect. The flap is then sutured into the original defect and donor area closed. A drain is placed beneath the flap when the defect needs it.

Case 1

Case number 1 is a 9-year-old male with recurrent high grade epitheloid malignant tumor of the right flank, suspect of extracranial meningioma (Figure 3). The tumor excised 6 x 16 cm in whole up from the peritoneum to the skin without margin free from tumor. Polypropylene mesh was used directly over abdominal viscera, then the defect was reconstructed with type III keystone flap that was raised from superior and inferior sides of the defect. The flap is then sutured into the original defect and donor area closed using a non absorbable suture (Figure 4).

Case 2

Case number 2 is a 41-year-old male with Adenocarcinoma of transverse colon & sigmoid, well-differentiated T4N1M1, which infiltrated the left wall hemi-abdomen (Figure 6). The tumor excised 7x7 cm and 7x12 cm in whole up from the peritoneum to the skin. The defect was reconstructed with type II keystone flap for the first defect and type III keystone flap for the second defect that was raised from superior and inferior sides of the defect. The flap is then sutured into the original defect and donor area closed using a non absorbable suture (Figure 7).

Case 3

Case number 3 was a 43-year-old female with malignant tumor of ascending colon & hepatic flexure of right hemi-abdomen (Figure 9). The tumor excised 7x11 cm in whole up from the peritoneum to the skin. The defect was reconstructed with type III keystone flap that was raised from lateral sides of the defect. The flap is then sutured into the original defect and donor area closed using a non-absorbable suture (Figure 10).

Disclosure: *The authors have no financial interest to disclose.*

Table 1. Patients characteristic and surgical details

Case	Age	Sex	Cause	Location	Size (cm)	Perforator	Operation time (min)	Mesh	Type of keystone flap
1	9 yr	M	High grade epitheloid malignant tumor, suspect of extracranial meningioma	Right flank	6x16	Unidentified	180	+	III
2	41 yr	M	Adenocarcinoma of transverse colon & sigmoid, well-differentiated T4N1M0, on colostomy	Left hemi abdomen	7x7 and 7x12	Unidentified	120	-	II & III
3	43 yr	F	Malignant tumor of ascending colon & hepatic flexure T3N0M0	Right hemi abdomen	7x11	Unidentified	180	-	III
Mean	31 yr				6.75 x 11.5		160		

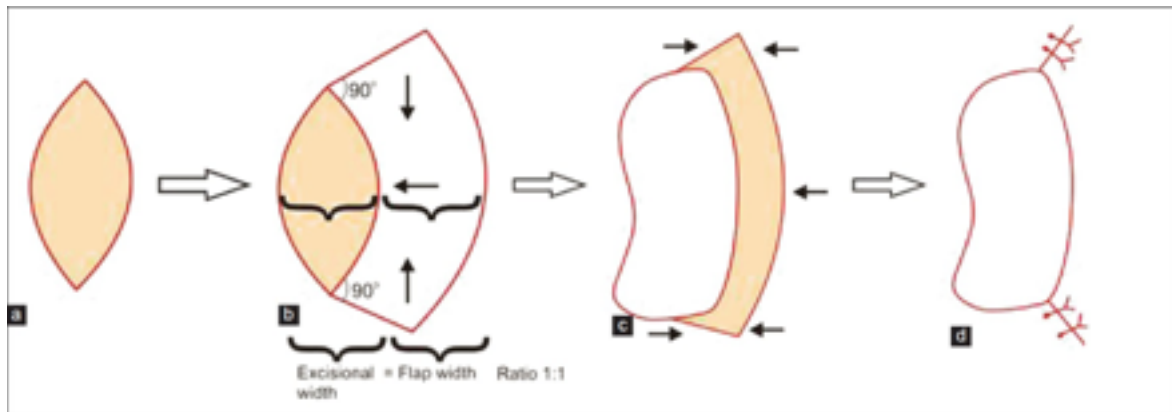


Figure 2. Surgical technique. Black arrows show the direction of defect closure.⁴

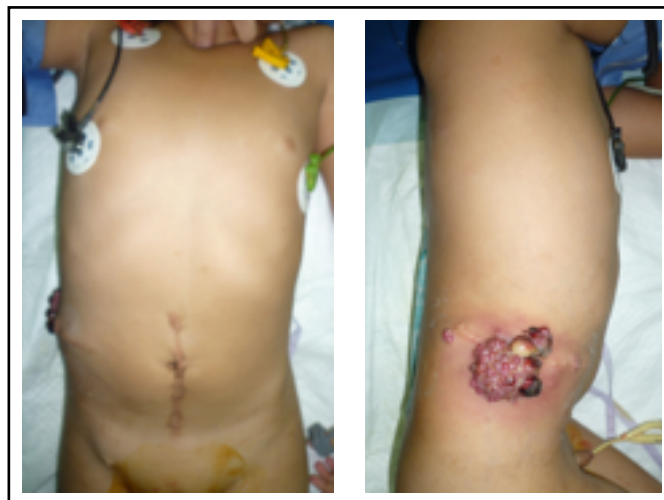

Figure 3. Preoperative image showing a 9-year-old male, with huge lump located in the right anterolateral abdominal wall.

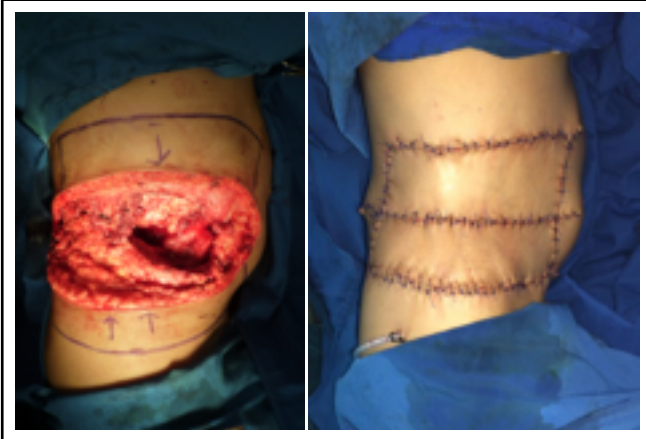


Figure 4. Left: Intraoperative picture of surgery for abdominal wall defect after tumor removal and the design of random perforator flap. Size of defect: 6 x 16 cm. **Right:** Immediately post operative.

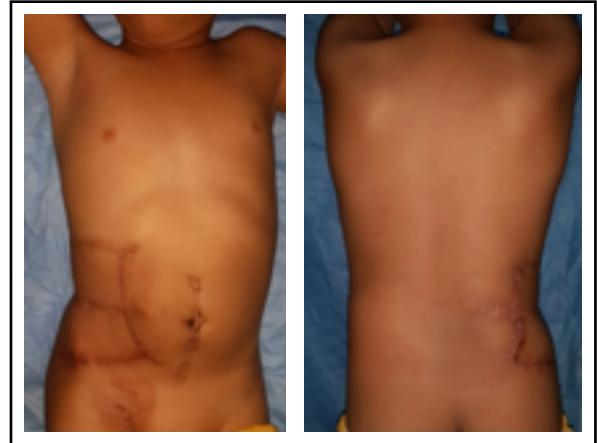


Figure 5. Postoperative views of flap at 6 month, after 30 cycles of radiotherapy. Due to the previous radiotherapy final suture removal was delayed until radiotherapy finished.

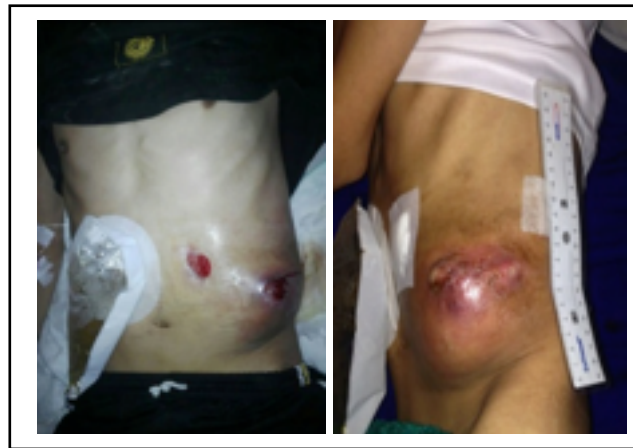

Figure 6. Preoperative image showing a 41-year-old male, with huge lump located in the left anterolateral abdominal wall.

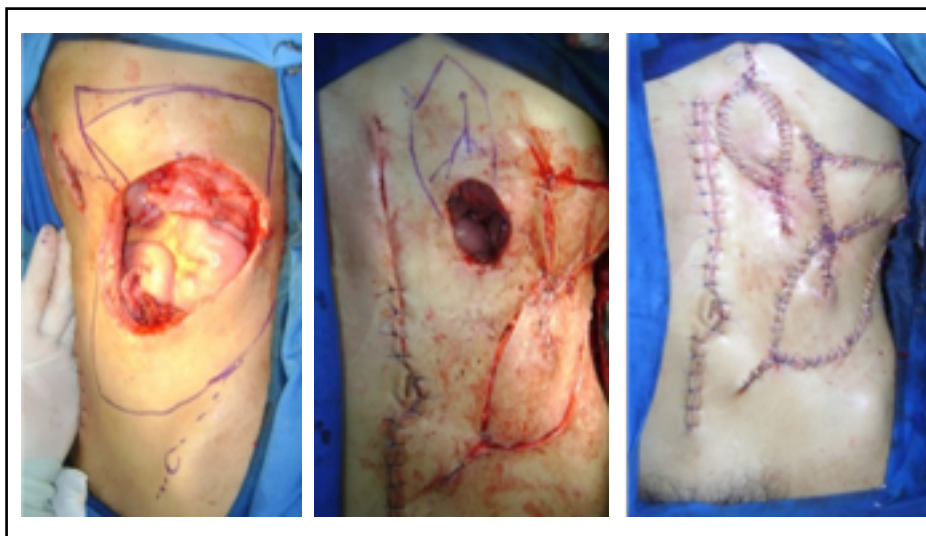

Figure 7. Left: Intraoperative pictures of surgery for abdominal wall defect after tumor removal and the design of the random perforator flap. Defect size: 7 x 7 cm and 7 x 12 cm. **Middle:** The design of the random perforator flap of the second defect. **Right:** Immediately post operative

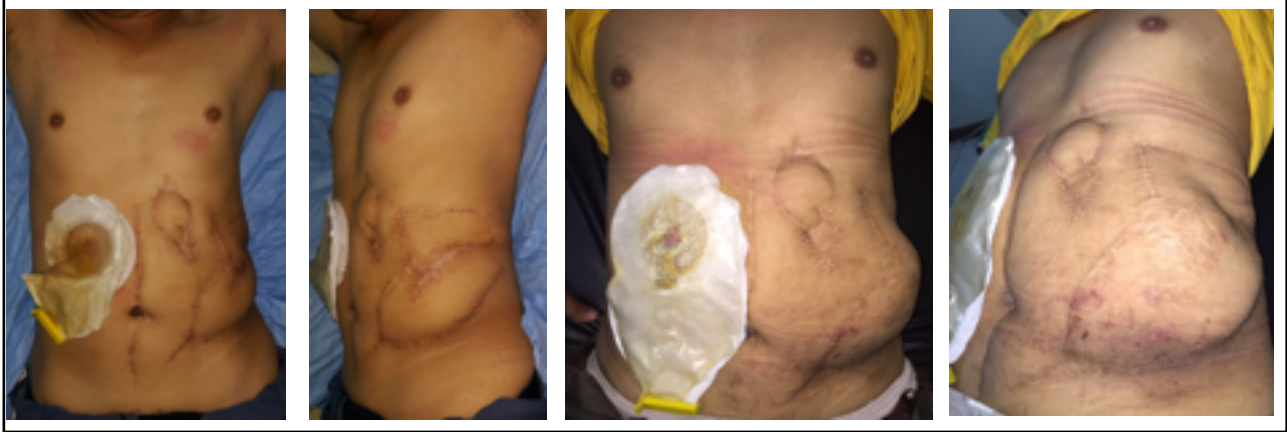

Figure 8. Top: Postoperative views of flap after 6 months. Bottom: Postoperative views of flap after 1 year.

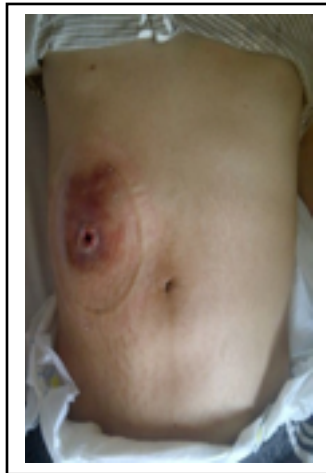

Figure 9. Preoperative image showing a 43-year-old female with huge lump located in the right anterolateral abdominal wall.

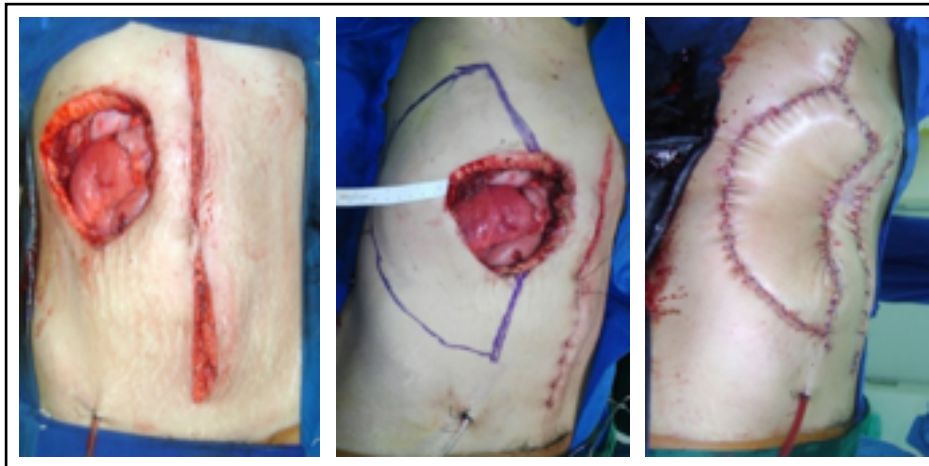


Figure 10. Left: Intraoperative pictures of surgery for abdominal wall defect after tumor removal. Defect size: 7 x 11 cm. Middle: Design of the random perforator flap. Right: Immediately post operative.

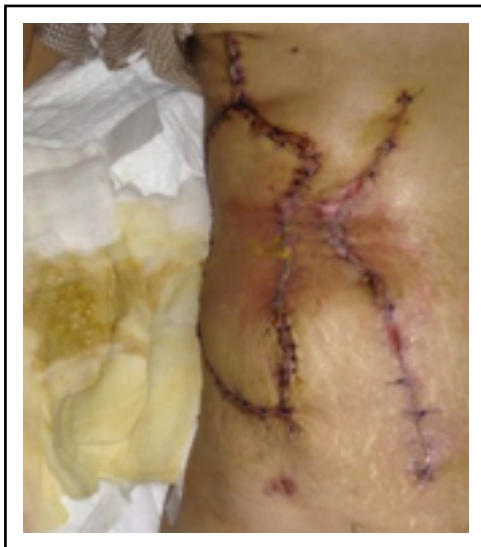

Figure 11. Postoperative views of flap at 9th day. Suffered from contaminated wound from stomal leakage, leading to dehiscence.

RESULT

The defects were closed using keystone flaps. All flaps survived without problem of vascularization (Figure 5, 8, 11), despite of its large defect, sequence of radiotherapy following reconstruction, infection, and with its margin unable to be freed from tumor. All surgeries were intraoperative consulted from the other division, and the mean time of surgery is 160 minutes. One out of three cases suffered from contaminated wound from stomal leakage, leading to dehiscence (Figure 11).

PATIENT AND METHOD

Given the universal distribution of perforators with the subcutaneous vascular support, keystone flap is potentially suitable for all areas of the body from head to toes, including the abdomen. Abdomen region has natural elasticity, which combines well with the multi-axial tissue recruitment of the flap. The keystone skin island is based on the randomly located perforators and there is no need to specifically identify these perforators.³

One patient in our experience was in a younger age group, here too the skin extensibility is less favorable for this technique compared to an older population group as seen with previous cases series mentioned in the literature.^{2,3,5} The favorable success seen in this series suggest that variety patient age is safe for use of this flap. The robust circulation of the keystone flap, along with its rapid healing, makes it an ideal form of reconstruction where radiotherapy is anticipated in the postoperative setting. It provides reliable healing, minimal morbidity and timely commencement of

In no case was it necessary to either preoperatively identify any perforator vessel supplying the flap or attempt to visualize it during dissection. Thus, preoperative imaging by Doppler or any other modality was not needed at all. Simpler operative technique usually converts into lesser operative time for the procedure, especially compared to alternative options of pedicled or free flap transfers. All these issues collectively convince us that the keystone flap does indeed have a shorter learning curve.

Thus, Keystone flaps achieve primary wound healing for a wide spectrum of defects with minimal pain and good aesthetic outcome. The technique in those patients possibly can obviate the need for microsurgical procedures, skin grafts, and extensive operative time. As a more physiological procedure, the hospitalization time, recovery, mobilization and rehabilitation periods. This outcome can be reproduced with consistently good result.³

CONCLUSION

The case series have shown that keystone flap is a useful and reliable random perforator-based flap, even in complex and challenging malignant cases of abdominal wall.

Corresponding author :

Nurliati Sari Handini
nshandini@gmail.com

REFERENCES

1. Sudjarmiko G. Petunjuk Praktis Ilmu Bedah Plastik dan Rekonstruksi. Ed 4. Jakarta: Lingkar Studi Bedah Plastik; 2015.
2. Sudjarmiko G, Pribadi S, Supit L. Random Perforator Flap : Some Experiences with Keystone Flap. *JurPlastRekons* 2013;2:42-46.
3. Behan FC, Wilson I. The principle of the angiotome, a system of linked axial pattern flaps. Paris: Masson; 1975.
4. Behan FC, Findlay M, Lo CH. The keystone perforator island flap concept. Australia: Elsevier Australia; 2012.
5. Bhat SP. Keystone flaps in coloured skin: Flap technology for the masses. *Indian Journal of Plastic Surgery* 2013; 46:1: 36-47.