

Frontal Suspension Procedure using Frontalis Muscle for Management of Ptosis

Hardisiswo Soedjana
Bandung, Indonesia

Background : Ptosis has a reputation as a cosmetic problem, but it is more often as a functional deficit that can have real impact on patients' lives. Ptosis results from the dysfunction of one or both of the upper eyelid retractors and often blocks peripheral vision. Ptosis can be congenital or caused by aging. Frontal suspension is one of few techniques for correction of ptosis especially for severe ptosis.

Patient and Method : We reported one case of severe ptosis. The patient had bilateral congenital ptosis at both of upper eyelids. The upperlid excursion was 4 mm and marginal reflex distance (MRD) was 2 mm. A frontal suspension procedure using frontalis muscle was done for correction.

Result : After frontal suspension procedure, MRD are 5 mm for both eyes. There were no difficulty for closing the eyes. The cosmetic appearance was good. Patient was satisfied with the result.

Conclusion : Frontal suspension procedure using frontalis muscle gives a good function and cosmetic result for severe ptosis.

Keywords : *Ptosis, frontal suspension*

Latar Belakang : Ptosis merupakan suatu gangguan yang erat kaitannya dengan masalah kosmetik, tetapi lebih dari pada itu, gangguan fungsi merupakan masalah yang lebih berdampak kepada pasien. Ptosis terjadi karena gangguan pada retractor kelopak mata atas dan sering menghalangi penglihatan. Ptosis dapat terjadi secara congenital maupun akibat proses penuaan. *Frontal suspension* merupakan salah satu teknik untuk mengkoreksi ptosis terutama pada ptosis derajat berat.

Pasien dan Metode : Kami melaporkan 1 kasus dengan ptosis berat. Pasien memiliki kelainan ptosis kongenital bilateral pada kelopak mata atas. *Upperlid excursion* pasien ini 4 mm dan *marginal reflex distance (MRD)* 2mm. Prosedur *frontal suspension* telah dilakukan dengan menggunakan otot frontalis untuk mengkoreksi kelainan ini.

Hasil : Setelah prosedur *frontal suspension*, MRD menjadi 5 mm pada kedua mata. Tidak ada kesulitan untuk menutup mata. Penampakan secara kosmetik baik. Pasien merasa puas terhadap hasilnya.

Kesimpulan : Prosedur *frontal suspension* menggunakan otot frontalis memberikan perubahan fungsi dan kosmetik yang baik untuk ptosis derajat berat.

Kata Kunci : *Ptosis, frontal suspension*

Received: 23 September 2013, Revised: 20 November 2013, Accepted: 28 November 2013.
(*Jur.Plast.Rekons.* 2013;3:131-135)

P tosis has a reputation as a cosmetic problem, but it is more often as a functional deficit that can have real impact on patients' lives. Ptosis is abnormally low-lying upper eyelid margin with the eye in primary gaze. The normal adult upper lid lies 1.5 mm below the superior corneal limbus and is highest just nasal to the pupil.¹

Based on age, ptosis can be classified to congenital (simple and complicated) and

acquired. The most common congenital ptosis is caused by myogenic, meanwhile acquired ptosis is caused by aponeurotic involuntarily changing.² Simple congenital ptosis occurred because of developmental dystrophy of levator muscle. Complicated congenital ptosis occurred when associated with developmental abnormality of surrounding structures like Horner syndrome, Marcus Gunn ptosis, and blepharophimosis syndrome.^{2,3}

Typical feature of aponeurosis ptosis are lid drop as opposed to a lid lag on down gaze, ptosis that is constant in all position of

*From the Division of Plastic Reconstructive and Aesthetic Surgery, Department of Surgery, Faculty of Medicine Universitas Padjajaran, Hasan Sadikin Hospital, Jakarta, Indonesia.
Presented in the 17th IAPS Scientific Meeting, Bandung, West Java, Indonesia.*

Disclosure: *The authors have no financial interest to declare in relation to the content of this article.*



gaze, good levator function, a high skin crease, an upper lid sulcus, thinning of the eye lid often with iris viable though the closed eye.^{2,4}

Ptosis can be measured with three measurements such as marginal reflex distance (MRD), levator function (upperlid excursion), and interpalpebral distance or vertical fissure height (Figure 1).⁵

Vertical fissure height is distance between upper and lower lid margins. Normal upper lid margin rest about 2mm below upper limbus. Normal lower lid margin rest 1mm above lower limbus. Amount of unilateral ptosis is determined by comparison.⁵

Indication of surgery for ptosis are congenital ptosis and acquired ptosis after treatment of the causes failed or impossible. Meanwhile, contraindication of surgery are complete 3rd nerve paralysis (except after treatment of paralytic squint to prevent diplopia) and corneal anesthesia or absence of Bell's phenomenon.^{5,6}

There are few surgical procedures for management of ptosis. There are Fasanella Servat operation, Muller muscle resection, levator resection (Blascovic's or Everbusch's operation), levator aponeurosis advancement (Figure 2).⁵

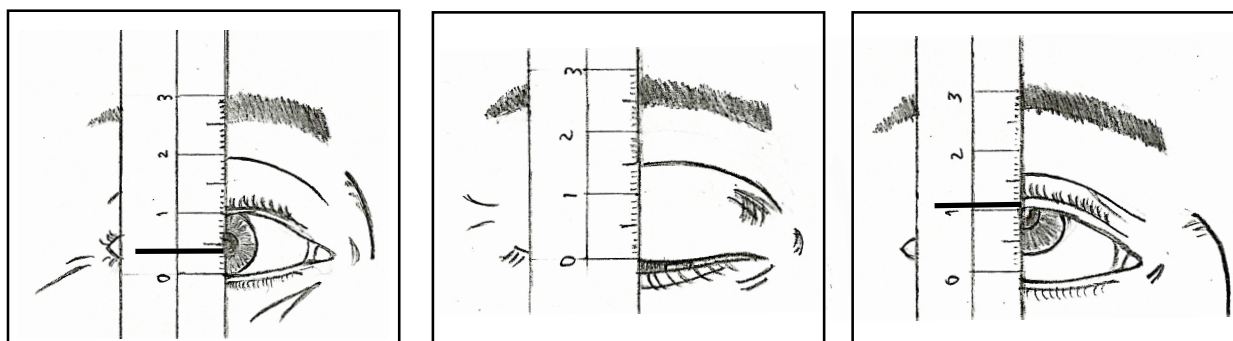


Figure 1. **Left:** Marginal reflex distance (MRD) measurement. The zero mark of the millimeter rule is aligned with the corneal light reflex and the distance to the upper eyelid margin is measured. The MRD is 4 mm in this schematic. **Middle and Right:** Levator function measurement. The zero mark is aligned with the upper eyelid margin with the patient looking in far down gaze. The patient is then asked to look up. The total excursion of the upper eyelid is recorded. The levator function is 11 mm in this schematic.

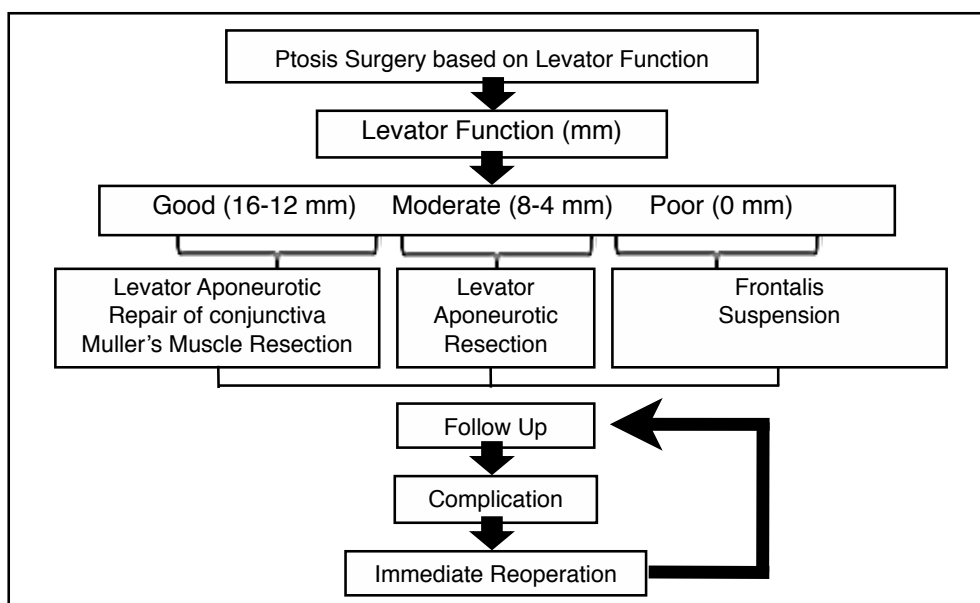


Figure 2. The procedures for correction of ptosis based on levator function. (From Blepharoptosis: Evaluation, Techniques, and Complications, Ahmad, 2007)

The frontal suspension technique is reserved for patients with poor levator function (0 to 4 mm) and intact frontalis muscle.^{7,8} It is the most commonly performed procedure in cases of congenital myogenic ptosis and external ophthalmoplegia. This technique involves elevating the eyelid by suspending the tarsus to the frontalis muscle. It is usually performed bilaterally and considered in unilateral cases with compensatory elevation of the brow.^{7,8}

A variety of sling material has been used. Autogenous fascia lata is useful in children and has a low risk of infection but requires harvesting tissue from a donor site. Other materials, such as frontalis muscle, catgut, collagen, polypropylene, silicone, stainless steel, silk, skin, sclera, tantalum, tarsus, and recently Mersilene mesh, umbilical vein, tendon, and other new synthetics have been tried.^{4,7}

Aponeurotic ptosis is caused by defect in the aponeurosis linkage between levator muscle and tarsal plate, for instance, Frank disinsertion of the aponeurosis from tarsal plate, dehiscence in the aponeurosis, involutional stretching and redundancy of the aponeurosis.⁴

PATIENT AND METHOD

Thirty-three year old male came with chief complain couldn't fully open the eyes. It had happened since he was a child. We measured the MRD, it was 2 mm and the levator function measurement (upperlid excursion) was 4 mm. The patient had severe bilateral congenital ptosis.

We performed a frontal suspension procedure using frontalis muscle as a sling. The frontalis muscle from both sides were cut longitudinally, the width is 20 mm each. Part of frontalis muscle then rotated infero-medially and suspended to upper eyelid levator aponeurosis on both sides, we made the attachment carefully with polypropylene 5.0.

After frontal suspension procedure on both eyes, MRD became 5 mm for both eyes. There are no difficulty for closing the eyes. The

cosmetic appearance was good. Patient was satisfied with the result.

RESULT

After frontal suspension procedure on both eyes, MRD became 5 mm for both eyes. There are no difficulty for closing the eyes. The cosmetic appearance was good. Patient was satisfied with the result.

DISCUSSION

Patient had a severe congenital ptosis bilateral on both eyes since he was a child. The measurement of levator function was poor (4 mm for both eyes). The MRD was 2 mm each. These ptosis occurred because of developmental dystrophy of levator muscle. This condition made the levator muscle couldn't elevate tarsus completely.²

In congenital ptosis, if there are no signs of amblyopia, strabismus, and abnormal head posture present, it can be monitored every 3-12 months using external photographs. Head postures should carefully examined, if the patient acquires a chin up posture due to the worsening of ptosis, surgery may be indicated.⁴ For mild and moderate ptosis (pupil uncovered with good vision and no torticollis), surgery can be done at age of 3-5 years old. Meanwhile, for severe ptosis, surgery can be done at younger ages, even at the age of 6 months to avoid amblyopia.⁶

The indication of surgery for this patient were to get better function and correct the cosmetic appearance. We used frontalis muscle as a sling for frontal suspension procedure because the function of levator muscle were poor, so it needs a additional force to elevate the tarsus.^{4,7}

The frontalis muscle from both sides were cut longitudinally, the length depends on the distance between origo of frontalis muscle to levator aponeurosis of the eyelid. Part of frontalis muscle then rotated infero-medially and suspended to upper eyelid levator aponeurosis on both sides with nonabsorbable sutures (polypropylene 5.0). We should consider that rotating frontalis muscle makes the length become shorter and the attachment

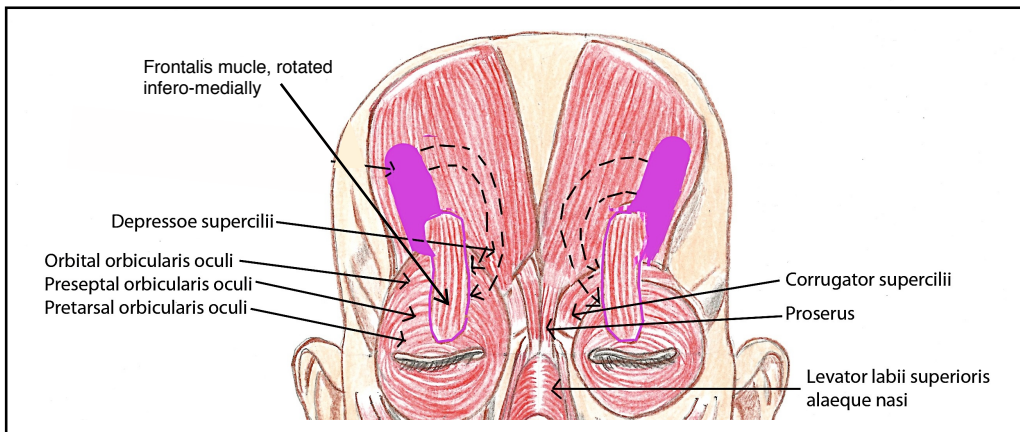


Figure 3. Part of frontalis muscle were rotated infero-medially, sutured to upper eyelid levator aponeurosis.

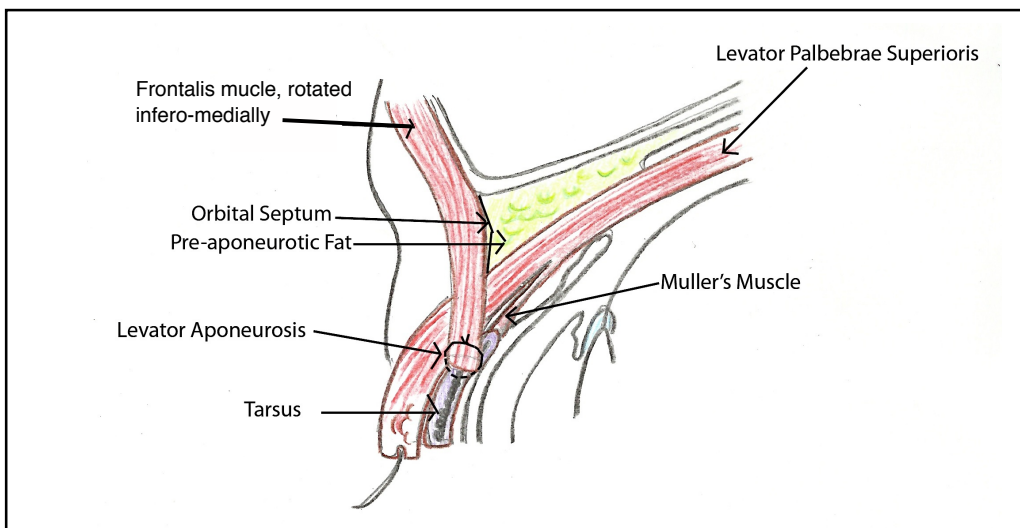


Figure 4. Lateral view of suspended frontalis muscle, sutured to upper eyelid levator aponeurosis.

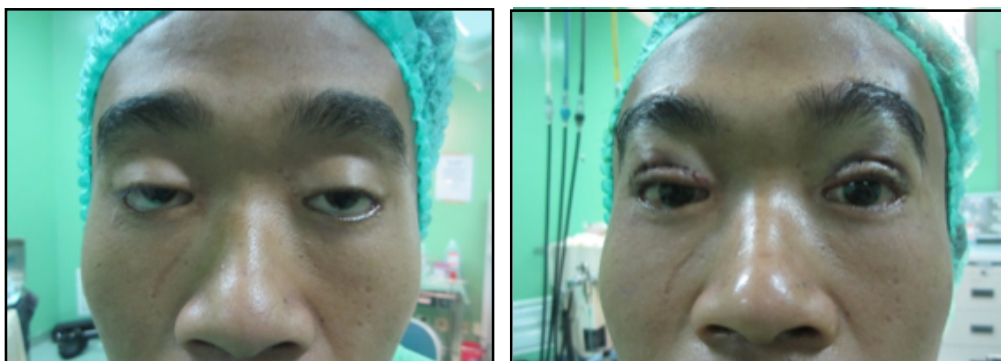


Figure 6. Left: Twenty-five year-old male with severe congenital ptosis bilateral (before surgery). **Right:** The appearance after frontal suspension procedure (immediate after surgery).

must be carefully suspended to get a best symmetrical result position for both upper eyelids, static and dynamic.^{5,7}

The result for this procedure is quite good. MRD has increased to 5 mm for both eyes. There were no complication neither undercorrection nor overcorrection, no poor or improper positioned lid crease. The cosmetic appearance was good.⁴

SUMMARY

Frontal suspension procedure using frontalis muscle is recommended for severe ptosis, especially when the function of levator muscle is poor. This procedure gives a good function and cosmetic result.

dr. Hardisiswo Soedjana
Plastic Surgery Division
Hasan Sadikin Hospital, Padjajaran University
hardisiswo.soedjana5@gmail.com

REFERENCES

1. Collin JRO. Ptosis. In: Manual of Systematic Eyelid Surgery. Oxford, England: Butterworth-Heinemann; 1999:41-72.
2. Sakol PJ, Mannor G, Massaro BM. Congenital and acquired blepharoptosis. *Curr Opin Ophthalmol*. Oct 1999;10(5):335-9.
3. Cohen AJ, Weinberg DA, eds. Evaluation and Management of Blepharoptosis. 1st. New York, NY: Springer-Verlag; 2010.
4. Leatherbarrow B. Blepharoptosis. In *Oculoplastic Surgery*. 2nd edition. Infoema healthcare. 2011
5. Ahmad SM, Rocca RC. Blepharoptosis: Evaluation, Tehcniques, and Complications. *Facial Plastic Surgery*. 2007. Vol. 23;3:203-215.
6. Jordan D. Ptosis in Children. in *Insight*. 2010
7. Crawford J S. Repair of ptosis using frontalis muscle and fascia lata: a 20-year review . *Ophthalmic Surg* 1977; 8:31-40.
8. Leone CR Jr, Shore JW, Van Gemert JV. Silicone rod frontalis sling for the correction of blepharoptosis. *Ophthalmic Surg* 1981;12:881-88