

## Random Perforator Flap : Some Experiences with Keystone Flap

Gentur Sudjatmiko, Sweety Pribadi, Lauren Supit  
Jakarta, Indonesia

**Background:** In reconstructing challenging defects, surgeons are considered fairly fortunate when they are able to obtain a similar donor tissue quality to that of the missing tissue; in regards to their color, texture, size, and the ease of donor transfer to the defect. Several methods may be used, which frequently include the free tissue transfers using microvascular anastomoses bearing their specific consequences. We report a select of challenging cases which were successfully reconstructed using the Keystone flaps and avoid microvascular anastomoses, where otherwise the free tissue transfers would be the typical option for closure in such defects.

**Patient and Method:** Nine cases of relatively large defect in various locations were reconstructed using the Keystone flaps supplied by either non-identified perforators or identified reliable perforators.

**Result:** Out of the 9 defects located on various region of the body (lumbar, thorax, dorsum of the foot, plantar of the foot, posterior leg, sacrum, and cervicofacial) only the first 2 cases had identifiable perforators. All flaps survived completely without problem of vascularization.

**Summary:** The Keystone flap is a useful and reliable random perforator-based flap even when the perforator vessels are not identified.

**Keywords:** *Keystone flap, small perforators, perforator flap*

**Latar Belakang:** Dalam rekonstruksi sebuah defek, dokter bedah dianggap beruntung bila memiliki donor yang kualitasnya menyerupai defek dari segi warna, tekstur dan kedekatan lokasinya dengan defek. Berbagai macam metode telah dikembangkan, yang terakhir adalah teknik anastomosis mikrovaskular dengan berbagai konsekuensinya. Pada laporan kasus berikut ini kami menyajikan beberapa kasus rekonstruksi defek yang dikerjakan tanpa teknik mikrovaskular, dan hasilnya pun cukup menjanjikan.

**Pasien dan Metode:** Kami mengumpulkan berbagai kasus dengan defek yang relatif besar dan kami lakukan rekonstruksi dengan *flap keystone* yang disuplai dengan perforator besar yang teridentifikasi maupun perforator kecil yang tidak teridentifikasi.

**Hasil:** Dari 9 kasus defek di region lumbal, torakal, dorsum pedis, plantar pedis, kruris posterior, sakrum dan servikofasial, hanya 2 kasus pertama yang memiliki perforator teridentifikasi. Seluruh flap vital tanpa gangguan vaskularisasi.

**Ringkasan:** *Flap keystone* adalah flap yang berguna dan dapat diandalkan bahkan ketika pembuluh darah perforatornya tidak teridentifikasi.

**Kata Kunci:** *Keystone flap, small perforators, perforator flap*

Received: 12 May 2013, Revised: 25 May 2013, Accepted: 15 June 2013.  
(*Jur.Plast.Rekons.* 2013;2:42-46)

Defects on the human body requires reconstruction. Open wounds may cause chronic pain, inability to ambulate, significant medical expenses, and unemployment. Exposed tendons and bones become dry and necrotic and exposed blood vessels are at risk for rupture.<sup>1</sup>

The major reconstructive strategies for surgeons are skin grafts and flaps. Surgeons are

fairly fortunate if they can obtain a donor tissue of similar quality to the lost tissue in regards to its color, texture and size, with close proximity of donor to the defect. Options of closure methods range from grafts, local flaps, regional flaps, and the more-recently favored distant tissue transfer with microvascular anastomosis. Free tissue transfers are technically more demanding, takes longer to perform, and does

*From the Division of Plastic Reconstructive and Aesthetic Surgery, Department of Surgery, Faculty of Medicine Universitas Indonesia, Cipto Mangunkusumo Hospital, Jakarta, Indonesia.  
Presented in the 17<sup>th</sup> IAPS Scientific Meeting, Bandung, West Java, Indonesia.*

**Disclosure:** *This work did not receive support from any grant, and no author has any financial interests*

not always provide the same tissue quality that compares to neighboring tissue. We present several cases of challenging defect reconstructions using the Keystone flap, where typically the free flaps would be the choice of reconstruction, evading the need of microvascular anastomoses.

Keystone is an architectural term referring to a wedge-shaped material placed on the peak central of the arcus, made to support the arch through gravity (Figure 1). The Keystone design perforator island flap was first published by Felix C Behan in 2003. It is described as “a curvilinear-shaped trapezoidal design flap”. Keystone concept is derived from Behan’s earlier work on the angiotome principle in 1975, where each angiotome may be safely raised as a flap, or extended by linkage vessels with an adjacent angiotome.<sup>2</sup>

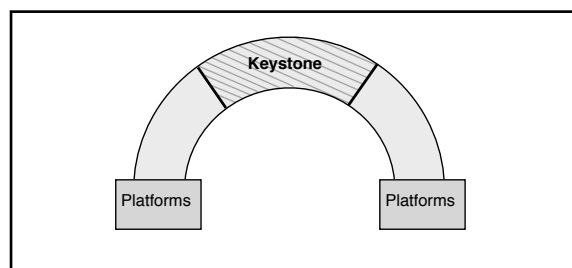


Figure 1. The keystone shape

Cutaneous perforators reach the skin by numerous different courses, either direct, through the fascial septae, fascia, muscle, or bone. The density of these vessels varies in different body areas ie. reticular dermis in the face is five times more vascularized than foot sole. This holds clinical implications in raising the flaps. Cormack and Lamberty type A flaps are usually the most common pattern for Keystone flaps. Given the universal distribution of perforators with the subcutaneous vascular support, Keystone flap is potentially suitable for all areas of the body from head to toes.<sup>4</sup> The Keystone skin island is based on the randomly located perforators and there is no need to specifically identify these perforators. The advantages of this kind of perforator flap are its simple to design, robust vascular supply, a more reliable healing, shorter operative time, minimal patient morbidity, with a relatively pain-free surgery, good aesthetic outcome, and a more cost-effective wound closure.

### PATIENT AND METHOD

From January of 2012 to March of 2013, the Keystone flap was performed in 9 patients with defects in various region of the body including the lumbar, thorax, dorsum of the foot, plantar of the foot, posterior leg, sacrum,

Table 1. Patient demographic and surgical details

Case	Age	Sex	Cause	Location	Size (cm)	Perforator	Op Time (min)
1	37 ds	F	Celle extirpation	Lumbar	4 x 8	Identified	90
2	24 yr	M	Malignant tumor	Thorax	10 x 10	Identified	90
3	18 yr	F	Contracture	Dorsum pedis	3.5 x 12	Unidentified	60
4	50 yr	F	Diabetic ulcer	Plantar pedis	3 x 12	Unidentified	120
5	45 yr	F	Malignant tumor	Cruris	9.5 x 7	Unidentified	90
6	47 yr	M	Pressure sore, spinal tumor	Sacrum	4 x 8	Unidentified	45
7	62 yr	M	Pressure sore, cerebrovascular disease	Sacrum, left trochanter, left calcaneus	10 x 12 6 x 7 2.5 x 2	Unidentified	120
8	6 mo	F	Vascular malformation	Posterior cruris	5 x 2.5	Unidentified	60
9	53 yr	M	Malignant tumor	Cervicofacial	7 x 4	Unidentified	60
<b>Mean</b>	33.2 yr				5.9 x 7.7		81.6

M, Male; F, female; Op, operative

and cervicofacial area. Etiology of the defects varies from diabetic ulcer, pressure ulcer, malignant tumor, joint contracture, and vascular malformation. The mean age of the patients is 33.2 years old. Four patients are male and the rest are female. The oldest patient had multiple defects due to pressure ulcer. The mean size of the defect is 5.9 x 7.7 cm. Patients' characteristics are summarized in Table 1.

### Cases

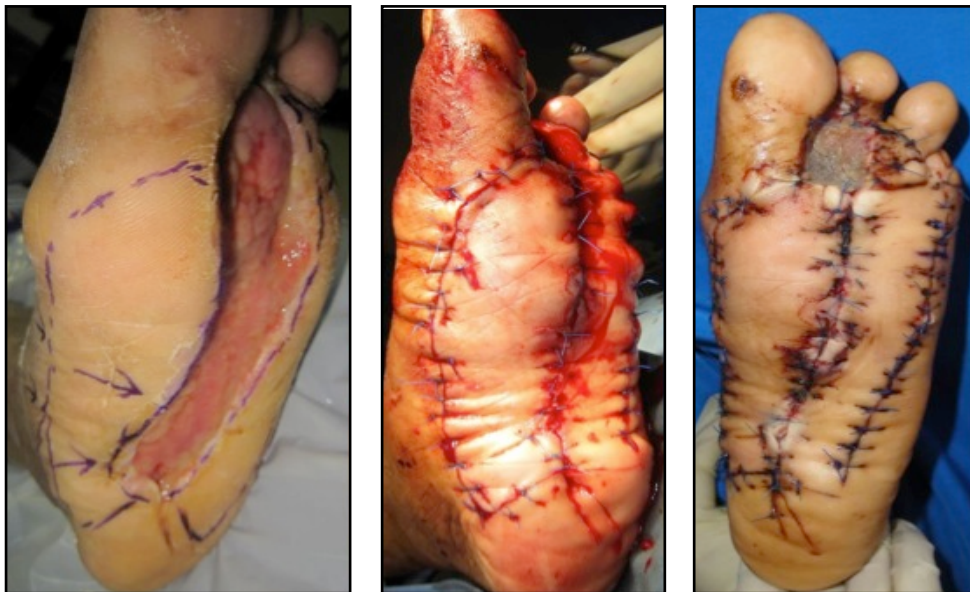Case number 4 is a 50-year-old female with plantar chronic diabetic ulcer of the left foot (Figure 2). She had difficulty walking and was frustrated about her limited gait. The type III Keystone island flap was raised from bilateral sides of the defect. In order to preserve vascularization of the first toe, the design of the medial flap should be placed not too close with the first toe. A portion of the defect on the proximal metatarsal of the middle toe was not covered by the flap and was covered using the split thickness skin graft.

Case number 8 is A 6-month-old baby girl with capillary type vascular malformation on the posterior of her right leg (Figure 3). The size of the malformation was 5 x 2.5 cm, excised in whole up to the fascia. The defect was reconstructed with type II keystone flap.

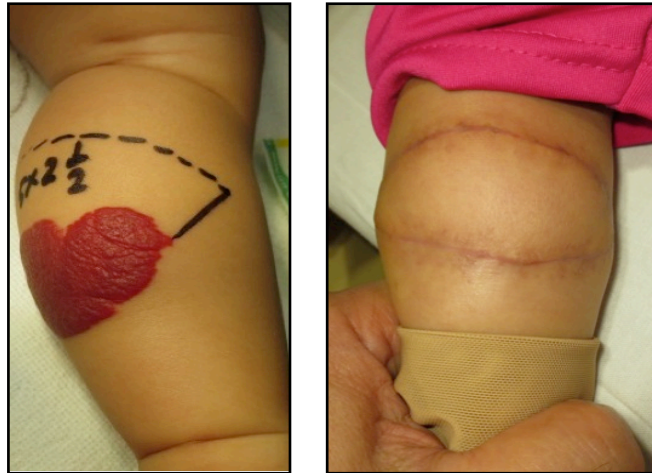
Case number nine was a a 53-year-old male with a prior excision of the lower lip due to malignancy, and reconstruction with local flaps. He underwent reexcision due to a suspected recurrence. The resultant defect was reconstructed using the type II keystone flap as illustrated in Figure 4.

### RESULT

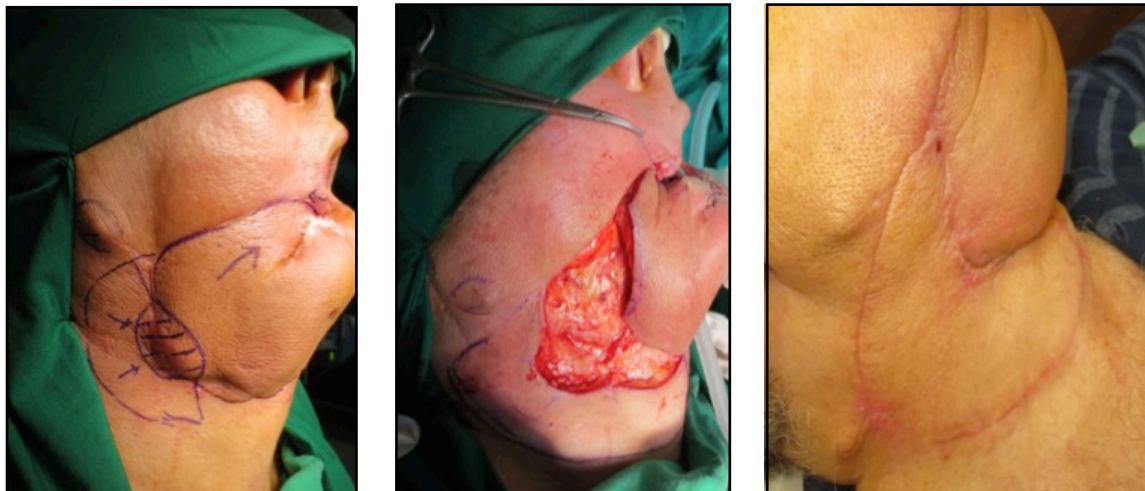
The results are summarized in Table 1. The keystone island flaps were used to reconstruct all defects in 9 patients. In two patients, the perforator were identified; at the lumbar and thoracic region. All surgeries were elective, and the mean time of surgery is 81.6 minutes. All flaps survived completely without any vascular problems, and patients were satisfied with the results.



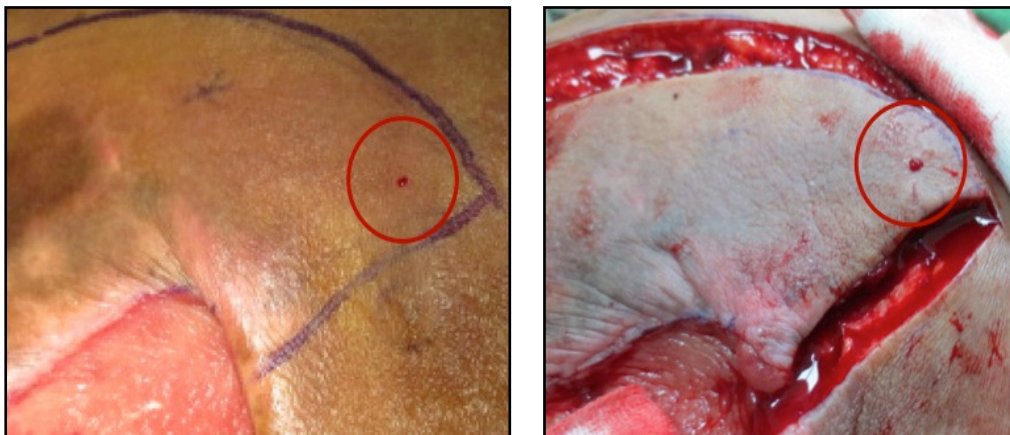
**Figure 2.** Female, 50-year-old with chronic plantar diabetic ulcer. **Left** : Bilateral Keystone flap design. **Center** : immediately postoperative. **Right** : five days postoperative (right).



**Figure 3.** Six-month-old baby girl with capillary type vascular malformation on the posterior right leg. **Left** : before excision. **Right** : one month postoperative.



**Figure 4.** **Left** : A 53-year-old male with prior history of reconstructed lower lip after malignancy excision, with keystone flap design. **Center** : after re-excision due to suspected recurrence. **Right** : The defect was closed using the keystone flap with satisfactory postoperative result.



**Figure 5.** **Left** : The red dot sign before islanding. **Right** : After islanding the flap.

## DISCUSSION

The keystone flaps were used to reconstruct nine defects from various body parts, with 100% success rate in this case series, demonstrating its reliability. The color, texture, and sensibility of the closed defect are similar to its neighboring tissue, because the donor are also obtained from nearby tissues. After surgery, patients were relatively pain free. The reason to this, as explained by Behan, is that the circumferential division or islanding of tissue results in a partial sympathectomy of the flap. It increases the cutaneous blood flow (up to 5-fold), raises skin temperature by  $>2^{\circ}\text{C}$ , and improves rest pain such as in lumbar sympathectomy.<sup>3</sup> This phenomena is clinically marked by the red dot sign (Figure 5) and vascular flare in the immediate phase, while in the delayed phase the relatively pain-free postoperative period is typically experienced by the patients .

The keystone flap design, elevation and inseting were straightforward and non-complicated. The mean time of surgery is 81.6 minutes. The longest duration was 120 minutes, in 2 cases, where the surgery involved closure of 3 defects in a single surgery, and another case required STSG.

## SUMMARY

The case series has shown that the keystone island flap is a versatile, reliable, and technically straightforward reconstructive method, that can be implemented from head to toe. It does not require a specific set of training or equipments, and can be performed either by an adept or expert reconstructive surgeon equally.

**Gentur Sudjatmiko M.D.**

*Plastic Surgery Division*

*Cipto Mangunkusumo General National Hospital  
Jalan Diponegoro.No.71, Gedung A, Lantai 4.*

*dr\_gentur@yahoo.co.id*

## REFERENCES

1. Parret BM, Pribaz JJ. Lower extremity reconstruction. *Rev Med Clin Condes* 2010; 21(1): 66 – 75.
2. Behan FC, Wilson I. The principle of the angiotome, a system of linked axial pattern flaps. Paris: Masson; 1975.
3. Behan FC, Findlay M, Lo CH. The keystone perforator island flap concept. Australia: Elsevier Australia; 2012.
4. Pelissier P, et al. The keystone design perforator island flap. Part II. *JPRAS* 2007;60(8).