

# RECONSTRUCTIVE

## Reconstruction of Traumatic Partial Ear Amputations Using Two-Stage Skin Flap Pocket Technique

Intan Friscilla Hakim, Prasetyanugraheni Kreshanti, Siti Handayani, Kristaninta Bangun  
Jakarta, Indonesia

**Background:** Various reconstructive techniques for partial traumatic ear amputations have been reported. The choice of technique is based on the missing ear components and the availability of tissue for defect coverage. The goal is to obtain an aesthetically acceptable ear. The authors report a two-stage skin flap pocket technique for the reconstruction of traumatic ear amputations.

**Patient and Method:** Three cases of partial traumatic ear amputation due to bite is reported. After sufficient debridement, skin flap pocket was created on the retroauriculomastoid area. Conchal cartilage graft was used to replace cartilage defect in one case. The other 2 cases utilized their amputated cartilage graft, deepithelialized and then resutured to the remaining cartilage. All three cases underwent second stage surgeries for flap division, three weeks after the pocketing.

**Result:** In 2 months follow-up, all of 3 cases showed no signs of infection. Normal dimension of the ears were achieved and aesthetic appearances were perceived as acceptable to the patients and other viewers. One case was able to be followed one year post surgery with acceptable aesthetics, and no sign of cartilage resorption.

**Summary:** The technique used in these cases provided acceptable results in reconstructing the size and shape of the partially amputated ears. Cartilage grafts implanted in the pockets retained their shape with no infection or resorption.

**Keywords:** Ear amputation, partial ear amputation, pocketing technique, dog-bite to the ear, conchal graft

**Latar Belakang:** Berbagai teknik rekonstruksi untuk kasus amputasi telinga parsial akibat trauma dapat ditemukan dalam literatur. Pemilihan tekniknya akan bergantung pada komponen telinga yang teramputasi, dan ketersediaan jaringan lunak di sekitarnya untuk menutup defek. Tujuan dari rekonstruksinya adalah mengembalikan penampilan estetik telinga. Penulis melaporkan teknik *pocket* menggunakan flap kulit, dua tahap.

**Pasien dan Metode:** Tiga kasus traumatik amputasi parsial telinga akibat luka gigitan dilaporkan. Setelah dilakukan *debridement*, dibuat kantung *skin flap* pada daerah retroaurikulomastoid. Pada satu kasus, kehilangan kartilago diganti dengan menggunakan graft kartilago dari concha. Dua kasus lain menggunakan potongan telinga yang teramputasi, dengan deepitialisasi kartilago, dan kartilago disatukan kembali dengan kartilago telinga yang tersisa. Pada ketiga kasus, operasi tahap kedua dilakukan untuk memotong flap, 3 minggu setelah tindakan *pocketing*.

**Hasil:** Pada follow-up 2 bulan pascaoperasi, ketiga kasus tidak menunjukkan tanda infeksi. Dimensi normal telinga tercapai dan tampilan estetik diterima dengan baik oleh pasien dan orang lain yang melihatnya. Pada satu kasus, follow-up dapat dilakukan hingga 1 tahun setelah operasi dengan hasil estetik baik dan kartilago tidak diserap.

**Ringkasan:** Teknik yang digunakan pada ketiga kasus yang dilaporkan dapat menghasilkan ukuran dan bentuk telinga yang baik pada telinga yang teramputasi. Graft-graft kartilago yang diimplantasi ke dalam kantung (*pocket*) tidak mengalami infeksi maupun resorpsi.

**Kata Kunci:** Ear amputation, partial ear amputation, pocketing technique, dog-bite to the ear, conchal graft

Received: 4 September 2012, Revised: 1 February 2013, Accepted: 15 February 2012.  
(*Jur. Plast. Rekons.* 2013;1:6-9)

Reconstruction of the external ear following traumatic amputation remains one of the most challenging reconstructive procedure. In most cases of auricular amputation, the amputee is brought to the emergency room by the patient, with expectation that it can be reattached.<sup>1</sup> At times the amputee may be lost during the accident,

and this will be more difficult to reconstruct. The plan will depend on the remaining auricular component, if there is any, and its neighboring available tissue.<sup>2</sup> The goal of reconstruction is to attain the most satisfactory aesthetic appearance in symmetrical regard to the contralateral non-trauma auricle.

Traumatic ear amputation due to bite is

From the Division of Plastic Reconstructive, and Aesthetic Surgery University of Indonesia Cipto Mangunkusumo Hospital, Jakarta, Indonesia.  
Presented in 16th IAPS Scientific Meetings In Medan, North Sumatra, Indonesia

**Disclosure:** The authors have no financial interest to declare in relation to the content of this article.

distinct to the other causes of amputation such as accident, burn, or torture.<sup>1</sup> Wounds due to human or animal bite is classified as highly contaminated wound and is mandatory to perform a thorough early debridement before definitive reconstruction is done later.<sup>3</sup> Human bite is considered more contaminated than animal bite.<sup>4</sup> If the patient arrives in the emergency department early after the insult, primary closure may be attempted immediately if wound debridement is deemed adequate.<sup>5</sup> Auricle differs from other body parts due to the thin dermal layer covering its complex cartilage contour tightly. Specifically in auricular amputation due to bite injury, the edges of the amputated ear are often irregular, and more tissue loss is anticipated after debridement.<sup>4</sup>

There have been many reported techniques for the reconstruction of partial ear amputation. The reconstructive plan will depend on the location of the defect and the extent of tissue loss, each of them as a unique case.<sup>2</sup> Microvascular replantation is the best method for replanting the amputated ear with excellent aesthetic results, provided that the procedure is successful. Patients ineligible for microvascular anastomosis may utilize other modalities such as the temporoparietal fascia flap, retroauricular pocketing procedure, or staged costal cartilage reconstruction, depending on the ear defect.<sup>6</sup> In a literature review, Ihrai T and colleagues opted between nonmicrosurcigal ear reattachment and the retroauricular pocketing technique based on the size of the amputated part and involvement of the ear lobe. Ear reattachment as composite graft can be achieved when the amputated part is smaller than 15 mm or when it involves the earlobe. Pocketing technique is appropriate for the replantation of auricular cartilage and can be used when the amputated part is bigger than 15 mm, with non-comprised earlobe.<sup>7</sup> However, reattachment as a composite graft of the total or subtotal amputated ear is unreliable with very unpredictable result.<sup>8,9</sup> The two-stage reconstruction with autologous cartilage graft has been previously described and is based on adaptations from the Nagata modification of Brent's original technique. Such was reported by Pearl in 2011.<sup>1</sup>

## **PATIENT AND METHOD**

Three cases of partial ear amputation due to bite presented to the Cipto Mangunkusumo Hospital, Jakarta between September 2010 to February 2012. All cases arrived at the

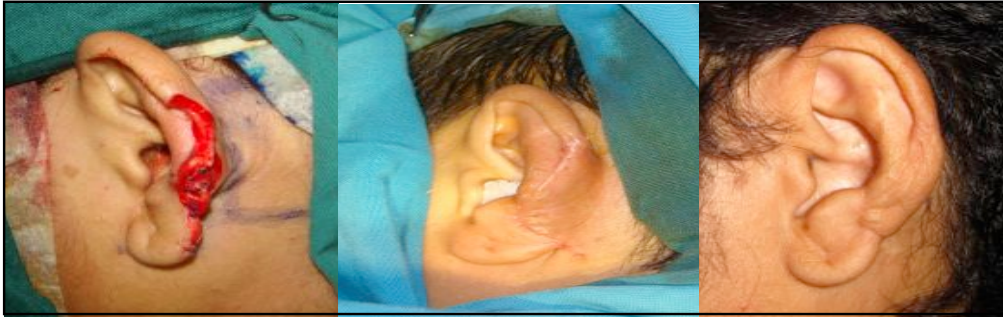emergency room within 24-hour after the incident.

### **Case 1**

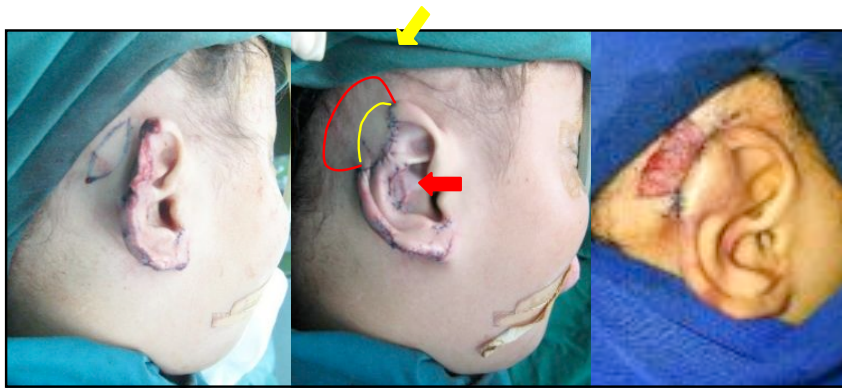
The first case was a 52-year-old female with partial amputation of the middle third left auricle, bitten by her grandson 6 hours prior to admission. Amputee was preserved in a clean dry plastic bag. Patient underwent debridement in the emergency operating theater under general anesthesia. Cartilage was preserved from the amputee by skinning off its dermal and epithelial layers. The nude cartilage was then sutured on to the remnant auricle, then covered by a retroauriculomastoid skin pocket. After 25 days, patient underwent the second stage surgery. Skin pocket containing the cartilage was elevated, by including a skin flap extended beyond the cartilage edge, which was then folded posteriorly to cover for the posterior surface of the elevated cartilage. Donor area was closed by primary suture. Final appearance one year after the second stage surgery was acceptable. The pocket flap covered the middle third ear and healed well without discoloration. Slight discontinuity is noted on the helical-lobular junction but is aesthetically acceptable for the patient. The reattached cartilage frame stayed well-defined without marked resorption. Hypertrophic scar developed on the retroauricular region, with slight itching and pain when the scar was compressed. Patient felt comfortable with the scar and did not request for revision surgery.

### **Case 2**

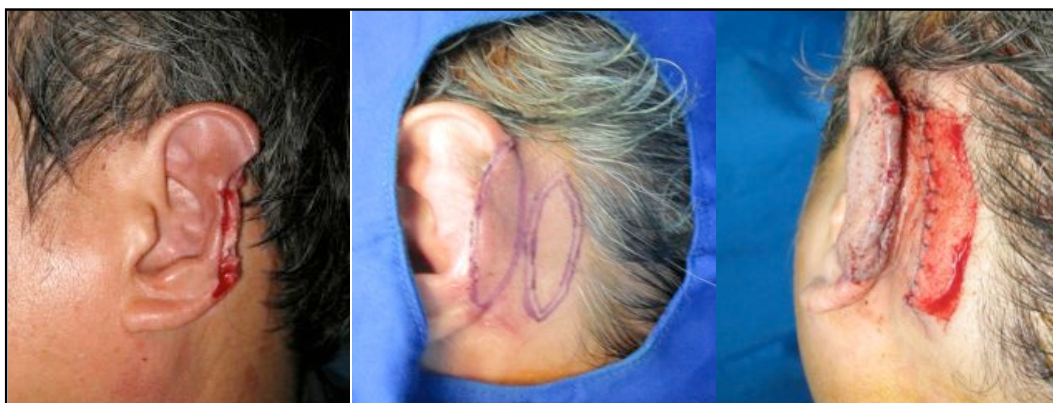The second case was a 3-year-old girl with partial amputation of the upper and middle third portion of the right auricle, presented in the emergency room 6 hours after bitten by a Rottweiler dog. The amputee was lost, perhaps swallowed by the dog. The right auricular helix was missing. Several scratches on the postauricular skin was found, and there was small skin avulsion on lobule, the size of 1 by 0.5 cm. Anti tetanus and anti rabies injections were administered. Patient underwent debridement under general anesthesia. Conchal cartilage graft from the affected ear side was harvested to form a helical frame, using the contralateral uninjured ear as the template. Conchal graft then sutured to the remaining attached cartilage and buried into a posterosuperior retroauricular skin pocket. After 25 days, she underwent a second surgery for flap division and cartilage elevation.



**Figure 1.** Patient in case 1. **Left:** After debridement and resuturing of salvaged cartilage. Marker on the retroauricular region is area for pocketing. **Middle:** Cartilage graft buried in the skin flap. **Right:** Twenty months after surgery.



**Figure 2.** Patient in case 2. **Left:** Traumatic partial ear amputation due to dog bite, after debridement. Markings on the retroauricular region denotes area of skin pocketing. **Middle:** Red arrow shows conchal donor area. Conchal graft was buried within the skin pocket (yellow arrow). **Right:** Flap division 25-days later. Posterior auricular defect covered with split-thickness skin graft.



**Figure 3.** Case number 3. **Left:** Amputated left auricle with the amputee. **Middle:** Graft buried in the skin flap pocket. Marker in retroauricular region is donor STSG area to cover posterior auricula defect. **Right:** Posterior cartilage site covered with STSG.

The secondary posterior auricular defect was covered using split-thickness skin graft harvested from the mastoid region.

### Case 3

The third case was a 51 year-old man with partial amputation of left auricle, presented to the emergency room 8 hours after his ear was bitten by his friend. The middle third of the ear was missing, the amputee was preserved in a clean dry plastic bag. Patient underwent debridement under general anesthesia. The first stage of reconstruction was similar with the procedure done for the patient in case 1. Twenty-six days later, flap division and cartilage elevation was performed, similar as in case number 2. Three cases of partial traumatic ear amputation were reconstructed using a two-stage skin flap pocketing technique. Two cases used their amputated cartilages as framework, while in one case a conchal cartilage was used. No infection nor cartilage resorption developed. One patient complained about hypertrophic scar on the donor site, and this was of donor area which underwent primary closure. All patients were adequately satisfied with the final results of reconstruction.

### DISCUSSION

There are many options to reconstruct the ear defects. In trauma, with missing parts of the ear, most will adapt the steps of microtia reconstruction, such as the Brent's or Nagata's techniques. Our two-stage flap pocketing procedure adapts the above techniques, modified into simpler ways due to the limitations in trauma setting. These include time limitation in emergency setting, tissue limitation for reconstruction, donor limitation, and other technical problems. These limit the surgeon from performing meticulous surgery.

Auricular trauma is unique due to its limitation in tissue availability. Usually in trauma, adjacent tissue suffered from destruction, causing unhealthy tissue and risk from more scarring. So plan should be done more carefully, and deliberate lifesaving boat prepared, if there should be an unpredictable outcome in the operating room. Missing cartilage components make the reconstruction more complex and take more time to accomplish.

Cartilage loss in auricular trauma must be replaced, especially if the defect is significant and there is loss of ear definition. The type of replacements need to be well considered. The option between obtaining cartilage graft from the ribs became one major consideration due to its risk of resorption, and donor morbidity. Several literatures summed that cartilage resorption takes place during different times. Some say it takes place after years, some say it can be seen within months. Observation of the cartilage graft should at least be followed-up within 2 months.

### SUMMARY

The technique used in this case series provides acceptable results in the reconstruction of partial traumatic ear amputation. Cartilage grafts implanted within the vascularized skin pockets maintained their shape well, with no development of infection or resorption.

**Kristaninta Bangun, M.D.**

*Plastic Surgery Division*

*Cipto Mangunkusumo General National Hospital*

*kristaninta@yahoo.com*

### REFERENCE

1. Pearl RA, Sabbagh W. Reconstruction following traumatic partial amputation of the ear. *Plast Reconstr Surg.* 2011;127: 621.
2. Brent B. The acquired auricular deformity. A systematic approach to its analysis and reconstruction. *Plast Reconstr Surg.* 1977;59(4):475-85.
3. Agarwal K, Mishra S, Panda KN. Primary reconstruction of major human bite wounds of the face. *Plast Reconstr Surg.* 1992;90:394.
4. Griego RD, Rosen T, Orengo I F, Wolfe JE. Dog, cat, and human bites: A review. *J Am Acad Dermatol.* 1995;33:1019.
5. Javaid M, Feldberg L, Gipson M. Primary repair of dog bites to the face: 40 cases. *J R Soc Med.* 1998;91:414.
6. Lin PY, Chiang YC, Hsieh CH, Jeng SF. Microsurgical replantation and salvage procedures in traumatic ear amputation. *J trauma.* 2010; 69(4):E15-9.
7. Ihrai T, Balaguer T, Monteil MC, Chignon-Sicard B, Médard de Chardon V, Riah Y, Lebreton E. Surgical management of traumatic ear amputations: literature review. *Ann Chir Plast Esthet.* 2009 April;54(2):146-51.
8. Pribaz JJ, Crespo LD, Orgill DP, Pousti TJ, Bartlett RA. Ear replantation without microsurgery. *Plast Reconstr Surg.* 1997;99(7):1868-7.
9. Elsayh NI. Ear replantation combined with local flaps. *Ann Plast Surg.* 1986 August; 17(2):102-11.