

Pitfalls in Rhinoplasty: Avoiding Mismatch Between Anatomy, Patient Expectation and Mastery of The Surgeon.

Imam Susanto

Jakarta, Indonesia.

Background: Aesthetic surgery is a component of Plastic Surgery which deals with a “normal” person with neither disease nor disfigurement. They seek surgery to enhance appearance, which is expected to boost confidence level and performance. Because aesthetic patient come with no physical deformity, their expectation for perfection is high. As plastic surgeons, we must be aware of the pitfalls in our works, how much can we deliver the expectations of patients as suited to our knowledge and our capability in mastering surgical technique including the implementation of new techniques combined with technology. Our awareness throughout each surgery, and the obsession for perfection must measure up to what the patient desire.

Patients and Method: A review of 3 augmentation rhinoplasty patient cases who come to my private practice between 2006-2012 with concern of postoperative results is presented, prior previous surgeries were done either by author or other surgeons.

Result: All patients received surgical counseling and scheduled correctional surgeries, nearly all patient accepted the final results and were satisfied.

Summary: Pitfalls are common in aesthetic surgeries. To prevent this, we must be aware all aspects involved starting from the first consultation with patient, carefully assess the anatomy and anomaly of each case, master the surgical techniques used, and careful when implementing new techniques. Finally, have the wisdom to say ‘no’ to patients who are not good candidates for aesthetic surgery.

Keywords: *pitfalls, aesthetic surgery, rhinoplasty*

Latar belakang: Bedah estetik adalah salah satu komponen dari bedah plastik yang menangani pasien ‘normal’ tanpa penyakit atau cacat tubuh. Umumnya, pasien ingin melakukan operasi untuk mempercantik penampilan, yang diharapkan dapat meningkatkan kepercayaan diri dan performa pasien itu sendiri. Dikarenakan pasien estetik umumnya datang tanpa deformitas tubuh, mereka memiliki harapan tinggi untuk menjadi sesosok sempurna. Sebagai ahli bedah plastik, penting untuk menyadari perangkat-perangkat dalam mengerjakan bedah estetik. Sebagai seorang ahli bedah plastik, dalam mewujudkan pengharapan pasien sebaiknya disesuaikan dengan pengetahuan kita dan kemampuan kita dalam menguasai teknik bedah termasuk implementasi teknik baru dikombinasikan dengan teknologi. Kesadaran ahli bedah plastik dalam pengerjaan operasi dan obsesi akan kesempurnaan harus diukur sejalan dengan keinginan pasien.

Pasien dan Metode: Tinjauan 3 kasus pasien pasca rhinoplasti yang datang pada klinik pribadi pada tahun 2006-2012 dipresentasikan dengan hasil pasca operasi. Dengan riwayat operasi sebelumnya yang telah dikerjakan oleh penulis sendiri atau bedah plastik lain.

Hasil: Seluruh pasien mendapat konsultasi bedah dan dilakukan koreksi bedah. Hampir seluruh pasien menerima hasil akhir operasi dengan baik dan merasa puas. minimal di daerah periareolar. Tidak ada satupun dari pasien mengalami komplikasi setelah pembedahan.

Ringkasan: Perangkat pada bidang bedah estetik banyak dan sering terjadi, untuk mencegahnya, kesadaran akan segala aspek harus disadari dimulai dari pertama kali pasien datang untuk konsultasi, memeriksa dengan hati-hati anatomi dan anomali setiap kasus, menguasai teknik bedah yang digunakan, dan teliti dalam mengimplementasikan teknik baru. Dan terakhir, berani untuk mengatakan “tidak” pada pasien yang tidak termasuk kandidat dalam operasi estetik.

Kata Kunci : *pitfalls, aesthetic surgery, rhinoplasty*

Pitfalls often found in the field of Aesthetic surgery practice. Conflict between surgeon concept of satisfactory results and patient’s expectation is one of source

problems. With no physical and prominent deformity found in aesthetic patients, high expectation for perfection may develop cautions problem for developing pitfalls cases.

Division of Plastic Reconstructive and Aesthetic Surgery, Universitas Indonesia, Ciptomangunkusumo Hospital, Jakarta Indonesia.

Presented in The 16th IAPS Scientific Meetings In Sibolangit, North Sumatra, Indonesia

Disclosure: *The authors have no financial interest to declare in relation to the content of this article.*

Aesthetic patients mostly has their own satisfactory concepts in their mind. This concepts influenced by environment and informative media among society , for example, some patient who brings along pictures of their favorite movie stars as a model, expecting the results to resemble what is seen in the photographs. Expectation during preoperative determine psychological condition after the surgery. Since the surgeon perspectives necessary concern ideal anatomic form and contours towards reconstruction or correction procedures, It is importance for surgeon to enriched their knowledge and learn anticipation management of pitfalls in aesthetic surgery.

Case of pitfalls usually correlate with various factors including the differences in perception between surgeon and patient regarding the process and outcome surgery, patient's great expectations, surgical anatomy and technique capabilities for surgeon, particularly in mastering new techniques and anomalies organs settings.

PATIENTS AND METHODS

Case 1

The first case is a 32 years old, female who had previously augmentation rhinoplasty with L shape implant done by other plastic surgeon, admitted to author's clinical practice. She complained the angle of her nose tip was too sharp and bended to the right side (Fig. 1). She has history of silicon injection in the nose. She expected her nasal tip could be corrected to 'natural' shape.

Concerning the aspect of nasal tip shape, condition of collumela, and to prevent bending of cartilage graft, open rhinoplasty was performed using transcolumellar incision. Author use a tip shaping with a lateral-crual spanning and dome spanning suture. Surgical correction used straight silicon implant for the dorsum and ear cartilage graft inserted in the nasal tip (Figure 2).

Three month post operative result was satisfactory, with nasal tip curving into natural

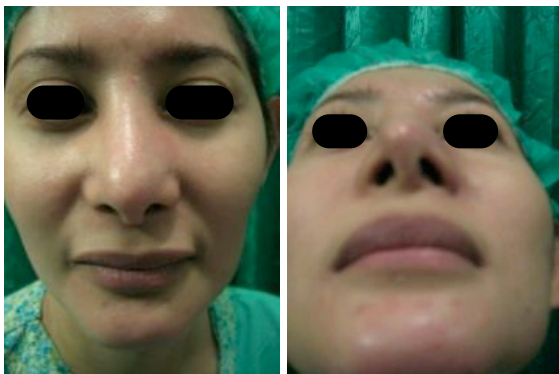

Figure 1. Pre-operative profile of a 32 years old augmentation rhinoplasty patient with L-shape implant.

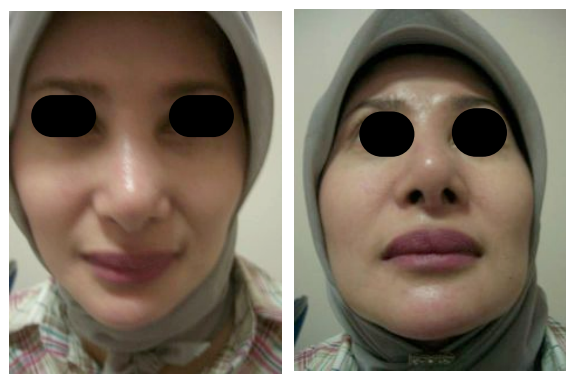

Figure 3. Post-operative result of correctional rhinoplasty with straight silicon implant placed in dorsum and ear cartilage graft implanted in nasal tip.

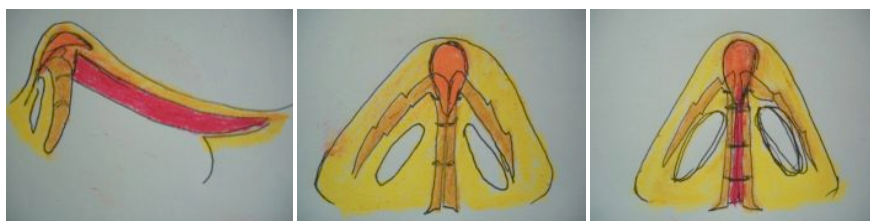


Figure 2. Illustration of trimming nasal implant and insertion of tip ear cartilage graft in secondary open rhinoplasty procedures.



shape, no evidence of swelling collumela and no occurrence of ear cartilage bending and patient satisfied (Figure 3).

of diced cartilage should be considered. Patient planned to have another surgical correction in the further time.

Case 2

A-35-years old female with history of augmentation rhinoplasty with ear cartilage graft implant in the nasal tip and alar base excision performed by author. Upon examination performed after 3 months operation, the nasal tip showed a good projection., however the 7-months followup examination, patient complained the loss projection of the nasal tip gradually appeared (Figure 4).

Author planned surgical correction by re-insertion another ear cartilage graft overlying previous graft and consideration to performed suture several stitches, if needed, to prevent another collapse of the graft and maintaining cartilage in new position. Other choice of surgical corrections in this case, such as insertion in the fascia over the graft or injection

Case 3

A case reported is 31-years old female patient presented a wide, little humpy and unnatural nose. She felt unsatisfied regarding the results of the three times rhinoplasty procedures performed by other plastic surgeon and expected a slender nose-shape.

Upon examination, a slight hump on projecting tip showed in lateral view and the nose appeared unnatural with silicon implant (Figure 5)

Surgical procedures through lateral osteotomy performed low on the prefrontal process of maxilla. Second management was excision hump nose and rhinoplasty of the nasal tip continued with ear cartilage graft procedure. The nasal arch was conservatively narrowed (Figure 6).

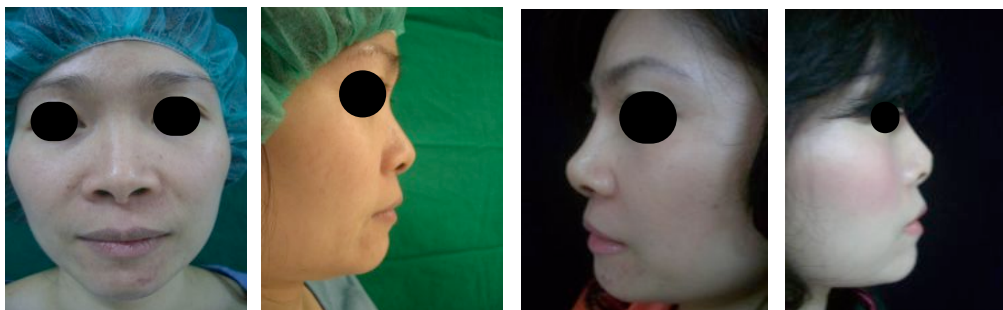


Figure 4. (a) Preoperative profile of patient before augmentation rhinoplasty,(and (b). 3-months followup examination showed good projection of the nasal tip (c) lateral view of 7-months post operative rhinoplasty, (d) loss of nasal tip projection appeared.

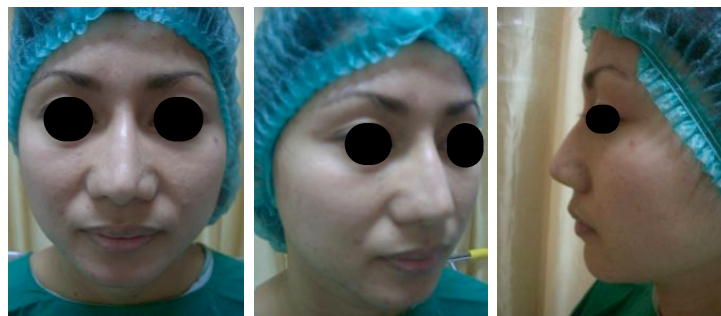

Figure 5. (Left) Pre-operative frontal view of 31-years old female patient underwent 3 times rhinoplasty procedures (center) pre-operative oblique view pre-operative (Right) lateral view

On follow up examination after 3 weeks surgery, the arch of nose appeared narrowed, no prominent hump found in lateral nasal profile and natural look of the nasal shape (Figure 7). Patient was satisfied with the result of operation.

DISCUSSION

In the first case, a 32 years old female patient complained the angle of her nose was too sharp and look unnatural after primary rhinoplasty with L-shape implant. Several factors may contribute this problem, such as non-equal dissection pocket of the nasal implant, the length of implant is longer than the pocket, the angle of L-shape implant less than 90 degree, and the root or leg of implant was too high.

Patient profile in Figure 4 illustrates changes of nasal tip projection during postoperative phase. The shrinkage or bend of the ear cartilage graft that implanted in tip may

develop loss of nasal projection. Another factors influencing nasal tip projection in post operative phase was collapse of the ear cartilage graft due to no fixation formed in the upper cartilage graft or possibility of cartilage reabsorption. No subcutaneous tissue supported below and behind the graft also consider as one of possible cause that might contribute to the loss of projection of the nasal tip..

In the third case, a 31-years old patient with chief complaint of a wide, slight humpy and unnatural appearance after 3 times rhinoplasty surgeries. Surgical approach aimed to remove hump in the nose, but also narrowing the nasal arch to formed slender nose appearance.

Lateral osteotomy as surgical approach in the case three aimed to narrow the lateral wall of the nose, to close the open-roof deformity after reduction of the dorsal hump, as

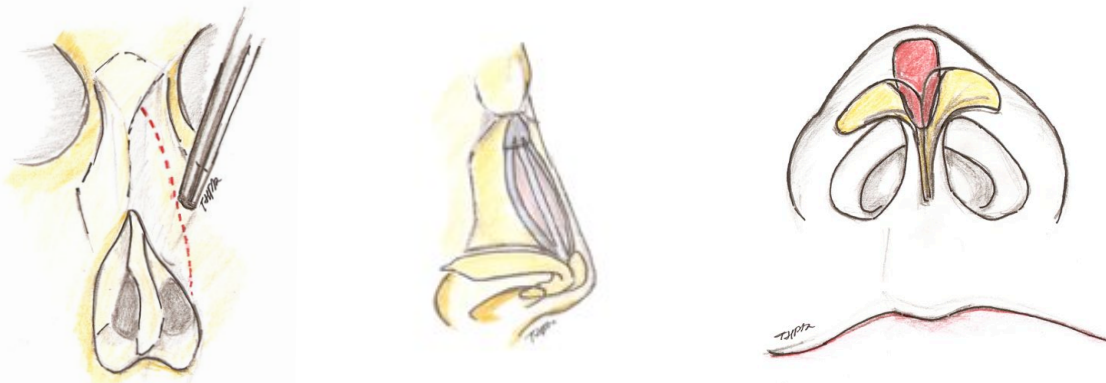

Figure 6. (Left) Operative procedure of lateral osteotomy. (Middle) Excision of hump nose (Right) Ear cartilage implanted in the tip of nasal

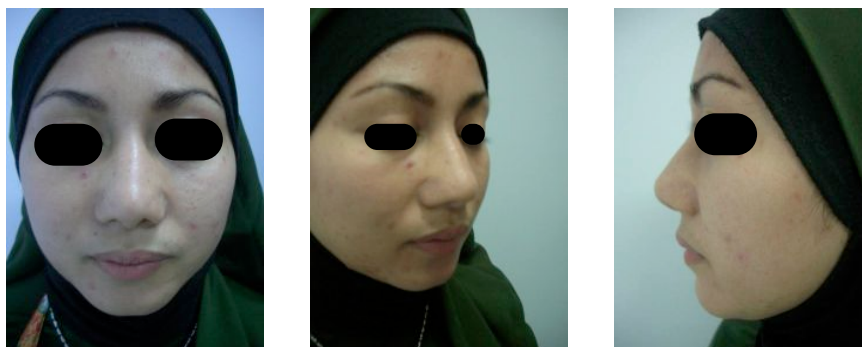


Figure 7. (Left) Postoperative frontal view after 3 weeks followup examination (Middle) Oblique and lateral post-operative view showed reduction of the hump nose and (Right) 'slender' nose appearance

well as to create symmetry by straightening between the bony frame.

In the perspectives of author, psychological condition of this patient also contribute the satisfactory concept of her surgery. History of several rhinoplasty procedures done previously revealed patient's expectation and the outcome of surgery has not meet her 'ideal' of aesthetic self-image concept. According to Cash et al² body image develop from several complex factors including culture, interpersonal relationship, physical changes, and personality aspect. A body image dissatisfactory may lead to serious disturbance for patient's daily life. A research of Crerand et al³, pointed an extreme condition of body disturbance, Body Dismorphic Disorder (BDD), found in 3-15% in group of patients presenting for aesthetic treatments. It is necessary to recognize 'caution alarm' of body image disturbance in this patients, therefore proper education and counseling regarding this problem must be planned in the future.

SUMMARY

Multiple aspects influencing pitfalls cases in aesthetic surgery. Preoperative

consultation should be a media between what is the expected end results and patient's expectation. Careful asses and identify the anatomy and anomaly of each pertaining case, mastering the surgical techniques used and consideration to implement new techniques are the key of pitfalls managements. And the most importance of preventing pitfalls case in aesthetic surgery is how to tactfully refuse to operate patients who are not good candidates.

Imam Susanto, MD

Plastic Surgery Division

Cipto Mangunkusumo Hospital, Jakarta, Indonesia

santo0350@yahoo.com

REFERENCES

1. Tebbetts JB. Primary Rhinoplasty: Redefining the Logic and Techniques. 2nd ed. Philadelphia: Elsevier; 2008. Chapter 9, Osteotomies; p.230-1.
2. Cash TF, Hortone CE. Aesthetic Surgery: Effects of Rhinoplasty on Social Perception of Patients by Others. *Plast Reconst Surg.* 1983;72(4):543-8.
3. Crerand CE, Franklin ME, Sarwer DB. Patient Safety: Body Dismorphic Disorder and Cosmetic Surgery. *Plast Reconst Surg.* 2008;122(4S):1-15