

Frontoethmoidal Encephalomeningocele Revisited : The Convenience Of Teamwork Approach, A Case- Series

Nadia Kusumastuti, Siti Handayani, Mendy Hatibie, Enrina Diah, Kristaninta Bangun
Jakarta, Indonesia.

Background: Frontoethmoidal encephalomeningocele (FEEM) is a congenital defect of the skull which poses many problems to the patient as it results in many craniofacial and neural morbidities. While recently surgical correction of this disease is done in a single-stage procedure, many in Indonesia still perform two-stage surgery which bears more risks and is technically difficult to achieve good aesthetic results. This case series intend to assess the feasibility and convenience of teamwork approach between plastic surgeon and neurosurgeon in correcting FEEM in a single-stage operation.

Methods: We reviewed 8 patients with FEEM treated in Plastic and Reconstructive Surgery Division, Cipto Mangunkusumo Hospital Jakarta from November 2005 until March 2010. Four of the cases were secondary cases from Neurosurgery Department, and the other 4 cases were treated in single-stage operation, in teamwork with Neurosurgery Department, using the Chula technique. Results of each surgery was assessed using objective parameters, which are Intercanthal Distance (ICD) and Interorbital Distance (IOD); and also subjective parameters which is aesthetic improvement.

Result: All of the patients showed significant improvements in ICD and IOD measurements. No complication was found intra and post-operatively. All patients, especially the ones treated with single-stage surgery show good aesthetic results.

Conclusion: To achieve goals of defect correction and aesthetically pleasant appearance, single-stage surgery in teamwork with the neurosurgery department seems to be most suitable and convenient.

Keywords: *Frontoethmoidal encephalomeningocele, frontoethmoidal meningoencephalocele, surgical correction, intracranial-extracranial approach, Chula technique*

Latar Belakang: Frontoethmoidal encephalomeningocele (FEEM) adalah suatu defek kongenital dari tulang kalvaria yang menyebabkan masalah kraniofasial dan sistem saraf. Teknik operasi yang digunakan saat ini adalah operasi satu tahap, namun di Indonesia masih banyak digunakan teknik operasi 2 tahap yang memiliki risiko lebih besar dan lebih sulit mencapai hasil yang baik secara estetik. Serial kasus ini bertujuan untuk menilai keuntungan dan kemudahan kerjasama antara bedah plastik dan bedah saraf dalam koreksi FEEM satu tahap.

Metode: Tulisan ini mengevaluasi 8 pasien dengan FEEM yang menjalani terapi di divisi bedah plastik dan rekonstruksi, Rumah Sakit Cipto Mangunkusumo, Jakarta dari November 2005 hingga Maret 2010. Empat kasus merupakan rujukan dari Departemen bedah saraf dan 4 kasus lainnya menjalani pengobatan satu tahap bekerjasama dengan bagian bedah saraf, menggunakan teknik Chula. Hasil dari setiap operasi dinilai menggunakan parameter obyektif, yaitu Intercanthal Distance (ICD) dan Interorbital Distance (IOD) serta parameter subyektif perbaikan secara estetik.

Hasil: Semua pasien menunjukkan peningkatan ukuran ICD dan IOD. Tidak didapatkan komplikasi intra dan pascaoperasi. semua pasien juga menunjukkan perbaikan secara estetik.

Kesimpulan: Operasi satu tahap merupakan pilihan yang tepat dan menguntungkan untuk mencapai koreksi defek dan mendapatkan penampilan yang diterima secara estetik.

Kata Kunci: *frontoethmoidal encephalomeningocele, frontoethmoidal meningoencephalocele, surgical correction, intracranial-extracranial approach, Chula technique*

Frontoethmoidal encephalomeningocele (FEEM) is defined as a neural tube defect with herniation of brain and meninges through a congenital bone defect of the skull base at the junction of the frontal and ethmoidal

bones. It is a congenital malformation that is very rare in the Western countries (estimated frequency, one in 40.000 live births) but relatively frequent in Southeast Asia region (one in 3.500 live births).¹ Suwanwela and

From Division of Plastic Reconstructive, and Aesthetic Surgery University of Indonesia Cipto Mangunkusumo Hospital, Jakarta, Indonesia.

Presented in the 14th IAPS Scientific Meeting, Balikpapan, Kalimantan, Indonesia

Disclosure: *The authors have no financial interest to declare in relation to the content of this article.*

Suwanwela classified FEEM into three basic types: nasofrontal, nasoethmoidal, nasoorbital and combined types; a classification which is still widely used by now.²

Morbidities which can be caused by FEEM include craniofacial disfigurement, impairment of nasal function, binocular vision and risk of infection of the central nervous system. Besides significant craniofacial deformity, increasing size of a meningocele may cause bilateral blindness. Infancy is the best time for definitive correction to prevent further growth disturbances and serious complications.³

Frontoethmoidal encephaloceles is usually associated with a long face and a long nose. The medial orbits walls in frontoethmoidal encephalocele may have displaced, but the orbits are not as widely separated as in other forms of hypertelorism. The orbital configuration may be abnormal because of the encephaloceles which is frequently asymmetric, so that affects one orbit more than other.^{4,5}

The goals of correction are: (1) Urgent closure of open skin and intracranial bone defects to prevent infection and desiccation of viable brain tissue. This includes the early removal of nonviable tissue, and early prevention of rupture of a thin meningoencephalocele sac, (2) Removal or invagination of nonfunctional extracranial cerebral tissue with water-tight closure of the dura, and (3) Total craniofacial reconstruction with particular emphasis on exact skeletal reconstruction, especially avoiding the "long-nose deformity".⁶

METHODS

We review our experience in treating FEEM at Plastic and Reconstructive Surgery Division, Cipto Mangunkusumo Hospital, Jakarta and discuss our evolution toward a definitive, single-stage correction. We collected 8 cases of FEEM from November 2005 until March 2010. Four of the cases had undergone mass reduction by Neurosurgical Department and referred to us for correction of craniofacial

and soft tissue defect. Two of those four cases above still presented with residual mass and significant hypertelorism. We performed single-stage correction for the remaining 4 cases with nasal-coronal approach, as a teamwork between Neurosurgery and Plastic Surgery. Some of the cases were done by the Chula technique, which incorporates limited T-shape frontal craniotomy instead of formal frontal craniotomy.

The operative steps⁷, are: Cranial Approach, Nasal Approach, Closure of the internal bone defects, Nasal Augmentation, Medical Canthopexy, Nasal soft tissue.

Cranial approach was performed with bicoronal incision. In case 1 the hypertelorism was corrected by the Chula technique. Osteotomy and reconstruction of the medial portion of the superior orbital rim, upper medial walls and nasal bones was performed. The osteotomy must include the medial orbital wall to adjust the medial orbital distance. With interosseous wiring, a new superomedial orbital wall was reconstructed to an expected interorbital distance. Because there was hypertelorism, a central portion of the T-shape bone is removed and then the medial orbital walls are moved medially to recreate a new appropriate medial IOD.

In two other cases, cranial approach was performed to exposure the internal skull defect and to reposition the medial canthal ligaments.

Nasal approach begin with reversed-Y shape or a lazy-S shape incision. The design follows natural contour lines and relaxed skin tension lines. This approach is able to remove herniated mass and redundant skin over the mass.

Before the bone defect is closed, the dura must be secured. In case 2, the reconstructed T-shaped segment was placed directly over the reconstructed dura and fixed by interosseous wiring.

For the nasal augmentation in case 3 we used a costochondral graft for augmentation of the flat nose.

Medial canthopexy is an important step that affects final aesthetic outcome. The medial canthal ligaments are always displaced either vertically or horizontally. In two cases we used

plate and screw with 2-0 polypropylene to perform medial canthopexy.

For the nasal soft tissue the skin that covers the mass usually shows signs of degenerations, e.g., hyperpigmentation, hyperkeratosis, and scarring. The degenerated skin should be removed as completely as possible with attention to the skin closure.

We evaluate the result of the surgical correction by measuring 2 parameters : interorbital distance (IOD) and intercanthal distance (ICD). Interorbital distance is defined as the distance between the orbits measured at their medial margins. Intercanthal distance is defined as the distance between left and right medial canthuses. Both parameters reflect the degree of telecanthus in our patients. IOD was assessed intraoperatively, as a relatively more objective measurement than ICD, which was assessed postoperatively and reflects soft tissue landmark. Besides parameters above, we also evaluate the convenience of the procedure done with the teamwork approach, by assessing post-operative complications and aesthetic improvements.

RESULT

Results of the patients' demographic, classification of lesion, and their measurements including bone defect, interorbital distance and intercanthal distance; are summarized into Table 1.

Below are brief descriptions of two of our patients. The first patient is secondary case, while the second patient is "fresh" or primary case.

Case 1

A girl, 14 years old with nasofrontal type encephalochele after chele extirpation 13 years before admission. The ICD was 47 mm, and the IOD was 28mm. Bicoronal approach was performed and intra-operatively we found malposition of the medial canthal ligaments and massive ossification of frontal bones. We performed forehead and nasal bone contouring. The IOD increased into 21 mm. Medial canthopexy with anchoring at 4 holes plate was performed to correct malposition of canthus,

the ICD became 29 mm. Some encephalocele mass at the dorsum nasi was excised and graft from temporal fascia was taken to correct the nasal dorsum defect (Figure 2).

Case 2

A girl, 22 months old with frontoethmoid type encephalocele, with large herniation that covered almost her entire face. The ICD was 38 mm and the IOD was 30 mm. We performed surgery with nasal-coronal approach by the Chula technique, in teamwork approach with neurosurgery department. A Y-shaped nasal incision was performed. Mass was excised and duraplasty was performed by neurosurgeon. T-shaped osteotomy was performed, medial portion of the bone was resected and used to cover external bone defect. The IOD became 22 mm. We performed medial canthopexy, the ICD became 30 mm. No complications were found during post operative care (Figure 3). After the surgery, CT scan was performed showing good results of craniofacial bone contour and closed bony defect (Figure 4).

DISCUSSION

Removal of frontoethmoidal encephalomeningocele can be achieved with several surgical techniques. The classic approach of Tessier involves a large trepanation of the skull and also detachment, realignment, and re-fixation of the osseous orbits. As the complete rim of the orbit is mobilized to correct hypertelorism, this procedure presumes craniofacial and neurosurgical expertise. It can be associated with significant blood loss, and prolonged postoperative care is eventually needed in the intensive care unit.⁸

In treating FEEM cases with medium to large sized defect, some centers in Indonesia still perform two-staged surgery, the first stage performed by neurosurgeon which aims at correcting neural defect by doing formal craniotomy; then the second stage which aims at correcting craniofacial soft tissue deformities including canthus and nose. With this approach there are some limitations including the difficulty to achieve good aesthetic outcome, because usually the skin overlying the mass has shown degenerative changes, for example

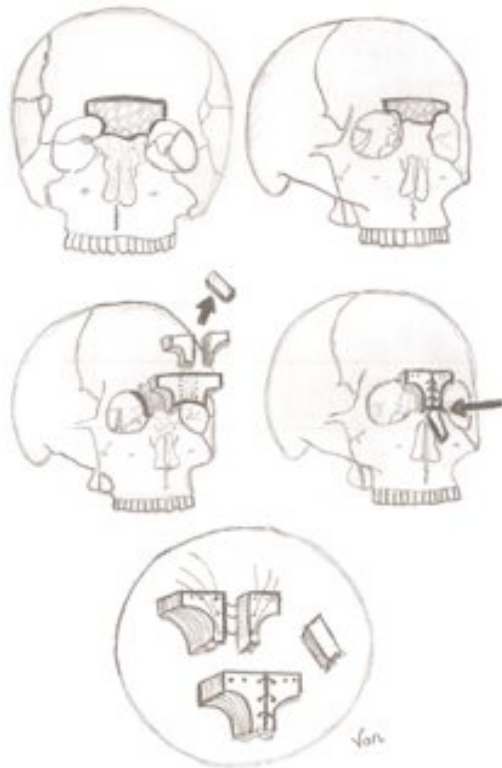


Figure 1. Lateral palatal defects resulted from two-stage palatoplasty

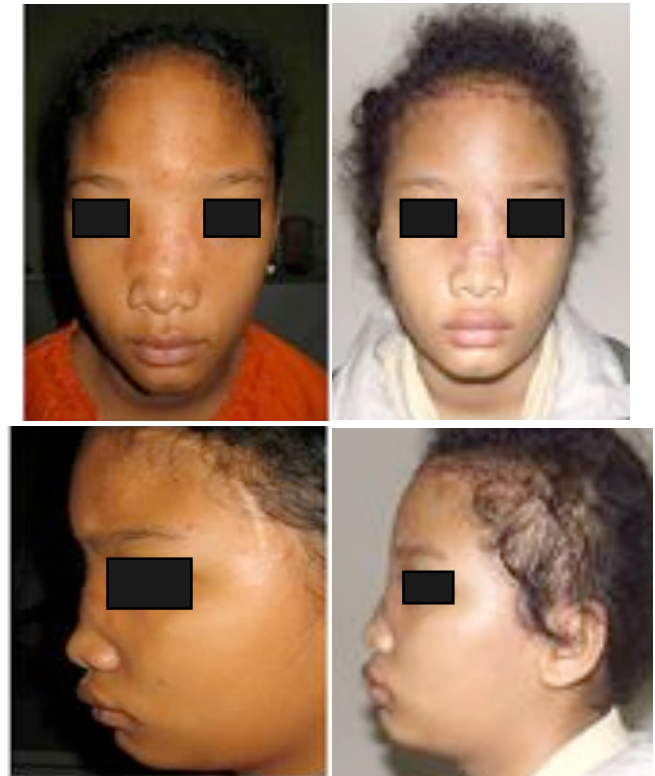

Figure 2. A 14-year old girl with secondary nasofrontal type FEEM. (Above, left) Preoperative frontal view demonstrating masses in dorsum nasi with irregular skin covering. (Above, right) Postoperative frontal view after mass excision, craniofacial reconstruction and nasal dorsum graft. (Below, left) Preoperative lateral view.

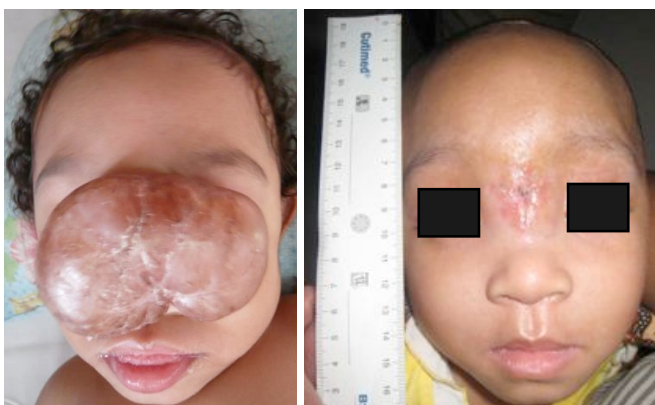

Figure 3. A 22-month old girl with frontoethmoid type FEEM. (Left) Preoperative frontal view demonstrating a large mass in the central of the face with low quality of overlying skin. (Right) Postoperative frontal view after single-stage reconstruction.

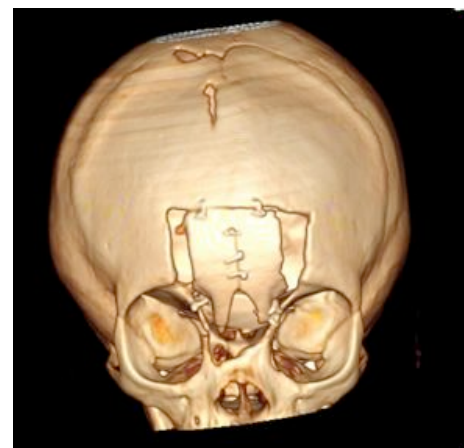

Figure 4. Post-operative CT-scan image of the patient. The medial third portion of the T-shaped osteotomy was used to cover bone defect in the superomedial parts of the orbits. In this image, that bone is seen underneath the lateral fragments joined

Table 1. Summary of patients' results

No	Age/Sex	Mass Location	Bone Defect	IOD		ICD	
				Pre	Post	Pre	Post
1	8 mo/F	Frontoethmoid	15 mm	33 mm	22 mm	44 mm	30 mm
2	14 yr/F	Nasofrontal	---	28 mm	21 mm	47 mm	29 mm
3	7 yr/F	Frontoethmoid	9 mm	27 mm	27 mm	35 mm	32 mm
4	10 yr/F	Nasofrontal	---	31 mm	31 mm	40 mm	33 mm
5	5 yr/F	Nasofrontal	4 mm	31 mm	31 mm	36 mm	32 mm
6	26 yr/M	Nasoorbital	1,5 mm 7 mm	26 mm	21 mm	56 mm	41 mm
7	7 mo/F	Frontoethmoid	5 mm	26 mm	16 mm	30 mm	14 mm
8	22 mo/F	Frontoethmoid	10 mm	30 mm	22 mm	38 mm	30 mm

hyperpigmentation, hyperkeratosis and significant scar from previous surgery.

Recently most cases of FEEM are corrected with nasal-coronal approach because it provides wide exposure and can be done in a single-stage. The Chula technique is one of the most feasible among all techniques, because there is no need to perform formal and extensive craniotomy, only limited frontal osteotomy. Four cases from this series have undergone mass reduction by the Neurosurgery Department. Nevertheless, from the four cases, two patients still presented with neural defects so we performed duraplasty with nasal-coronal approach. This approach provides adequate exposure to perform medial canthopexy; which is important because the medial canthal ligaments are almost always displaced in FEEM; whether to the superior, inferior, anterior or posterior from the mass.⁹

Another novel technique in treating FEEM is pure extracranial approach. This technique promised feasibility in countries with limited resources that is difficult to perform craniotomy or any neurosurgical procedure. Yet this technique proves to have some difficulties and risks. Technical difficulties were caused primarily by the restricted exposure of the neck of the hernia sac, which was limited by the size of the external bony defect. This made dural closure much more difficult than when using a frontal osteotomy to directly expose the herniation sac and the surrounding brain.¹⁰ When dealing with small meningoceles, the exposure through the external bony defect was

sufficient. With larger encephaloceles as in our cases, where the sac had to be surgically excised, water-tight closure of the dura became increasingly difficult. In these patients, the dura was abnormally thin and fragile, making it sometimes impossible to avoid tearing. Closure of the internal bony defect at the frontal base was obviously not possible when using a pure external approach.¹⁰

Looking at the early complication rate, extracranial approach is associated with a higher incidence of cerebrospinal fluid leakage than intracranial techniques. This was due to the fact that tearing of the dura was almost unavoidable with an extracranial approach in medium or large meningoceles. Furthermore, dural repair was not as sufficient as if an intracranial duraplasty had been performed.¹⁰

A second limitation of a pure external approach was the donor-site morbidity associated with closure of the external defect and/or nasal reconstruction. In one series by Kline et al,¹¹ unicortical calvarial bone grafts had to be used to close external defect, and these were always taken from the parietal skull overlying the nondominant hemisphere. Even though harvesting an outer table graft is a routine procedure for a craniofacial surgeon, it has been previously described that harvesting of unicortical calvarial bone grafts by nonneurosurgeons can be associated with brain injury and dural lacerations, especially in cases of thin calvaria.¹¹ Therefore, an obvious advantage of the Chula technique is the design of the osteotomy, which closes the external

defect and provides a bone graft for nasal reconstruction, thus avoiding donor-site morbidity in the majority of cases. Furthermore, performing the surgical procedure with neurosurgeons in a single stage would definitely be an advantage, since an adequate dural closure can be expected.

In this case series, we found no sign of increase in intracranial pressure or any sequel postoperatively. The IOD and ICD of the patients are acceptable, and the scar was esthetically pleasant, especially in patients who underwent single-stage teamwork approach. Nevertheless, this study is still a preliminary study, thus needing a long term evaluation of patients with FEEM after reconstruction.

SUMMARY

FEEM can be treated in various surgical techniques, however, to achieve goals of defect correction and aesthetically pleasant appearance, single-stage surgery in teamwork with the neurosurgery department is the most suitable and convenient technique. Preferred by our institution is the intracranial-extracranial approach with limited craniotomy, which is the Chula technique. It can be applied to most FEEM with various sizes and location, is convenient and has low risk of complications, as shown by this case series.

Kristaninta Bangun, M.D.

*Cleft Craniofacial Center. Plastic Surgery Division
Cipto Mangunkusumo General National Hospital
kristaninta@yahoo.com*

REFERENCES

1. Suwanwela, C., Sukabote, C., and Suwanwela, N. Frontoethmoidal encephalomeningocele. *Surgery* 69: 617, 1971
2. Suwanwela C, Suwanwela N. A morphological classification of sincipital encephalomeningoceles. *J Neurosurg* 1972;36: 201-211
3. David, D. J. Cephaloceles: Classification, pathology, and management. A review. *J. Craniofac. Surg.* 4: 192, 1993
4. Salyer KE, Aesthetic craniofacial surgery. 1989. New York : 48-65,83-8
5. Jackson IT, Tanner NSB, Hide TAH. Frontonasal encephalocele "long nose hypertelorism". *Ann Plast Surg* 1983; 11(60):490-500.
6. Holmes AD, Meara JG, Kolker AR, Rosenfeld JV, Klug GL. Frontoethmoidal Encephaloceles: reconstruction and refinements. *J Craniofac Surg* 2001; 12: 6-18.
7. Mahatumarat, C., Rojvachiranonda, N., and Taecholarn, C. Frontoethmoidal Encephalomeningocele: Surgical correction by the Chula technique. *Plast. Reconstr. Surg.* 111: 556, 2003
8. Tessier, P. Orbital hypertelorism I: Successive surgical attempts. Material and methods. Causes and mechanisms. *Scand. J. Plast. Reconstr. Surg.* 6: 135, 1972
9. Ur Rahman N. Nasal Encephalocele. *Journal of the Neurological Science*; 42: 73-85. Brown MS, Sheridan M. Outlook for the child with a cephalocele. *Pediatrics*; 90: 914-919
10. Holm C, Myatt T, Anderl H, Mayr M, Gogeler-Schroder S, Schoneich W. Extracranial Correction of Frontoethmoidal Meningoencephaloceles: Feasibility and Outcome in 52 Consecutive Cases. *Plast. Reconstr. Surg.* 121: 386e, 2008.
11. Kline, R., and Wolfe, A. Complications associated with the harvesting of cranial bone grafts. *Plast. Reconstr. Surg.* 95: 5, 1995.