

Management and Treatment of Gynecomastia with Liposuction

Tessa Puspita Sari, Gentur Sudjarmiko
Jakarta, Indonesia.

Background: Gynecomastia is a common problem of the male breast, with a reported overall incidence of 32 to 36 percent. The surgical management of gynecomastia has undergone significant changes over the past few decades, from a predominantly open approach to one involving liposuction only or liposuction combined with direct excision through a periareolar or remote incision.

Patients and Method: We present five cases with bilateral gynecomastia. One patient is a teenager and others are adult males. Liposuction only was performed in patients without palpable glandular breast mass. Direct excision was made to help remove the excessive glandular breast mass. The compressive garment is worn for 4 to 6 weeks after procedure to prevent the complications of the surgical procedure.

Result: Three of the patients are corrected with liposuction only. There are two patients who underwent combination of open excision and liposuction. The liposuction procedure only left minimal scar from canulas incision. Other patient has minimal periareolar incision to remove excess breast tissue. None of the patients showed complication after surgery.

Summary: All of the patients presented were satisfied by the correction of gynecomastia using liposuction. None of the patients shows any complication after liposuction procedure. The result after surgery is a natural-looking chest without extensive scar. The patients appreciate the early return to work and normal physical activities.

Keywords: gynecomastia, reduction technique, liposuction

Latar belakang: Ginekomastia merupakan salah satu permasalahan tersering pada laki-laki dengan insidens keseluruhan sekitar 32 sampai 36 persen. Penatalaksanaan pembedahan pada kasus ginekomastia sedang mengalami perubahan dalam beberapa dekade terakhir dari pendekatan eksisi terbuka menjadi teknik dengan invasi minimal melalui sedot lemak saja atau dikombinasikan dengan insisi periareolar.

Pasien dan Metode: Terdapat lima kasus dengan ginekomastia bilateral, terdiri dari satu pasien remaja dan empat laki-laki dewasa. Sedot lemak dilakukan hanya pada pasien tanpa perabaan kelenjar payudara. Kombinasi sedot lemak dan insisi dilakukan untuk membantu mengurangi massa kelenjar payudara yang berlebih. Kompresi dada dengan garmen dilakukan pasca pembedahan untuk mencegah terjadinya komplikasi.

Hasil: Terdapat tiga kasus yang dikoreksi hanya dengan teknik sedot lemak. Dua kasus lainnya perlu menjalani kombinasi sedot lemak dan eksisi massa. Teknik sedot lemak meninggalkan luka minimal yang berasal dari insisi tempat masuknya canula. Pasien yang menjalani eksisi massa mendapatkan luka minimal di daerah periareolar. Tidak ada satupun dari pasien mengalami komplikasi setelah pembedahan.

Ringkasan: Keseluruhan pasien merasa puas dengan teknik sedot lemak dalam mengatasi permasalahan ginekomastia. Tidak terdapat seorang pun dari pasien tersebut yang mengalami komplikasi pasca operasi. Hasil dari pembedahan adalah kontur dada alami tanpa terlihatnya bekas luka yang nyata. Para pasien mengaku puas dapat segera kembali melakukan aktivitas seperti biasa.

Kata kunci : gynecomastia, reduction technique, liposuction

Gynecomastia is a common occurrence on male particularly during early sexual development with an overall incidence of 32 to 36 percent.^{1,2,3} This persistent enlargement of the male breast can be related to

a variety of endocrinopathies, mostly as the result of an imbalance between estrogens, which stimulate breast tissue, and androgens, which counteract these effects.³ A careful history and physical examination is the most

From The Division Of Plastic Reconstructive and Aesthetic Surgery, University of Indonesia, Cipto Mangunkusumo Hospital, Jakarta, Indonesia Presented in 16th IAPS Scientific Meetings In Sibolangit, North Sumatra, Indonesia.

Disclosure: The authors have no financial interest to declare in relation to the content of this article.

important part of any work-up for gynecomastia. The history must note the time of onset of the gynecomastia, drug use (both medically prescribe and recreational) and careful review of systems.⁴

There are many classification of gynecomastia. The classification described by Simon et al is commonly used and is based on the size of the breast and the amount of redundant skin. Simon et al divided gynecomastia into four grades. Grade 1 is gynecomastia with small enlargement without skin excess. Grade 2a have moderate enlargement but without skin excess, while grade 2b with extra skin. Grade 3 is a marked breast enlargement with extra skin. In their opinion, grades 2b and 3 require some skin resection.^{1,3}

The surgical management of gynecomastia has undergone significant changes over the past few decades, from a predominantly open approach to a minimally invasive technique using liposuction only or liposuction combined with direct excision through a periareolar or remote incision.² The first surgical procedures used to treat gynecomastia were excisional in nature. Suction assisted lipectomy was first reported in the early 1980s and more recently ultrasound-assisted liposuction has been used for certain types of gynecomastia.^{1,5}

Several approaches to the surgical treatment of gynecomastia have been describe in the literature. Extra-areaolar incision produce unsightly scars, but semicircular intra-areolar incision has become the standard incision used in operations for excision of gynecomastia and remains the most commonly used intra-areolar method.⁶

PATIENT AND METHODS

We present five patients with bilateral gynecomastia. Four of them are adult males and only one of the patients is adolescent male. Three of five patients underwent liposuction only and two of them underwent

liposuctions combine with direct excision through a periareolar or remote incision. Case 1 and 2 are treated with liposuction with direct excision of the glandular mass, while case 3 until 5 are treated only by liposuction.

Case 1

A 33-year-old male suffer from gynecomastia since 1 year ago. The patient has history of taking recreational medicine to enlarge muscle mass in recent year. He previously went to alternative medicine and underwent multiple incisions in both breasts as a therapy. At admission in the outpatient clinic, physical examination shows bilateral enlargement of the breast. A mass is palpable in right upper quadrant of the right breast but elsewhere is diffuse. There are scars of incisions from previous alternative medicine therapy. Other physical examinations are unremarkable. Laboratory data were apparently normal.

Before operation, the patient is marked in upright position. All areas of tissue excess are are marked. The mass palpable prior visit was marked with a different shadow. Operation was performed under general anesthesia. The patient was position in the supine position. Small incisions were made in the subxyphoid and submammary fold on anterior axillary line to insert the canulas of liposuction. Liposuction is performed in all directions through both incisions from the clavicle to below the inframammary fold. After the flat, smooth contour is reached, the residual glandular mass is palpable. An incision is made on previous alternative medicine scar to reach glandular mass. The mass was dissected circumferentially and a mass sized 9 x 8 cm was carried out toward the incision. There is no closed suction drainage inserted in this procedure. The postoperative course was uneventful.

On the next visit in outpatient clinic on day 10 after operation, the patient still using compressive vest. There is no hematoma or

seroma observed. The patient will wear this compressive garment for 4 to 6 weeks. From the interview, the patient declares his satisfaction of the result after surgery. The view of the patients could be seen on Figure 1.

Case 2

A 35-year-old male complains for bilateral breast enlargement since 6 months ago. The patient has history of consuming recreational drugs to enlarge his muscle over the year. From the physical examination, glandular masses were palpable on the left upper quadrant of the right breast and on the

right upper quadrant of the left breast. Other physical examinations and laboratory result are normal. The area of breast enlargement and locations of glandular masses are marked in the upright position. The patient then sedated and underwent liposuction procedure. A semicircular incision at the inferior areola-cutaneous junction is performed to remove residual fibrous tissue. In postoperative visit day 9 after surgery, the patient still using elastic bandage on the breast. There is no hematoma shown. The patient feels satisfy with the postoperative result. See the patients pictures from Figure 2.

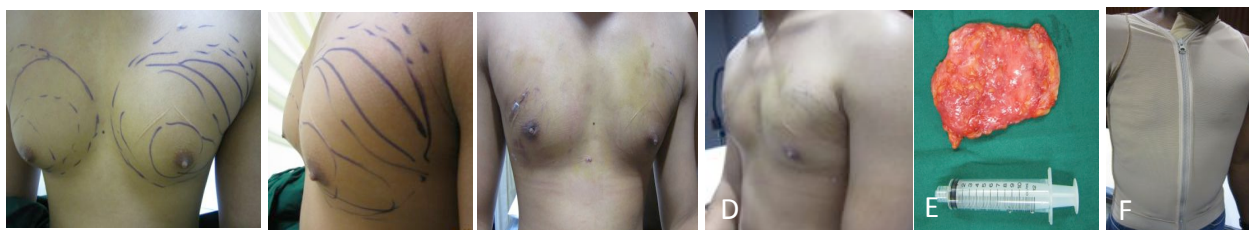

Figure 1. A dan B: A 33-year-old male with bilateral gynecomastia, previously underwent multiple incisions as therapy of alternative medicine. C and D: day 10 after surgery. E: Appearance of fibrous tissue after excision. F: Compressive vest used until 4 to 6 weeks after surgery.

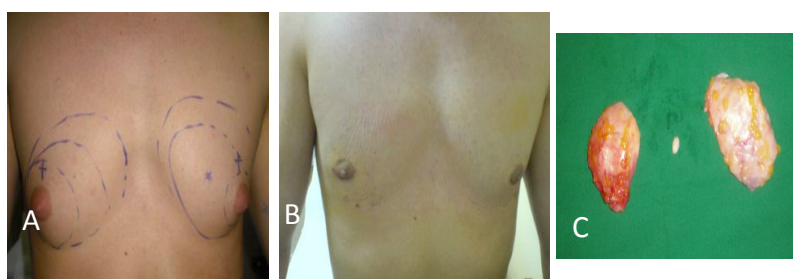


Figure.2. A: Preoperative appearance of a 35-year-old patient with bilateral gynecomastia, B: Postoperative anterior view at day 9 after liposuction and periareolar incision, C: Intraoperative view of specimen from right breast (a) and left breast (b).

Case 3

A 12-year-old boy with enlargement from both of the breast since 4 months ago came to the outpatient clinic (Figure 3). He was not confident with the appearance of his body. Physical examinations revealed an overweight adolescent boy without any feminizing characteristic. The bilateral breast showed a moderate diffuse enlargement. The laboratory result is unremarkable. Before operation, the area of breast enlargement and ptosis is marked. The patient was underwent liposuction procedure only and reached a smooth normal contour of the breast. He did not require another procedure to address skin excess. Patient visits outpatient clinic 7 days after surgery and showing no hematoma or seroma. He was using compressive garment until 4 weeks after surgery. The patient confesses feeling confident enough after liposuction procedure.

Case 4

A 30-year-old male came to outpatient clinic with enlargement of bilateral breast. No history of previous drugs consumption. From physical examination, there is a moderate enlargement of the breast. No palpable glandular mass on both breasts. Before bringing

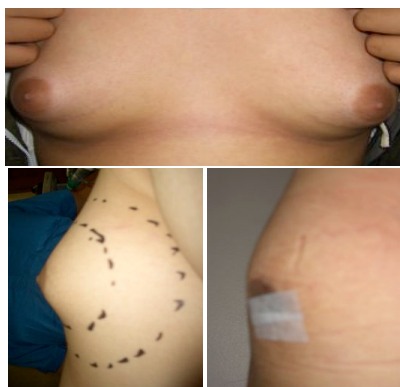

Figure 3. A. A 12-year-old with moderate enlargement gynecomastia with ptosis. B. Lateral view preoperative. C. Postoperative result showing a normal chest wall contour.

him into the operating room, the area of excess breast tissue on both breast of the patient was marked. Only liposuction procedure was performed and successfully restores the normal chest contour. Post operative visits revealed no hematomas on the chest wall.

Case 5

A 40-year-old male complains for bilateral gynecomastia since 5 months ago (Figures 4). He consumed recreational drugs to enlarge muscle mass previously. From physical examination, both of the breasts are enlarged without any palpable fibrous breast tissue. The area of the enlargement was marked prior to liposuction procedure. On day 7 after surgery, the patient showing no signs of hematomas or other complications. He continued to wear compression vest garment up to 4 weeks after surgery. He is satisfied that the liposuction has restored the normal contour of his chest.

DISCUSSION

Gynecomastia was a common problem of the male breast. It generally presents as an aesthetic complaint. The associated emotional trauma can have real consequences for adolescent boys afflicted with this condition. A

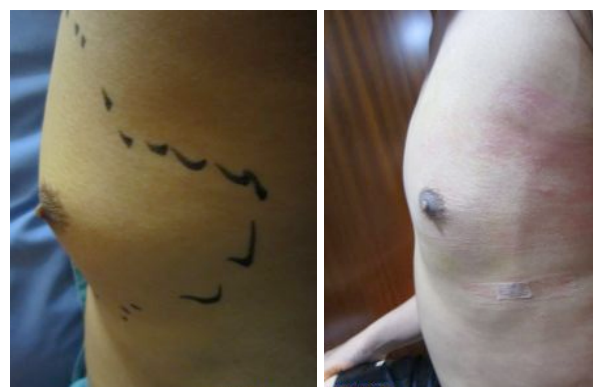

Figure 4 A. Lateral preoperative view of a 40-year-old male with bilateral gynecomastia. B. Postoperative views show restoration of a normal chest contour.

Careful history and physical examination is the most important part of any work-up for gynecomastia. The history must note the time of onset of the gynecomastia, symptoms associated with gynecomastia, drug use (both medically prescribed and recreational) and careful review of systems.^{3,4} Healthy adults with a normal physical examination (other than gynecomastia) do not need further work up.² All of the patients presented here seek for the doctor help mostly because feeling unconfident with an enlargement of their breast. None of them shows feminizing characteristic hence none underwent endocrine testing.⁴

Numerous techniques have been advocated to treat gynecomastia, but in the past two decades, there has been a shift from the open approach to minimally invasive techniques. Recent literature supports the use of liposuction alone or in combination with direct excision of the residual breast tissue using either a periareolar incision or a remote incision.^{1,2}

Three of five patients have undergone liposuction only to achieve normal contour of the chest. All these three are having fatty bilateral gynecomastia without any glandular mass palpable. One of the patients is having a moderate enlargement with slight ptosis but not require any skin resection. Liposuction was performed in all directions to maximize the suction of excess breast tissue. Incision for the canulas was made in inframammary fold or in axillary line to prevent the scar to be exposed. Two incisions were needed to help the surgeon reach all area of the excess breast tissue.

The other two patients were having glandular breast tissue in one or both breasts. Liposuction alone was not succeeded to remove all the excess breast tissue. There was still a residual of glandular breast tissue that is needed to be excised in order to have a normal chest contour. One patient using a remote incision from previous scar to excise the tissue while the other using a periareolar incision approach to minimize scar. Biopsy was not commonly performed in bilateral gynecomastia. It should be performed for unilateral

gynecomastia in the context of Klinefelter syndrome.²

After surgical procedure, the compressive garment is worn for 4 to 6 weeks. The patients are allowed to remove the garment for a few minutes each day for bathing. The goal of the compression garment is to prevent the complications of the surgical procedure such as hematomas or seroma.^{2,5} All of the patients presented showed no sign of these complications. None of the patients are inserted with suction drainage.

SUMMARY

All of the patients presented were satisfied by the correction of gynecomastia using liposuction. None of the patients shows any complications after liposuction procedure. The result after surgery is a natural-looking chest without extensive scar. The patients appreciate the early return to work and normal physical activities.

Gentur Sudjatmiko, MD

Division of Plastic Surgery

Cipto Mangunkusumo General Hospital, Jakarta.

dr_gentur@yahoo.co.id

REFERENCES

1. Petty PM, Solomon M, Buchel EW, Tran NV. Gynecomastia: Evolving Paradigm of Management and Comparison of Techniques. *PlastReconstSurgvol* 106, October 2010.
2. Hammond DC. Surgical Correction of Gynecomastia. *Plastic Reconstructive Surgery* vol 124, July 2009.
3. Braunstein GD. Gynecomastia. *New England Journal of Medicine* 357;12. September 2007.
4. Pensler JM, Silverman BL, Sanghavi J, et al. Estrogen and Progesterone Receptors in Gynecomastia. *PlastReconstSurgvol* 106. October 2000
5. Rosenberg GJ. *Surgery of the Breast: Principles and Art. Gynecomastia.*
6. Durani P, McCulley SJ. Transareolar and H-incision for the Surgical treatment of Gynecomastia. *Plastic Reconstr Surgery* vol119, April 1997