

Hypospadiac Cripple: How To Avoid

Bisono

Jakarta, Indonesia

The term hypospadiac cripple is very apt to use for hypospadiac patient who has underwent several unsuccessful reconstruction attempt. The meaning of the word cripple is incapable to function properly. If it is used for condition after failure of several attempt of reconstructions in hypospadiac repair, the meaning of severe damage should apply; a crippled penis with fistula, stricture, contracture and less healthy skin cover.

The function of the penis is for normal micturition, penetration and deposition of semen in the right place of the vagina. A crippled penis is incapable of doing those functions. To avoid that disaster, the following points should be heeded.

1. The longer urethral reconstruction is required, two stages reconstruction is safer.
2. Excision of chordate should be complete; the sheath of spongy body of the penis should be free of any fibrous strands that formed chordae.
3. Bleeding from remaining normal urethral cavernous body should be attended properly. Post-op bleeding easily develops due to erection.

4. If repair is scheduled in two stages, coverage of the raw surface developed after chordate release using preputial skin flaps is such that enough skin is provided in the proximal part for future use in urethral reconstruction. Z-plasty can be used.
5. In the second stage repair, design for inner lining of urethra should be such that there won't be superposition of sutures with outer flap covering. Superposition will make leakage easier to develop.
6. The width design for inner lining of urethra should not cause tension when suture is made to make a tube. Tension is the cause of dehiscence.
7. Aposition suturing to construct the urethra should be meticulous, everting, not inverting.
8. Silicon or siliconized catheter should be used, especially for younger patients, to minimize blockage of flow of urine. Effort to change blocked catheter is disaster.
9. Early change of dressing, massaging to evacuate any hematoma/muck formation should be done. Hematoma/muck collection is the cause of disruption and fistula.
10. One stage repair, using island flap from inner preputium for inner lining reconstruction of the urethra should be done by the experienced only and only for proximal penile hypospadiac.
11. Design of flap from inner preputium in cylindrical form of penis is difficult and likewise success for long enough urethral reconstruction in one stage.

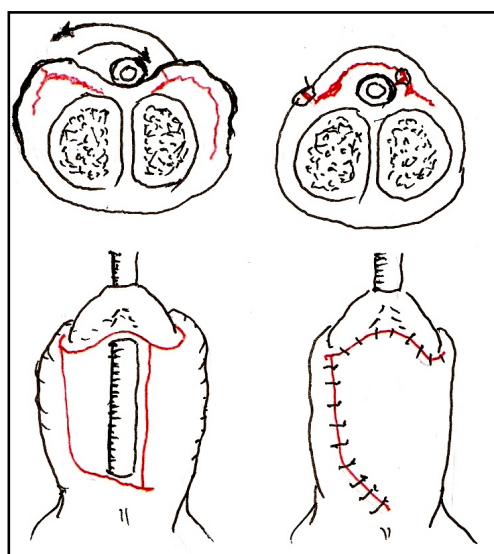


Figure 1. Design of reconstruction of urethra, avoiding super position of suture

Hypospadiac is really a plastic surgery case.

Bisono R, M.D.

Plastic Surgery Division

Cipto Mangunkusumo General National Hospital
Jalan Diponegoro.No.71, Gedung A, Lantai 4.

dr.bisono@yahoo.com