

EXTERNAL GENITALIA

Penile Reconstruction of Congenital Urogenital Malformation: Penile Duplication, Bifid Scrotum, Symphysiolysis, and Remnant Urachus

Anastasia Dessy Harsono, Budiman, Chaula Luthfia Sukasah
Jakarta, Indonesia.

Background: This report describes the penile reconstruction of a congenital urogenital malformation.

Patient and Method: A 12 year-old boy came to our hospital with 'penile duplication', bifid scrotum, symphysiolysis, and remnant urachus. The procedures were done by the urologist, pediatric surgeon, and plastic surgeon. Urethral evaluation done by the urologist determined which penis was tenable, pediatric surgeon then excised the remnant urachus, and we performed urethroplasty onto the chosen urethra. The medial side of the penis was deepithelialized and both penis were put within one skin covering.

Results: Patient was able to control micturition, and has normal erectile function. In the future, we plan to do further reconstruction of the pubic symphysiolysis at pubertal age.

Summary: Surgery was performed by a team dedicated to their specialties. There is no single standard procedure for urogenital malformation, and we must emphasize the functional and aesthetic results in reconstruction surgery. It is important to master the basic principles of plastic surgery.

Keywords: Penile duplication, congenital urogenital malformation, urachus, bifid scrotum

Pendahuluan: Laporan kasus ini adalah memberi gambaran tata laksana rekonstruksi penis pada malformasi kongenital urogenital.

Pasien dan metode: Anak laki-laki 12 tahun dengan 'duplikasi penis', bifid skrotum, simfisiolisis, dan remnan urachus. Operasi ini melibatkan urologi, bedah anak dan bedah plastik. Urologi mengevaluasi uretra penis yang dapat dipertahankan. Bedah anak melakukan eksisi remnant urachus. Untuk rekonstruksi penis, bedah plastik melakukan urethroplasty dari uretra yang dipertahankan, uretra yg lain mengalami obstruksi. Dilakukan deepitelisasi sisi medial penis lalu kedua penis dijadikan satu dan dibungkus dengan satu kulit penutup.

Hasil: Pasien dapat mengontrol miksi dan memiliki fungsi ereksi yang normal. Kami mempertimbangkan untuk melakukan rekonstruksi lanjutan untuk simfisiolisis pubis di usia pubertas.

Ringkasan: Operasi dilakukan oleh tim kerja bedah dengan keahliannya masing-masing. Belum ada prosedur standar untuk operasi malformasi urogenital. Fungsi dan penampilan harus dipertimbangkan, sehingga enting bagi dokter bedah plastik untuk menguasai prinsip-prinsip dasar bedah plastik.

This article presents a case of uncommon urogenital malformation consisting of penile duplication, epispadias (penile and penopubic types), symphysiolysis, remnant urachus, and bifid scrotum without bladder extrophy. Embriologically, this presentation is a variant of the extrophy-epispadias complex. The etiology of this complex was the failure of mesoderm ingrowth to reinforce the cloacal membrane.

PATIENT AND METHODS

A twelve years old boy came to our hospital with multiple congenital anomaly: a

mass covered by mucous over the pubic symphysis, 4 cm in diameter, reddish, soft and tenacious. Penis is deformed where the corpora cavernosa structure was spread apart and the corpus spongiosum was absent or deficient. Scrotum was present with two testicles in it (Figure 1). This patient was born at term from a mother who suffered severe pre-eclampsia.

From CT scan, a 6 cm symphysiolysis was found. One cavernous body could be identified in each penis (Fig. 2). Penopubic epispadia was found on the left penile, urethral meatus located on the pubic. No stricture at the verumontanum was found by urethroscopy.

From Department Of Surgery, Gatot Soebroto Army National Hospital.

Presented in 15th IAPS Scientific Meetings In Semarang, Central Java, Indonesia

Disclosure: The authors have no financial interest to declare in relation to the content of this article.



Prostates were well, both ureters could be identified starting from the bladder neck. On the right penis, the urethral opening lied on the corona of the glans. Urethrocystoscopy revealed normal urethra but there was fibrotic tissue on the mucosa along the canal until the bladder.

The surgery was done by a team consisting of urologist, pediatric surgeon and plastic surgeon. The urologist found 2 external urethral orifices. The pediatric surgeon performed explorative laparotomy and found a remnant urachus, which was not connection to the urinary bladder or other organs. Defect was then excised and closed primarily (Fig. 3). Based on urethroscopy findings, plastic surgeon decided to make the neourethra from the 'left

penile' and discarded the fibrotic urethrae. The right corpora cavernosa was dissected, fibrotic urethra excised until the firth and closed using tobacco sac suture, deepithelialzation followed to attain a wider raw surface which were then joined to the opposite of 'shaft penile' (Fig. 4).

In performing urethroplasty on the left penile, rectangular flap design was raised from the glands to the proximal side (Fig. 3). The flap was elevated then wrapped around the catheter (tubularized) and sutured with 6.0 interrupted unabsorbable sutures. Overhecting sutures added to achieve water-tight condition (Fig. 4). Finally, both corporal bodies was sutured medially and covered by foreskin. W plasty design joined both glands (Fig. 4). Catheter was removed 2 weeks following the surgery.

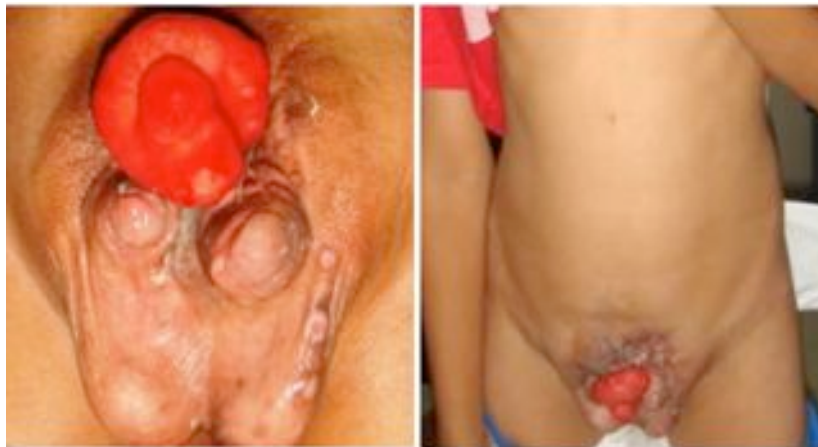

Figure 1. The picture shows the remnant *urachus*, 'penile duplication', and *scrotum bifide* (left), noted that the navel was missing (right).

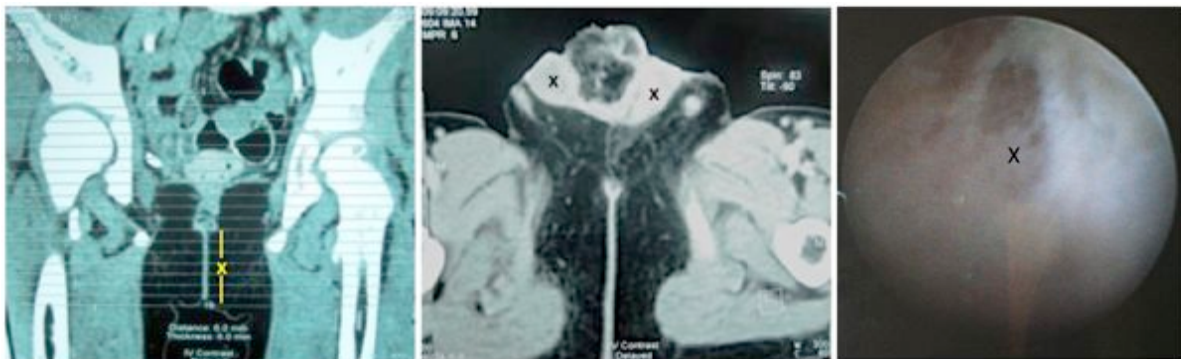


Figure 2. Radiologic examination from left to right showed 6 cm distance symphysiolysis (x), two corpora cavernosa (x), fibrotic tissue on the mucosa along the canal urethra of the right penile to the vesica (x).(right)

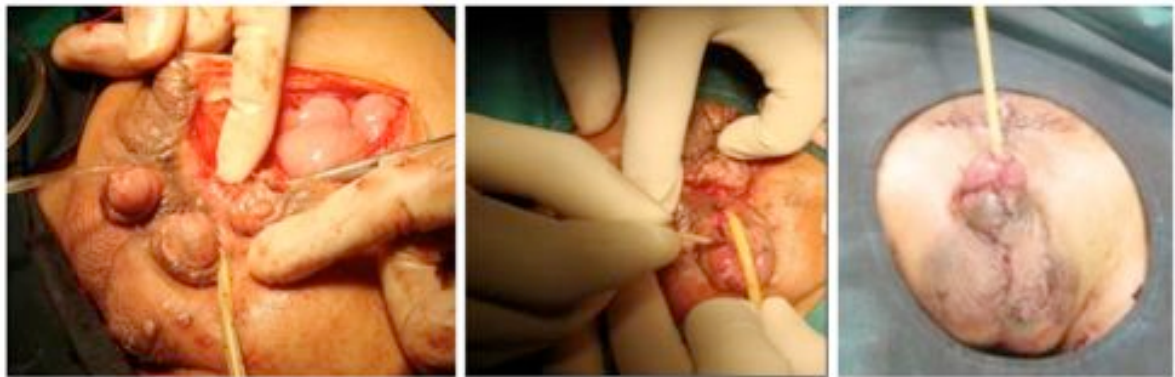


Figure 3. (From left to right) Excision of the remnant urachus, the urethroplasty design, post-operative result

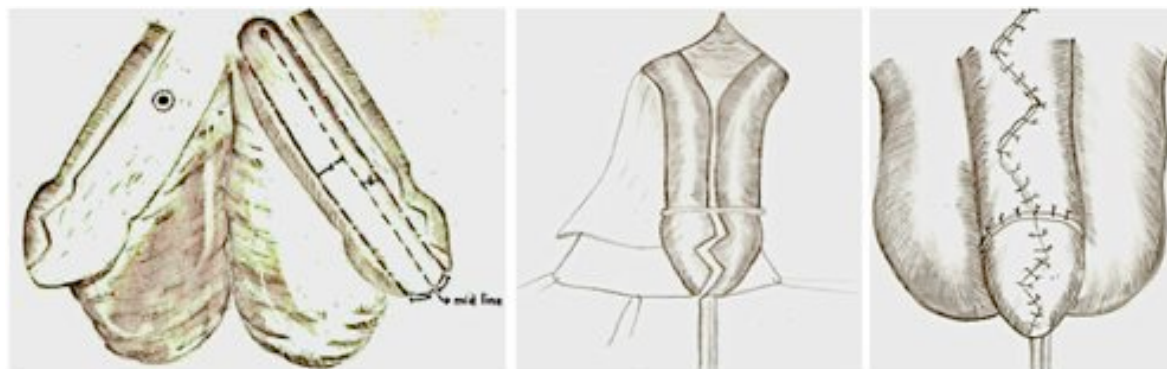

Figure 4. Illustration of intra-operative technique

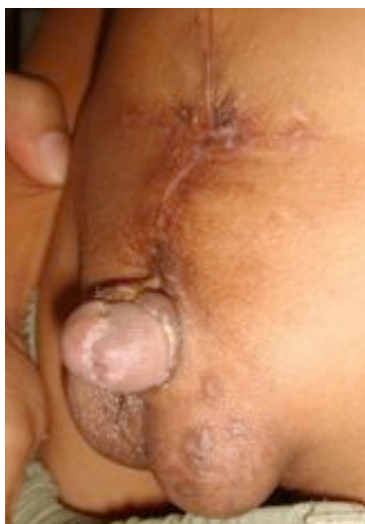

Figure 5. One month postoperative result, no fistula nor leakage present.

There was no leakage or fistula, with satisfying functional and aesthetic results.

DISCUSSION

In the Central Army Hospital Indonesia, most cases involving genitalia reconstruction are referred to the plastic surgeons, especially for complex cases such as epispadia and hypospadia cripples. In this surgical technique, plastic surgery principles were applied to incorporate both sides of gland penis. W-plasty design was used instead of the inversion suture to avoid unpleasant cosmetic appearance.

The principles of urethroplasty are (a) to choose a healthy skin to draw a good design on, (b) eversion interrupted sutures should be places into the lumen, (c) siliconized catheter kept in place for 3 weeks, or place cystostomy, (d) use a small prolonged absorbable monofilament, (e) do overhecting to attain water proofing, (f) skin should be closed by vertical mattress sutures.

One month after the surgery, there was no fistula or urethral leakage although latex catheter was left in place for 14 days. At first, the function of urethral sphincter could not be predicted. Postoperatively, patient could control his micturition. After several days of




Figure 6. W-plasty design for glands




Figure 7. Neourethra suture

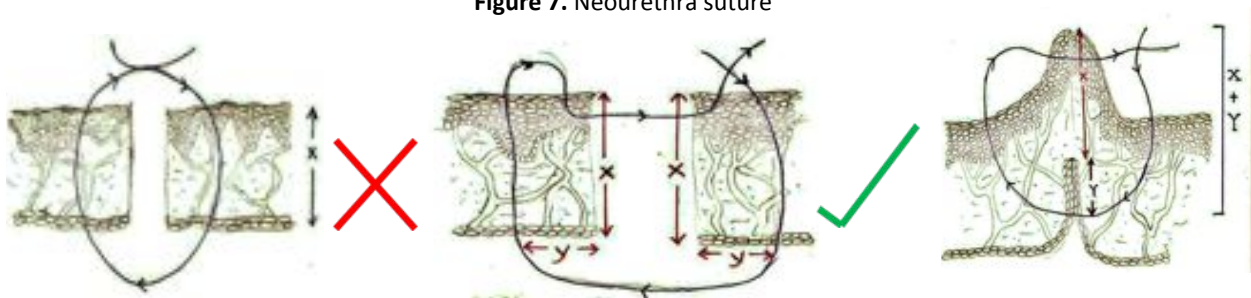


Figure 8. For this urethroplasty case, the probability for leakage was less because the raw surface contact was large enough. Neourethra was burried in the middle of raw surface, which thick enough layer(between 2 corpus cavernosum).

observation, his ability to attain erection was normal. In the future, we must consider further reconstruction for the pubic symphysiolyisis.

SUMMARY

There is no single standard procedure acceptable for urogenital malformation to date, yet we must have concerns regarding the function and appearance of the surgery. The team work of surgeons is helpful, each brings with them the expertise of their specialty. The basic principles of reconstruction are very important master and be applied in every case.

Budiman, M.D.

Department of Plastic Surgery

Gatot Subroto Central Army Hospital Indonesia

Budimanplasticsurgeon@yahoo.com

REFERENCES

1. Ambrose SS, O'Brien DP. Surgical embryology of the extrophy-epipadias complex. *Surg Clin North Am.* 1974; 54: 1379.
2. Ansell JE. Extrophy and epispadias. In: Glenn JF, ed. *Urologic Surgery.* Philadelphia: JB Lippincott; 1983:647.
3. Appignani et al., 1994. Appignani BA, Jaramillo D, Barnes PD, Poussaint TY: Dysraphic myelodysplasias associated with urogenital and anorectal anomalies: Prevalence and types seen with MR imaging. *AJR Am J Roentgenol* 1994; 163:1199.
4. Arap et al., 1988. Arap S, Nahas WC, Giron AM, et al: Continent epipadias: Surgical treatment of 38 cases. *J Urol* 1988; 140:577.
5. Baird et al., 2005. Baird AD, Mathews RI, Gearhart JP: The use of combined bladder and epipadias repair in boys with classic extrophy: Outcomes, complications and consequences. *J Urol* 2005; 174:1421.
6. Baka-Jakubiak, 2000. Baka-Jakubiak M: Combined bladder neck, urethral and penile reconstruction in

- boys with exstrophy-epipadias complex. *BJU Int* 2000; 86:513.
7. Baker and Gearhart, 1998. Baker LA, Gearhart JP: Staged approach to bladder exstrophy and the role of osteotomy. *World J Urol* 1998; 16:205.
 8. Baker Towell and Towell, 2003. Baker Towell DM, Towell AD: A preliminary investigation into quality of life, psychological distress and social competence in children with cloacal exstrophy. *J Urol* 2003; 169:1850.
 9. Bassiouny, 1992. Bassiouny IE: Continent urinary reservoir in exstrophy/epipadias complex. *Br J Urol* 1992; 70:558.
 10. Beaudoin et al., 1997. Beaudoin S, Simon L, Bargo F: Anatomical basis of a common embryological origin for epipadias and bladder or cloacal exstrophies. *Surg Radiol Anat* 1997; 19:11.
 11. Ben-Chaim et al., 1995b. Ben-Chaim J, Peppas DS, Jeffs RD, Gearhart JP: Complete male epipadias: Genital reconstruction achieving
 12. Coursey et al., 2001. Coursey JW, Morey AF, McAninch JW, et al: Erectile function after anterior urethroplasty. *J Urol* 2001; 166:2273-2276.
 13. Devine and Horton, 1977. Devine PC, Horton CE: Epipadias and exstrophy of the bladder. In: Converse JM, ed. *Reconstructive Plastic Surgery*, vol 7. 2nd ed.. Philadelphia: WB Saunders; 1977:3883-3895.
 14. Duckett, 1992. Duckett JW: Epipadias. In: Walsh PC, ed. *Campbell's Urology*, vol 2. 6th ed.. Philadelphia: WB Saunders; 1992:1914.
 15. El-Kassaby et al., 1996. El-Kassaby AW, Alla MF, Noweir A, et al: One stage anterior urethroplasty. *J Urol* 1996; 156:975-978.
 16. Gearhart et al., 1994. Gearhart JP, Leonard MP, Burgers JK, Jeffs RD: The Cantwell-Ransley technique for repair of epipadias. *J Urol* 1994; 15:457-459.
 17. Greenwell et al., 1999. Greenwell TJ, Venn SN, Mundy AR: Changing practice in anterior urethroplasty. *BJU Int* 1999; 83:631-635.
 18. Hendren, 1979. Hendren WH: Penile lengthening after previous repair of epipadias. *J Urol* 1979; 121:527-534.