

Self Made Nostril Retainer

Benni Raymond, Gentur Sudjatmiko
Jakarta, Indonesia

Background : The main feature of the unilateral cleft lip nasal deformity is the asymmetry of the nose compared with the non cleft side. Nasal stents or nostril retainers are suggested to be useful in the management of these patients in order to maintain the new morphology and to mold the shape during healing process. To date, there are many types of factory made nostril retainer, but the price is relatively expensive and in contrary, most of our patient came from low-income population.

Aim : The idea is to provide an easy and practical nostril retainer to obtain, easy to manufacture and easy to apply preoperatively and postoperatively, and it is also cost effective.

Materials and Method: Primary nose model including the nasal cavity is designed on the basis of non cleft side of patient's nose. It is made by injecting alginate as negative impression. We use gypsum powder as positive impression material. From that positive impression, we mirror it to create other side of the nostril. Nostril retainer is then made using home-use silicone gel.

Summary : We postulate that by using self-made nostril retainer which is made using cheap material. All of our patients could afford one, because the use of nostril retainer has been found effective post operatively after cleft primary rhinoplasty, avoiding relapse of the nasal reconstruction and drop of the nasal ala.

Keywords: cleft lip, nose retainer, nasal stents.

Latar Belakang: Kelainan utama pada sumbing bibir unilateral adalah ketidaksimetrisan hidung dibandingkan dengan sisi hidung yang normal. Dalam penanganan pasien seperti ini dianjurkan untuk menggunakan *stent* hidung atau nostril *retainer* untuk mempertahankan bentuk hidung pasca operasi selama proses penyembuhan. Saat ini, terdapat banyak jenis nostril *retainer* yang diproduksi pabrik, tetapi harga relatif mahal sedangkan kebanyakan pasien berpenghasilan rendah.

Tujuan: Ide tulisan ini untuk mendapatkan penggunaan nostril *retainer* yang mudah dan praktis, mudah dibuat, dan mudah untuk diaplikasikan pada waktu pra-operasi dan pasca-operasi, serta harga yang terjangkau.

Materi dan Metode: Suatu model hidung beserta rongga hidungnya dibuat berdasarkan hidung pasien pada sisi yang tidak terdapat cacat. Alat ini dibuat dengan cara menginjeksikan *alginate* sebagai cetakan negatif. Kami menggunakan bubuk gypsum sebagai bahan cetakan positif. Kami berpedoman pada cetakan positif untuk membuat nostril sisi yang bercelah. Nostril *retainer* dibuat dengan menggunakan gel silikon jenis *home-use*.

Kesimpulan : Kami menyimpulkan penggunaan nostril *retainer* buatan sendiri lebih efektif karena menggunakan bahan-bahan yang murah. Semua pasien kami membelinya, karena kegunaannya yang sangat penting setelah operasi rinoplasti primer, untuk menghindari jatuhnya ala nasi yang berakibat rekonstruksi ulang pada hidung.

Kata Kunci: cleft lip, nose retainer, nasal stents.

The main feature of the unilateral cleft lip nasal deformity is the asymmetry of the nose compared with the non cleft side. The extent of the asymmetry is often proportional to the severity of the unilateral cleft lip deformity¹. Performing primary cleft rhinoplasty

at the same setting as the cleft lip repair had been accepted worldwide^{2,3}.

Appropriate surgical procedures and subsequent accurate sustained corrected shape are indispensable for achieving a symmetrical and well-proportioned nose for patients with cleft lip and is aimed to recreate a balanced, symmetrical lip and a normal-looking nose¹. Especially in Asian patients, sustaining the sha-

From Cleft Craniofacial Center, Division of Plastic Surgery, Department Of Surgery, Cipto Mangunkusumo General National Hospital, Universitas Indonesia.

Presented in the 15th Indonesian Association Of Plastic Surgery Scientific Meeting. Semarang, Java, Indonesia

Disclosure: The authors have no financial interest to declare in relation to the content of this article.

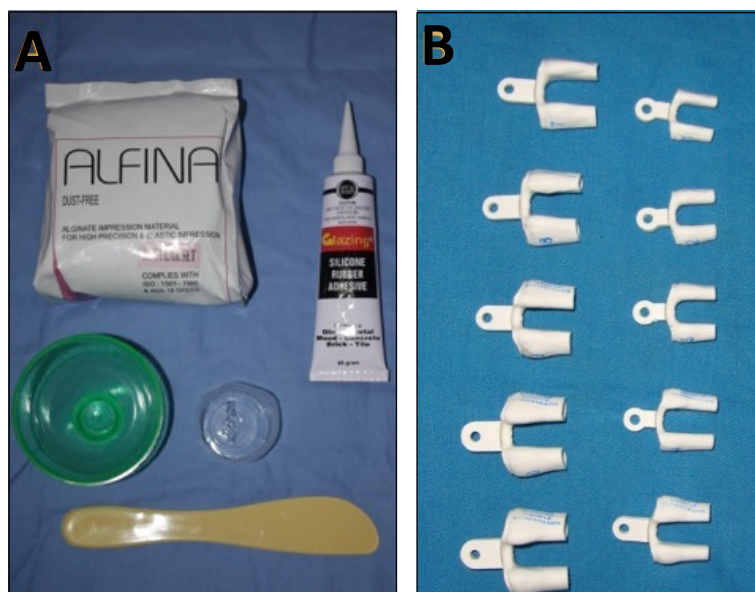


Figure 1. (A) Materials needed : alginate powder, home use silicone gel, two small container and alginate spoon. (B) Different sizes of sizer.

pe of the repaired nose after corrective surgery is extremely important. Because the Asian nose has underdeveloped, thin alar cartilage and thick skin, the corrected nose is prone to relapse after surgery⁴.

Many authors have mentioned the value of postoperative use of the nostril retainer⁵. Using a retainer, the appearance obtained by surgical correction may be maintained postoperatively and collapse may be avoided. To date, there have been reports in the literature of many types of nostril retainer, including ready-made or custom-made retainers manufactured from various materials, such as suction tubing, nasogastric tubing, and silicone urine catheters^{1, 6, 7}.

MATERIALS AND METHOD

We use materials that are cheap and easy to obtain, consisting of: alginate powder, home use silicone gel, two small container and alginate spoon (Figure 1). First of all we need sizer, it is used for measuring the diameter of patient's nostril.

Choose the correct size of sizer which suits the patient's nostril. We will use it later as a positive impression. Negative impression is made from alginate, which is mixed with water in a ratio of 1:1. If we use too much water, it will take longer time for the alginate to dry up

and if we use less water, alginate will become thick and cannot be molded to the shape of the sizer especially if it's small-sized. Diluted alginate is then poured into small container – we use small plastic glass and the sizer is put in it immediately. We wait for about ten minutes to give time for the alginate to dry and then we pull out the sizer; it should be easy to do so. For the inner nostril hole, it is made using gypsum powder. Gypsum powder is once again mixed with water in a 1:1 ratio. We will only need very small amount of this material. The sizer is laid on a clean and flat surface with one of sizer's hole facing upward. Diluted gypsum powder is then poured carefully into the hole; it will not leak through lower sizer hole due to the thickness of the solution. We wait until the gypsum is dried up and solid enough to push it out.

Take negative impression which is made earlier from alginate and carefully pour silicone gel in it, shortly after that, put solid gypsum which is made before in the middle of the negative impression, be careful and make sure it is put in the middle. Then we should wait until it is solid enough, usually it takes about 24 hours. After 24 hours, take the nostril retainer out, push the solid gypsum out of it. Craft it using a scissor or a knife to shape it better

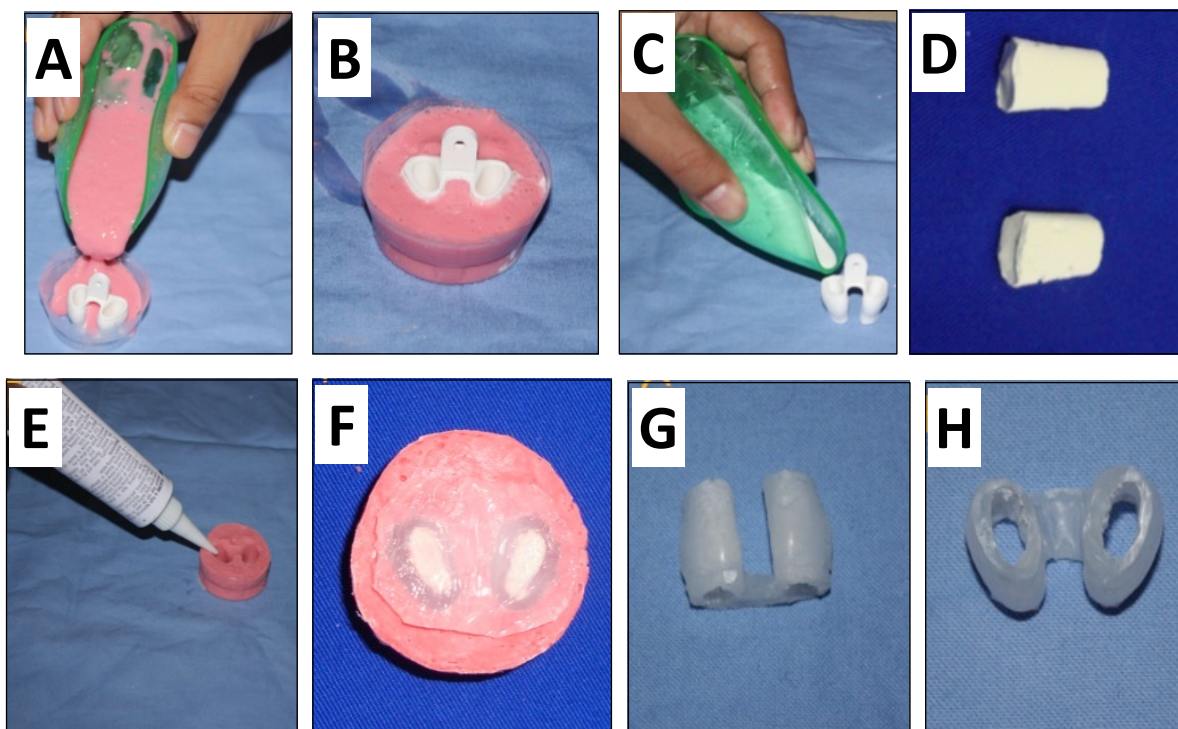


Figure 2. Processing step by step (A) Alginate solution is poured onto the sizer. (B) Make sure the solution does not exceed sizer's edge. (C) Gypsum powder is used to make nostril's hole. (D) Solid cast for nostril's hole. (E) Silicone gel being injected into alginate. (F) Solid cast is put in the middle of nostril's hole. (G-H) Final results.

(Figure 2). Finally, boil it in water for about half an hour to dilute citric acid in the silicone gel that would cause skin irritation.

DISCUSSION

Several studies show that postoperative nasal splinting in the primary management of the unilateral cleft nasal deformity serves to preserve and maintain the corrected position of the nose after primary lip and nasal correction, resulting in a significantly improved aesthetic result. Therefore, it is recommended that all patients undergoing primary correction of complete unilateral cleft deformity use the nasal retainer postoperatively for a period of at least 6 months⁸.

We propose a simple and feasible method to produce nostril retainer. It is made of cheap materials which are easy to obtain. Factory-made nostril retainers cost about IDR 700,000 (2011 price list) while all of the materials needed for our own nostril restrainers only cost about IDR 79,000. Furthermore, with this relatively small amount of money we are able to produce

8-10 nostril retainer. Bearing in mind the fact that most of our patients come from low income population, we hope that all of our patients would be able to afford this nostril restrainer after they underwent surgery. We also hope that practitioners in need of this nostril retainer will be able to produce the restrainer for their patients themselves.

SUMMARY

Self-made nostril retainer is a good tool for postoperative cleft patients after having primary rhinoplasty. It is a cheap and effective material to hold the nasal alae to stay in its position after the operation. It also keeps airway patency and avoids surgical adhesion because of nasal secretions and scarring. Among the procedures, we also need parents' participation.

Gentur Sudjatmiko, M.D.

Cleft Craniofacial Center. Plastic Surgery Division
Cipto Mangunkusumo General National Hospital
Jalan Diponegoro.No.71, Gedung A, Lantai 4.
dr_gentur@yahoo.co.id

REFERENCES

1. Yeow V. K. L., Chen P. K. T., Chen Y. R., Noordhoff S. The use of nasal splints in the primary management of unilateral cleft nasal deformity. *Plast Reconstr Surg.* 1999; 103(5): 1347-1354.
2. McComb H. Primary correction of unilateral cleft lip nasal deformity: A 10-year review. *Plast Reconstr Surg.* 1985; 75: 791-797.
3. Salyer KE. Primary correction of the unilateral cleft lip nose: A 15-year experience. *Plast Reconstr Surg.* 1986; 77: 558-566.
4. Uhm K. I., Hwang S. H., Choi B. G. Cleft lip nose correction with onlay calvarial bone graft and suture suspension in Oriental patients. *Plast Reconstr Surg.* 2000; 105: 499.
5. Noordhoff M. S., Chen Y. R., Chen K. T., Hong K. F., Lo L. J. The surgical technique for the complete unilateral cleft lip nasal deformity. *Oper Tech Plast Reconstr Surg.* 1995; 2: 167.
6. Dhanraj P. The use of a suction tube as a nostril retainer. *Plast Reconstr Surg.* 1994; 93: 643.
7. Ozgur F, Tuncali D, Kayıkcıoğlu A. Securing the nostril retainer. *Plast Reconstr Surg.* 1999; 104: 882.
8. Yildirim S., Aköz T. A simple and cheap nostril retainer: Silicone urine catheter. *Plast Reconstr Surg.* 2001; 107: 1308.