

## Squamous Cell Carcinoma Arising From Marjolin's Ulcer Due To Post Burn Scar: A Case Report

Parintosa Atmodiwirjo, Sachraswaty Laidding  
Jakarta, Indonesia.

**Background:** Marjolin's ulcers are a rare squamous cell carcinomas which develops in non-healing scar tissue. The most frequent predisposing lesion is in a post burn wound, especially after flame burns. Incidence appears to be on the rise and outcome of treatment remains poor.

**Methods:** A 51-years old male with burn scar at the posterior left calf since 43 years ago. After burnt, the wound was left to heal spontaneously with minimal treatment. Three years later an unhealing wound emerged on the scar. This wound got bigger, spreaded further, turned into a mass 15 x 8 x 5 cm in size. The tumor was mobile, ulcerative with unprovoked bleeding, malodorous, and painful. Biopsy and imaging concluded a diagnosis of Squamous Cell Carcinoma from Marjolin's Ulcer, Stage III (T4N0M0). Wide excision was performed 1-2 cm from hiperemis area, neighboring muscles sacrificed. Frozen section revealed a free-tumor margin and wound covered by split thicknes skin graft.

**Result:** On folllow up, STSG's "take" was 100%. Four months postoperation, a wound the size of 1 x 1 x 0,5 cm appeared at the distal left posterior calf. Biopsy was performed, result showed granulating tissues with no sign of malignancy. The wound was treated in the outpatient, and healed well.

**Summary:** Marjolin Ulcer's prognosis is not very favorable so it best to prevent at the best first place.

**Key Words:** *Marjolin's ulcers, Squamos Cell Carcinomas, post burn wound, wide excision.*

**Background:** Ulkus Marjolin adalah kasus jarang karsinoma sel skuamosa yang terbentuk dari jaringan parut yang tidak sembuh-sembuh. Paling sering terjadi pada luka pasca luka bakar, terutama akibat luka bakar api. Insidens tampaknya meningkat namun hasil akhir terapi tetap buruk.

**Metodologi:** Laki-laki usia 51 tahun dengan luka parut akibat luka bakar di paha kiri sisi belakang yang dideritanya sejak 43 tahun yang lalu. Saat terbakar, luka dibiarkan sembuh sendiri tanpa perawatan khusus, 3 tahun kemudian muncul luka yang tidak sembuh-sembuh pada bekas luka. Luka membesar dan menjadi benjolan berukuran 15 x 8 x 5 cm. Massa mobile, ulseratif dan mudah berdarah, berbau serta nyeri. Biopsi dan pemeriksaan radiologi menyimpulkan diagnosa karsinoma sel skuamosa dari ulkus Marjolin, stadium III (T4N0M0). Dilakukan eksisi luas 1-2 cm dari tepi hiperemis, otot sekitar tempat massa melekat dibuang. Pemeriksaan potong beku menyatakan margin bebas tumor, dan luka ditutup dengan STSG.

**Hasil:** Pada follow up, STSG take 100%. Empat bulan setelah operasi, didapatkan luka ukuran 1 x 1 x 0.5 cm muncul spontan di paha kiri distal sisi belakang. Dilakukan biopsy ulang, dinyatakan berupa jaringan granulasi, tanpa tanda ganas. Luka dirawat di poliklinik dan membaik.

**Ringkasan:** Ulkus Marjolin mempunyai prognosis yang buruk maka dari itu hendaknya di cegah sejak awal.

**Kata kunci:** *Ulkus Marjolin, karsinoma sel skuamosa, pasca luka bakar, eksisi luas.*

**M**arjolin's ulcer is a lesion which grows out of fibrous scar tissue mostly due to burn wounds, chronic osteomyelitis, chronic inflammation, or chronic fistula<sup>1-6</sup>. This type of ulcer is rare, typically grows out of non-healing wounds accompanied by chronic trauma, and especially on post burn scars<sup>5</sup>. Marjolin's ulcer ever so often progressed

into squamous cell carcinoma (SCC) although it would require a long period of time<sup>4,7,8</sup>.

Squamous cell carcinoma (SCC) is a type of neoplasm which arises from the epidermal suprabasal keratinocytes. This is the second most common non-melanocytic neoplasm after basal cell carcinoma (BCC)<sup>1,2</sup>. The true incidence of SCC to date is not well documented by the National Cancer Institute.

*From Division of Plastic Surgery, Department Of Surgery, Cipto Mangunkusumo General National Hospital, Universitas Indonesia.*

*Presented in 15th IAPS Scientific Meetings In Semarang, East Java, Indonesia*

**Disclosure:** *The authors have no financial interest to declare or commercial affiliations in relation to the content of this article.*

An estimated number is one per 1000 population in the United States<sup>1</sup>. The incidence escalates within the area with more exposure to sunlight, reaching 200-300 cases per 100,000 population in Australia<sup>3</sup>.

Several predisposing factors are known to be associated to SCC, such as age above 40-years old, exposure to sunlight, carcinogenic agents (tar, arsenic, hydrocarbon, polycyclic aromatase, paraffins), smoking, chronic trauma or burn wound to the skin, ionizing radiation, and Marjolin ulcer.

The clinical presentation of skin SCC is usually seen as ulcerated nodular lesion or as a verrucose plaque with cornification or hyperkeratoticity<sup>1,2</sup>. These lesions are usually located on the body areas most exposed to the sunlight<sup>1-3</sup>. Unlike the typical skin SCC, one which arise from a Marjolin's ulcer develops from a chronic non-healing wound, or one which experience repetitive chronic trauma, or burn wounds<sup>4,5,7,8</sup>. This paper reports a case of Marjolin's ulcer which progressed into SCC.

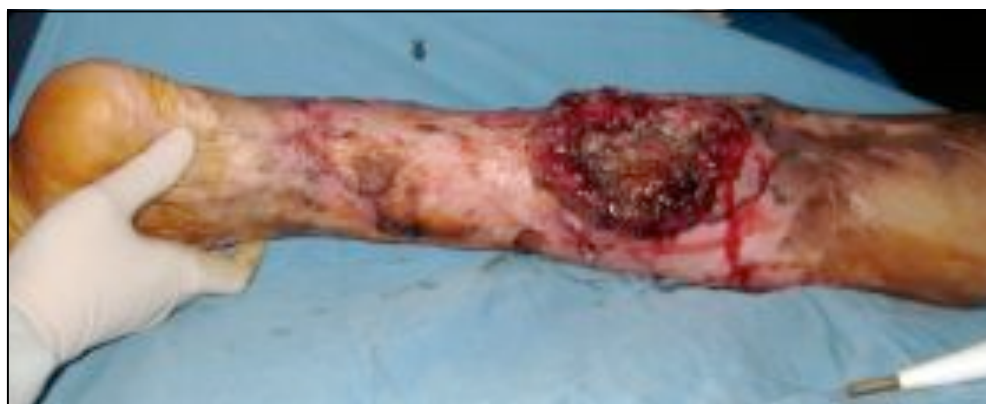### CASE REPORT

A 51-year old male came to the Plastic Surgery Polyclinic in our hospital with complain of an unhealing growing wound on the back of his left calf. 43 years ago the patient had a burn injury on that site and the wound was left to heal without specific treatments. In the last three years a wound spontaneously appeared on top of the burn scar, it did not heal during the three-year time and grew bigger (Figures 1). The patient went to the Puskesmas


to seek treatment, was diagnosed with infected wound and were given some medications in form of ointment and oral medication. The patient regularly apply penicillin powder on the surface of his wound, however the wound kept getting bigger. It also easily bleeds, malodorous, and tender to a point that the patient's working life was disturbed. He sells soto for a living. Patient smokes at least a pack of cigarettes a day, with no history of chronic disease.

Upon examination, patient's general condition is relatively well, fully alert, with good nutritional state. Inspection of he left posterior cruris region revealed an oval shaped tumor the size of 15 cm x 8 cm x 5 cm. The mass is mobilis, has irregular edges, with induration and elevation on various part. The center of the lesion is ulcerated with areas of erosion and crusting, and pus present. The mass was brittle, easily bled, foul-smelling and painful. No lymph nodes enlargement was found in the inguinal area. Laboratory findings revealed normal complete blood counts, blood chemistry, blood sugar level, and hemostatic factors. The working diagnosis was chronic wound suspected to be Marjolin's ulcer with secondary infection.

Incisional biopsy of the lesion, and histopathological examination revealed tissue pieces which displayed hyperplastic and hyperkeratotic stratified squamous epithelium, with irregular growth, papillary in some part. Epithelial tumor cells are found clustered in the dermal layer with mild pleomorphic nuclei,



**Figure 1.** Tumor mass on the left posterior calf, oval in shape, uneven surface with nodular lesions. Size: 15 cm x 8 cm x 5 cm, mobile, irregular border. Induration, ulceration, erosion are present. Mass easily bleeds, malodorous, and painful.



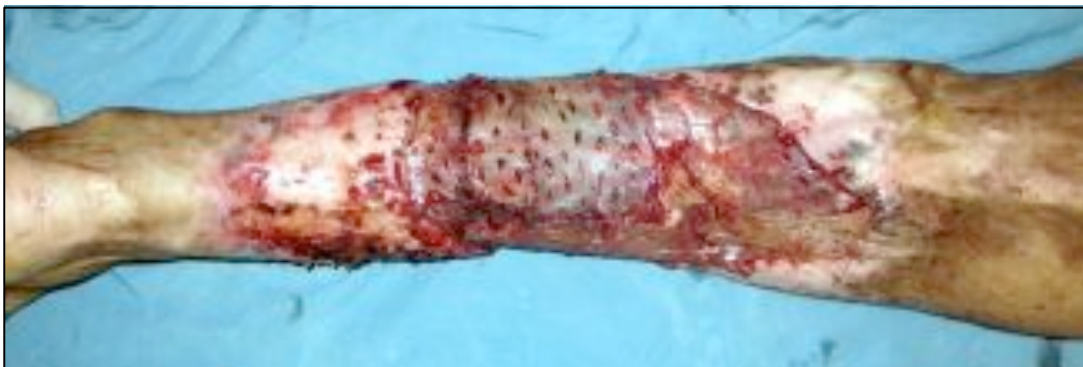with cell-bridging still visible, and many eosinophilic cytoplasm. Tumor mass invasion can be seen, with necrotic focus. Histological picture is in accordance with "pseudepitheliomatosis hyperplasia". Pathological diagnosis favors Marjolin's ulcer. After biopsy, the patient was given antibiotic and analgetic therapy.

MRI examination showed soft tissue mass on the dermal layer, located subcutaneously on the proximal to distal site of posterior tibia, with partial infiltration to the gastrocnemius and soleus muscles. Ultrasound did not revealed any distant metastatic lesion. The patient was diagnosed with Squamous cell carcinoma arising from Marjolin's Ulcer stage III (T4NoMo).

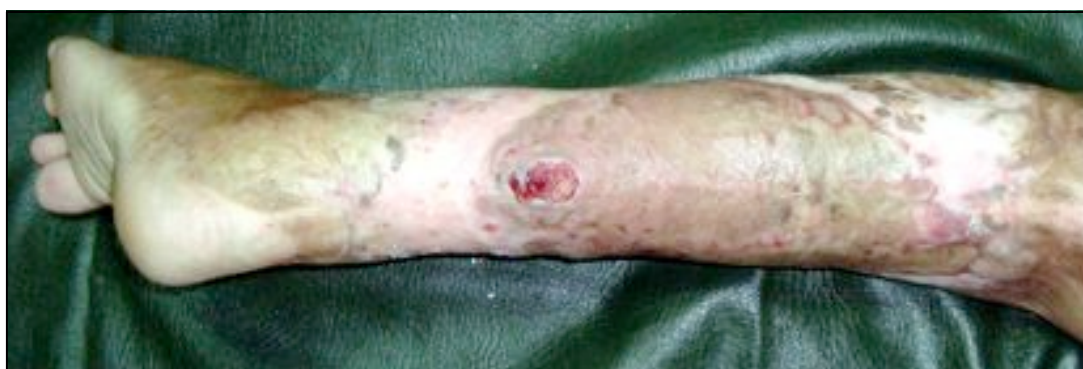Patient underwent a tumor ablation surgery by wide excision. Intraoperative, frozen section was performed and hyperplastic epidermal skin tissue was identified, with some

part of the tumor progressing into a malignant epithelial tumors. Pleomorphic nuclei, coarse and prominent chromatin, and mitotic process were found in tumor cells. It also revealed a pearl-like chromatin and intercellular bridging, with dense acute and chronic inflammatory cells. The lateral, superior, inferior, medial, and base margin of incision were free of tumors. Pathological conclusion: tumor displayed squamous cell carcinoma with well-differentiated keratinized accordance with Marjolin's ulcer. Defect was then covered using the split-thickness skin graft (STSG) harvested from the contralateral thigh (Figure 2).

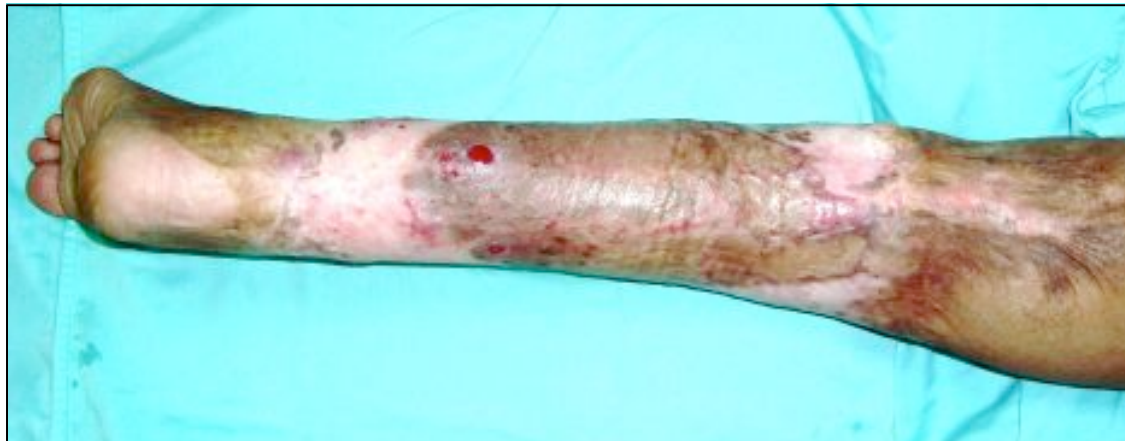Patient was treated in the ward for two weeks after surgery with antibiotic and analgetic administration. Seven days postsurgery, the STSG took 100%. Patient was scheduled for a weekly follow-up visits in RSCM's Plastic Surgery Clinic. Four months after the wide-excision surgery, two small



**Figure 2.** Tumor excision and defect coverage by split-thickness skin graft.



**Figure 3.** Four months post excision and graft, spontaneous lesion recurs. Biopsy revealed granulating tissue with no sign of malignancy.



**Figure 4.** Two weeks post spontaneous lesion occurrence and re-biopsy, wound is healing.

wounds appeared on the area that was been covered by kin graft (Figure 3). Another biopsy was performed, and the pathologist revealed findings of epidermal cyst and granulating tissue, with sign of malignancy. The wound were treated with gentamycin ointment and oral antibiotic twice a day. Patient's wound eventually healed within a few weeks and patient was able to return to his daily activities with minimal discomfort. To prevent SCC recurrence, the patient was advised to undergo adjuvant radiotherapy, but until this article is published the patient had not complied.

### DISCUSSION

In 1828, Jean-Nicholas Marjolin first reported the presence of ulcers which arised from chronic inflammation, chronic osteomyelitis, chronic fistulas, and especially from scar tissue caused by burns<sup>4,7</sup>. With the increasing knowledge of ulcers and burn scar tissue, Marjolin ulcer was known to have a malignant tendency which frequently develops into SCC after 25-40 years.<sup>7</sup> This rare type of ulcer usually develops from ulcers which have failed to heal<sup>4,5,8</sup>. Prior literatures regarding the Marjolin's ulcers are rarely found. In Indonesia within the last 10 years, only two cases were recorded, both from RS. Dr. Sardjito Hospital, Yogyakarta<sup>9</sup>.

The pathogenesis of Marjolin's ulcer has not been clearly established until now. Chronic skin trauma and scar tissue growth especially

from burn injury, leads to an avascular condition which decreases the surveillance system of immunity cells against neoplastic cells, and this is suspected to be the cause<sup>4,7</sup>. The surveillance function against neoplastic cells failed, and is assumed to be the responsible cause in the growth of malignant cells in the Marjolin's ulcer<sup>4,7,8</sup>. The majority of Marjolin's ulcers are found in the extremities (85%) especially the lower leg (58%)<sup>8</sup>. Various reports indicated that 70% to 90% of Marjolin's ulcer scarring are caused by burns<sup>4,5,7,8</sup>. Our patiet had a few predisposing factors which contributes to the development of SCC, such as: the longstanding scar tissue once inflicted by a burn injury which has been suffered by more than 40 years, smoking habits, age, persistent chronic wound, and the habit of applying penicillin powder on the wound's surface.

Squamous cell carcinoma can be clinically classified using the tumor-node-metastases (TNM) system<sup>2,10</sup>. The SCC lesions in this patient clinically met the criteria of T4N0M0 where T4 means the tumor has invaded extradermal structure based on MRI examinations. Physical examination, did not reveal regional lymph node metastases (N0), while chest x- ray and ultrasound found no distant metastases (M0).

According to the TNM criteria of SCC's classification, the patient were at stage III. In accordance with a protocol implementation of operable SCC of the body and extremities, a

wide excision with additional 1-2 cm out of safety margin was done. This patient underwent a surgical removal of the tumor with by excision and frozen section which proved tumor-free incision. Wide excision is an effective conventional technique for the ablation of SCC when possible. The recommended excision for tumors with more than 2 cm diameter is 1-2 cm out of tumor's safety margin.

Post-surgical wide excision defect was covered using STSG, taking into consideration that an STSG alone can later easily indicate whether the base and margins of excision free from tumor. The STSG was fully successful taking into account that no part had necrosed in this patient, and lasted for 4 months after surgery, when suddenly 2 small raw surface appeared. At first, a recurring SCC was a concern but rebiopsy showed no sign of malignancy. The wound dried after conservative management in a few weeks, and patient were able to return to his daily activities with minimal interruption.

Histopathologic outlook, TNM classification, and recurrence rate are prognostic factor of SCC<sup>1,2</sup>. Recurring factors that have been reported include more than 2 cm in diameter, greater than 4 mm depth of lesion, involvement of bones, muscles, and nerves, the location on the ear and lip, tumor developed from scar tissue, immunosuppression condition, and the absence of inflammatory infiltrates in the lesion.<sup>1,2,4,8</sup>

Based on the pathological results, TNM classification, location of lesions, lesions that originate from the development of scar tissue, the patient's age, smoking factor, concludes the prognosis of this patient with SCC to be uncertain.

Preventing a secondary wound healing on an injury (particularly burns) is a preventive effort that should be done early to avoid the formation of Marjolin's ulcers which has a tendency to develop into SCC<sup>4,7</sup>. Clinicians should always be vigilant and have an awareness to suspect malignancy when encountering an ulcer which could not heal in more than 3 months<sup>1,4,8,12</sup>. An earlier diagnosis obtained from a histopathological examination will improve the prognosis of this disease<sup>1,4,11</sup>.

**Parintosa Atmodiwirjo, M.D.**

Plastic Surgery Division

Cipto Mangunkusumo Hospital

Jalan Diponegoro 71, Salemba, Jakarta

parintosaa@yahoo.com

#### **Acknowledgement**

We thank B.J. Bismedi, M.D. for help in reviewing this article. Laureen Supit, M.D. for basic article editing and proof reading.

#### **REFERENCES**

1. Grossman D, Leffel DJ. Squamous Cell Carcinoma. In: Wolff K, Goldsmith LA, Katz SI, Gilchrist BA, Leffel ASPJ, editors. Fitzpatrick's Dermatology in General Medicine, 7 ed. New York: McGraw-Hill; 2008:1028-36.
2. Alam M, Ratner D. Cutaneous Squamous-Cell Carcinoma, NEJM 2001;334:975-83.
3. Leibovitch I, Huigol SC, Selva D, Hill D, Richrads S, Paver R. Cutaneous Squamous Cell Carcinoma treated with Mohs micrographic surgery in Australia II, Perineural invasion. J Am Dermatol 2005;53:261-6.
4. Kowal-Vern A, Chiswell BK. Burn Scar Neoplasm: a literature review and statistical analysis. Burns 2005;31:403-13
5. Ozek C, Cankayah R, Bilkay U, Cagdas A. Marjolin's ulcer arising in burns scar. J Burns Care Rehabilitation 2001; 22:384-9.
6. Gul U, Kilic A. Squamous cell carcinoma developing on burn scar. Ann Plast Surg 2006;56:406-8.
7. Soto-Davalos BA, Cortes-Flores AO, Bandera-Delgado A, Luna-Ortiz K, Padilla-Rosciano AE. Malignant neoplasm in burn scar; Marjolin's Ulcer. Report of two cases and review of the literature. Cir 2008;76:323-5.
8. Jellouli-Elloumi A, Kochbati L, Dharaief S. Cancers arising from burn scar; 62 cases. Ann Dermatol Venerol 2003;130:413-6.
9. Waldrof HA. Squamous cell carcinoma. In: Lebowitz MG, Heymann WR, Berth-jonesa J, Coulson I, editors. Treatment of Skin Disease. Comprehensive Therapeutic Strategies. London, Mosby; 2002:592-5.

10. McKee PH, Calonje E, Granter SR. Pathology of the skin. In: Disorder Pigmentation, 3 ed. Philadelphia: Elsevier Mosby;2005:1119-208.
11. Copcu E, Aktas A, Sisman N, Oztant Y. Thirty-one caases of marjolin's ulcer. Clinial Exp Dermatol 2003;28:138-41.
12. Weisberg NK, Bertagnolli MM, Becker DS. Combine sentinel lymphadectomy and mohns micgrographic surgery for high risk cutaneus squamous cell carcinoma. J Am Acad Dermatol 2000;43:438-8.