

# THE EFFICACY OF BARE SCLERA AND MULTILAYER AMNIOTIC MEMBRANE TRANSPLANTATION (MLAMT) FOR RECURRENT MOOREN'S ULCER

Getri Sukmawati, Havriza Vitresia

Infection-Immunology Division, Department of Ophthalmology Faculty of Medicine Andalas University / Dr. M. Djamil Hospital Padang, West Sumatera-Indonesia  
E-mail : getri\_sukmawati@yahoo.co.id

## Abstrak

**“Mooren’s Ulcer”** adalah ulkus kornea yang bersifat progresif, nyeri, sering berulang sedangkan penyebabnya tidak diketahui. Pada tulisan ini dilaporkan kegunaan tindakan operasi **“Bare Sclera conjunctival resection”** dengan pemasangan **MLAMT** pada ulkus Mooren yang diikuti dengan penutupan mata selama 3 hari berturut turut. Pada pasien ini dikerjakan 3 kali operasi yang sama. Kasus adalah seorang wanita berumur 45 tahun dengan Ulkus Mooren yang sudah berulang di pinggir kornea didaerah flap konyungtiva pada mata kanannya sedangkan mata kiri dengan **“pthysis bulbi”**. Visus mata kanan 20/25, mata kiri Nol, pemeriksaan laboratorium normal, saat ini pasien menolak untuk dilakukan operasi. Pasien datang 1 bulan kemudian dengan keadaan yang lebih buruk, dan setuju dioperasi, dilakukan **Partial Bare Sclera conjunctival resection** dengan **MLAMT**, pada hari kesembilan setelah operasi sudah terjadi epitelisasi komplit. Empat bulan kemudian ulkus korneanya meluas keparasentral dan superior kornea yang cenderung perforasi, dilakukan operasi kedua dengan tehnik yng sama. Ternyata epitelisasi kornea baru komplit pada hari ketigabelas. Hal yang sangat jelek adalah ditemukan lagi ulkus baru dibagian bawah kornea, sehingga diputuskan untuk langsung melakukan **Total Bare Sclera conjunctival resection** dan **MLAMT**, Epitelisasi komplit pada ulkus terjadi pada hari kesembilan. Pengobatan setelah operasi antibiotik tetes mata dan kortikosteroid secara sistemik. Visus mata kanan saat ini 20/40. Dapat disimpulkan bahwa Ulkus Mooren merupakan ulkus kornea yang progresif, dengan transplantasi membrane Amnion dan **Bare Sclera** dapat memperlama munculnya rekurensi tapi tidak menyembuhkannya.

**Kata kunci:** *MLAMT, Bare Sclera, Mooren’s ulcer*

## Abstract

Mooren’s Ulcer is a progressive, pain corneal disease, which is difficult to be treated with unknown etiology. This Interventional Case Report is aimed at reporting the efficacy of Bare Sclera and (MLAMT) with three days patching for recurrent Mooren’s Ulcer.

We performed three times Bare Sclera conjunctiva resection with MLAMT on one case of recurrent Mooren's ulcer. Forty five years old female with Recurrent Mooren's ulcer on the right eye, at margin of the conjunctival flap and pthysis bulbi on the left eye. Visual acuity (VA) on the right eye was 20/25. Normal laboratory examinations. In this condition she did not agree for operation. One month later, with worse condition, and we performed partial Bare Sclera with MLAMT. After surgery, the epithelialization was completes on the ninth day. Four months later, the active ulcer was extended to paracentral and superior cornea with impending perforation. We did second surgery, partial Bare Sclera with MLAMT. After surgery, the epithelialization was completes on the thirteenth day. Unfortunately, we found the new ulcer on the inferior cornea, and then we decided to perform the third surgery, total Bare Sclera and MLAMT, the epithelialization was completes on the ninth day. Post operation, topical antibiotic and systemic corticosteroid. The VA on the right eye was 20/40.

We conclude that, Mooren's ulcer is a progressive corneal disease. Although only one case being reported, MLAMT can reduce the recurrence duration of Mooren's ulcer, but cannot stop the progressivity. MLAMT could be performed more than once. Total conjunctiva resection can make epithelialization significantly faster than partial resection.

*Keywords: MLAMT, Bare Sclera, Mooren's ulcer*

## Introduction

Mooren's ulcer was first described by Bowman in 1849 and McKenzie in 1854 as '*chronic serpiginous ulcer of the cornea or ulcus rodens*'. However, Mooren who was the first to publish several cases on this condition in 1867 and also the first to clearly describe this corneal condition and define it as a clinical entity.<sup>(1)</sup>

Mooren's ulcer is an idiopathic, painful, relentlessly progressive chronic ulcerative keratitis that begins as grayish infiltrations,<sup>(2)</sup> as a crescent-shaped gray-white infiltrate in the perilimbal cornea, usually in the interpalpebral fissures.<sup>(3)</sup> Its most unique clinical characteristics include the "*eating away*" of cornea central to the most obvious crescent of epithelial defect and stromal melting, the process eventually undermines the central wall of the thinned tissue, leading to characteristic "*overhanging*" central edge.<sup>(2,3)</sup> It's progresses circumferentially and centrally, some times progressing to full corneal thickness and perforation. Srinivasan et al,<sup>(4)</sup> were reported that in patients with total corneal involvement, the corneal stroma was replaced by fibro vascular scar covering an intact Descemet's membrane. Although spontaneous perforation is uncommon, these eyes are characteristically quite vulnerable toward perforation with minimal trauma. The ulcer usually responds poorly to conventional therapy, occurring in the complete absence of any diagnosable systemic disorder that could be responsible for the progressive destruction of the cornea.<sup>(1-3)</sup>

Wood and Kaufman classified the disease into two groups according to the age of onset, clinical characteristics, and prognosis. Type I

was benign and usually unilateral with mild to moderate symptoms, occurs in old people over 35 years, usually well responded to medical and surgical treatments. The second type was more likely to be bilateral with relative more pain and generally a poor response to the therapy occurs in young patients younger than 35 years. Watson divided the disease into three types, unilateral Mooren's ulcer, bilateral aggressive Mooren's ulcer, and bilateral indolent Mooren's ulcer.<sup>(1-3)</sup>

## Pathogenesis

Mooren's Ulcer is one differential diagnosis of peripheral ulcerative keratitis (PUK), involvement of the limbus, begins as grayish infiltrations in the perilimbal cornea, there is no clear zone (lucid interval)<sup>(1)</sup> between the ulcer and the limbus. The central margin of the ulcer has an overhanging edge, without associated with necrotizing scleritis, and many of the collagen vascular diseases. In very severe cases, episcleritis or even scleritis may be present,<sup>(5)</sup> the exact pathophysiology remains uncertain and recent study indicates that it is an autoimmune process, with both cell-mediated and humoral components. On pathological examination, plasma cells, neutrophils, mast cells and eosinophils have been found in the adjacent conjunctiva. In the involved areas, Brown<sup>in1</sup> has demonstrated the high levels of proteolysis enzymes and they found that numerous active neutrophils were the source of the proteases and collagenases that degrade the corneal stroma.

A deficiency of suppressor T cells was found in the serum of patient with Mooren's ulcer. The ratio of helper T cell/suppressor T cell greater than 1/1.<sup>(3)</sup> The unregulated helper T cells overproduce antibodies, resulting

in the deposition of immune complexes, complement activation, inflammatory cell infiltration, and proteolysis enzyme release in Mooren's ulcer.

Gottsch et al (1995),<sup>(6)</sup> Bielinska A et al (2006),<sup>(7)</sup> found that a great role play for pathogenesis in Mooren's ulcer, probably reaction of auto antibodies against to Cornea-Associated Stromal Antigen (CO-Ag). This antigen has appeared to be similar to calgranulin C, which found in circulating leucocytes,<sup>(8)</sup> and the protein binding  $Ca^{2+}$  fixed on the surface of the helminthes.<sup>(8)</sup>

Taylor et al (2000),<sup>(8)</sup> Zelefsky JR et al (2007),<sup>(9)</sup> had been reported a possible association between HLA-DR17 and/or DQ2 susceptibility to Mooren's ulcer. Liang CK et al (2002),<sup>(10)</sup> also reported about HLA-DR17 and HLA-DQ2 and suggested HLA-DQ5 might be another candidate gene of HLA associated with Mooren's ulcer. This is why the immunosuppressive therapy has been shown to be increasingly successful in patient who is unresponsive to conventional treatment.<sup>(1)</sup> Advances have been made for better understanding of the etiopathogenesis and for the management of this disorder, but a significant percentage of cases remain refractory to available therapies and results in severe visual morbidity.

Infectious associations have been reported with helminthiasis and hepatitis C. Schanzlin<sup>in1</sup>, speculated that the antigen antibody reaction to helminth toxins deposited in the peripheral cornea provokes the inflammation and ulceration. Wilson SE et al(1993),<sup>(11)</sup> Baratz KH et al (1998),<sup>(12)</sup> proposed that molecular mimicry maybe involved, with the

hepatitis C virus stimulating an autoimmune in response to corneal antigens through cross-reacting epitopes. Alternatively, they also proposed that deposition of immune complexes in limbal or peripheral corneal tissues may lead to an immune response and release of proteolysis enzymes. Other infections that have been associated with Mooren's ulcer include herpes simplex and zoster, syphilis, tuberculosis, and there are also other associations reported with physical trauma, foreign body, chemical burn, and may recurred after surgical procedure such as cataract extraction and penetrating keratoplasty.<sup>(1,2)</sup>

Touge et al (2004),<sup>(13)</sup> found in their case, that Mooren's ulcer occurred solely at the head of a pterygium. On their observed, they found the infiltration of lymphocytes in the body of the pterygium, and in the ulcer area, there was irregular proliferation of the corneal epithelium and infiltration of numerous neutrophils and lymphocytes under the corneal epithelium. Both T and B cells were infiltrated into the pterygium body and ulcer area, and T cells especially were more abundant in the ulcer area than in the pterygium body.

### **Treatment**

The initial medical therapy for Mooren's ulcer include, aggressive steroid topical eye drops such as prednisolone acetate or phosphate 1%, hourly (or every half hour),<sup>(14)</sup> cycloplegics eye drops and prophylactic antibiotics. If epithelialization occurs, topical steroids can be tapered slowly over several months, we must be aware in used intensive corticosteroid topical, it can be delayed of epithelial wound healing

and impedes corneal perforation, in this case we can consider to changes with systemic corticosteroid.<sup>(14)</sup> Topical tetracycline or medroxyprogesterone can be used for anticollagenolytic properties and therapeutic soft contact lens or patching of the eye for rapid epithelialization and reduces corneal pain.

The use of topical and systemic immunosuppressive chemotherapy; cyclophosphamide (3mg/kg/day), metho-trexate (7,5 to 25 mg/week) and azathioprine (3mg/kg/day),<sup>(1)</sup> cyclophosphamide may be effective by suppressing B-lymphocytes, which produce autoantibodies and promote immune complex disease. Cyclosporine-A systemic 3-4 mg/kg/day and topical 0,05%, 0,1%,<sup>(15)</sup> 0,2%, may work by suppression of the helper T-cells population and stimulation of the depressed population of cytotoxic T-cells, has been successfully used to treat Mooren's ulcer.

Erdem U et al (2006),<sup>(16)</sup> reported the beneficial effect of topical Interferon Alfa 2a (1 million international units per milliliter, were prepared via dilution of the injectable recombinant IFN $\alpha$ 2a with preservative-free balanced salt solution) for 2 patients with unilateral Mooren's ulcer. The diagnosis of Mooren's ulcer was made based on clinical presentation, negative laboratory work up for underlying diseases and the antibodies against herpes simplex virus, herpes zoster virus, toxoplasma, hepatitis B and C viruses were not detected in the serum patients. The corneal cultures for possible infective agents were negative too.

Fontana L et al (2007),<sup>(17)</sup> reported their case about using of infliximab, an anti-tumour necrosis factor agent, for the treatment of one

patient with progressive bilateral Mooren's ulcer developed recurrent corneal perforations and melting, requiring tectonic grafts. The patient had been treated with conventional triple oral immunosuppression (Azathioprine, and then Cyclosporin A coupled with Metotrexate) during 2 years. Before that, the patient also was treated by conjunctival resection, corneal gluing and oral prednisone. The reduction of conjunctival injection was observed soon after the first infliximab infusions and no recurrence of ulcerations and perforations during a follow up of 2 years. No significant side effects occurred during treatment.

Conjunctival resection and excision (Bare sclera) was shown to be an effective temporary surgical treatment for Mooren's ulcers because it decreases the exposure of corneal stromal antigen by systemic circulation. The resection should extend 3 to 4 mm posterior to the limbus and well beyond the edge of the affected area,<sup>(18)</sup> and the recommended area of conjunctival excision includes 1 clock hour on the either side of the ulceration.<sup>(19)</sup> the operation can follow with used Amnion Membrane Transplantation for faster recovery and minimal cicatrices after operation.

Human Amniotic Membrane (HAM) is the innermost of the three layers forming the fetal membranes; it is a biological tissue that has been used as graft for corneal and conjunctiva reconstruction in a variety of ocular surface diseases. The first use of HAMT in ophthalmology was by De Rotth in 1940; follow by Sorsby and Symons 1946, Kim and Tseng 1994.<sup>(20)</sup> It is avascular and possesses antiangiogenic, to facilitate ocular surface healing with minimal inflammation and scarring, antimicrobial, non-immunogenic, anti

inflammatory properties and reduces of corneal pain. It is not a substitution but rather a substrate upon which cells can migrate and regenerate, promote epithelial differentiation, reinforce adhesion of the epithelial cells, and prevent epithelial cell apoptosis or programmed cell death.<sup>(21,22)</sup> The AM used as a biologic patch, as a bandage, to treat corneal and conjunctiva inflammation to forming new and healthy tissues.<sup>(21,22)</sup>

The MLAMT is useful in corneal ulceration and corneal perforation, the success rate of 72% compare 64% with monolayer. Reported by Lee SH et al (1966),<sup>(23)</sup> Kruse et al (1999),<sup>(24)</sup> Hanada et al (2001),<sup>(25)</sup> Prabhasawat et al (2001),<sup>(26)</sup> Sukmawati (2006),<sup>(27)</sup> the multilayered AMT have been successful because the monolayer AMT disappears within a few weeks. Solomon et al (2001),<sup>(28)</sup> reported a success result in 82.3% in multilayered AMT and, by using multilayered the corneal defect healed significantly faster than a single layer.

The Amnion Membrane use in this case is The Freeze-Dried (FDAM) prepared by The M. Djamil Hospital Tissue Bank (West Sumatera, Indonesia) has a Standard Operating Procedure from International Atomic Energy Agency (IAEA), to assure the quality of the lyophilisation and radiation sterilization.<sup>(29)</sup>

### Case Report

We reported one patient, 45 years old female with Mooren's ulcer on the right eye and pthisis bulbi on the left eye. The diagnosis based on the clinical characteristic and negative laboratory work up for rheumatologic, hepatitis, helminthes, allergic and negative scraping and culture infectious causes of PUK. Visual acuity of the

right eye was 20/25 and there was no history of the left eye. On the right eye, we found conjunctivalization with corneal thinning and excavation on the margin of the conjunctival flap on the temporal side, its size about 5x1mm, the depth up to 2/3 the stromal cornea, from 7<sup>00</sup> to 11<sup>00</sup> clock and cicatrices on the nasal side about 4x3 mm. Unfortunately, this patient with history of conjunctival flap to protect corneal perforation. (See photos on August 06).

At this time, we suggest to perform operation for Bare Sclera (resection of conjunctiva) with Multi Layer Amniotic Membrane Transplantation (MLAMT), but she did not agree. So we only gave medications i.e. topical antibiotic, lubrication, topical and systemic anti collagenase, systemic anti glaucoma and multivitamins for epithelialization. We did not give topical corticosteroid because impending perforation and risky case (one eyed) and cyclosporine (no available preparation).

One month later (See photos on September 2006), she admitted to our hospital with worse condition, the recurrent Mooren's ulcer is deeper, extended to paracentral cornea and she was agree for the operation. We performed partial Bare Sclera and MLAMT with three days patching, under general anesthesia and informed concern was done before that. On the fifth day after the operation, the epithelialization begins to cover the thin corneal and on the ninth day epithelialization was completes (fluorescents staining was negative), but the thinner corneal surface that covered by the thin amnion membrane on the central ulcer, may impends for perforation too. The patient was discharged from hospital.

Day by day (on October), the size of the thin cornea becomes small that was covered by the thin amnion. On November – December 2006 (two months later) we did not see her again. We were very happy and thought that MLAMT can reduce progressivity of the Mooren's ulcer.

On January 2007, she came with impending perforation on the margin ulcer and the ulcer was extended to paracentral and superior corneal region, about 7x3 mm. (see photos on Januari 2007). Because of that, we suggested doing MLAMT and partial Bare Sclera immediately again, the patient agrees spontaneously. On the ninth day after the operation, epithelialization begins, and completes on the 14<sup>th</sup> day. The duration of the epithelialization for this operation need longer than previous operation, and we plan to discharge her from hospital.

But one day after that (about 2 weeks after the second surgery), we found a new rounded ulcer on the inferior cornea and we decided to perform an operation the next day. We performed total Bare Sclera and MLAMT with three days patching again. MLAMT and total Bare Sclera can make complete epithelialization on the 9<sup>th</sup> day after the operation, fast from second operation, but still have impending perforation of the cornea. (See photos on February 2007) In this time, we followed with systemic corticosteroid, but we still did not give topical cyclosporine, because no available preparation. The patient discharged of hospitalization, and visual acuity on the right eye was 20/40.

Until now, she never came again, maybe afraid to face an operation again, but we hope, that the ulcer doesn't perforate yet and the eye still on the same condition.

### **Surgery Procedure**

Conjunctival resection is useful in treating Mooren's ulcer; it can be perform under general, subconjunctival or retrobulbar anesthesia. In this case we had done under general anesthesia and povidone iodine solution for disinfectant. All of the conjunctival flap on the corneal surface will be removed and performed conjunctival excision (bare sclera) for extended 3 to 4 mm posterior to the corneascleral limbus, and parallel to the ulcer. After removed the adjacent conjunctiva, we could see the ulcer size with thin cornea and excavation, from peripheral to parasentral corneal. The affected tissues were excised and repeated the povidone iodine irrigation again.

The amniotic membrane was peeled from its holding gauze, cut with the same size of the ulcer excavation that near from the normal cornea, and with epithelial side up placed on the stromal ulcer, one by one layer (two layers) for filling-in, and two layers for cover all size of the ulcer. After that, all corneal surface and surrounding, about two millimeter of adjacent conjunctiva were patched with three layers of amniotic membrane. All of the amniotic membrane layers sutured with interrupted 8-0 silk on the conjunctiva at 8 positions. Antibiotic eye drop applied, closed and patching the eye. One day after surgery, the eye may open only 1 mm for eye drop and we continue this condition until 3 days. On the day 3<sup>rd</sup>, we will measure the apparent epithelialization and observe, when the epithelialization was completes (negative fluorescent staining). The sutures in the amniotic membrane to conjunctiva were removed about 2 week's period.

The second surgery is similar with the first surgery; we performed conjunctival resection parallel with the

new ulcer on the superior and more central cornea and performed MLAMT. The remnant Amnion membrane on the surface ulcer after the first surgery didn't removed, because the attachment was good. After surgery, we followed with three days patching. The method of the third surgery is similar too, but we performed total Bare Sclera with MLAMT and three days patching.

### Discussion

We had been reported one patient with recurrent Mooren's ulcer on the RE with VA 20/25, and pthisis on the LE without clear history, that may be the malignant type of Mooren's ulcer, because it had been grown when she was young, recurrent and responded poorly to conventional therapy. And now, unfortunately, she had conjunctival flap for prevent perforated of the thin cornea, and on the margin of the flap conjunctiva was seen the deep ulcer. The conjunctival flap can provoke progression of the ulcer, because it's increasing autoimmune response, lymphocytes, plasma cells, macrophages by vascular, it's can cause increased production of collagenolytic enzyme and lysis the healthy cornea. Chen KH et al (2003),<sup>(30)</sup> reported the relapsing Mooren's ulcer after AMT combined with conjunctival autografting. On this condition, she didn't agree to get surgery; we only gave antibiotic eye drops, lubrication/tear film substitution, and topical cycloplegic, topical and systemic anticollagenases, systemic and topical anti glaucoma and multivitamins. We didn't give topical corticosteroid; because the corneal impending perforation and high risky case, and cyclosporine preparation didn't available.

One month later (See photos on September 2006), she admitted to our hospital with worse condition, the recurrent Mooren's ulcer was deeper, extended to paracentral cornea and she was agreed for the operation. We performed partial Bare Sclera and MLAMT with three days patching, under general anesthesia. Conjunctival resection is indicated in treating peripheral corneal ulcers of autoimmune origin that is unresponsive to medical intervention, and it's useful in treating Mooren's ulcer,<sup>(1,20)</sup> and by using MLAMT the corneal wound healing become faster. On the ninth day after surgery the epithelialization was completes (fluorescents staining was negative).

For one month, she regularly control, but 2 months later, she came with impending perforation on the margin ulcer and the ulcer was extended to paracentral and superior corneal region, about 7x3 mm. (see photos on January 2007). Because of that, we suggested doing MLAMT and partial Bare Sclera immediately again. The epithelialization was completes on the 14<sup>th</sup> day. The duration of the epithelialization for this operation need longer than previous operation.

But one day after that (about 2 weeks after the second surgery), we found a new rounded ulcer on the inferior cornea and we decided to perform an operation the next day. We performed total Bare Sclera and MLAMT with three days patching again. MLAMT and total Bare Sclera can make complete epithelialization on the 9<sup>th</sup> day after the operation, fast from second operation, but still have impending perforation of the cornea. (See photos on February 2007) In this time, we followed with systemic corticosteroid, but we still did not give



topical cyclosporine, because no available preparation. The patient discharged of hospitalization, and the uncorrected visual acuity on the right eye was 20/40.

The treatment of Mooren's ulcer is difficult and frequently unsatisfactory,<sup>(2)</sup> but for this patient may be better if the surgery followed by application of topical and systemic immunosuppressant.<sup>(1)</sup> The recurrence of Mooren's ulcer still unclear, and possibility the immunology process, tissue-fixed immunoglobins and complement in both the adjacent conjunctiva and in the corneal epithelial basement membrane.<sup>(2)</sup> For this reason perhaps, is impossible to prevent the recurrence of Mooren's ulcer.

Until now, she never came, maybe afraid to face an operation again, but we hope, that the ulcer does not perforate and the eye still on the same condition.

### **Conclusions**


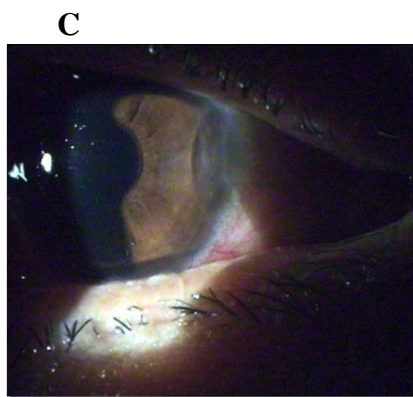
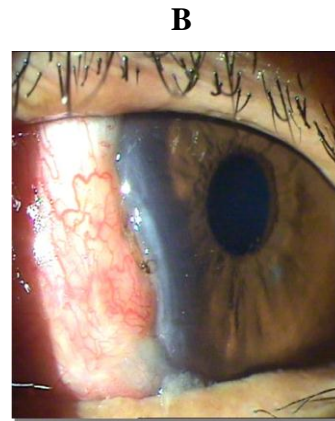
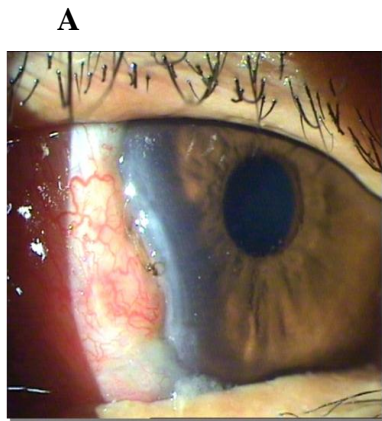
Although only one case is reported, in fact that MLAMT can reduce the time of recurrence of Mooren's ulcer, but cannot stop the progressivity. We can do MLAMT more than once and we must think and do more discussions whether MLAMT can stop the Mooren's ulcer progressivity to prevent severe visual morbidity. Total conjunctiva resection (Bare Sclera) probably gives better result than partial resection for Mooren's ulcer.

**Patient Photos**

**Identity** : Female, 44 yo.

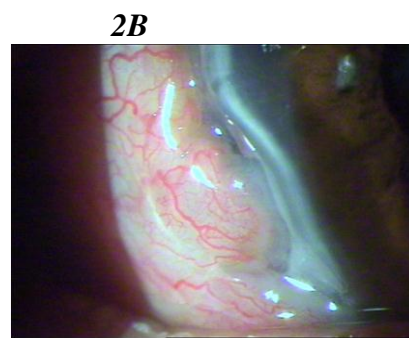
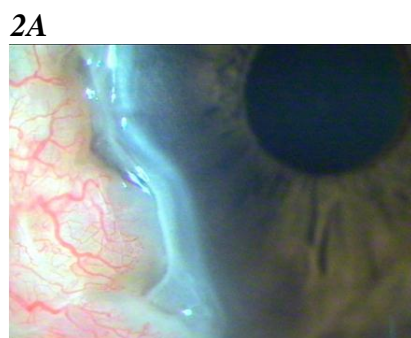
**Diagnosis** : Recurrent Mooren's Ulcer's

*On August 06*

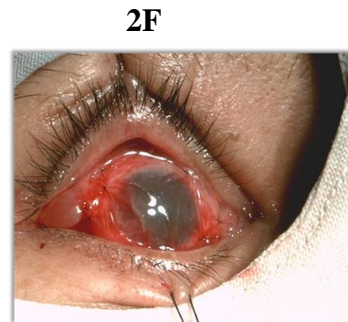
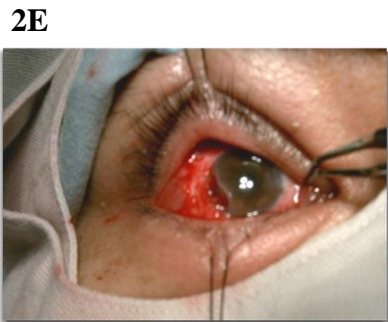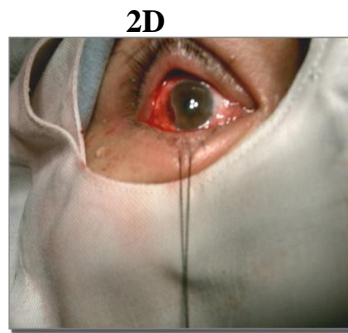
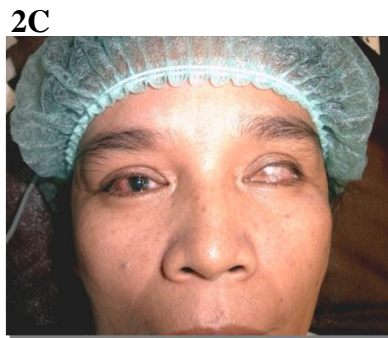


**1A: Recurrent Mooren's ulcer with conjunctival flap on the temporal side RE.**  
**1B: Excavatio near to the conj flap.** **1C: the quite ulcer on the nasal side RE.** **1D:**  
**The thinner part of the corneal.**

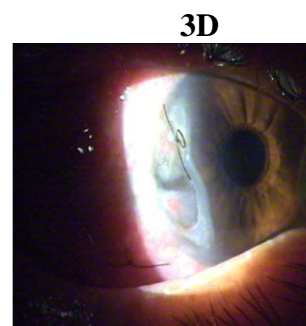
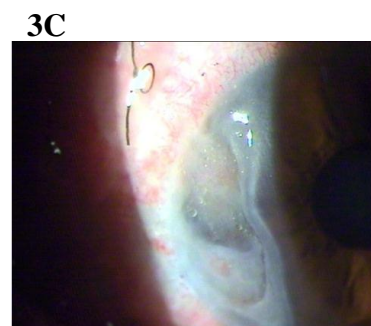
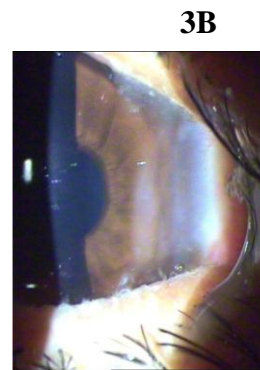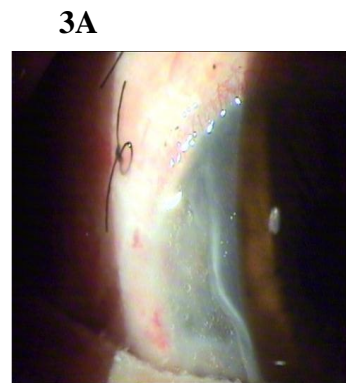
*On September 2006*



**2A-2B: The active ulcer on the margin of the conjunctiva flap with excavation**

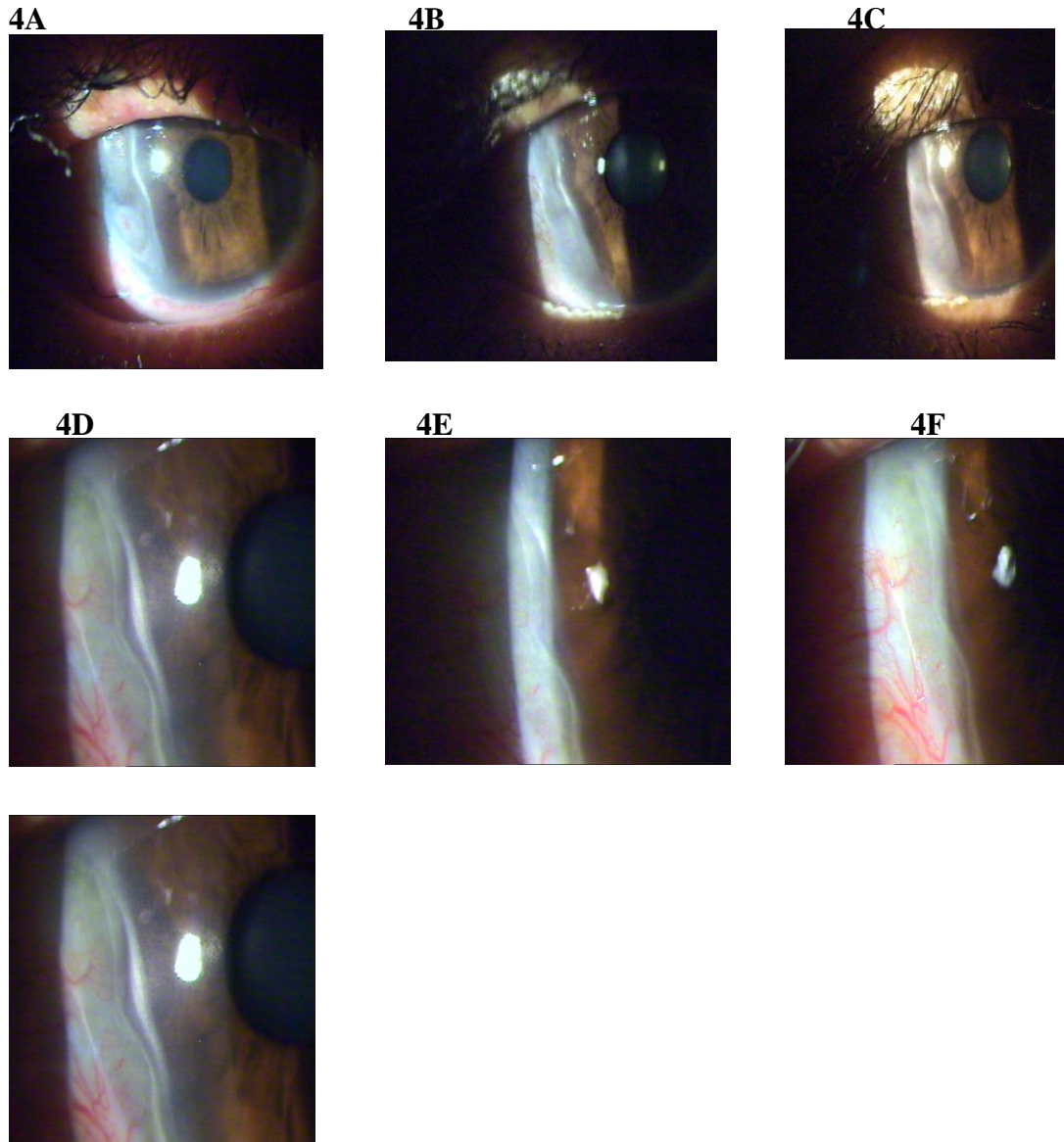


**2D-F: 1<sup>st</sup> bare sclera with MLAMT for filling, graft of ulcer, and patching all of the corneal surface and suture on the conjunctiva**

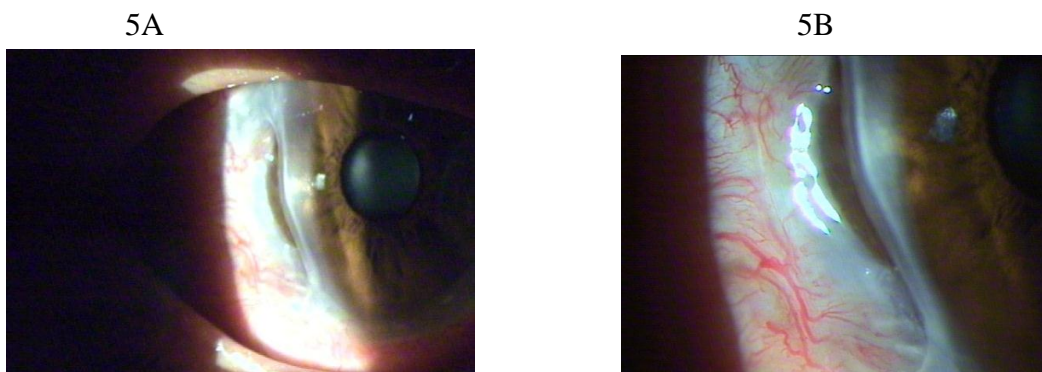


**3A - 3B: Post 1<sup>st</sup> operation MLAMT & Bare Sclera with epithelialization, the AM sutured on the conjunctiva circumferentially. 3C -3D: The thin AM layer can cover the surface of the thinner cornea on the surface of the ulcer**

*On Oktober- November 2006*




**4A-F: Complete epithelization on the surface of the ulcer.  
On January 2007**



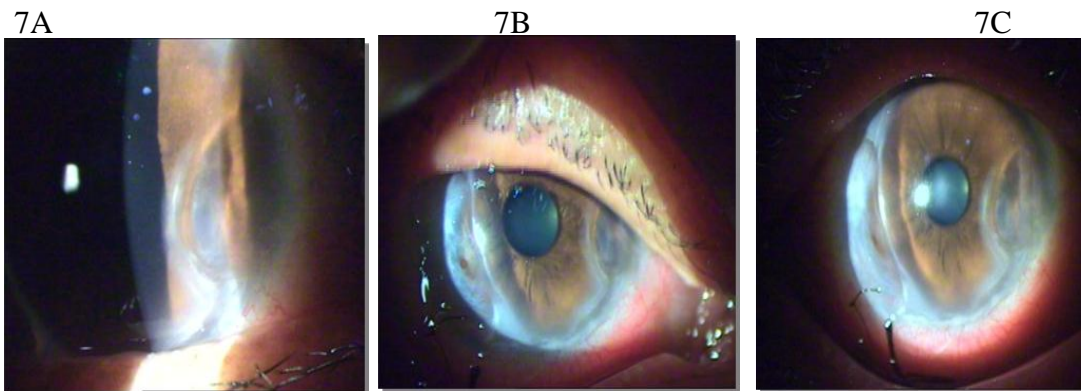
**5A - 5B: The impending perforation ulcer and extended to the paracentral and superior cornea.**

*On February 2007 (after the 2<sup>nd</sup> MLAMT and Partial Bare Sclera)*




**6A-C: MLAMT and Bare sclera can make epithelialization and covered the thinner corneal**

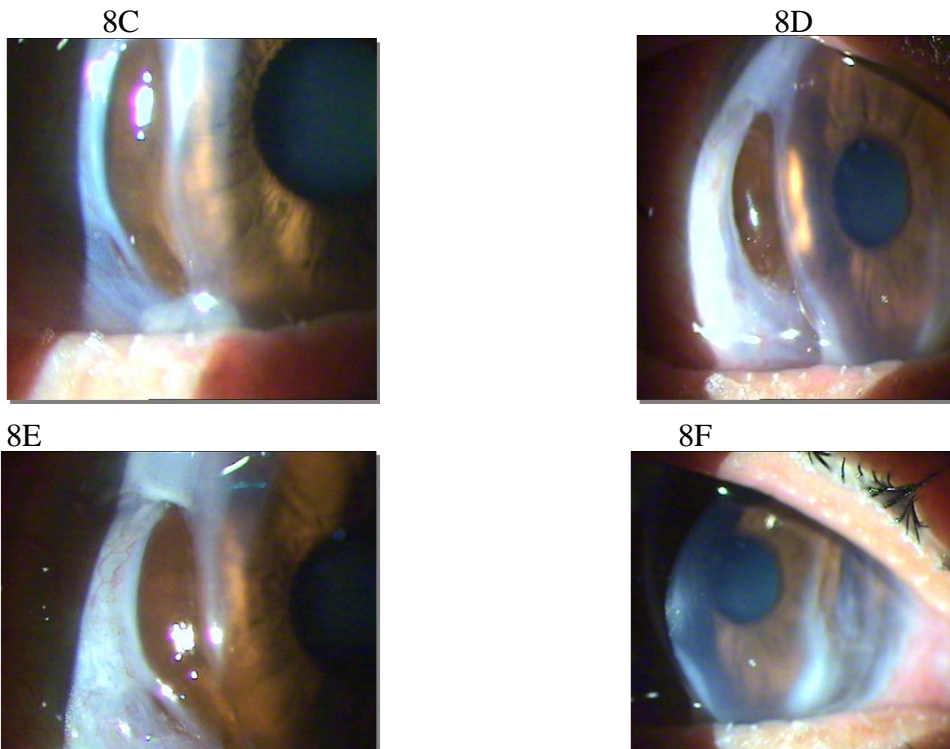
*On February 2007*



**7A-C: Ulcer was extended to the inferior cornea**

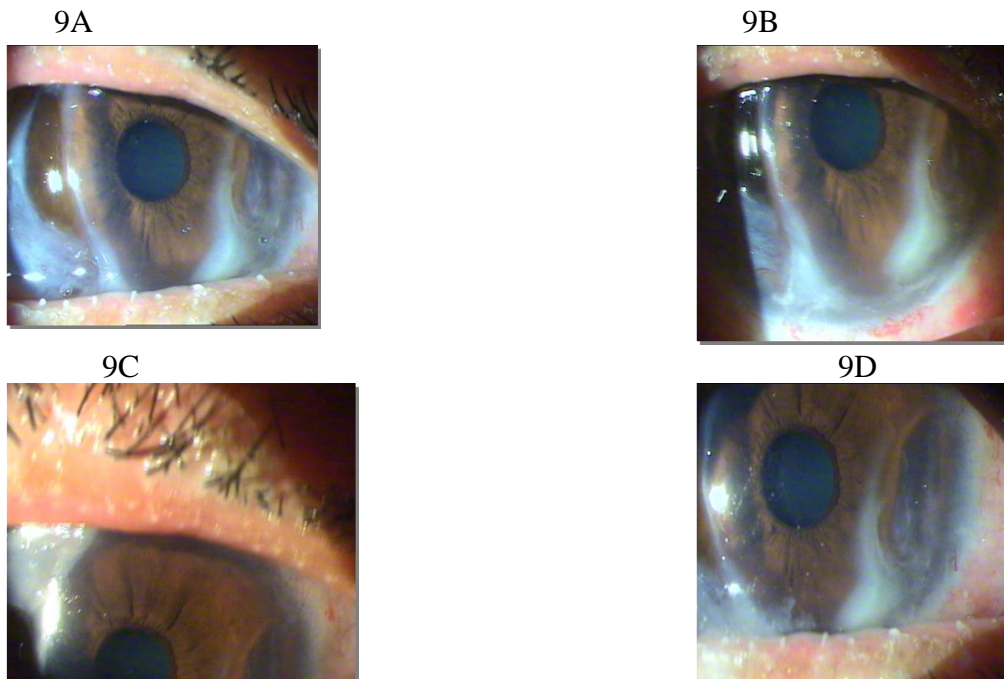
*On February 2007*





**8A-F: After 3<sup>rd</sup> MLAMT and Bare Sclera, the impending perforation cornea still present, although AM can make complete epithelialization on the 9<sup>th</sup> day.**

*On March 2007*



**9A-D: The last condition, with complete epithelialization**

## References

1. **Foster S.** Mooren's ulcer. In: *Smolin and Thoft's. The Cornea.* Scientific Foundation and Clinical Practice. Fourth Edition. Lippincott Williams & Wilkins. 2005; 551-556.
2. **Robin SB, Robin JB.** In: *Ocular Infection and Immunology.* Mosby 1996; 38: 471- 3.
3. **Zaidman GW, Mondino BJ.** In: *Cornea.* Surgery of the Cornea and Conjunctiva Second edition. Elsevier Mosby. 2005; IB; 99: 1241-44.
4. **Srinivasan M, Zegans M, Zelefsky J, Kundu A, Lietman T, et al.** Clinical characteristics of Mooren's ulcer in South India. *British Journal of Ophthalmology.* 2007; 91: 570-75.
5. **Kalogeropoulos CD, Vassiliki D, Malamou-Mitsi, Miltiadis B, Aspiotis & Konstantinos GP.** Bilateral Mooren's ulcer in six patients: diagnosis, surgery and histopathology. *International Ophthalmology.* 2004; 25: 1- 8.
6. **Gottsch JD, Liu SH, Minkovitz JB, Goodman DF et al.** Autoimmunity to a Cornea-Associated Stromal Antigen in patients with Mooren's ulcer. *Investigative Ophthalmology & Visual Science,* July 1995; 36; 8; 1541-47.
7. **Bielinska A, Bielinski P, Czerny K, Wojcierowski J.** Mooren's corneal ulcer – pathogenesis, clinical characteristics and treatment. *Annals Universitatis Mariae-Curie-Sklodowska Lublin Polonia.* 2006, LXI, N2, 182: 1006-11.
8. **Taylor CJ, Smith SI, Morgan CH, Stephenson SF et al.** HLA and Mooren's ulceration. *Br J Ophthalmol.* 2000;84: 72-75.
9. **Zelefsky J, Taylor C, Srinivasan M, Peacock S, Goodman R, et al.** HLA-DR17 and Mooren's ulcer in South India. *British Journal of Ophthalmology.* 92: 179-181.
10. **Liang C, Chen K, Hsu W.** Association of HLA type and Mooren's Ulcer in Chinese in Taiwan. *British Journal of Ophthalmology.*
11. **Wilson SE, Lee WM, Murakami C, Weng J, Moninger GA.** Mooren's Corneal Ulcers and Hepatitis C Virus Infection. *The New England J of Medicine.* July 1; 1993; 329:62.
12. **Baratz KH, Fulcher SFA, Bourne WM.** Hepatitis C – Associated Keratitis. *Archives of Ophthalmology.* April 1998; 116: 529-30.
13. **Touge C, Mihara E, Funakoshi T, Saeki Y, Hasegawa J.** A Case of Mooren's Ulcer Associated with a Pterygium. *Japan Journal Ophthalmology;* 2005, 49: 535-50.
14. **Sangwan VS, Zafirakis P, Foster CS.** Mooren's ulcer: Current concepts in management. *Indian Journal of Ophthalmology.* 1997;45;1: 7-17.
15. **Chen J, Xie H, Wang Z, Yang B, Liu Z et al.** Mooren's ulcer in China: a study of clinical characteristics and treatment. *British Journal of Ophthalmology.* Nov 2000; 84:1244-49.
16. **Erdem U, Kerimoglu H, Gundogan F, Dagli S.** Treatment of Mooren's Ulcer with Topical Administration of Interferon Alfa 2 a. *Ophthalmology* 2007; 114; 446-49.
17. **Fontana L, Parente G, Neri P, Reta M, Tassinari G.** Favourable response to infliximab in a case of bilateral refractory Mooren's ulcer.

- Royal Australian and New Zealand College of Ophthalmologists Journal*. 2007, 871-73.
18. **Hassard FA, Eiferman RA.** Surgery for Peripheral Corneal Thinning Disorders. In : *Cornea. Surgery of the Cornea and Conjunctiva*. Second edition. Elsevier Mosby, 2005; II; 135: 1645-54.
  19. **Stern G.** Peripheral Corneal Disease In: *Cornea. Surgery of the Cornea and Conjunctiva* Second edition. Elsevier Mosby. 2005; Ch23, 339 - 52.
  20. **Kim J, Tseng S.** Transplantation of Preserved Human Amniotic Membrane for Surface Reconstruction in Severely Damaged Rabbit Corneas. *Cornea*: 1995; 14 (5); 473 - 84.
  21. **John Thomas.** Human Amniotic Membrane Transplantation: Past, Present, and Future. *Ophthalmology Clinics of North America* 2003; 16: 43-65.
  22. **Sukmawati G, Sastradiwirya I.** Result of the Amniotic Transplantation in Ophthalmology. Presented in Congress Of Indonesian Ophthalmology Association (IOA). Medan, 2006.
  23. **Lee SH, Tseng SCG.** Amniotic Membrane Transplantation for Persistent Epithelial Defects with Ulceration. *American Journal of Ophthalmology* 1997; 123: 303 - 12.
  24. **Kruse FE, Jousen AM, Rohrschneider K, You L, Sinn B,** et al. Cryopreserved human Amniotic Membrane for Ocular Surface Reconstruction. *Graefe's Arch Clin Exp Ophthalmol*. 2000; 238: 68-75
  25. **Hanada K, Shimazaki J, Shimmura S, Tsubota K.** Multilayered Amniotic Membrane Transplantation for Severe Ulceration of the Cornea and Sclera. *Am J Ophthalmol*. 2001; 131: 324 - 31.
  26. **Prabhasawat P, Tesavibul N, Komolsuradej W.** Single and Multilayer Amniotic Membrane Transplantation for Persistent Corneal Epithelial Defect With and Without Stromal Thinning and Perforation. *Br. J. Ophthalmol*. 2001; 85: 1455 - 63.
  27. **Sukmawati G, Sastradiwirya I.** Multilayered Amniotic Membran Transplantation (MLAMT) and Tarsorrhaphy for the Treatment of Corneal Epithelial Defects and Ulcers. In; Use of Freeze Dried Irradiated Amnion in Ophthalmologic Practice. *Radiation in Tissue Banking*. World Scientific Publishing Co.Pte.Ltd. 2007; 360 - 62.
  28. **Solomon A, Meller D, Prabhasawat P, John T, Espana EM,** et al. Amniotic Membrane Grafts for Nontraumatic Corneal Perforations, Descemetocelles, and Deep Ulcers. *Ophthalmology* 2002; 109; 4: 694 -703.
  29. Multi-Media Distance Learning Package on Tissue Banking, Regional Co-operative Agreement International Atomic Energy Agency. Vienna August 1997.
  30. **Chen KH, Hsu WM, Liang CK.** Relapsing Mooren's ulcer. After Amniotic Membrane Transplantation Combine with Conjunctival Grafting. *Am J Ophthalmology*. 2004; 111: 792-95.