

Response Evaluation of Patients Undergoing Transarterial Chemoembolization (TACE) for Hepatocellular Carcinoma with Respect to Tumour Size, Number of Lesion, and Alpha-Fetoprotein (AFP) Level

Adaninggar PN, Ulfa Kholili, Ummi Maimunah, Poernomo B Setiawan, Iswan A Nusi, Herry Purbayu, Titong Sugihartono, Budi Widodo, Husin Thamrin, Amie Vidyani

Division of Gastroentero-hepatology, Department of Internal Medicine, Faculty of Medicine, Airlangga University/Dr. Soetomo General Hospital, Surabaya

Corresponding author:

Ummi Maimunah. Division of Gastroentero-hepatology, Department of Internal Medicine, Dr. Soetomo Hospital. Jl. Prof dr Moestopo NO.6-8 Surabaya Indonesia. Phone/facsimile: +62-31-5023865. E-mail:umima@gmail.com

ABSTRACT

Background: Transarterial chemoembolization (TACE) is widely used as a palliative treatment for unresectable hepatocellular carcinoma (HCC). TACE is also used as bridging therapy before liver transplantation to avoid tumour progression and considered for downstaging to fulfill tumour resection or liver transplantation criterias. This study aimed to evaluate response of TACE in unresectable HCC according to changing of tumour size, number of lesion, and AFP level.

Method: Retrospectively, we evaluate 69 HCC patients who underwent TACE in Dr. Soetomo General Hospital in January 2012-June 2015, including their age, sex, aetiologies, and Barcelona Clinic Liver Cancer/BCLC staging. Laboratory examinations such as complete blood count (hemoglobin/Hb, leucocyte, thrombocyte), liver function test (aspartate aminotransferase/AST, alanine aminotransferase/ALT, bilirubin, albumin, international normalized ratio/INR), alpha-fetoprotein/AFP level, and abdominal CT-scan were performed before and 1 month post-TACE. Data was analysed using paired t-test.

Results: 69 patients with mean age of 51.81 (SD 12.8) years old, predominantly 76.8% males, the most common aetiology was hepatitis B (68.1%), BCLC B (92.8%), with stable disease (64.3%), none achieved complete response, had tumour size > 5 cm (97.1%), had single tumour (69.6%), and had AFP level >1000 ng/mL (55.7%). There was a significant increase in tumour size and number of lesions in 1 month post-TACE that were approximately 1.76 cm and 2.33, respectively, and there was no significant difference between AFP level before and 1 month post TACE.

Conclusion: In 1 month post TACE evaluation, there was no significant decrease of tumour size and number of lesion, and also there was no significant alteration in AFP level. TACE might be performed repeatedly with shorter evaluation interval than 1 month to achieve better response.

Keywords: hepatocellular carcinoma, transarterial chemoembolization, alpha fetoprotein, tumour size, number of lesion.

ABSTRAK

Latar belakang: Transarterial chemoembolization (TACE) telah digunakan secara luas sebagai pengobatan paliatif untuk karsinoma hepatoselular yang telah dioperasi. TACE juga digunakan sebagai terapi awal sebelum

transplantasi hati untuk menghindari perkembangan tumor dan dianggap sebagai fase awal untuk memenuhi reseksi tumor atau memenuhi kriteria transplantasi hati. Penelitian ini bertujuan untuk mengevaluasi respon TACE pada karsinoma hepatoselular yang telah dioperasi terkait perubahan ukuran tumor, jumlah lesi, dan level alpha-fetoprotein.

Metode: Secara retrospektif, penelitian ini mengevaluasi 69 pasien karsinoma hepatoselular yang menjalani TACE di Rumah Sakit Umum Dr. Soetomo pada Januari 2012-Juni 2015, termasuk umur, jenis kelamin, etiologi, dan stase Barcelona Clinic Liver Cancer (BCLC). Pemeriksaan laboratorium seperti perhitungan darah lengkap (hemoglobin/Hb, leukosit, trombosit), tes fungsi hati (aspartate aminotransferase/AST, alanine aminotransferase/ALT, bilirubin, albumin, international normalized ratio/INR), level alpha-fetoprotein, dan CT-scan abdominal dilakukan 1 bulan sebelum dan setelah TACE. Data dianalisis menggunakan uji t berpasangan.

Hasil: Sebanyak 69 pasien dengan rerata umur 51.81 ± 12.8 tahun, dominan pada laki-laki sebesar 76.8%, etiologi yang paling sering adalah hepatitis B sebesar 68.1%, 92.8% merupakan BCLC B, 64.3% merupakan penyakit yang stabil, tidak satupun menerima respon lengkap, 97.1% memiliki ukuran tumor > 5 cm, 69.6% memiliki tumor tunggal, dan 55.7% memiliki kadar AFP > 1000 ng/mL. Ada penambahan signifikan pada ukuran tumor dan jumlah lesi pada satu bulan setelah TACE secara berturut-turut 1.76 dan 2.33 cm, dan tidak ada perbedaan signifikan antara kadar AFP satu bulan sebelum dan setelah TACE.

Simpulan: Dalam satu bulan setelah evaluasi TACE, ada penambahan signifikan ukuran tumor dan jumlah lesi, namun tidak ada perubahan signifikan pada kadar AFP. TACE mungkin dilakukan secara berulang dengan jarak evaluasi yang lebih singkat dari 1 bulan untuk mendapatkan respon yang lebih baik.

Kata kunci: karsinoma hepatoselular, transarterial chemoembolization (TACE), alpha-fetoprotein, ukuran tumor, jumlah lesi.

INTRODUCTION

Hepatocellular carcinoma (HCC) is the fifth leading cause of cancer and third leading cause of death among cancer worldwide, with incidence about 14.7% and 4.9% per 100.000 patients, respectively.^{1,2} Approximately 70-90% HCC patients suffered from chronic liver disease or cirrhosis manifestations prior to HCC, with hepatitis B infection, hepatitis C infection, non-alcoholic and alcoholic fatty liver disease as the main causes.^{2,3} Treatment of choice in HCC depends on tumour size, number of lesions, patient's performance status, and liver functional reserve, that were presented in BCLC staging.^{4,5} During initial diagnosis, only 30% patients fulfilled the criteria for curative treatment, such as liver transplant, ablation therapy, and surgical resection, whereas others were not suitable for curative therapy so they had to underwent palliative treatment, such as transarterial chemoembolization (TACE) and Sorafenib.^{1,6}

TACE is treatment strategy that is recommended for HCC patients with intermediate stage, where there is large uninodular and multinodular HCC with preserved liver function (Child A/B), and without vascular invasion or extrahepatic dissemination.^{5,7} Rationalization of TACE in HCC is based on 2 vascularization. First, portal vein that gives nutrition to liver parenchyma, and second, hepatic artery that gives nutrition to the tumour with various stage of

hypervascularization. Administration of transarterial cytotoxic drugs combined with arterial embolization will cause local cytotoxic effect and tumour ischemia.^{1,8} Response to TACE could be evaluated through the decreasing of tumour marker level, amount of intratumour necrotic area, and shrinking of tumour size and number of tumour lesions. These responses were associated with better survival.^{5,9}

Although TACE has direct anti tumour effect, it can also cause complications such as increasing of transaminase serum level and negative changes in liver function, that probably caused by ischemic injury in liver and also tumour necrosis.^{10,11,12} Alpha-fetoprotein (AFP) is protein from fetal component that is produced by fetal liver and gestational sac during embryo period. Adult AFP normal level is < 20 ng/mL. High AFP serum level was found in 60-70% HCC patients, but was still normal in 15-30% patients. False positive results are usually found in many conditions such as pregnancy, liver cirrhosis, lung cancer, biliary cancer, gastric cancer, pancreatic cancer, testicular cancer, and drugs/alcohol abuse.^{5,13-18} In this study, we evaluated the influence of TACE to tumour size, number of lesions, and AFP serum levels.

METHOD

We compiled secondary data from medical records in interventional radiology department and

gastrohepatology outpatient clinic in Dr. Soetomo General Hospital, including all patients above 18 years old, who were diagnosed with HCC stage BCLC B/C, and underwent first TACE, during January 2012 to June 2015 period. Diagnosis of HCC was based on European Association for The Study of The Liver (EASL) criteria, where there was classical lesion in 2 radiology imaging (CT-Scan/MRI/USG) or 1 radiology imaging, with elevation of AFP serum level > 400 ng/mL or histopathology finding showing HCC from liver biopsy. Exclusion criteria were: (1) Presence of liver decompensation signs and symptoms (ascites, active gastrointestinal bleeding, encephalopathy, liver failure); (2) Had been underwent resection therapy, ablation, transplant, or TACE; (3) Presence of severe illness Karnofsky score < 50); (4) Presence of history of malignancy before HCC or HCC that has metastasized; (5) Presence of history of coronary heart disease, heart failure, or chronic renal failure. We found 69 patients who fulfilled inclusion and exclusion criteria.

Data that were collected include age, sex, HCC aetiologies (hepatitis B and hepatitis C viral marker), BCLC staging, and chief complaint. Data of hemoglobin, leucocyte, trombocyte, AST, ALT, bilirubin, albumin, AFP, tumour size, and number of lesions that were collected were initial data (before first session of TACE) and data 1 month after the first session of TACE session, when patients came to the gastro-hepatology outpatient clinic. CT scan abdomen for evaluation was performed 1 month after the first session of TACE. Tumour size was defined as largest tumour diameter and if there was multiple tumour, tumour size was defined as sum of largest tumour diameter from all lesions.

TACE procedure was performed according to the standardised protocol and was performed by experienced interventionist in interventional radiology unit in Dr. Soetomo General Hospital Surabaya. TACE was performed percutaneously using Seldinger technique. After catheter 5 Fr was inserted into femoral artery, angiography was done to evaluate blood flow of left and right hepatica arteries. After that, selective catheterization was performed to arteries that gave blood supply to the tumour. TACE was performed with combination suspension of chemotherapy drugs, that consisted of Doxorubicin 10-40 mg with or without carboplatin 450 mg mixed in 10 mL lipiodol, followed by embolization using gel foam. The procedure was complete if from contrast test result, there was no arterial blood flow left to the tumour

(devascularization). Amount of chemotherapy drugs and lipiodol was given according to the number, location, and diameter of lesions.

Data were collected and analyzed using SPSS software version 20. Qualitative data was presented in number and percentage. Quantitative data was presented in mean and standard deviation ($X \pm SD$). Comparison quantitative data before and 1 month after first session of TACE, were analysed using paired t-test. P value of < 0.05 was considered as significant.

RESULTS

There were 69 patients who fulfilled inclusion and exclusion criterias in this study, consisting of 53 male patients (76.8%) and 16 female patients (23.2%), with mean age of 51.81 (SD 12.8) years old; with aetiology of HCC: hepatitis B in 47 patients (68.1%), hepatitis C in 9 patients (13%), and other causes (other than hepatitis B and C infection) in 13 patients (18.8%); 2 patients (2.9%) with HCC BCLC A, 64 patients (92.8%) with BCLC B, and 3 patients (4.3%) with BCLC C; 14 patients (22.9%) with AFP level < 200 ng/mL, 13 patients (21.3%) with AFP level 200-1000 ng/mL, and 34 patients (55.7%) with AFP level > 1000 ng/mL. During initial diagnosis, 67 patients (97.1%) had tumour size of > 5 cm, and 2 patients (2.9%) had tumour size of 2-5 cm, with mean of 12.14 (SD 4.3 cm); 48 patients (69.6%) had solitary tumour and 21 patients (30.4%) had multiple tumour, with mean number of lesions 1.33 (SD 0.56) Patients' characteristic were presented in Table 1.

From laboratory findings, we found mean albumin level (pre-TACE) of 3.25 (SD 0.41) g/dL and 1 month post TACE 3.26 (SD 0.41)g/dL; total bilirubin level (pre-TACE) 1.44 (SD 0.56) mg/dL and 1 month post-TACE 1.78 (SD 2.54) mg/dL; AST (pre-TACE) 136.41 (SD 117.84) U/L and 1 month post-TACE 136.03 (SD 121.53) U/L; ALT (pre-TACE) 74.19 (SD 76.14) U/L and 1 month post-TACE 63.36 (SD 41.26) U/L; hemoglobin (pre-TACE) 12.94 (SD 1.86) g/L and 1 month post-TACE 12.72 (SD 1.66) g/L; leucocyte (pre-TACE) 6804.77 (SD 2661.9)/uL and 1 month post-TACE 6296.65 (SD 2210.93)/uL; thrombocyte (pre-TACE) 195258.41 (SD 99525.02)/uL and 1 month post-TACE 178363.77 (SD 90445.63)/uL. Data was shown in Table 2.

In this study, evaluation of TACE included tumour size, number of tumour lesions, and AFP level before and 1 month post TACE. Statistical analysis showed significant correlation between tumour size, number of

Table 1. Demographic and tumour characteristics of patients who underwent transarterial chemoembolization (TACE)

Variables (n = 69)	n (%)	mean (SD)
Demography		
Age (year old)		51.81 (12.8)
Gender		
Male	53/76.8	
Female	16/23.2	
Liver function		
ALT (IU/L)		
≤ 40	20/29	74.19 (76.1)
> 40	49/71	
AST (IU/L)		
≤ 40	5/7.2	136.41 (117.8)
> 40	64/92.8	
Albumin		
< 3	20/29	3.25 (0.41)
3-3.5	28/40.6	
> 3.5	21/30.4	
Bilirubin total (mg/dL)		
< 2	48/69.6	1.44 (0.56)
2-2.5	21/30.4	
Aetiologies		
Hepatitis B	47/68.1	
Hepatitis C	9/13	
Others	13/18.8	
Tumour marker		
AFP (ng/mL)		
< 200	14/22.9	
200-1000	13/21.3	
> 1000	34/55.7	
Tumour characteristic		
Tumour size (cm)		
2-5	2/2.9	12.14 (4.3)
> 5	67/97.1	
Number of lesions		
Solitaire	48/69.6	
Multiple	21/30.4	
Staging BCLC		
BCLC A	2/2.9	
BCLC B	64/92.8	
BCLC C	3/4.3	
Main Complaints		
Abdominal pain	20/29	
Weight loss	4/5.8	
Abdominal lump	25/36.2	
Abdominal discomfort/nausea/vomit	16/23.2	
Others (icterus/haematemesis-melena/Oedema, etc)	4/5.8	
Chemotherapy Drug		
Doxorubicin	36/52.2	
Doxorubicin-Carboplatin	33/47.8	

ALT: alanine aminotransferase, AST: aspartate aminotransferase, AFP: alpha-fetoprotein; BCLC: Barcelona clinic liver cancer

Table 2. Laboratory findings pre-TACE and 1 month post-TACE

Variables	Pre-TACE mean (SD)	1 month post TACE mean (SD)
AST	136.41 (117.84)	136.03 (121.53)
ALT	74.19 (76.14)	63.36 (41.26)
Hemoglobin	12.94 (1.86)	12.72 (1.66)
Leucocyte	6804.77 (2661.9)	6296.65 (2210.93)
Thrombocyte	195258.41 (99525.02)	178363.77 (90445.63)
INR	1.26 (0.86)	1.27 (1.2)
Albumin	3.25 (0.41)	3.26 (0.41)
Total Bilirubin	1.44 (0.56)	1.78 (2.54)

AST: aspartate aminotransferase; ALT: alanine aminotransferase; INR: International normalized ratio; TACE: transarterial chemoembolization

tumour lesions, and AFP level before and 1 month post TACE ($p < 0.000$). There was a significant increase of tumour size in 1 month post-TACE ($p = 0.008$) with mean tumour size pre-TACE of 12.17 ± 4.43 cm and 1 month post-TACE of 13.94 ± 5.94 cm, with mean increase of 1.76 cm. There was also a significant increase of number of lesions significantly in 1 month post-TACE ($p = 0.012$) with mean number of lesions pre-TACE 1.35 ± 0.58 and 1 month post-TACE 1.58 ± 0.72 , with mean increase of 2.33. Number of patients with AFP level >1000 ng/mL pre-TACE was 38 patients and decreased to 29 patients in 1 month post-TACE, patients with AFP level 200-1000 ng/mL pre-TACE was 13 patients and increased to 24 patients in 1 month post-TACE, and patients with AFP level < 200 ng/mL was 13 patients decreased to 12 patients. However, these fluctuations were not significant ($p > 0.05$). Graph was shown in Figure 1.

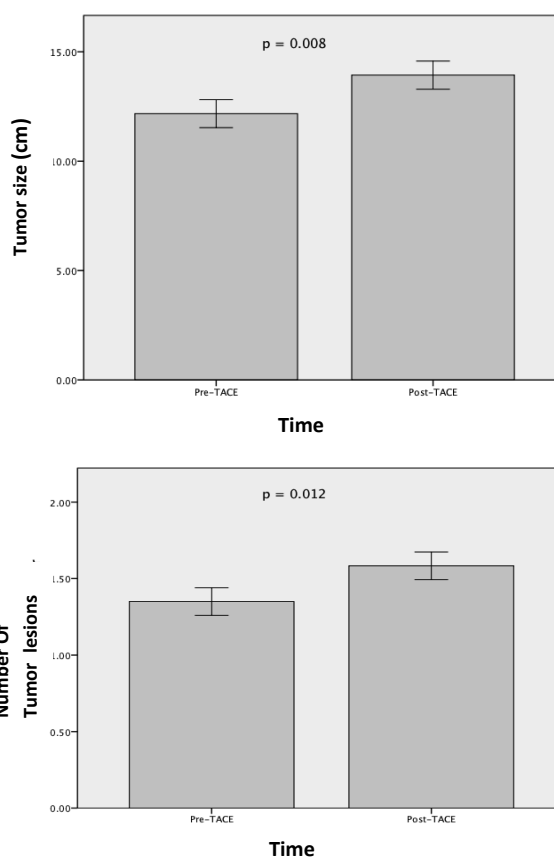


Figure 1. TACE effect to tumour size and number of tumour lesions

DISCUSSION

Hepatocellular carcinoma (HCC) is the fifth leading cancer and third leading cause of death among cancer,

worldwide, with high mortality rates.^{1,2} TACE is the main palliative treatment of choice for HCC patients who did not fulfil criteria for surgery.^{5,7} In one meta-analysis that included 18 randomised-controlled clinical trial, Camma et al, showed better survival in TACE group compared to the control group.¹⁹

Chronic hepatitis B and hepatitis C infection are major risk factors of HCC, besides other causes, such as metabolic syndrome (obesity, diabetes mellitus), alcohol, toxin, drugs, and autoimmune.²⁰ In this study, the most common risk factor of HCC was hepatitis B infection. This was consistent with prior studies, where hepatitis B-associated HCC was mostly found in Asian, Africa, and Latin America Countries, whereas hepatitis C-associated HCC was mostly found in countries in Europe, North America, Japan, Mongolian, and Egypt.^{21,22,23,24}

Male had higher risk for HCC, with ratio to female about 2-4:1. In this study, male HCC patients were more than female with ratio of about 3:1. Genetic susceptibility factors and hormonal factors, as well as smoking and alcohol drinking habits were believed as strong risk factors for HCC in male.^{15,20,25-30}

Elevation of AFP level could reflect abnormal hepatocyte regeneration, so AFP was long used as marker to detect HCC. High AFP serum level was found in 60-70% HCC patients, but was still at normal level in 15-30% patients.^{5,13} For diagnosis, AFP level 20 ng/mL showed high sensitivity and low specificity, but in level 200 ng/mL, its sensitivity decreased to only 20% with high specificity.^{31,32} In this study, we found 14 patients (22.9%) with AFP level < 200 ng/mL, 13 patients (21.3%) with AFP level 200-1000 ng/mL, and 34 patients (55.7%) with AFP level >1000 ng/mL. We used upper cut-off of 1000 because AFP level data in this study could not detect absolute amount higher than 1000 ng/mL. Survival is the main goal of TACE in HCC, but evaluation of tumour local response is also important to evaluate the effectiveness of TACE technique. Tumour local response evaluation with CT-Scan or MRI could be done in 1-3 months after TACE procedure.¹ In this study, we did not evaluate survival, but only tumour local response that we observed from tumour size, number of tumour lesions, and tumour marker level in 1 month post TACE.^{33,34,35} Tumour local response was also influenced by different TACE technique or chemotherapy drugs and embolization, but were not evaluated in this study.¹

Large tumour size is a risk factor for tumour recurrence, although in this study, it was found that early tumour recurrence could also happen in small tumour, in resectable HCC.³⁶ In this study, there was

a significant increase of tumour size and number of tumour lesion in 1 month post TACE, with mean of about 1.76 cm and 2.33, respectively. These results were consistent with prior studies, where it was so rare to achieve complete response after TACE (0-4%), even tumour often adapted to the new angiogenesis. Therefore, in the next evaluation, usually increased size or number of tumour lesions was found.³⁵ In contrast, other study found significant decrease of tumour size and number of tumour lesions post TACE, but in this study, evaluation was performed 1 week post TACE, where neoangiogenesis process had not increase tumour size or number of tumour lesions significantly compared to evaluation in 1 month post TACE.³⁷

Decrease of > 50% AFP level from initial level after locoregional therapy such as TACE and radioembolization, was reported to be useful in evaluate tumour response and survival, also in evaluating progressivity of lesion that could be seen through radiology examination.^{18,33} AFP level also had been studied as prognostic predictor of resectable HCC.^{2,17} In this study, patients with AFP level >1000 ng/mL.

In this study, patients whose AFP level were > 1000 ng/mL pre-TACE were 34 patients, and this number decreased to 24 patients in 1 month post-TACE. Patients whose AFP level were 200-1000 ng/mL pre-TACE were 13 and this increased to 24 patients in 1 month post-TACE, while 13 patients with AFP level < 200 ng/mL decreased to 12 patients in 1 month post-TACE. However, these fluctuations in patients number were not significantly different. This study could not reflect all population because only performed in one health center, with small sample size, short follow-up time (only 1 month) so it could not asses survival. The future studies with longer time of follow up, bigger sample size, and evaluation of survival are needed to achieve better results which can be applied in bigger population, especially in Indonesia.

CONCLUSION

From this study, it could be concluded that tumour size and number of tumour lesion were significantly increased in 1 month post TACE, whereas AFP level before and 1 month post TACE were not significantly different. Therefore, the decision to perform TACE as choice of HCC treatment was individual and benefit-to-risk ratio must be considered.

REFERENCES

1. Huppert, Peter. Current concepts in transarterial chemoembolization of hepatocellular carcinoma. *Abdominal Imaging* 2011;36:677-83.
2. Toro A, Ardiri A, Mannino M, Arcerito MC, Mannino G, Palermo F, et al. Effect of pre- and post-treatment alpha fetoprotein levels and tumor size on survival of patients with hepatocellular carcinoma treated by resection, transarterial chemoembolization or radiofrequency ablation: a retrospective study. *BMC Surgery* 2014;14:40-7.
3. Sanyal AJ, Yoon SK, Lencioni R. The etiology of hepatocellular carcinoma and consequences for treatment. *The Oncologist* 2010;15:14-22.
4. Raza A, Sood GK. Hepatocellular carcinoma review: current treatment and evidence-based medicine. *World J Gastroenterol* 2014;20:4115-27.
5. Bruix J, Sherman M. AASLD practice guideline: management of hepatocellular carcinoma: an update. *Hepatology* 2011;53:1020-57.
6. Kocyigit A, Dicle O, Goktay Y, Astarcioglu I. The effect of using different embolic agents on survival in transarterial chemoembolization of hepatocellular carcinoma. *Interventional Radiology* 2014;20:323-9.
7. Golfieri R, Cappelli A, Cucchetti A, Piscaglia F, Carpenzano M, Peri E, et al. Efficacy of selective transarterial chemoembolization in inducing tumor necrosis in small (< 5 cm) hepatocellular carcinomas. *American Association for The Study of Liver Diseases* 2011;5:1580-9.
8. Elbaz T, Kassas ME, Esmat G. Management of hepatocellular carcinoma: updated review. *Journal of Cancer Therapy* 2013;4:536-45.
9. Sato Y, Watanabe H, Sone M, Onaya H, Sakamoto N, Osuga K, et al. Tumor response evaluation criteria for HCC treated using TACE: RECIST and mRECIST (modified RECIST). *Upsala Journal of Medical Science* 2013;118:16-22.
10. Chan AO, Yuen MF, Hui CK. A prospective study regard complications of transcatheter intraarterial lipiodol chemoembolization in patients with hepatocellular carcinoma. *Cancer* 2002;94:1747-52.
11. Sun Z, Li G, Ai X. Hepatic and biliary damage after transarterial chemoembolization for malignant hepatic tumors: incidence, diagnosis, treatment, outcome, and mechanism. *Crit Oncol Hematol* 2011;79:164-74.
12. Wigmore SJ, Redhead DN, Thomson BN. Postchemoembolization syndrome-tumor necrosis or hepatocyte injury? *Br J Cancer* 2003;89:1423-7.
13. Arrieta O, Cacho B, Morales ED, Ruelas VA, Flores ED, Hernandez PN. The progressive elevation of alpha fetoprotein for the diagnosis of hepatocellular carcinoma in patients with liver cirrhosis. *BMC Cancer* 2007;8:28-35.
14. Van DV, Cappel WH, Langers AM, Van HB. Two patients with extremely elevated tumor markers: where is the malignancy? *Gastroenterol Res Pract* 2011;1:123743.
15. Abbasi A, Bhutto AR, Butt N, Munir SM. Correlation of serum alpha fetoprotein and tumor size in hepatocellular carcinoma. *JPMA* 2012;62:33-6.
16. Sharieff S, Burney IA, Salani A, Siddiqui T. Lack of correlation between alpha fetoprotein and tumor size in hepatocellular carcinoma. *JPMA* 2001;55:24-8.
17. Ma WJ, Wang HY, Teng LS. Correlation analysis of preoperative serum alpha-fetoprotein (AFP) level and prognosis of hepatocellular carcinoma (HCC) after hepatectomy. *World J Surg Oncol* 2013;11:212-8.
18. Riaz A, Ryu RK, Kulik LM, Mulcahy MF, Lewandowski RJ, Minocha J, et al. Alpha-fetoprotein response after locoregional therapy for hepatocellular carcinoma: oncologic marker of radiologic response, progression, and survival. *JCO* 2009;27:5734-42.
19. Camma C, Schepsis F, Orlando A, Albanese M, Shahied L, Trevisani F, et al. Transarterial chemoembolization for unresectable hepatocellular carcinoma: meta-analysis of randomized controlled trials. *Radiology* 2002;224:47-54.
20. Gao J, Xie L, Yang WS, Zhang W, Gao S, Wang J, et al. Risk factors of hepatocellular carcinoma-current status and perspectives. *Asian Pasific J Cancer Prev*, 2012;13:743-52.
21. Raza SA, Clifford GM, Franceschi S. Worldwide variation in the relative importance of hepatitis B and hepatitis C viruses in hepatocellular carcinoma: a systematic review. *Br J Cancer* 2007;96:1127-34.
22. Sarin SK, Thakur V, Guptan RC, Saigal S, Malhotra V, Thyagarajan SP. Profile of hepatocellular carcinoma in India: an insight into the possible etiologic associations. *J Gastroenterol Hepatol* 2001;16:666-73.
23. Takayasu K, Arai S, Ikai I, Omata M, Okita K, Ichida T, et al. Prospective cohort study of transarterial chemoembolization for unresectable hepatocellular carcinoma in 8510 patients. *Gastroenterology* 2006;131:461-9.
24. Wang Y, Yanping S. Unresectable hepatocellular carcinoma treated with transarterial chemoembolization: clinical data from a single teaching hospital. *Int J Clin Exp Med* 2013;6:367-71.
25. Keng VW, Largaespada DA, Villanueva A. Why men are at higher risk for hepatocellular carcinoma? *J Cell* 2012;148:72-83.
26. Sacco R, Bertini M, Petrucci P. Clinical impact of selective transarterial chemoembolization on hepatocellular carcinoma: a cohort study. *World J Gastroenterol* 2009;15:1843-8.
27. Kothary N, Weintraub JL, Susman J. Transarterial chemoembolization for primary hepatocellular carcinoma in patients at high risk. *J Vasc Interv Radiol* 2007;18:1517-26.
28. Kohla MA, Zeid MI, Al WM, Taha M, Gish RG. Predictors of hepatic decompensation after TACE for hepatocellular carcinoma. *BMJ Open Gastroenterology* 2015;2:e000032.
29. Herber SC, Otto G, Schneider J. Transarterial chemoembolization in patients not eligible for liver transplantation: single-center results. *Am J Roentgenol* 2008;190:1035-42.
30. Munk PL, Ho SG, Legiehn GM, Lee MJ, Morris DC. Chemoembolization of hepatic tumors: changes in platelet count, hemoglobin, and creatinine postembolization. *J HK Coll Radiol* 2002;5:14-8.
31. Lai Q, Melandro F, Pinheiro RS, Donfrancesco A, Fadel BA, Sandri GB, et al. Alpha-fetoprotein and novel tumor biomarkers as predictors of hepatocellular carcinoma recurrence after surgery: a brilliant star rises again. *Hindawi Journal* 2012;3:89-97.
32. Li P, Wang SS, Liu H, Li N, McNutt MA, Li G, et al. Elevated serum alpha fetoprotein levels promote pathological progression of hepatocellular carcinoma. *World J Gastroenterol* 2011;17:4563-71.
33. Ikai I, Arai S, Kojiro M, Ichida T, Makuuchi M, Matsuyama Y, et al. Reevaluation of prognostic factors for survival after hati resection in patients with hepatocellular carcinoma in a Japanese nationwide survey. *Cancer* 2004;101:796-802.

34. Eisenhauer EA, Therasse P, Bogaerts J, Schwartz LH, Sargent D, Ford R, et al. New response evaluation criteria in solid tumor: revised RECIST guideline (version 1.1). *J Cancer* 2009;45:228-47.
35. Paul SB, Gamanagatti S, Sreenivas V, Chandrashekhara SH, Mukund A, Gulati MS. Transarterial chemoembolization in patients with unresectable hepatocellular carcinoma: experience from a tertiary care centre in India. *Indian J Radiol Imaging* 2011;21:113-20.
36. Poon TT, Fan ST, Wong J. Risk factors, prevention, and management of postoperative recurrence after resection of hepatocellular carcinoma. *Ann Surg* 2000;232:10-24.
37. Firouznia K, Ghanaati H, Alavian SM, Azadeh P, Toosi MN, Mirzaian AH, et al. Transcatheter arterial chemoembolization therapy for patients with unresectable hepatocellular carcinoma. *Hepat Mon* 2014;14:e25792.