

First permanent molar mandible root development assesed by periapical radiograph

Lidya Irani Nainggolan, Adinda Munawarah

Department of Dentomaxillofacial Radiology Faculty of Dentistry, University of Sumatera Utara

ABSTRACT

First permanent molar mandible had already erupted in 6-7 years old and the root formation completes at age of 9-10 years. The root formation of first permanent mandible starts at 5 years and 3 months old, which in radiograph shows as radiopaque area that appear below the crown line, and the root development become half of the root formation at 6 years and 2 months old. This stage of first permanent mandible root development can be associated with age estimation. The aim of this study was to determine the stage of the root development, the shape and length of the first permanent molar mandible in children aged 6-10 years old in periapical radiograph. The radiograph was placed on the viewer box and marked the edge of cemento enamel junction and the tip of apex root by pencil and placed the tip of calipper on the two point that have been marked then measured the length using a ruler. Measurement of the roots length were taken for mesial and distal of each tooth and noted the root shape that assessed from the radiograph. The result of this study shown that the length of first permanent mandible of 6-10 years old was in the range of 5,5 -14 mm for mesial root and 4,5 - 12 mm for distal root. The majority of root development shape was at stage R $\frac{3}{4}$ at 6 years (71,4 %), at 7 years (100 %), at 8 years (85,7%) and at the age of 9 years old 85,7% of root shape was at stage Rc and 57,1 % of the root shape of the 10 years old was at stage Ac, which stage means the root formation already complete. As a conclusion, the mesial root length appears longer than the distal length with the root length varies on the age of 6-10 years old. The root development shape of 6 and 7 until 8 years old mostly shows the root already formed $\frac{3}{4}$ of root formation, then at 9 years old the root shape become complete but the apex not yet, and at 10 years old the stage of the root shape already complete which shown by the closed of the root apex completely.

Keywords : First permanent molar mandible, root shape and root length, radiography periapical

ABSTRAK

Latar belakang: Molar permanen pertama rahang bawah erupsi pada usia 6-7 tahun dan pembentukan akar lengkap pada usia 9-10 tahun. Pembentukan akar molar permanen pertama rahang bawah dimulai pada usia 5 tahun 3 bulan, yang pada gambaran radiografi menunjukkan sebagai daerah radiopak, tampak di bawah garis mahkota dan perkembangan akar hingga setengah dari pembentukan akar pada usia 6 tahun 2 bulan. Tujuan dari penelitian ini adalah untuk menentukan tahap perkembangan akar, bentuk dan panjang dari molar permanen pertama rahang bawah anak-anak usia 6-10 tahun melalui radiografi periapikal. Tahapan perkembangan akar mandibula permanen pertama ini dapat dikaitkan dengan estimasi usia. Metode: Foto radiografi ditempatkan pada kotak cahaya, lalu menandai batas daerah cemento enamel dan ujung akar apeks menggunakan pensil. Ujung calipper ditempatkan pada dua titik yang telah ditandai kemudian diukur menggunakan penggaris. Pengukuran panjang akar pada mesial dan distal setiap gigi dan mencatat bentuk akar yang diperiksa dari foto radiograf. Hasil penelitian: Panjang mandibula permanen pertama anak usia 6-10 tahun berada di kisaran 5,5 - 14 mm untuk akar mesial dan 4,5 - 12 mm untuk akar distal. Mayoritas bentuk perkembangan akar adalah pada tahap R $\frac{3}{4}$ pada usia 6 tahun (71,4%), usia 7 tahun (100%), usia 8 tahun (85,7%) dan pada usia 9 tahun 85,7% bentuk akar adalah pada tahap Rc dan 57,1% bentuk akar anak usia 10 tahun pada tahap Ac, yang berarti pembentukan akar sudah lengkap. Simpulan: Panjang akar mesial tampak lebih panjang dari akar distal dengan panjang akar bervariasi pada usia 6-10 tahun. Perkembangan akar usia 6 sampai 8 tahun sebagian besar menunjukkan akar sudah terbentuk sebesar $\frac{3}{4}$, kemudian pada 9 tahun bentuk akar menjadi lengkap tapi apeks belum dan pada usia 10 tahun pembentukan akar sudah lengkap, ditunjukkan oleh apeks yang tertutup secara lengkap.

Kata Kunci: Molar permanen pertama rahang bawah,

INTRODUCTION

Growth and development of teeth is something that must be considered, particularly in the permanent dentition of children. The first permanent molar eruption before the loose of deciduous teeth, and this teeth are not the teeth that replaced the deciduous teeth. The first eruption of permanent teeth is the first molar tooth that erupted at the age of 6-7 years and the roots of the teeth formed completely at the age of 9-10 years.¹⁻³

Demirjian research indicating growth of permanent tooth bud of boys starting at age 8 years old and the permanent tooth bud growth in girl started at age 4 years and 5 months old showed the formation of the tooth crown has been completed and beginning to expand toward the cemento-enamel junction, the upper edge of the pulp chamber in single-rooted teeth appear radiopaque in the pulp horns and it is the beginning of the teeth root formation.⁴

Moorrees classification assess development of the permanent mandibular molar in boys showed $\frac{1}{2}$ tooth root occurs at the age of 6 years

and 2 months, $\frac{3}{4}$ tooth root occurs at the age of 7 years and 4 months, a complete root formation occurred at the age of 8 years, the apical foramen opens at the age of 8 years and 5 months, and closed the apical foramen age of 9 years and 3 months, while in girls $\frac{1}{4}$ tooth root occurs at the age of 4 years and 7 months, $\frac{1}{2}$ tooth root occurs at the age of 5 years and 9 month, $\frac{3}{4}$ tooth root occurs at the age of 6 years 7 months, the perfect root formation occurs at the age of 7 years and 6 months, open apical foramen age of 8 years and 1 month, while the apical foramen closed 8 years 5 months.⁵

The root development according to Demirjian, the mineralization stage is the process of teeth bud calcification until the completion of the root development of the tooth bud is divided into eight phases (scale A to H), the boy phase D and phase E shows the beginning of root formation and the tooth bud bifurcation length that formed smaller than the crown shown at the age of 3.5 years to 4 years and 7 months. Phase F showed the length of tooth root equal or longer with the tooth crown height occurs at the age of 5 years and 8 months, the apical foramen at phase G is

still open, can be seen at the age of 6 years and 9 months old, which in phase H apical foramen was closely impeccable in age 8 years 5 months, which in girls the beginning of the tooth root formation occurs at the age of 3 years and 5 months, and at the age of 5 years and 9 months showed that the root is higher than the crown of the tooth, and at the age of 8 years the root development of apical foramen was almost impeccable that can be seen in phase H.^{4,8}

Results of research conducted by Ratna Indriyanti obtained that the pattern of tooth eruption permanent in terms of chronological age in children aged 6 to 12 years in Sumedang district showed that the eruption of the permanent mandibular molars occurs at the age of 6-7 years. Research of Dr.Woelfel (2002) in Ohio that mostly the length of the first permanent mandibular molars root in the mesial was 14 mm and 13 mm for distal root.^{6,7}

The purpose of this study was to determine from periapical radiograph the root shape and root length of the first molar permanent mandibular teeth of children aged 6-10 years in one of the public elementary school in Medan so we can compare from another race and evaluated the age estimation relation.

MATERIAL AND METHODS

This study was done in Radiology Installation of Dental Clinic of Dentistry Faculty University of Sumatera Utara, Medan. The sample taken with purposive sampling method from children in 6 - 10 years old that have a vital first permanent mandible over 70 population of government primary school in Medan. The measurements taken by put the periapical radiograph on the viewer box and marked the edge of cemento enamel junction and the tip apex of the tooth by pencil and then place the tip of the calipper on the two point that have been marked then measured using a ruler. Measurements were taken at the mesial and distal roots and processed for having the root length and assed the root shape form the radiograph.

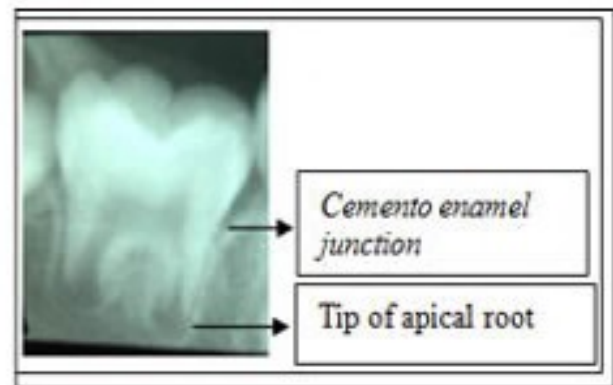


Figure 3. Measurements of root length of the first molar permanent mandibular.

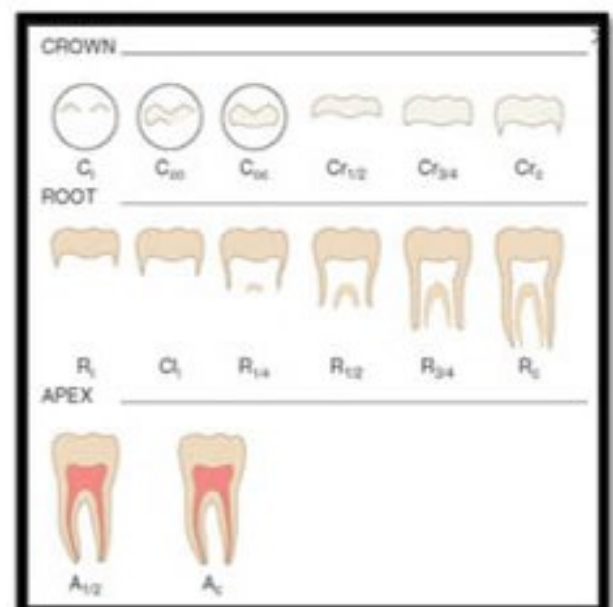


Figure 4. Moorrees root development shape⁹

RESULT AND DISCUSSION

According to the result that shown at table 1, the first permanent molar mandible of children of 6,7 and 8 years old roots development was at stage R ¾ (¾ of roots formed) was the most dominant, while in the age of 9 years the roots development in Rc (formation of root formed completely) was the most dominant and at the age of 10 years the development of the root was at Ac stage (apex section has been formed completely) was the most dominant formed.

Tabel 1. The prevalence results of the roots development of the first permanent mandibular molars.

Age (years)	Moore's (%)			Demerjian (%)				
	R 1/2	R 3/4	Rc	A 1/2	Ao	F	G	H
6	28,6	71,4	-	-	-	28,6	71,4	-
7	-	100	-	-	-	-	100	-
8	-	85,7	14,3	-	-	-	85,7	14,3
9	-	-	85,7	7,1	-	-	42,9	57,1
10	-	-	-	42,9	57,1	-	-	100

In this study obtained at the age of 7 years old all forms of first permanent mandibular roots was on stage R ¾ (¾ of roots formed). At the age of 9 years, seen more variations of root form, in 7.1 % the shape was in stage R ¾, the shape of the root in stage Rc (formation of root formed completely) had 85.7% prevalence, and 7.1 % shape of the root was at stage A ½ (apical of the root has not been closed yet) and according to Demerjian classification 42.9% of the apical tip of the root is still open (phase G) and the apical tip of the root that has been closed (step H) was 57.1%, while at the age of 9 and 10 years the root shape was at stage H (apical tip of the tooth was closed and periodontal membrane has the same thickness around the tooth root and apical) were dominant. At the age of 7 years was seen the whole shape of the tooth root entered the stage G (100%) and at the age of 10 years old all the root form that has been studied was entered the stage H (100%).

Tabel 2. Root length measurement results of the permanent mandibular molar teeth by age category.

Age (years)	Root length (mm)	
	Mesial	Distal
6	5,5-13	4,5-10
7	7-12,5	6-9,5
8	9-13,5	7-11,5
9	10,5-14	8-11,5
10	10-14	7-12

A new young eruption tooth has an apical foramen that still wide opened. As time goes by the teeth roots will continue to grow, so the apical foramen becomes narrower. Changes in the shape and location of the foramen visible during the post-eruption phase for functional strength (pressure

tongue, mesial shift) working on the teeth that leads to resorption that occurs in cementum and deposition on the walls of the foramen. The whole process is generating new foramen far from its peak.⁵

From the results of this study shown at table 2, the length of the first molar permanent mandibular are very varied, with the length measurement of the mandibular molar root average range of 5.5 mm-14 mm, in which mesial root length on average longer than the distal root, but it appears that at the age of 9 and 10 years, the difference in the length of the root is not too significant. Results of Dr. Woelfel (2002) study says that the length of the crown of the first permanent mandibular molars 7.7mm, length 14 mm while the mesial root root length 13 mm distal. Variations on this eruption due to tooth eruption, length and shape of the root is influenced by a variety of different circumstances in each person such as heredity, disease, race, climate, and social state.^{6,7}

Growth and development of the teeth eruption is a process that begins with the stage of initial calcification that occurs at birth or shortly before. Radiographic examination is a step which can help to see clearly the period of mixed tooth to see the root shape and development of the first molar permanent mandible that hopefully can help in dental treatment and evaluate the relation of age estimation of certain race.^{8,10}

CONCLUSION

The result showed that at the age of 6 years seen form the roots of the first molar mandible shape generally was already formed of ¾ root formed, while the apical end of the tooth was

still open. At the age of 7 and 8 years forms the root of the category also already formed of ¾ root formed, where the apical tip of the tooth is still entirely open. At the age of 9 years the most dominant shape of the roots showed that the root form become complete, while the apical of the root majority begin to closed. At the age of 10 years the root form was already complete, with apical tip of the root has been closed completely. The conclusion about the length that average length of mesial root of the first permanent molar mandible teeth is longer than distal root, and it appears that at the age of 9 and 10 years, the difference in the length of the root is not too significant.

ACKNOWLEDGEMENTS

Thank you to Amrin Thahir, DDS for the contribution and discussion during the reasearch

REFERENCES

1. Whaites E. Radiography and radiology for dental care professionals. 2nd ed. London: Churchill Livingstone Elsevier., 2009. p. 83-115.
2. Susi, Kuswardani, Putri S et al. Pengaruh pola makan dan menyikat gigi terhadap kejadian karies molar pertama permanen pada murid SD NEGERI 26 Rimbo kaluang kecamatan padang barat. *Maj Kedok Andal* 2012;36(2):227-32.
3. Mc Donald Ralph E, David R, Avery et al. *Dentistry for the child and adolescent*. 8th Ed., USA: Mosby Elsevier., 2004. p. 61-78,176-88.
4. Nielsen SH, Becktor KB, et al. Primary retention of first permanent mandibular molars in 29 subjects. *Europ J Ortho* 2006;529-34.
5. David R, Seen, Paul G, Stimson. *Forensic Dentistry*. 2nd ed. Francis: CRS Press., 2010: 263-88.
6. Indriyanti R et al. Pola erupsi gigi permanen ditinjau dari usia kronologis pada anak usia 6 sampai 12 tahun di Kabupaten Sumedang. Tahun 2006. Tesis. Jawa Barat: Laporan Penelitian Fakultas Kedokteran Gigi UNPAD, 2006. p. 1-23.
7. Julian B, Rickne C. *Dental anatomy its relevance to dentistry*. Sixth edition., Philadelphia: Lippincott William & Wilkins., 2002. p. 178-96.
8. Koch G, Poulsen S. *Pediatric dentistry*. 1st Ed., Denmark: Blackwell Munksgaard, 2001:99-67.
9. Avery JK, J D. *Essentials of oral hystology and embryology a clinical approach*. 3rd ed. Canada: Mosby Elsevier. 2006. p. 63-95.
10. Balogh MB, Margaret J, Fehrenbach. *Dental Embryology, histology, and anatomy*. 2nd ed. USA: Elsevier Saunders. 2006. p. 61-91.