

Relaps and retention after orthodontic treatment

Elih

Departement of Orthodontic Fakulty of Dentistry Universitas Padjadjaran

ABSTRACT

Orthodontic treatment results are potentially unstable that has a tendency to return to the former position. This is the so called relapses and therefore retention is necessary because the gingival and periodontal tissues are affected by orthodontic tooth movement and required time for reorganization when the appliances are removed. Retention is the prolonged dental detention that is done at the end of an orthodontic treatment with use of appliances designed for dental stabilization. The purpose of this paper is to explain the cause of relapse and a wide range to prevent relapse. The method used is based on literature. The conclusion is stabilizing treatment results with the retention procedure is an important part in orthodontic treatment. The patient must be given information about the implications of relapse and how to use the retainer, so that the patient can take responsibility for retention phase of treatment.

Key word: relapse, retention, stable, orthodontic treatment

ABSTRAK

Latar belakang. Hasil perawatan ortodontik berpotensi tidak stabil sehingga memiliki kecenderungan untuk kembali ke posisi semula. Hal ini disebut Relaps dan oleh karena itu Retensi diperlukan pada perawatan ortodonti karena gingiva dan jaringan periodontal dipengaruhi oleh pergerakan gigi secara ortodonti dan diperlukan waktu untuk reorganisasi ketika alat ortodonti dilepas. *Tujuan.* Tujuan dari makalah ini adalah untuk menjelaskan penyebab relaps dan berbagai cara untuk mencegah relaps. *Metode penulisan* adalah studi literatur. *Ulasan.* Retensi adalah periode mempertahankan gigi yang dilakukan pada akhir suatu perawatan ortodonti dengan penggunaan peralatan yang dirancang untuk stabilisasi gigi. *Kesimpulan.* Mempertahankan hasil perawatan dengan prosedur retensi merupakan bagian penting dalam perawatan ortodontik. Pasien harus diberi informasi tentang implikasi relaps dan bagaimana menggunakan retainer, sehingga pasien dapat mengambil tanggung jawab untuk fase retensi pengobatan.

Kata kunci: relaps, retensi, stabil, perawatan ortodonti

INTRODUCTION

Relapse is officially defined by the British Standar Institut as the return, following correction, of the features of the original malocclusion. Relaps is perhaps better described as any change from the final tooth position at the end of treatment. It may be return towards the original malocclusion, but may also be movement caused by age changes and unrelated to the orthodontic treatment.¹ There are several factors that can lead to relapse after orthodontic treatment can be prevented with the use of retainer.

Retention is prolonged dental detention that is done at the end orthodontic treatment with the use of appliance designed for dental stabilization. Orthodontic treatment result are potentially unstable and therefore retention is necessary because the gingival and periodontal tissue are affected by orthodontic tooth movement and require time for reorganization when the appliances are removed, the teeth may be in an inherently unstable position after the treatment, so that soft tissue pressures constantly produce a relapse tendency, and changed produced by growth may alter the orthodontic treatment result.²

Retainer there are various types and their respective functions. Therefore, dentists must know the factors that lead to relapse and various retainer is used to prevent relapse.^{2,3} The purpose of this article is to discuss the causes of relapse and various retainer to prevent relapse

LITERATUR REVIEW

Relapse

Relapse is a state of loss of correction has been achieved in orthodontic treatment. Great results orthodontic treatment refers to the six keys of occlusion according to Andrew that relationship first molar Class I, mesiodistal angulation of the tooth, the dental crown inclination, no rotation, contact point is good and Spee curves, with reference to the six keys of occlusion of the expected results of orthodontic treatment will be stable.⁴ In addition, to prevent relapse, it is necessary to stabilize the results of treatment with retention procedures.

Etiology of relapse

Basically, there are four broad areas have been suggested as possible reason for relapse:

1. Gingival and periodontal factors. When teeth are moved the periodontal ligament and associated alveolar bone remodels. Until the periodontium adapts to the new position, there is a tendency for the stretched periodontal fibers to pull the tooth back to its original position. The alveolar bone remodels within a month, the principal fiber rearrange in 3-4 months and the collagen fibers in the gingival reorganize after 4-6 months. Elastic fibers in the dento-gingival and interdental fibers can take more than 8 months to remodel. Until the fibers have remodelled there is a tendency for the tooth to be pulled back to its original position.¹
2. Occusal factor. If the teeth interdigitate well at the end of orthodontic treatment then the results is likely to be more stable.¹ To obtain stability after treatment, it must be accomplished his key six occlusion according to Andrew.⁴
3. Soft Tissue. The teeth lie in an area of balance between the tongue on the lingual aspect and cheeks and lips on the buccal and labial aspect. This theoretical area of balance is known as the neutral zone. The force from the tongue are greater than those from the lips and cheeks, but providing the periodontal ligament is healthy, the teeth will be maintained in a position equilibrium. If the teeth are moved out of the neutral zone, then the chances of relaps are increased.¹
4. Growth. Growth is an aid in the correction of many types of orthodontic problem, but it also may cause relaps in treated orthodontic patient.¹

The factors that cause relapse are failure in eliminating the causes of malocclusion, diagnosis and treatment plan that is not appropriate, premature contact, stretched periodontal fiber, alveolar bone adaptation, muscle tone, size and improper jaw relationships, axial inclination not right, not good contact, failure to correct the rotation, tooth size disharmony, influence of growth changes, persistence of habits or bad muscular function, decrease in intercanine width, third molar presence (there is much controversy

about this fact), periodontal memory or tendency of the teeth to return to their original position, inadequate insertion of buccal frenum. Activity of growth factors, cytokines and colony stimulating factors will affect the biological activity of the periodontal tissues during relaps.^{5,6}

Retention

The retention is to maintain teeth in the new position in a time long enough to stabilize the treatment result and hold the teeth in position already in terms of both aesthetic and functional.⁷ Required retention after orthodontic treatment because of gingival, periodontal ligament and alveolar bone takes time for reorganization after the tool is removed. Soft tissue and bone remodeling rudimentary cause tooth position is not stable after treatment and cause a relapse.

According to Graber, there are several criteria that must be owned by a retainer that retainer should be able to maintain the new position of the teeth after orthodontic treatment, a retainer must be able to provide access to functional pressure to be able to move freely on the retaining teeth, retainers must be easy to clean and can maintain oral hygiene, and strong enough to withstand everyday use.³ Retention tool consists of two kinds of fixed appliance and a removable appliance used in accordance with the indication.

Removable retainer

1. Hawley retainer

It is the most utilized retainer. Hawley Retainer has four major component: (1) clasps that hold the retainer on the teeth, (2) occlusal rests that keep the mandibular retainer in place, (3) a labial bow wire to hold the teeth in place in conjunction with (4) an acrylic body that supports the lingual surfaces of the teeth and holds the clasps and labial bow in place.⁸

A number of different clasps are used to anchor a Hawley retainer to the teeth. The anchor elements can be Adams, ball, circumferential, Duyzing and Schwartz hooks. The most used are the Adams and the ball hook which are placed in the interproximal spaces.^{6,8}

The buccal arch must be perfectly adapted to the incisor and the canine and must pass through the middle third of the crowns. This will

provide more retention and will lessen rebound. Hawley retainer should be worn all day and night, except when eating and brushing. This must be done for at least the first 6 months after active treatment. Thereafter, night wear should be continued at least through the period of active growth.⁶

Removable Hawley Retainer have many advantages that make them the preferred retainer for most patients. Hawley Retainers allow a patient to sustain a program of good oral hygiene, does not provoke caries or periodontal problems, retainer can maintain teeth in good occlusion for many years, Hawley are excellent long term retainers. Springs, fingers, rackets can be added to correct slight rebound. An anterior bite plane can be added for deep bite patients. A posterior block can be added for open bite patients. It serves as a guide for the eruption of second and third molars. It is a lasting retainer.^{2,4,8}

Several disadvantages come to mind such as wires passing over the occlusal surfaces that interfere with occlusion and prevent the setting of the teeth and the dependence on patient to wear and clean the retainer as directed. They are laboratory time consuming construction. The gripping hooks can be damaged and modify the occlusion of patient. Anti esthetic. Speech is impaired. Due to continuous use, the retainer can change color and absorb bad odors.^{6,8}

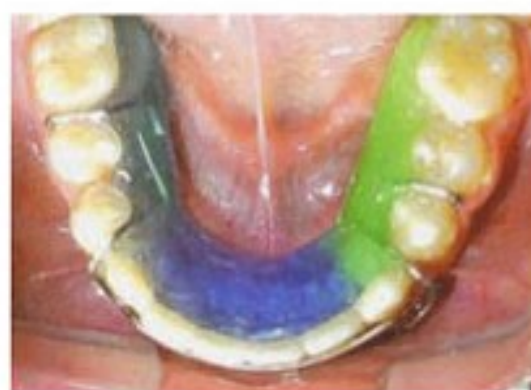

Figure 1. Hawley Retainer.⁸

2. Wrap around retainer

This type of retainer is very similar to the Hawley retainer, the difference between the Hawley and the Wrap around retainer is the buccal arch. In the wrap around retainer the buccal arch

embraces all the erupted teeth as to grasp them and avoid the reopening of the extraction sites, so this retainer is used in premolar extraction case.⁶

Advantages of Wrap around retainer are sanitary because it does not build up tartar. It allows the use of dental floss without impediments. Does not provoke caries or periodontal problems. Well built retainer can maintain teeth in good occlusion many years. Circumferential retainers are excellent long term retainer. Does not interfere with the occlusion of the patient. An anterior bite plane can be added for deep bite patients. A posterior bite block can be added for open bite patients. If we cut the buccal arch (in the distal portion of the loop) it can be transformed into an elastic wrap around retainer.

Disadvantages of Wrap around retainer are laboratory time consuming. The buccal arch is very long, it distorts easily and adjustment can be difficult. We depend upon patient compliance for its use and clearing. Anti esthetic. Speech is impaired. Due to continuous use, the retainer can change color and absorb bad odors. It must be worn all day and night and must only be removed when the patient is going to eat and when the patient is going to brush his teeth. This must be done for at least the first 6 months after active treatment.

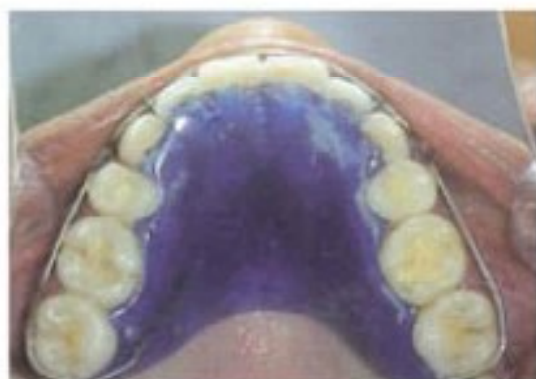


Figure 2. Wrap Around Retainer.⁶

3. Elastic wrap around

This retainer has an acrylic plate with two buccal 0.036" steel arms on which an elastic is placed in order to correct small rebounds like anterior proclination and space closure. The terminal part of these arms has a hook at premolar and canine level, an elastic latex band will be placed in the hooks to help us close remnant or recurring.⁶

The retainer must be used 24 hours a day, except during meals and oral hygiene. Change the elastic every 24 hours. The elastic used must be ¼" in diameter and the elastic must pass through the middle third of crown of anterior teeth.

Advantages of Elastic wrap around are sanitary, it is a lasting retainer, well accepted by patient, it allows the use of dental floss without impediment, It gives us posterior segment stability and closes spaces in the anterior segment. Esthetic, depends on the color of the elastic chosen by patient.⁶

Disadvantages of Elastic wrap around are it depends upon patient cooperation. Space closure is difficult to control. Speech is impaired. The retainer can dislodge if the elastic worn is too heavy.⁶

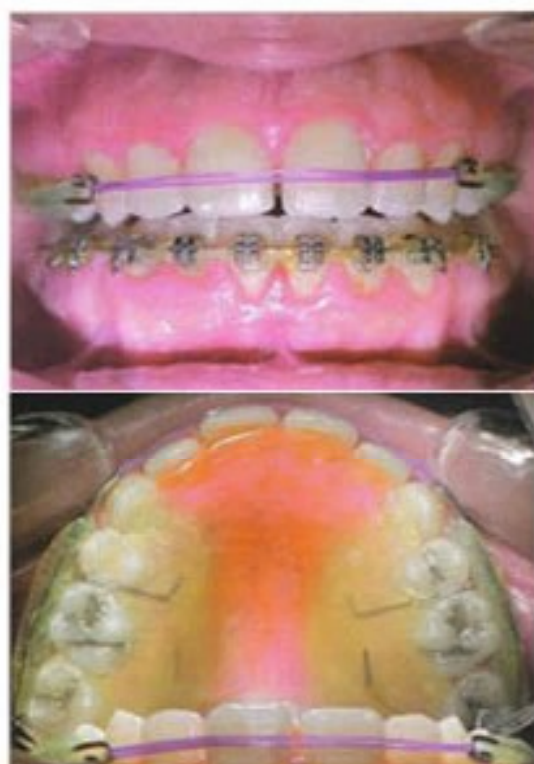

Figure 3. Elastic Wrap Around.⁶

4. Van der Linden retainer

Developed in 2003 by Dr Frans Van der Linden, it consists of a stainless steel canine to canine 0.028 " buccal arch and two 0.032" hooks in the last molar. Premolar and molars are acrylic free because this sector settles with the occlusion, and retention will only be necessary in the anterior region. Use the retainer at night time.⁶

Advantages of Van der Linden retainer are Hygiene, the retainer does not interfere with occlusion because the majority of disto-incisal angles of the upper lateral incisors are rounded and there is enough space to allow the passage of the wire toward the palate. All the teeth are free to occlude. It can be combined with a fixed retainer. Spring, fingers, rackets can be added to correct

slight rebound. Well built retainers can maintain teeth in good occlusion and aligned for many years.⁴

Disadvantages of Van der Linden are it depend upon patient compliance for retention and cleaning. We need to invest time in the laboratory. Anti esthetic. It impairs speech. Because of the continuous use, the retainer can change color and retain foul odors.⁴

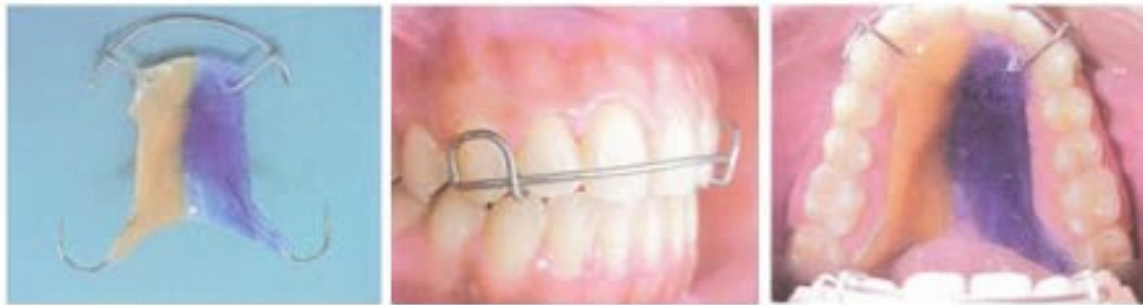

Figure 4. Van der Linden Retainer.⁴

5. Sarhan or all wire retainer

It has the particularity that it does not have any acrylic, it is made of 0.032" stainless steel wire that envelopes all the erupted teeth. Useful in extraction cases, because it envelopes the teeth. It should be use 24 hours a day.⁴

Advantages of Sarhan or all wire retainer are Highly hygienic, It does not affect speech,

Comfortable, very cheap, difficult to fracture, does not absorb odors, the occlusion patients is free. Disadvanges of Sarhan or all wire retainer are takes a long tme to manufacture, it is not esthetic.

We depend upon patient compliance for use. Rebound correction like rotation, diastemas, proclination, intrusion with retainer are difficult.

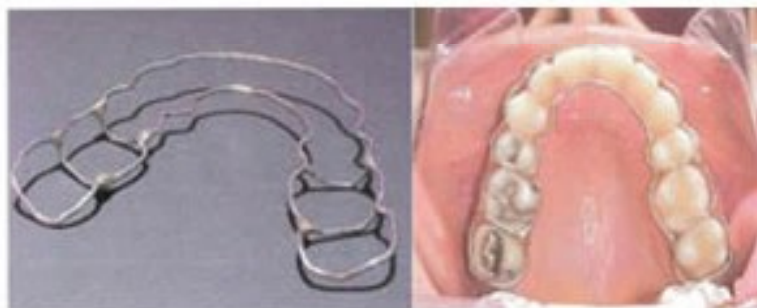

Figure 5. Sarhan or all Wire Retainer.⁴

6. Spring aligner

This retainer is like a circumferential or wrap around retainer, but the main difference is that it only include the six anterior teeth meanwhile the wrap around retainer includes all the erupted teeth. The retainer must be worn all day and night during the first two or three weeks, later it may be worn only at night.⁴ Advantages of Spring Aligner are hygiene, does not cause caries or periodontal

problems, well made retainer can correct rebound in 2 to3 motnhs, it allows syndesmosthomy, and it is lasting. Disadvantages of Spring Aligner are not very esthetic, we depend upon patient cooperation, it can absorb foul odors and change color, we must invest laboratory time, the wire that pass over the incisal edge can interfere with the occlusion and not allow settlement of the posterior teeth.⁴

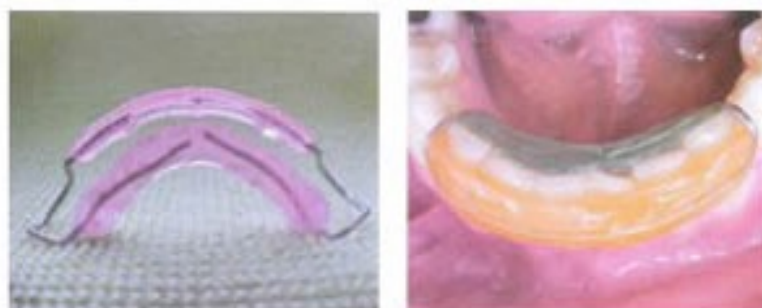


Figure 6. Spring Aligner.⁶

7. Coregg (Garcia-Gaitan rebound corrector)

This appliance is alternative for the correction of small post treatment rebounds in the anterior and posterior region, and this way may avoid a retreatment with braces. The acrylic must be 0.5mm to 1 mm thick, all the antagonist teeth must occlude on all the acrylic.⁶

Advantages of Correg retainer are very cheap, hygiene, excellent space closure appliance,

teeth tip and torque is maintained, in block space closure is obtained, these are excellent long term retainer, it allows syndesmothomy, dan it is lasting retainer. Disadvantages of Coregg retainer are it takes a long time to make, it is not esthetic, absorbs foul odors, with continuous use the acrylic changes color, the acrylic can fracture under occlusion pressure. If it is not well made it can provoke an open bite. Unadjusted loops can hurt the oral mucosa.⁶

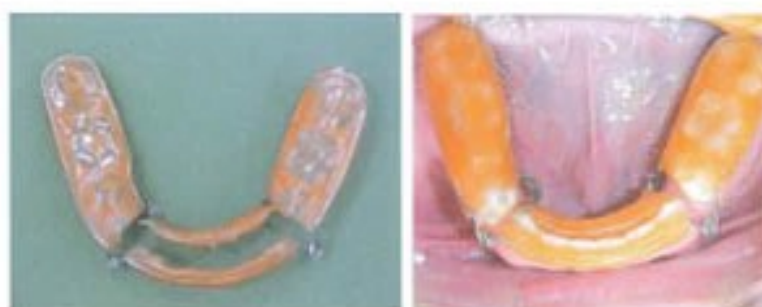

Figure 7. Coregg retainer.⁶

8. Osamu retainer

This retention system was developed in Japan by Dr. Yushii Osamu. It consists of a thermoplastic retainer that wraps the whole dental arch and part of the alveolar mucosa. It is made of one soft acetate 1.5 mm thick and one hard acetate 0.5 mm thick. It must be worn 12 hours daily, and recommended in extraction cases.

Advantages of Osamu retainer are esthetic, hygienic, well accepted by patient, it has good retention. Disadvantages of Osamu retainer are produces a slight open bite, it consumes laboratory time, it may fracture under occlusion pressure, it depend upon patient compliance for retention, it last about 8-12 months, due to continuous use it can change color and absorb foul odors.

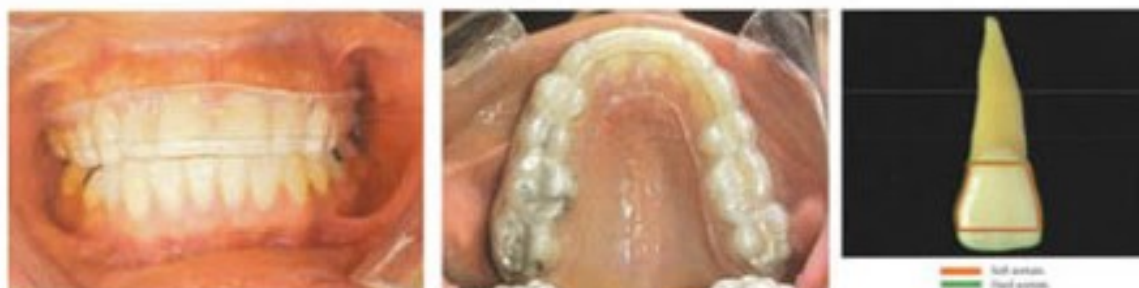

Figure 8. Osamu retainer.⁶

9. Essix

The Essix retainer is an example of the invisible retainer. This is a very esthetic and versatile retainer developed by Dr Jack Sheridan. This retention system is based on acetate or plastic plate. There are two types for the fabrication of Essix, Type "A" are used for the elaboration of canine to canine retainers. They are very esthetic, they reflect light and maintain the natural brilliance of teeth. Essix Type C, there are less esthetic than the type "A" because they do not reflect light as

well, but are more resistant, type "C" are used for night use molar to molar, to maintain a palatine expansion, useful in patient that grand their teeth, as space maintainers.⁶ Advantages of Essix are highly esthetic, easy to make, comfortable, cheap, the Essix "C" can be used as a tray for dental bleaching and can be sectioned for space closure. Disadvantages of Essix are the Essix "type A" lasts about 6 months, the Essix "type C" lasts about 12 months, the Essix "type A" is not recommended for palatal expansion maintenance.⁶

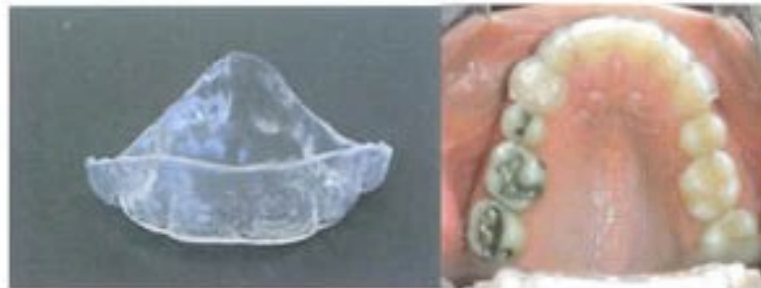

Figure 9. The Essix type A.⁶

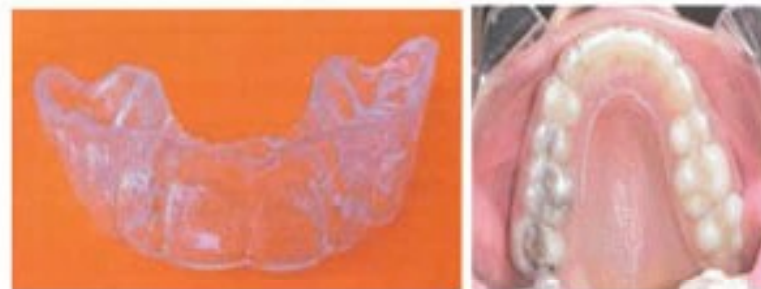

Figure 10. Essix type C.⁶

10. Reinforced essix

This is an esthetic retainer developed by Dr Kevin Theroux. This retention system is based on two plastic plates or acetates to provide greater support and stiffness to the retainer. It is recommended to use continuously for the first 15 days, only taking it off during food consumption,

later on two hours in the afternoon and nightly use is enough. Not recommended in cases of dental rotations.⁶ Advantages of Reinforced Essix are esthetic, hygienic, cheap, easy elaborate, well tolerated, due to its rigidity it can maintain any palatal expansion. Disadvantages are it lasts about 6 to 8 months, the anterior segment can fracture.⁶

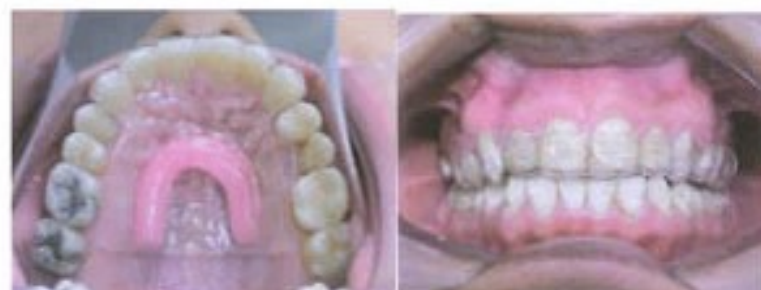

Figure. 11 Reinforced Essix.⁶

B. Fixed Retainer

This type of retention is used when a prolonged retention is planned or when we fear that teeth alignment is instable. Lingual fixed retainers in mandibular arch do not interfere with occlusion. However, sufficient overjet is required for the placement of fixed bonded wires on the lingual surfaces of upper incisors so that the fixed retainer does not interfere with the occluding lower anterior teeth. In the upper arch, bonded wire fixed retainers are often used to retain closed diastemas between the upper central incisors.^{2,4,8}

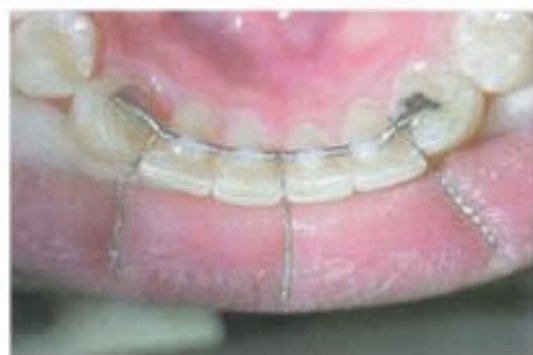

Figure 12. Prefabricated Fixed retainer.⁶

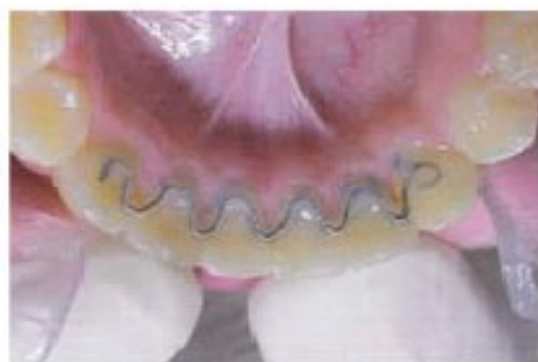

Figure 13. Fixed retainer.⁶

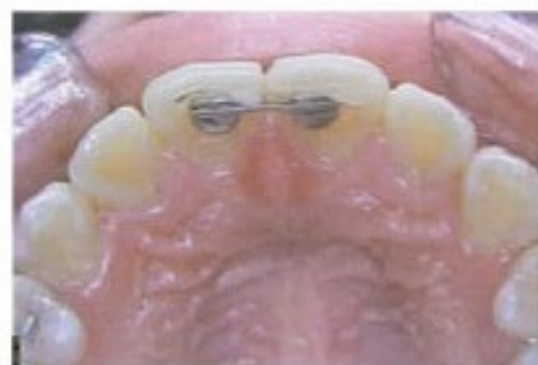

Figure 14. Fixed retainer in upper arch to retain a closed diastema.⁶

Lower inferior retainers can be left until growth is completed and for two years in adult. After this, an individual decision must be taken for its removal. There are two type of additaments for fixed retention : prefabricated and adapted to the patient. Prefabricated, there is a great variete of brands and models. Some of these lingual bars have two bases soldered to a 0,036" wire. There are different lengths. These bases are bonded to the lingual aspects of the canines.

Adapted on the patient. It consists of a length of wire, generally twisted and of medium caliber that is bonded to the lingual aspects of the teeth localized in the anteroinferior segment of the dental arch.

DISCUSSION

Relapse after orthodontic treatment was reported by Van Leeuwen et al (2003) at first relapse rate was 40 μm / day, then decreased and stabilized after 65 days. The average relapse rate 13 μm / day. Total number of relapses occur 40-90% of the position of the orthodontic treatment results after 10 to 20 days. Pattern of relapse is influenced by a large force applied during orthodontic treatment, the amount of active tooth movement, individual variation, remodeling tissues supporting the teeth, muscle imbalance, dental factors such as morphology and dental agenesis and growth factors.⁹

In additional, relapse is related to the amount of overjet at the beginning of treatment, the initial inclination oh the maxillary incisors, the labial inclination of the maxillary incisors in the postretention period, the lingual inclination of the mandibular incisor in the postretention, and the increase of the interincisal angle at the end of treatment.^{9,10} Several factors are related to overbite relapse and ovejet, movement of the incisors and molars, interincisal angle, anterior face height, pattern of craniofacial growth, initial incisor crowding and even the amount of overbite correction during orthodontic treatment.^{9,11} Protrusion and final position of the mandibular incisor might influence the stability of orthodontic treatment.¹² The pretreatment position of the mandibular incisors is the best guide for their labialingual position of stability. Nance asserted that flaring the mandibular incisors is never a

successful treatment technique.¹² On the other hand, Freitas et al reported that final mandibular incisor inclination and linear protrusion do not influence crowding relapse.^{12,13}

Relapse after orthodontic treatment can be prevented with the use of a retention or retainer.^{1,2,5} According to Moyers retention is to maintain the teeth in the new position in a time long enough to stabilize the treatment result and hold the teeth in position already in terms of both aesthetic and functional.⁷ Orthodontic retainer is a passive tool that helps stabilize the position of the teeth in a long time to allow reorganization of the supporting tissues of the teeth after the active phase of orthodontic treatment

The clinician is faced with a multituted of different options when choosing which retainer to used and how many hours per day the patient should wear it. When choosing the retention, the following factors should be considered: stability of the result, initial malocclusion, type of appliance, oral hygiene, quality of the result, compliance of patient, patient expectations, patient preference. Retainer can either be removable or fixed.¹

Dr Interlandi suggests that retention should be indefinite, for this reason he recommends that retainers should be removable. A removable mandibular retainer has many advantages over a fixed retainer ; the removable retainer does not allow extraction site reopening, and does not allow incisors, premolar or molar to rotate. The removable retainer serves as a space maintainer (in patients that are going to receive a prosthetic replacement). Capable of being worn part time if required. If there was a lot of rebound it will be the responsibility of the patient, because he did not use the retainers and maybe a new treatment may be needed.^{1,4}

Beside, the fixed mandibular retainer from canine to canine is not the ideal retainer for several reason being fixed so it needs frequent supervision. It does not control premolar and molar alignment. It does not impede space reopening in the extraction site, unless it is bonded from premolar to premolar or molar to molar. It does not maintain perfect alignment of the incisor unless the lingual wire is bonded to every incisor, which can make proper hygiene difficult with the subsequent accumulation of calculus. Fixed retainer is not

recommended in patient with bad oral hygiene or patient that a accumulate calculus easily.⁴

Data or research on the basic biology of tooth relapse after orthodontic treatment success is not yet known, existing research largely descriptive showing that the relapse caused by the fibrous structure of the tissue supporting the teeth, therefore it is the basis for determining the length of retention until this structure reorganized during the period after treatment ortodonti. However, other data stated periodontal ligament collagen remodeling, gingival fibers, especially fiber transeptal happen quickly. It can be concluded remodeling of collagen in the periodontal tissue is not the most important factor in the etiology of relapse, there ekstra other cellular matrix components which provide important influence on the process of relapse.³

Tissue reactions at the cellular and molecular level will affect the movement of teeth during orthodontic treatment. Similarly, on the relapse process, the benefits of various growth factors, cytokines, colony stimulating factors will affect the biological activity of the periodontal tissues during relaps. therefore necessary to find another way to prevent relapse is by giving drugs locally or systemically to affect and cellular growth factor influencing the process of relapse.³

Currently developing ways to prevent relapse by using drugs. Bisphosphonat known to give effect to inhibit bone resorption and increase bone mineral density locally so it can be used for the prevention of relapse after treatment ortodonti.¹⁴ The results Puji 2013 states that Lemuru fish oil containing omega-3 polyunsaturated fatty acids (n-3 PUFA) can reduce the number of osteoclasts and increasing the number and activity of osteoblasts to increase bone formation on the teeth alveolar driven orthodontic rabbits. Thus, Lemuru fish oil is expected to accelerate bone remodeling and prevent relapse.¹⁵

The clinician should discuss retention procedures with patient before starting orthodontic treatment to impress upon them the importance of the retentive phase that follows active treatment. The patient must given information of relapse and how to look after the retainers, so that the patient can take responsibility for the retention phase of treatment.

CONCLUSION

Retention is an important part of orthodontic treatment. The choice of retainer is affected by stability of the result, initial malocclusion, type of appliance, oral hygiene, quality of the result, compliance of patient and patient expectations. The patient must be given information about the implications of relapse and how to look after the retainer, so that the patient can take responsibility for retention phase of treatment.

REFERENCES

1. Mitchell L. Retention. An introduction to orthodontics. 3rd ed. Oxford. 2007. p.168-76.
2. Proffit W. Contemporary orthodontics. 4th ed. Mosby Inc., St Louis. 2007. p. 606-20.
3. Joondeph DR. Stability retention and relapse. In orthodontics current principles and treatment. Eds Graber V. Elsevier. Philadelphia. 2012. p. 991-1016.
4. Rakosi T, Irmtrud J, Thomas MG. Color atlas of dental medicine orthodontic diagnosis. thieme medical. New York.1993. p. 51-6.
5. Krishnan V, Davidovitch Z. Biology of orthodontic tooth movement. Blackwell Publishing. Oxford. 2009. p. 201-14.
6. Rodriguez El, Larry W, Rogelio C, Adriana N. 2007. Retention of orthodontics. 1001 Tpis for Orthodontics and its Secrfet. Amolca., Venezuela. 2007. p. 312-51.
7. Rygh P, Robert EM. Force systems and tissue responses to forces in orthodontics and facial orthopedics in handbook of orthodontics. 4th ed. Year book Medical Publishers. Chicago. 1998. p. 326-7.
8. Bishara SE. Text book of orthodontics. W.B Saunders Com. Philadelphia: 2001. p. 318-23.
9. Francisconi MF, Guilherme J, Karina MSF, Renata CGO, Ricardo CGO, Marcos RF. Overjet, overbite, and anterior crowding relapse in extraction and non extraction patients, and their correlations. Am J Orthod Dentofac Ortho 2014;146:67-72.
10. Nelson B, Hansen K, Hagg U. Overjet reduction and molar correction in fixedappliancs treatmen of class II division 1 malocclusion: sagital and vertical component. Am J Orthod Dentofac Ortho 1999;115:12-23.
11. De Praeter J, Dermaut L, Martens G, Kujjpers-Jagtman AM. Long-term stability of of the leveling of the curve of spee. Am J Orthod Dentofac Ortho 2002;121:266-72
12. Erdinc AE, Ram SH, Erdal I. Relapse of anterior crowding in patients treated with extraction and nonextraction of premolar. Am J Orthod Dentofacial Orthop 2006;129:775-84.
13. Freitas KMS, Freitas MR, Henriques JFC. Pinzan A, Janson G. Postretention relapse of mandibular anterior crowding in patients treted without mandibular premolar extraction. Am J Orthod Dentofac Orthop 2004;125:480-7
14. Krishnan V, Ze'ev D. The effect of drug and diet on orthodontic tooth movement. Biology of orthodontic tooth movement. Blackwell Publishing. Oxford. 2009. p. 169.
15. Hartanto P. Pengaruh pemberian minyak ikan lemuru (*Sardinella longiceps*) pada Proses remodeling alveolar gigi kelinci new zaeland yang digerakkan secara ortodonti. Yogyakarta: University of Gajah Mada. 2013.