

Immunoexpression of cytokeratin 19 in oral swab from fixed orthodontic appliance users

Dwi Mutia Ramdhini, Sunardhi Widyaputra, Murnisari Darjan

Department of Oral Biology Faculty of Dentistry Universitas Padjadjaran

ABSTRACT

The use of fixed orthodontic appliances can improve someone's mastication, speech and appearance. However, this appliance acts as a strange object that may cause irritation to the mucosa epithelial of oral cavity, because of the friction and pressure from the components of the fixed orthodontic appliances which are in direct contact with the oral mucosa. Irritation in the oral mucosa could stimulate the increase of cytokeratin. The appearance of cytokeratin is then used to identify the condition of these cells. This study was a descriptive research to find the expression of cytokeratin 19 with immunohistochemical method in oral mucosa epithelial of fixed orthodontic appliances users. Sample in this study was chosen from 30 fixed orthodontic appliances users. The result of this study was determined by calculating the number of positive cells (brown), compared with total number of cells. The account of positive cells would present the reaction of the epithelial cells according to the inflammation stage which caused by the use of orthodontic appliances. As a conclusion of this study, the use of fixed orthodontic appliances may cause changes in epithelial mucosa which form an adaptation process by increasing the number of progenitor cells marked by cytokeratin 19.

Key words: Fixed orthodontic appliances, cytokeratin 19, immunohistochemical

INTRODUCTION

Tooth is an important organ that plays a role in mastication, esthetic and phonetic functions. When an abnormality or damage is found in one of the dental components, the dental function will be disturbed. Currently, esthetic plays important role because people's concern of appearance is getting higher.

Along with improved community awareness on the importance of health and appearance, the need for orthodontic treatment increases. Small arch with big size teeth may lead to crowding.¹ This often causes health disturbance in the mouth

as well as esthetic disturbance in the form of malocclusion. To achieve a maximum result, in addition to fixing esthetic function, the dentist should pay attention to the biological aspect.

The objective of this orthodontic treatment is to improve the occlusal relationship as optimum as possible in the facial esthetic frame and good stability.¹ In addition to get good dentofacial appearance, orthodontic treatment is also aimed at improving crowded dental structure, get healthy oral tissue, improve confidence and restore mastication, speech and breathing functions.²

Orthodontic treatment using fixed orthodontic appliance is one of the orthodontic

treatments. Fixed orthodontic treatment has several advantages compared to removable orthodontic appliance including wider indication and ability to correct a malocclusion in a relatively short duration compared to removable appliance. On the other hand, pain and uncomfortable feeling in oral mucosa may be found during the application of orthodontic appliance. This may be due to friction between oral mucosa and parts of fixed orthodontic appliance such as bracket, band and wire.³

The components of fixed orthodontic appliance may cause irritation and lesions in the oral cavity and chronic irritation may cause hyperplasia and hyperkeratosis.⁴ Because of the irritation in the oral mucosa, the epithelial cells adapt through keratinization by creating defense mechanism that triggers cell mitosis activity and cell maturation faster.

The progenitor cells that play the role in cell mitotic process can be found in the base layer. Inflammation may happen due to chronic irritation from orthodontic appliance components, causing increased number of progenitor cells. There are various keratin cell type, referred as cytokeratin, found in epithelial cells, according to their functions. One of the cytokeratins, i.e. cytokeratin 19, may specifically show changes in cells and becomes a marker for progenitor epithelial cells that play a role in cell mitosis.

One of the methods to detect oral abnormalities in early stage using an easy and accurate manner is oral swab method. In oral swab taken from oral mucosa, changes in oral mucosal cells caused by irritation can be seen.⁵ The result of oral mucosal oral swab is then smeared using immunohistochemical technique that is specific and sensitive.

Several studies have proven changes in oral mucosal cytology description in people who use orthodontic and prosthodontic appliance, those with smoking habit and alcohol drinker. The presence of irritation in oral mucosal cell may cause changes in superficial, intermediate, and even base layers. By using immunohistochemical dye that is specific and sensitive, cell changes in intermediate and base layer can be observed.

Based on those reasons, the author was encouraged to study the presence of cytokeratin

19, which is the progenitor cell marker, in oral mucosal swab due to inflammation caused by fixed orthodontic appliance using immunohistochemistry smear method.

MATERIALS AND METHODS

Population of this study consisted of female students of the Universitas Padjadjaran who were wearing fixed orthodontic appliance. The sample consisted of 30 subjects and from each subject, a buccal and labial mucosal swabs were taken as the study objects.

The criteria for the population in this study included: Fixed orthodontic appliance wearer; Age 18-22 years old; No smoking habit; Not an alcohol drinker and beetle chewer; Do not have oral habits like lip or cheek biting; No abnormality in oral mucosa; Do not experience cancer or in cancer treatment; During the swab, the subject was not consuming or just finish consuming candy or other sweets.

Materials: Buccal and labial mucosa swab; ethyl alcohol (95%) as fixation solution; aquadest; xylene; 100% ethanol; 95% ethanol; 0.3% H₂O₂; 2% human normal serum; TBS; primary antibody; Peroxidase labelled-goat anti mouse immunoglobulin (dilution 1:50).

Procedure: before swabbing was performed for cytological examination, question and answer was performed to fill out the informed consent form. Subject was asked to rinse her mouth. Wood spatula was wetted with aquadest. Swab was performed using wood spatula with 20 one-direction movements in the buccal part and a swab was made using the same technique in labial mucosa with different wood spatula. The material that accumulate in spatula was smeared immediately with one light movement without pressure on the object glass that was given preparation number according to the ID number in the questionnaire on one of the edge using special pencil. The smear on the object glass was then fixated in 95% ethyl alcohol for 30 minutes and dried. After the preparation was dry, it was then covered with aluminum paper for immunohistochemical dying. The positive control was made from tongue carcinoma block paraffin preparation; that would give positive result to cytokeratin 19 dying.

The negative control was made from one of the subjects whose swab was taken twice without application of cytokeratin 19 antibody and normal serum was applied instead.

Laboratory procedure. Fixation of the smear; Incubation in xylene, 3 times, each for 10 minutes; Incubation in 100% ethanol for 10 minutes; Incubation in 95% ethanol for 10 minutes; Rinsing with aquadest; Incubation in 0.3% H₂O₂ in methanol for 10 minutes; Trypsinization using trypsinase; Incubation with 2% human normal serum in TBS for 10 minutes; Rinsing with 3 times TBS every 5 minutes; Incubation with primary antibody (cytokeratin 19); Rinsing with 3 times TBS every 5 minutes; Incubation using peroxidase-labelled goat anti-mouse immunoglobuline with a dilution of 1:50 for 30 minutes in room temperature; Rinsing with 3 times TBS every 5 minutes; Made a reaction with DAB (Diamino Benzidine)/H₂O₂ for 15-20 minutes in room temperature; Rinsing with 3 times TBS every 5 minutes and continued with running water; and counterstain with hematoxillin Harris, and mounting with aqueous mounting medium.

The assessment of oral swab result using immunohistochemical dye to detect the presence of cell changes was interpreted with the following results; Cytokeratin 19 smear was considered positive if there was brown color in cell cytoplasm. Cytokeratin 19 smear was considered negative if there was no brown color in cell cytoplasm.

RESULTS

The observation on oral smear preparation of fixed orthodontic users dyed immunohistochemically resulted in the Table 1. Referring to Table 1, it could be seen that the percentage of positive sample is 50%. There were 15 samples with positive smear results and 15 samples with negative smear results. If we look at the duration of the fixed orthodontic usage, both samples who had been wearing orthodontic appliance for a long time and short time show various smear results.

Number of samples that gave positive results with the duration of appliance use of more than one year was 10, the number of sample with positive results with the duration of appliance use of less than one year was 5, sample with negative

Table 1. Results of immunohistochemical smear of oral swab samples.

No sample	The duration of fixed appliance usage		Result	
	Month	Year	Positive	Negative
1	6	1/2	√	
2	72	6	√	
3	3	1/4	√	
4	4	1/3		√
5	36	3	√	
6	15	13/4	√	
7	12	1		√
8	72	6	√	
9	54	4 1/2	√	
10	30	2 1/2		√
11	48	4	√	
12	12	1		√
13	12	1		√
14	10	5/6	√	
15	9	3/4	√	
16	36	3		√
17	36	3	√	
18	12	1		√
19	18	1 1/2		√
20	12	1	√	
21	36	3	√	
22	6	1/2	√	
23	48	4	√	
24	12	1		√
25	24	2		√
26	12	1		√
27	36	3		√
28	12	1		√
29	60	5	√	
30	36	3		√
Total			15	15
Percentage			50%	50%

results with the duration of appliance use of more than one year was 14, and sample with negative results with the duration of appliance use of less than one year was 1.

Based on the results of the study shown in appendix 1, in oral mucosal swab of fixed orthodontic users, the total number of cells exposed from 30 samples was 77.125 cells. The number of cells that give positive results (brown) from 30 samples was 3.666 cells.

The number of positive cells was compared to the total number of collected cells from 30 existing

Table 2. Percentage of positive cells.

No sample	Percentage	No sample	Percentage	No sample	Percentage
1	7.93	11	8.90	21	17.42
2	33.00	12	0	22	26.00
3	4.41	13	0	23	0
4	0	14	3.06	24	0
5	6.64	15	7.92	25	0
6	8.56	16	0	26	0
7	0	17	12.71	27	0
8	12.84	18	0	28	0
9	12.43	19	0	29	2.61
10	0	20	11.41	30	0

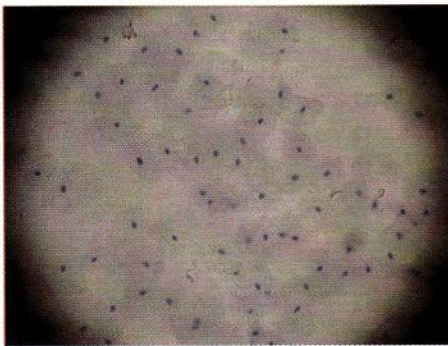


Figure 1. Result of negative smear (purple) with 100X magnification.

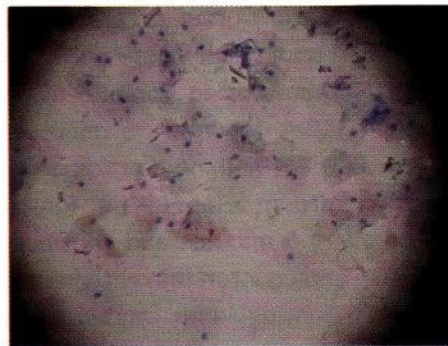


Figure 2. Result of thin positive smear (brown) with 100X magnification.

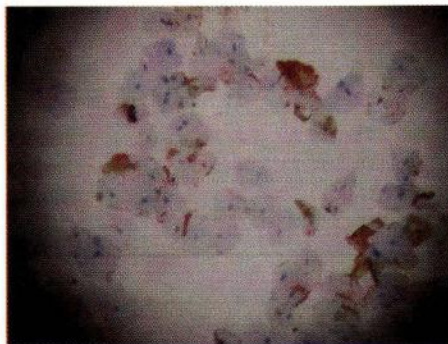


Figure 3. Result of thick positive smear (brown) with 100X magnification.

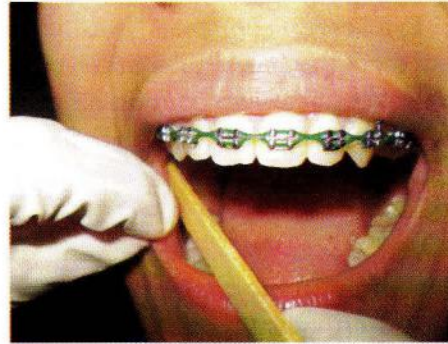


Figure 4. Procedure of buccal mucosa swabbing in research sample with wood spatula.

preparations that average total percentage for the presence of cytokeratin 19 in fixed orthodontic appliance users. Based on the calculation in this study, the average percentage of the presence of cytokeratin 19 in fixed orthodontic users is 5.86%.

Percentage positive cells from each sample

Microscopic examination showed a number of positive cells in each sample that was later compared to the total number of cells in the smear. The results

of the comparison can be observed in the Table 2.

The biggest positive cell percentage was found in sample number 2, i.e. 33.00% while the lowest percentage for positive cells was 2.61% found in sample number 29. From the data, sample number 2 with the highest percentage had been in orthodontic treatment for 6 years and the duration of the orthodontic appliance use of sample number 29 with the lowest percentage was 5 years.

DISCUSSION

Based on the results of this study, it was apparent that the positive result towards immunohistochemical smear using cytokeratin 19 antibody was found in 15 out of 30 samples. Of all samples, 50% show positive result. This shows that the use of fixed orthodontic appliance may cause changes in oral mucosal cells but not all fixed orthodontic appliance users show changing condition in oral mucosal cells.

Overall, by counting the number of total positive cells compared to the total cells retrieved from 30 existing samples, an average positivity percentage for cytokeratin 19 among fixed orthodontic appliance users was 5.86%. The result showed that there have been changes in fixed orthodontic appliance user cells but the change was still in a low level and the inflammation caused by orthodontic appliance components is not too severe.

The percentage of positive cells in each sample shows various results. The biggest percentage (33.00%) was found in sample who has been wearing fixed orthodontic appliance for 6 years and the lowest percentage (2.61%) was found in sample with a duration of fixed orthodontic appliance usage of 5 years. The following is the duration of wearing fixed orthodontic appliance in an order according to the biggest positive result: 6 years, ½ year, 3 years, 6 years, 3 years, 4 ½ years, 1 year, 4 year, 1 ¼ year, ½ year, ¾ year, 3 years, ¼ year, 5/6 years and 5 years.

This study shows that the presence of cytokeratin 19 in oral swab of fixed orthodontic appliance users is greatly varied in each individual. Samples with the duration of orthodontic appliance usage of 6 years produces a percentage of cytokeratin 19 of 33.00% but the low percentage (2.61%) is also found in sample who has used the orthodontic appliance for a quite long period, i.e 5 years. In samples who have been in orthodontic treatment for 4 years, there is no cytokeratin 19 found in the preparation but a positive result is gained from sample with a duration of orthodontic appliance usage of ¼ year (3 months)

There are several factors that may create this variations, both internally and externally. From time point of few, it should be that the use of fixed orthodontic appliance in long period should

create more significant changes, in line with the duration of contact between the orthodontic appliance components and oral mucosa. This is not true in the results in this study. Sample who has been using orthodontic appliance for 4 years does not give positive result. Four years is a quite long period to adapt, therefore the oral mucosa has adapted to the orthodontic appliance component that negative result is gained.

A different thing happens to sample who just uses the orthodontic appliance for 3 months but gives positive result on cytokeratin 19 dye. According to the mechanism of inflammation, the increase in the initial stage of the irritant exposure to reach a peak in a certain period is experienced and then it decreases after adaptation is reached. The use of a new orthodontic appliance, in this case 3 months, means that the sample is still in the period of adaptation where the inflammation process is still high.

The use of fixed orthodontic appliance creates friction and pressure to the oral mucosa directly. This will cause chronic irritation. Continuous irritation may stimulate over production of keratin.⁶ If the non-keratinized stratified squamous epithelium cells are ruptured because of a very strong stimulus, the stratum corneum will be thicker and the keratin layer will be formed.⁷ With over keratinization, leukoplakia maybe produced, which may be come a pre cancerous cells.

Epithelials are changed continuously through cell division in the base layer followed by cell release in the superficial layer. The cell homeostasis is reached when the differentiation and shedding of the cells on the upper layer of the epithelial is balanced by cell division at the base layer. In normal condition, oral epithelial continuously renewed to maintain the cell integrity. The basal cell performs mitosis activity balanced by cell shedding on the superficial surface Schroeder⁸, A lot of factors will change this balance that the epithelial becomes thicker (hyperplastic) or thin (atrophic) compared to normal. Continuous irritation is one of the factors of cell homeostasis imbalance.⁹

It is not rare that a patient who is on orthodontic treatment has poor oral hygiene. The difficulty to reach areas covered by fixed orthodontic appliance components using toothbrush and also

limited brushing movement makes toothbrushing not optimum. The areas that cannot be reached by toothbrush may experience plaque accumulation.¹⁰ The presence of plaque accumulation that creates retention for bacteria may cause a chronic irritation. In individuals who do not pay enough attention to their oral hygiene, plaque deposit or retention can be found and this will trigger inflammation.¹¹

As a reaction to a chronic irritation, an inflammation process occurs and the basal cells increase its rate of cell division. With a presence of an inflammation process, the number of progenitor cells will increase that the cell division rate increases.⁹ The progenitor cells are located in the epithelial base cell layer and are cells formed by stem cells and have the ability to do cell division.¹² Several base layer keratinocytes are progenitor cells that differentiate along with its journey to reach the surface above.¹³ Cytokeratin 19 expression becomes a marker for progenitor cells and shows a presence of cell changes.¹⁴

This study is an initial study on the changes in oral mucosal epithelial in fixed orthodontic appliance users using cytokeratin 19 antibody smear. Due to the presence of cytokeratin which shows tissue specification, cytokeratin can be used as (a) marker in diagnosing a malignancy and pre cancer state.¹⁵

The presence of cytokeratin 19 in oral mucosa swab from fixed orthodontic appliance users indicates the presence of changes in the epithelial cells due to increased number of progenitor cells caused by inflammation. Based on the data collected, a concept that inflammation plays a role in a tumour is born. Many cases in cancer starts from an infection, chronic irritation and inflammation.¹⁶ The positive result from this study can be used as initial detection of changes in epithelial cells before worse condition happens where the cell change has a potential to trigger malignancy. Therefore, to prevent an inflammation, it is very important to prevent neoplasm development and changes to malignant state.¹⁶

CONCLUSION

The study shows that in the oral swab from fixed orthodontic appliance users increased

progenitor cells marked by cytokeratin 19 is found. The percentage of positive cells for cytokeratin 19 smear is 5.86% of total existing cells. This may be due to stimulation and inflammation caused by the use of fixed orthodontic appliance in a certain period that leads to changes in oral mucosa.

REFERENCES

1. Foster TD. Buku ajar ortodonsi. 3rd ed. Jakarta: Penerbit Buku Kedokteran EGC; 1993.
2. Proffit WR. Contemporary orthodontics. 3rd ed. St. Louis: CV Mosby Co.; 2000.
3. Williams JK, Cook PA, Isaacson KG. Alat-alat ortodonti cekat: Prinsip dan praktik. Jakarta: Penerbit Buku Kedokteran EGC; 2000.
4. Scully C, Cawson RA. Atlas bantu kedokteran gigi penyakit gigi dan mulut. Jakarta: Hipokrates; 1991.
5. Koss LG. Diagnostic cytology and histopathology bases. 5th ed. Philadelphia: JB.Lippincott Co.; 2006.
6. Flaitz CM. Oral frictional hyperkeratosis. 2006 Available from: <http://www.emedicine.com>.
7. Fiore MSH. Atlas histologi manusia. 6th ed Jakarta: Penerbit Buku Kedokteran EGC; 1992.
8. Schroeder HE. Oral structure biology. New York: Thieme Medical Publishing Inc.; 1991.
9. Squier CA, Kremer MJ. Biology of oral mucosa and esophagus. JNCI Monographs 2001;29:7-15.
10. Lau PY, Wong RW. Risk and complications in orthodontic treatment. Hong Kong Dent J 2006;3(1):15-22.
11. Radunovic VV. Neural modulation of inflammatory reactions in dental tissues incidents to orthodontic movements. Euro J Orthod 1999;21:231-47.
12. Moharamzadeh K, Brook IM, Van Noort R. Tissue-engineered oral mucosa. A review of the scientific literature. J Dent Res 2007;86(2):115-24.
13. Michel M, Natalie T, Marie-Josée G. Keratin 19 as a biochemical marker of skin stem cells in vivo and in vitro. J Cell Sci 1996;109:1017-28.
14. Houghton JM, Morozov A, Smirnova I. Stem cells and cancer. Seminars in cancer biology 2007;17:191-203. Available from: <http://>

www.elsevier.com/locate/semcancer.

15. Ranganathan K, Kavitha R, Sawant SS. Cytokeratin expression in oral submucous fibrosis - An immunohistochemical study. *J Oral Pathol Med* 2006;35:25-32.
16. Coussens LM, Werb Z. Inflammation and cancer. *Nature* 2002;420:860-7. Available from: <http://www.nature.com/nature>.