

Potential of Red Spinach Leaves Ethanolic Extract (*Amaranthus tricolor* L.) as a Complementary Therapy For Hiperlipidemia: Study in Vivo of Histopathologic and Activity of Alanin Aminotransferase (ALT)

Dimas Adhi Pradana*, Irna Destya Anggriani, Tri Ratna Setyaningrum

Department of Pharmacy, Universitas Islam Indonesia

Keywords:
Amaranthus tricolor L., Alanin Aminotransferase, Hiperlipidemic, Complementary, Histopathologic

ABSTRACT: This study was conducted to determine the potential of ethanolic extract of red spinach leaves (*Amaranthus tricolor* L.) with control quality as a complementary treatment of hyperlipidemic based on histopathology and activity of alanin aminotransferase (ALT). A total of 24 male Wistar rats were randomized in 6 groups: normal group; positive control group were given the drug simvastatin; negative control group; 1st treatment group was given extract at dose of 400mg/kgBW rat, 2nd group was given extract at dose of 400mg/kgBW rat and simvastatin dose 0.18 mg/kgBW rat; 3rd treatment groups were given extract at dose of 800mg/kgBW rat and simvastatin dose 0.18 mg/kgBW rat. Induction hyperlipidemic using high fat diet and poloxamer. The data obtained were tested normality with the Shapiro-Wilk test. Statistical analysis using Oneway ANOVA and Post-Hoc Tukey HSD to determine the significance of differences between groups for ALT parameter. Result show the use of ethanolic extract of red spinach leaves can reduce fatty liver condition based on decreased level of ALT and liver histopathologic. It is concluded that the ethanolic extract of red spinach leaves dose 400mg/kgBW rat combine with simvastatin can reduce activity of ALT until 31.57 U1-1.

INTRODUCTION

Hyperlipidemia is defined as a condition of the high lipid concentration in blood which is characterized by an increase triglycerides, low-density lipoprotein (LDL), and blood cholesterol exceed normal limits in humans ie >200 mg/dl [1]. It is a risk factor that is known to cause fatty infiltration of the liver. This condition may progress to cirrhosis and liver failure. The induction of fat continuously can cause fat accumulation, steatosis, until necrosis and liver cirrhosis [2]. South Asian countries have a high prevalence of hyperlipidemia in line with

their economic development. Hyperlipidemia associated lipid disorders are considered to cause atherosclerotic, cardiovascular disease and also cirrhosis and liver failure [3].

Many physician prescribe drugs to reduce lipid plasma level using antihyperlipidemic drug, such as Simvastatin. However, the current use of a single lipid-lowering drugs was inadequate, making it necessary to obtain additional therapy.

The use of herbal medicine as a complementary therapy is growing rapidly in health care. It may happens because a lot of people who want a complementary or combination therapies to reducing the severity and minimize side effects.

*Corresponding Author: Dimas Adhi Pradana (Departmen of Pharmacy Universitas Islam Indonesia. Jalan Kaliurang km 14,5 Yogyakarta 55584 Indonesia) email: adhi_pradana85@yahoo.com

Article History:

Received: 16 Mar 2016
Published: 01 Nov 2016

Accepted: 23 Mar 2016
Available online: 20 Dec 2016

In Indonesia, herbal therapy as complementary therapies are most favored by the public, especially with the availability of herbal medicines in Indonesia.

Metabolic disorder due to the high fat content also affect the condition of fatty liver. To determine the level of fatty liver can use the ALT liver enzyme parameters to see increased activity occurs [4]. Fatty liver can also indicate the severity of which occurs in the liver. Lipid lowering drug like simvastatin proved effective, but found various reports by the FDA regarding adverse side effects when used in high doses and long-term [5].

Flavonoid found in red spinach leaves (*Amaranthus tricolor* L.) alleged to have effect antihyperlipidemia [6,7]. Based on previous studies, the activity of red spinach ethanolic extract a decrease in Low Density Lipoprotein (LDL) levels in male Wistar rats with dose 400 mg/kg BW [8]. Research on herbal medicine as a complementary therapy has not been found, so research must be done to clarify or prove the efficacy of herbal medicine. This study was conducted to determine the potential of ethanolic extract of red spinach leaves with control quality as a complementary treatment of hyperlipidemic in terms of parameters histopathology and activity of alanin aminotrasferase (ALT).

MATERIALS AND METHODS

Preparation of Plant Materials

This study used organic red spinach originating from Sembungan Wukirsari Cangkringan Sleman, Yogyakarta. This location has a height of land \pm 500 m above sea level with the coordinates of the location $-7^{\circ} 39' 37.48''$ $110^{\circ} 26' 21:44''$. Harvesting is done at the age of 25-35 days plant.

Red leaves of fresh spinach washed, aerated after it dried. Red spinach leaves that have been dried and then in the miller to form a powder and

then weighed as much as 20 grams in the bag filter paper. Then put into a soxhlet apparatus using 70% ethanol as a solvent, with a ratio of herb:ethanol 70%=1:10. It had done as much as 7 times the circulation. Results residue extract was concentrated by using a rotary evaporator at a temperature of 60°C speed of 60 rpm. Viscous extract obtained is then evaporated on a water bath to have a thick texture resembling pasta. Viscous extract then weighed and packed in a glass container and stored in a desiccator. Then do the determination of the quality control extracts [8].

Animal Model, materials and instrument

This study used male Wistar rats, healthy, age 2-2.5 months, body weight of 150-200 grams. Materials used in this study are the leaves red spinach (*Amaranthus tricolor* L.), distilled water, blue tip, 70% ethanol, methanol mobile phase: ethanol (2:1), filter paper, pure lard, masks, microtube, feed BR - II, poloxamer, ALT reagents, gloves, a set of instruments Atomic Absorption Spectrophotometer (AAS), silica gel F254, simvastatin, injection syringes, oral syringe.

Antihyperlipidemic test

Thirty male Wistar rats were divided into 6 groups with each group consisting of 4 rats, with the following distribution:

Group I (Normal Control): Rats fed a standard BR-II and water ad libitum for 16 days. Group II (Positive Control): Rats were Induced a high-fat diet for 16 days from the first day. On day 8, rats given lipid induction with poloxamer 1000 mg/kg BW. Then on the 12th day until the 16th given simvastatin 0.18 mg/kgBW rat. Group III (Negative Control): Rats were induced with a high-fat diet for 16 days from the first day. On day 8, rats given lipid induction with poloxamer 1000 mg/kg BW. Group IV (treatment 1): Rats were induced with a high-fat diet for 16 days from the first day.

On day 8 given induction poloxamer 1000 mg/kg BW. Then on the 12th day until the 16th, rats were given etanolic extract red spinach leaves dose of 400 g/kg BW rat. Group V (treatment 2): Rats were induced with high-fat diet for 16 days from the first day. On day 8 given induction poloxamer 1000 mg/kg BW. Then on the 12th day until the 16th rats were given etanolic extract red spinach leaves dose of 400/kg BW rat and simvastatin 0.18 mg/kg BW rat. Group VI (Treatment 3) Induced rats a high-fat diet for 16 days from the first day. On day 8 given induction poloxamer 1000 mg/kg BW. Then on the 12th day until the 16th rats were given etanolic extract red spinach leaves dose of 800 g/kg BW rat and simvastatin 0.18 mg/kg BW rat.

Histopatologic test

Macroscopic examination conducted on liver taken from test animals to determine the damage. Macroscopic conditions observed when surgery and liver organ harvesting. Macroscopic observation will check the physical condition of the fatty liver and compared it to normal liver. On microscopic examination carried out observations of changes in the liver cells and scoring the types of damage to the liver cells. Preparation, examination and interpretation of histopathological preparations were done in histopathological Laboratorum Pathology Veterinary, Universitas Gadjah Mada. The stages in the making of histopathologic preparations are as follows:

a) Trimming

Trimming is the steps being taken after fixation by cutting a thin tissue of approximately 4 mm thick with orientation according to the organ to be cut. Knife used for trimming are the scalpel blade no. 22-24.

b) Dehydration

Dehydration of the tissue carried out after trimming using a tissue processor. It is intended to remove the water contained in the tissue, using dehidran liquids such as ethanol or isopropylalcohol. Dehidran fluid then cleared from the tissue using a cleaning reagent such as xylene or toluene. Reagents cleaners will be replaced with paraffin by means of penetration into tissue. This process is called impregnation. Paraffin is used which has a melting point of 56-58 °C. Fluid in the tissue processor should be replaced every 1-2 weeks.

c) Embedding

After going through the process of dehydration, the tissues that are in embedding cassette is moved into a base mold, then filled with liquid paraffin, then placed on a wooden block or a cassette called block. The function of the block of wood is to the holder at the time the block is cut in the microtome.

d) Cutting

Cutting is cutting tissue that has been dehydrated by using a microtome. A sharp knife will produce good histological preparations, which microscopically characterized by the absence of artifacts such as vertical and horizontal strokes.

e) Staining/coloring

Coloring preparations using the technique of hematoxyline-eosin staining.

f) Mounting

After the tissue on the slide was colored, the next step is mounting material and covered with a coverglass prevent air bubbles.

g) The reading of the slides with a microscope slides are examined under a light microscope.

ALT Examination

ALT examination performed on days 0, and 17th day . A total of 100 (60) mL serum AST is added to the reagent mix 1000 (600) mL and mixed until homogeneous. Then incubated at room temperature (37°C) for 1 minute. Results can then be read using Spectrophotometer MicroLab 300, λ 340 nm using comparators aqudest.

RESULTS

The purpose of this study to determine the activity of ethanolic extract of red spinach leaves (*Amaranthus tricolor* L.) with control quality as complementary treatment of hyperlipidemia, based on histopathological parameters and ALT activity. Animal model used were 24 male

Wistar rats induced high-diet lipid (pure pork) and poloxamer. This study was approved by the Research Ethics Committee of the Faculty of Medicine Universitas Islam Indonesia Number 88/Ka.Kom.Et/70/KE/III/2015.

Quality Control Of Extract

The results of quality control testing extracts are used as a reference for the state that ethanolic extract of red spinach leaves produced have good quality. The test results are shown in Table 1.

Histopathologic parameters of liver

Histopathologic aims to study the conditions and state of the liver tissue function related to the incidence of fatty liver in test animals. Liver organ harvesting is done by sampling each group

Table 1. The results of quality control testing of red spinach extracts

No	Parameters	Results	Reference	Conformity
1.	Specific parameters			
	a. Organoleptic	smell : typical spinach	-	
		flavor : bitter		
		color : greenish black		
		texture : viscous		
	b. Rendemen	12.24%	-	
	c. Chromatogram pattern	Rf : 0.74-0.81	-	
	d. Levels of quersetin	29.29%	-	
	e. Levels of water soluble extract	24.38%	> 7% [9]	Suitable
	f. Levels of ethanol soluble extract	12.06%	> 2.5% [9]	Suitable
2.	Non-specific parameters			
	a. Specific gravity	1.388 g/ml	> water specific gravity (1 g/ml) [10]	Suitable
	b. Water levels	14.07%	5-30% [11]	Suitable
	c. 1) Total ash levels	15.03 %	< 10% [9]	Not suitable
	2) Acid insoluble ash content	0.51	< 1 % [9]	Suitable
	d. Microbial contamination	Negative	< 5x10 ² coloni/g	Suitable
	1) MPN koliform			
	e. Metal contamination	<0.096	< 10 mg/kg [13]	Suitable
	1) Pb			
	2) Cu	16.70	< 50 ppm [13]	Suitable

as much as once ie on day 17th.

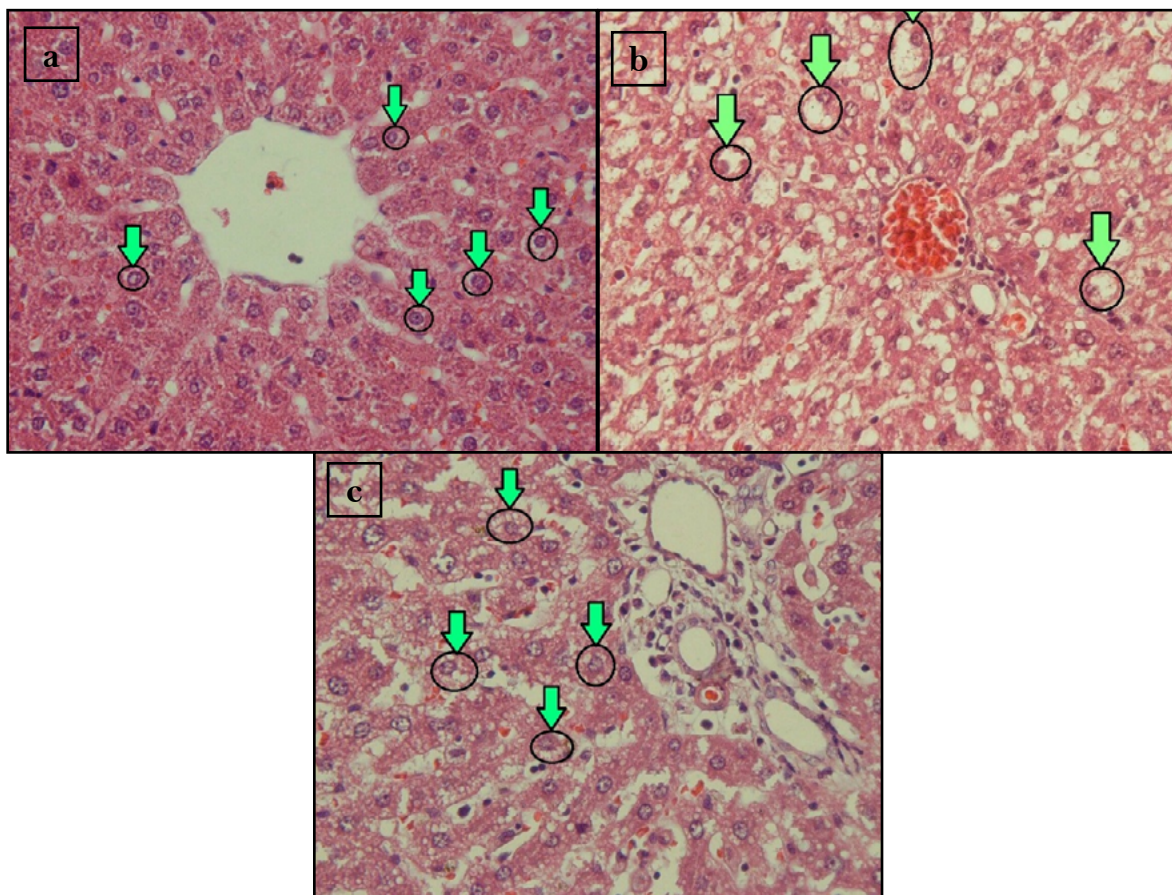
Fatty liver condition illustrated with clear boundary fat vacuoles in the cytoplasm [14]. Results of histopathological liver of rats taken by sampling are shown in Table 2 and Figure 1 .

Figure 1. show that in normal control group did not occur fatty indicated by a circle which is part of the nucleus that remains the focus lies in the middle of the cell or cells. In the negative group, found a magnification size of vacuoles then urged

the cell nucleus towards the cell edge. At a dose of 400 mg/kg extract combination with simvastatin group fatty liver condition also occur, but the severity less than negative group. It can be seen from the formation of liposit around the nucleus of the cell and have not led to the magnification of the size of the vacuoles. Negative control group showed that the induction of hyperlipidemia have been able to produce fatty liver comparison with normal group who have normal liver condition.

Table 2. Liver Hystopatologic Test Result

Group	Day 17th
Normal	Normal
Negative Control	Fatty degeneration
Positive Control	Normal
Dose 400 mg/kg BW	Normal
Dose 400 mg/kg BW + simvastatin	Normal
Dose 800 mg/kg BW + simvastatin	Normal



Picture 1. Hystopatologic Liver

Description: (a) normal control, (b) negative control, (c) extract dose of 400 mg + simvastatin
The arrows indicate the condition of the cell nucleus.

Table 3. Average Alanin Aminotransferase (ALT) levels

Group	Levels ALT (UI-1) \pm SD	
	Baseline	Day 17th
Normal Control	32.76 \pm 7.82	38.76 \pm 2.59 ^(a)
Negative Control	45.44 \pm 2.72	93.76 \pm 10.19*
Positive Control	38.47 \pm 10.15	42.05 \pm 8.43 ^(a)
Extract dose 400 mg/kg BW	42.80 \pm 5.45	32.32 \pm 6.66 ^(a)
Extract dose 400 mg/kg BW + simvastatin	40.90 \pm 6.86	31.57 \pm 9.69 ^(a)

Value significantly between groups based on test results oneway ANOVA ($p < 0.05$).

(a): a significant difference with the negative control ($p < 0.05$)

*: a significant difference compare with baseline based on paired sample T-test ($p < 0.05$)

While the extract group dosage of 400 mg/kg of simvastatin combination proved capable of inhibiting the occurrence of fatty liver fatty liver compared to the negative group.

Monitoring the activity of Alanin aminotransferase (ALT)

ALT activity average obtained by each group during capture footage shown in Table 3.

Based on table 3, we know that downward trend in ALT activity that occurs between the 3 treatment groups, it can be concluded that a given therapy can decrease the serum ALT activity significantly if compared with negative control. From these results it can be concluded that the use of red spinach leaves ethanolic extract will provide a better therapeutic outcome as a complementary therapy compared to monotherapy. Red spinach leaves ethanolic extract dose of 400 mg / kg BW combination with Simvastatin can lower ALT activity until 31.57 U1-1. It is better than the single administration of simvastatin or extract based on histopathologic parameters and ALT activity but not statistically significant ($p < 0.05$)

DISCUSSION

Liver plays an important role in lipoprotein metabolism. In addition to producing

apolipoprotein, the liver also produces enzymes and receptors involved in lipoprotein metabolism such as HMG CoA reductase and LDL receptor [15]. In addition, there is also Scavenger receptor class B type I (SR-BI) which is selective for the receptors and mediators obtain HDL contained in hepatic parenchyma, liver endothelial cells and Kupffer cells.

One of the clinical manifestations are due to disorders of fat metabolism of fatty liver (stetosis). Under normal condition, the liver fat in only 5% of the weight of the entire liver. Most of the fat in the liver in the form of triglycerides, phospholipids, cholesterol, fatty acids, and cholesterol esters. At fatty liver condition, fat in the liver can reach 50-60% of the weight of the whole liver [15]. Fatty liver cells suggests that there is an imbalance in the body's normal processes that affect lipid levels inside and outside the liver tissue as a result of a metabolic disorder.

Poloxamer is a surfactant agent which could potentially lead to hyperlipidemia. Although the detailed mechanism is unknown, but found elevated levels of cholesterol and triglyceride levels significantly in some of the test animals such as rats, mice and rabbits [16]. In addition, poloxamer also have the effect of fixing the damaged cell membranes using a lipid monolayer. X-ray results showed that in the low density lipid

amount, poloxamer will physically occupy the available area and the phase separation of lipids, forcing the lipid molecules to bind tightly and restore the barrier function of the membrane [17]. To induce hyperlipidemic especially fatty liver and ALT activities, we used poloxamer combine with lipid diet 2 ml/kg BW of rats. Ideally, the time required to induction of hyperlipidemia is 8-10 weeks with high-fat-diet [18]. Therefore combination with poloxamer which can trigger an acute response is expected to accelerate hyperlipidemia hyperlipidemia condition

ALT activity on day 17th is directly proportional to the histopathological results, whereas in the negative control group describes the state of the most abnormal condition. In the treatment group especially combination extract dose 400 mg/kg BW and Simvastatin, describe the better conditions from both 2 parameters.

Based on determination of standard parameter extracts result, it is known that red spinach ethanolic extract containing flavanoid especially quercetin 29.29%. A study by Zhu et al (2000) reported that natural compounds in flavonoids such as kaempferol, morin, misetin, and quercetin are varied activity of protection against a decrease of α -tocopherol in LDL [19]. Components of α -tocopherol in the form of vitamin E is what is known as primary antioxidants that protect LDL from oxidation. Results of another study also mentions that flavonoids function inhibits the formation of atherosclerotic plaques by increasing the synthesis of HDL in the body. Flavonoids may also reduce the activity of the enzyme HMG-CoA reductase inhibitors and apo-B in hepatocytes [20].

CONCLUSION

Ethanolic extract of red spinach combination dose of 400 mg / kg BW and simvastatin have the

ability to reduce the activity of ALT and fatty liver (histopathologic parameter) better than positive control, but not statistically significant ($p < 0.05$)

ACKNOWLEDGEMENT

Directorate Of Research and Community Service, Universitas Islam Indonesia.

REFERENCES

1. Ganong WF. (1991). Review of medical physiology. New York: McGraw-Hill Professional Publishing.
2. Nimer A, Kaita K, Mymin D, Levin C, Rooser B, Minuk G, (2000) Fatty Infiltration of Liver in Hyperlipidemic patient. Dig Dis Sci. 2000;34: 1929
3. Marella, S., Konda PY, Mohammad A, Nabi SA, Venkateshwarulu JKM, Natava R, Chippada AR. (2014). Antihyperlipidemic activity of the stem bark of *Boswellia ovalifoliolata* in high fat diet fed rats, International Journal Of Medical Plants, Photon 107 572-576
4. Huang, X. J., Choi, Y. K., Im, H. S., Yarimaga, O., Yoon, E., & Kim, H. S. (2006). Aspartate aminotransferase (AST/GOT) and alanine aminotransferase (ALT/GPT) detection techniques. Sensors, 6(7), 756-782.
5. FDA. (2015). Expands advice on statin risk [Internet]. 2014 [cited 2015 Jan 15]. Available from: www.fda.gov/forconsumers/consumerupdates/ucm293330.htm
6. Dalimartha S. (2008). Atlas tumbuhan obat Indonesia. Jilid 2. Jakarta: Trubus Agriwidya.
7. Wiranto WP. (2004). Memanfaatkan tanaman sayur untuk mengatasi aneka penyakit. Depok: Agro Media Pustaka.
8. Pradana DA, Rahmah FS,. (2015). Potensi Terapi Kuratif Hiperlipidemia Dari Ekstrak Etanolik Daun Bayam Merah (*Amaranthus Tricolor L.*) Terstandar Secara In Vivo Berdasarkan Parameter LDL (Low Density Lipoprotein), dipublikasikan dalam RAKERNAS dan PIT IAI 2015.
9. MENKES, (1989). *Materia Medika Indonesia*.IV. Jakarta: Departemen Kesehatan RI
10. DEPKES. (2000). Parameter standar umum ekstrak tumbuhan obat. Jakarta: Departemen Kesehatan RI: P 2, 5-6, 10-31
11. Saifudin A, Rahayu V, Teruna HY, (2001). Standardisasi bahan obat alam Yogyakarta: Graha Ilmu.
12. Badan Standardisasi Nasional. (2009). *Batas Cemaran Mikroba Dalam Pangan: 2009*
13. Widaningrum, Miskiyah, Suismono. (2007) Bahaya kontaminasi logam berat dalam sayuran dan alternatif pencegahan cemarannya. Buletin Teknologi Pascapanen. Balai Besar Penelitian dan Pengembangan Pascapanen Pertanian, 18-25.
14. Sukandar EY, Qowiyyah A, Larasati L. (2011). Efek ekstrak metanol daun binahong (*Anredera cordifolia* (Ten.) Steenis) terhadap gula darah pada mencit model diabetes melitus. J Med Planta, 1(4), 1-10.

15. Soemarto, Djanas S. (1999). Perlemakan hati: buku ajar ilmu penyakit dalam, Jilid I. III. Jakarta: Balai Penerbit FKUI.
16. Wasan KM, Subramanian R, Kwong M, Goldberg IJ, Wright T. (2003). Poloxamer 407-mediated alterations in the activities of enzymes regulating lipid metabolism in rats . J Pharm Pharm Sci, 6(2), 189-197.
17. Patel HR, Patel RP, Patel MM. (2009). Poloxamers : A pharmaceutical excipients with therapeutic behaviors. Int J Pharm Sci Reserch,1(2), 299-303.
18. Han JM, Lee JS, Kim HG, Seol IC, Im HJ. (2015). Synergistic effects of *Artemisia iwayomogi* and *Curcuma longa* radix on high-fat diest-induced hyperlipidemia in a mouse model. Journal of Etnopharmacology, 173, 217-224
19. Zhu YQ .(2000). Interaction between flavonoids and α -tocopherol in human low density lipoprotein. J Nutr Biochem, 11,14-21.
20. Redha A. (2010). Flavonoid: Struktur, sifat antioksidatif dan peranannya dalam sistem biologis. J Berlin, 9(2),196-202.