

Calcinosis and myocarditis in systemic lupus erythematosus patient

S Dewi, RG Wachjudi

Rheumatology Sub Division,
Department of Internal
Medicine, University of
Padjadjaran School of
Medicine/ Hasan Sadikin
Hospital, Bandung

Systemic lupus erythematosus (SLE) patients have multi-organ involvement related to their chronic inflammatory, autoimmune disease. *Calcinosis* can be clinical manifestations of SLE. Tissue calcinosis is reported in approximately 17% patients and myocarditis in 20-55% patients. Thus, both manifestations are not unusual in SLE. Tachypnea, tachycardia, pericardial effusion, and wheezing are often present and can be misleading in SLE patient.^{1,2}

Calcinosis is less common in SLE, sometimes it is found as an incidental radiological finding. Calcification in SLE maybe periarticular, within joints or muscles, or in the subcutis (calcinosis universalis).¹ Calcinosis is classified into four subsets: dystrophic, metastatic, idiopathic, or calciphylaxis/iatrogenic. When calcinosis cutis is isolated to a small area in extremities and joints, it is called calcinosis circumscripta; whereas its diffuse form, refers to calcinosis universalis, affects subcutaneous and fibrous structures of muscles and tendons. The pathophysiology of this condition is unknown and no effective therapy is currently available.^{3,4,5}

Systemic lupus erythematosus can involve the myocardium, pericardium, cardiac valves, and coronary arteries. Myocarditis in SLE is not likely to produce major regional wall motion abnormalities but may contribute to global left ventricular dysfunction.^{7,8}

We report a young woman with SLE who developed calcinosis and myocarditis.

CASE ILLUSTRATION

CASE REPORT

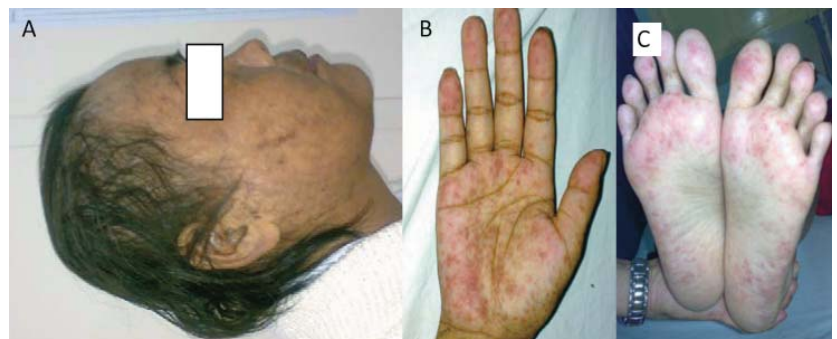A 23-year-old female presented with a history of severe fatigue, dyspnea, and dysphagia. Fatigue had developed over the past 3 months and had gotten worse upon exertion. She had dysphagia

from solid meals because of many oral ulcers in her mouth but she could still eat liquids. She also had chest pain associated with breath and dyspnea. She admitted a 20 kg weight loss and the occasional dizziness. She denied chronic cough with hemoptysis or bleeding per rectum. She reported oral ulcer exacerbation for the past 2 months, falling hair with alopecia for the past 10 years, chronic fatigue for the past 3 years, and also intermittent fever and amenorrhea for the past 2 months. She also complained of photosensitivity associated with ultraviolet light.

She was referred from another hospital with diagnoses of suspected pulmonary tuberculosis, anemia and fever, and lymphadenitis axillaries caused by tuberculosis in 1997.

The results of physical examination were as follows. She looked older than her stated age, emaciated and lethargic, mental state was somnolent, blood pressure was 104/60 mmHg, pulse rate was 120 times/minute, respiratory rate was 32-36 times/minute, and body temperature was 38.8°C. She had no lymphadenopathy. On head examination, there were alopecia areata (Lupus hair), pale conjunctiva, malar rash, and oral ulcer. There was no abnormality detected in ears, nose, and throat. On lung examination, the main respiratory sound was vesicular breathing in both lungs. there were rales in right and left thorax, decreased breath sounds, pleural friction rub in left thoracic, and there was no audible murmur or pericardial friction rub. The abdomen was supple on palpation, but we found the chessboard phenomenon and tenderness. The liver and spleen were not palpable and intestinal sound was normal on auscultation. On the extremities, there was vasculitis in palm and sole. There was not any arthritis or oedema.

Figure 1 A. Lupus hair and photosensitivity. B & C. Vasculitis of palm and soles



Laboratory studies disclosed the following values: haemoglobin 8.6 gr/dL, haematocrit 25%, leukocyte count was 13.200-30.300/mm³, platelet count was 170.000/mm³, erythrocyte sedimentation rate 120 / 138, blood glucose levels was 74/104mg/dL, blood urea nitrogen level was 45mg/dL, serum creatinine level was 1.7 mg/dL, Na level was 116 mEq/L, K level was 3.7 mEq/L, SGOT level was 126 U/L, SGPT level was 41 U/L. The urinalysis showed proteinuria (++) , erythrocyte (++++), leucocyte 5-11/high power field.

The first chest x-ray showed calcification but no cardiomegaly. Electrocardiogram showed sinus tachycardia with 120 times/minute. An ultrasonography of the abdomen showed mild hepatomegaly with ascites, there was no enlargement of paraaorta or parailiaca lymph nodes, bilateral pleural effusions, no abnormality in spleen, pancreas, kidney and ureter, and there was a cystitis.

She was admitted to the hospital with working diagnoses of pulmonary tuberculosis and abdominal tuberculosis, suspected SLE, and dehydration caused by low intake.

The patient was getting worst on the third day of hospitalization. The mental state become delirium, loss of consciousness, respiratory distress, arhythmias, bilateral pleural effusions, suspected pericardial effusion, and focal neurological deficit. The working diagnoses were changed into suspected hospital acquired pneumonia, pulmonary and peritonitis tuberculosis, suspected SLE, unconsciousness caused by meningitis tuberculosis with differential diagnoses of hyponatremia and neuropsychiatric lupus. She was subsequently given rehydration with normal saline and intravenous antibiotic. Afterwards the patient was consulted to rheumatologist.

The final diagnoses were established SLE with vasculitis, calcinosis and myocarditis based on the results of blood test of positive antinuclear antibody test with homogenous pattern and positive anti-double-stranded DNA (anti-ds DNA), 936.6 IU/ml (the significance was higher when the anti-ds DNA antibody level was >300 IU/ml) by ELISA method.

The patient was treated with broadspectrum antibiotics (2 gram ceftriaxone, single dose/day) and pulse dose of 1000 mg methyl prednisolone on the last day, but did not give any response. Her condition was deteriorated with infection and complication of the main organ (carditis). The patient had full arrest and was not able to be resuscitated. She died on the fifth day of hospitalization, before get the MRI, CT scan, and serial hemoculture examination, and also an adequate therapy.

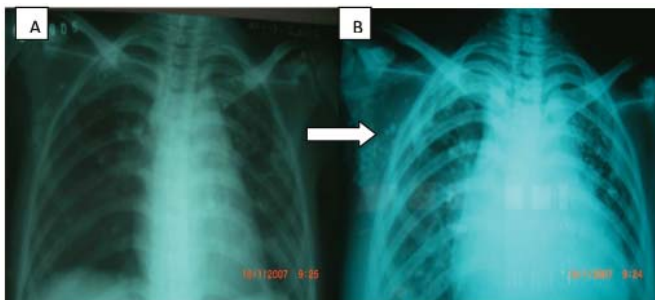


Figure 2 A. X-Ray on the first day of admission. B. X-Ray on the fourth day of admission

DISCUSSION

In this case we discussed about a young woman with SLE who developed calcinosis and myocarditis. Tissue calcinosis is reported in approximately 17% and myocarditis in 20-55% of patients with SLE. Thus, both manifestations are not unusual in SLE. Calciphylaxis and calcinosis can both cause severe morbidity and mortality in patients with SLE.^{1,2} It was hypothesized that in calciphylaxis and calcinosis, ongoing inflammatory activity contributes to the calcium deposition in the media of small arteries, as well as perivascular and periarticular tissues. The neuropsychiatric lupus with wide variety of conditions has been reported in association with SLE. Note that true cerebral vasculitis has been documented in SLE, but it is very uncommon. An example of an uncommon condition associated with SLE is severe cerebral calcinosis. Calcification in the basal ganglia has been reported in SLE at a higher incidence than in the general population, and in fewer cases, the cerebral cortex, cerebral white matter, thalamus, cerebellum, and brain stem are involved.^{3,4,5}

Cardiomegaly can be a result of SLE myocarditis, Libman-Sacks endocarditis, subacute bacterial endocarditis, uremia, pulmonary arterial hypertension with right-sided heart failure, or corticosteroid-related cardiomyopathy.^{6,7,8} Myocarditis may be clinically silent in up to 50% of patients and is an uncommon manifestation of SLE, consisting of myositis with perivascular infiltration by lymphocytes and neutrophils. Intimal proliferation within the smaller intramyocardial arteries with hyalinization has been reported. Transesophageal echocardiography helps define wall motion abnormality. The newer and faster magnetic resonance imaging in cine acquisition mode may allow noninvasive evaluation. In addition, exercise electrocardiography and myocardial scintigraphy may help define reversible ischemia, typically from accelerated atherosclerosis, that is amenable to surgery or intravascular therapy in SLE patients with symptoms of myocardial disease.^{6,7,8}

Exudative pericardial effusions and pericarditis occur in 17-50% of patients with SLE. Unless pericarditis is accompanied by effusion, echocardiography is insensitive for the diagnosis. Clinical symptoms and electrocardiographic findings may be helpful in the diagnosis of SLE pericarditis. Contrast-enhanced chest CT may reveal abnormal thickening and enhancement of the pericardium as well as a pericardial effusion.⁶⁻⁸

Patient with myocarditis may present tachypnea, tachycardia, hyperthermia or hypothermia, and hypotension. Sign of poor perfusion and heart failure such as tachycardia, weak pulses, decreased capillary refill, cool mottled extremities, jugular venous distention, lower extremity edema may also be found. Heart tones may include an S3 gallop and may be muffled if pericarditis is present. An additional sound can be found in lung examination. Although several types of dysrhythmias occur, the most common dysrhythmia is sinus tachycardia. A tachycardia faster than expected for the degree of fever (10 BPM for each degree of temperature elevation) may be indicative of myocarditis. Tamponade may result in hypotension, muffled heart tones, and distended neck vein (present in >50% of patients with tamponade). The ECG

shows tachycardia, low QRS voltages, flattened or inverted T waves with ST-T wave changes, and prolongation of the QT interval. Cardiomegaly may be found on CX-Ray.⁶⁻⁸

Autoimmune myocarditis, a chronic stage of myocardial inflammation, occurs in a small subset of patients after acute cardiotropic viral infection and can lead to dilated cardiomyopathy (DCM). The etiologies of myocarditis are multifactorial and genetically complex. Genetic linkage between susceptibility to myocarditis/DCM and the major histocompatibility complex (MHC) genes has been reported in both humans and experimentally induced mouse models. However, unlike other autoimmune diseases, the non-MHC genes seem to have greater impact than MHC genes on disease susceptibility. In humans, mutations/deletions in immunologically important genes such as CD45, and genes encoding cardiac proteins, have been reported in patients with recurrent myocarditis or DCM. Identification of genetic polymorphisms controlling autoimmune myocarditis will help us understand the mechanisms underlying autoimmune diseases in general, thereby improving potential therapies in patients.⁷

In this case, the patient had clinical characteristic for myocarditis on the last day of her life. The worsening of the disease activities with acute chest syndrome may be associated with myocarditis. The clinical characteristics of acute chest syndrome are fever (80%), cough (62%), chest pain (44%), and radiographic findings which developed in 2-5 days of hospital admission. She should have been treated for acute chest syndrome, including oxygen therapy if the patient is hypoxic, pain control to avoid splinting, fluid therapy at maintenance rates (do not overload), broad spectrum antibiotic such as cefuroxime and macrolide, bronchodilators, furosemide (no digoxin as this may increase cytokines and mortality), dopamin, dobutamine, and nitropruside, pulse dose steroid and cyclosporine, and pericardiocentesis if unstable.⁹

The leukocytosis in this case should be evaluated for many causes, infection or other causes (dehydration, steroid induced, etc). In this case, the blood culture only made on the first

admission, and the result was sterile. We should have made the serial hemocultures to found the microorganism, analysis of the sputum, cultures of the sputum, etc. The result of urinalysis (proteinuria (++) , erythrocyte (++++), leucocyte 5-11/high power field) made the suspicion of kidney involvement came into view, but more information such as measurement of 24-hours was needed. In this case we have no more data, because the patient died before the examination.

There are many limitation in this case: 1) Some laboratory findings are missing: no data for serial hemocultures, 24-hour proteinuria, and other autoantibodies (especially antiphospholipid), 2) The patient developed neurologic manifestations, but MRI or CT was not performed, and 3) We have no any information regarding post-mortem examination, because we did not do the test.

The management of SLE patients depends on the organ involvements, disease activity, and time of establishing the diagnoses. In this case, the diagnoses and the management were missed and delayed. We must be aware for early diagnose of SLE in young woman with the skin abnormalities (lupus hair, vasculitis, calcinosis, etc), and many organ involvement such as lung (pleuritic/pneumonitis), cardiac (myocarditis), kidney (nephritis), and neurologic manifestations, to avoid the delay in the adequate management. In this case, the patient should have been diagnosed earlier and therefore received adequate therapies.⁹

SUMMARY

Systemic lupus erythematosus is a complex autoimmune disease with multisystem involvement. The patients with SLE and calcinosis may increase the severity of disease and can spread to other organs and cause other diseases such as myocarditis. This condition may lead to a life threatening disease and therefore it is crucial to receive an immunosuppressant therapy as soon as possible to save their lives. We can use a set of recommendations for monitoring SLE patients in routine clinical practice. The use of a standardized core set to monitor SLE patients should facilitate clinical practice, as well as the quality control of care for SLE patients.

REFERENCES:

- Wallace DJ, Hahn BH, editors. *Dubois' lupus erythematosus*. 7th ed. Philadelphia: Lipincot Williams & Wilkins; 2007. p. 621-1223.
- Tsokos GC, Gordon C, Smolen JS, editors. *Systemic lupus erythematosus: a companion to rheumatology*. 1st ed. Philadelphia: Mosby Elsevier; 2007. p. 498-508.
- Tristano AG, Villarroel JL, Rodriguez MA, Millan A. Calcinosis cutis universalis in a patient with systemic lupus erythematosus: case report. *Clin Rheumatol* 2005;25:70-4.
- Boulman N, Slobodin G, Rozenbaum M, Rosner I. Calcinosis in rheumatic diseases. *Arthritis & Rheumatism* 2005;34:805-12.
- Ogretmen Z, Akay A, Bicakci C, Bicakci HC. Calcinosis cutis universalis. *J Eur Acad Dermatol Venereol* 2002;16(6):621-4.
- Li HS, Ligons DL, Rose NR. Genetic complexity of autoimmune myocarditis. *Autoimmun Rev* 2008;7(3):168-73.
- Woo SI, Hwang GS, Kang SJ, Park JS, Lee YS, Lee YH, and Tahk SJ. Lupus myocarditis presenting as acute congestive heart failure: a case report. *J Korean Med Sci* 2009;24:176-8.
- Mosca M, Tani C, Aringer M, Bombardieri S, Boumpas D, Brey R, et al. EULAR Recommendations for monitoring systemic lupus erythematosus patients in clinical practice and in observational studies. *Ann Rheum Dis* 2009;10:1136-72.