

Chronic Osteomyelitis of Wrist Joint in An Immunocompromised Host

Amanda P Utari¹, Dina Oktavia¹, Sumaryono², Bambang Setyohadi²

¹Department of Internal Medicine, Faculty of Medicine University of Indonesia, Jakarta

²Division of Rheumatology, Department of Internal Medicine, Faculty of Medicine University of Indonesia/Cipto Mangunkusumo General Hospital, Jakarta

Osteomyelitis is heterogeneous in its pathophysiology, clinical presentation, and management. Osteomyelitis is generally categorized as acute or chronic based on histopathologic findings, rather than duration of the infection. Necrotic bone is present in chronic osteomyelitis, and symptoms may not occur until six weeks after the onset of infection.¹ Epidemiology of chronic osteomyelitis is less well characterized compared with acute osteomyelitis.

Adult osteomyelitis most commonly arises from open fractures, diabetic foot infections, or the surgical treatment of closed injuries. Hematogenous osteomyelitis accounts for approximately 20% of cases of osteomyelitis in adults. It is more common in males regardless of age. Although rare in adults, it most frequently involves the vertebral bodies.² *S. aureus* is the most common isolate in all types of bone infection and is implicated in 50-70% of cases of chronic osteomyelitis.³

CASE REPORT

A 42-year old male came to hospital with progressive vomiting and weakness since two weeks before admission. The symptoms began three days after he got four kinds of drug from a doctor, as treatment for his chronic cough and abscesses on his right hand.

One and a half year ago, his right hand suddenly swelled. The swelling extended and reached his upper arm. He started to feel feverish, especially at night. Painful suppurating abscesses occurred on the back of his right hand a year later. The pus was white, thick, mixed with blood, but was not malodorous. Three months before admission, he noticed that his hand was “drop”. He could not move his right wrist. He had lost approximately 30 kilograms of body weight during his illness. Two weeks before admission, he consulted a doctor and was given four kinds of drug which had to be taken for six months. After a few days, he noted that his urine coloring turned red. The fever subsided and the pus diminished, but he started to feel nauseous and vomited, which was the main reason of his visit to the hospital.

Twenty years ago, distal part of the third finger of his right hand was accidentally cut by a machine. He did not realize that the finger was cut until he was told.

The patient had been married for 19 years and had a healthy 8-year old daughter. He once worked in a parking lot but had been jobless for six months. He had been smoking for about twenty years. He sometimes consumed alcoholic drinks. He also admitted that he had been doing free sex.

The patient looked ill and weak. He was 168 centimetres tall and weighted 39 kilograms. On examination, his blood pressure was 120/70 mmHg, heart rate of 120 bpm and respiratory rate of 28/minutes. His temperature was 37°C. The skin was dry and xerotic. There were multiple hypopigmented macules of various size with greasy white scales along the body. No anaesthetic or pain sensation on the lesions. He has noticeable paleness of his conjunctivae. Lagophthalmus could be seen when eyes were closed. No oral thrush was found. Percussion detected dullness below the fifth costae on both lungs. Lung auscultation revealed vesicular breath sound with crackles on both lungs. Heart rhythm was regular without murmurs or gallops. There was no abnormalities in the abdomen. There were bilateral pitting edema on the foot.

Local examination of the right hand noted that his wrist was slightly swollen, erythematous in appearance, and very tender to palpation. He could not move his wrist. There were deformity and subluxation of the joint to the ulnar side. There were also three atrophic scars on the dorsal of the wrist joint, which were once the pus-secreting abscesses. The distal segment of third finger of right hand was mutilated. Sensory of all fingers were considered intact.

On the anterior part of his right lower leg, there was a linear scar, about 14 centimetres long, without sign of inflammation. Enlargement of right auricularis magnus nerve and right ulnar nerve were palpated. Left lateral peroneus nerve and left posterior tibial nerve were also enlarged and tender to palpation. His toe nails had ragged appearance with yellow discoloration, onychodystrophy, and subungual hyperkeratotic.

Blood was obtained for initial laboratory analysis and the results were as follow: hemoglobin 11,1 g/dl; haematocrite 34%; leukocyte 12,200/μl, thrombocyte 574,000/μl, ESR 8 mm; MCV 73,3; MCH 24; MCHC 32,8, SGOT 27 U/l, SGPT 14 U/L, albumin 1,4 g/dL, globulin 2,7 g/dL, random blood glucose 87 mg/dl, CRP 48,3; sodium 124 meq/L; potassium 3,54 meq/L; and chloride 101

meq/L. Chest x-ray showed chronic active tuberculosis of the lungs with bilateral pleural effusion (Figure 1).

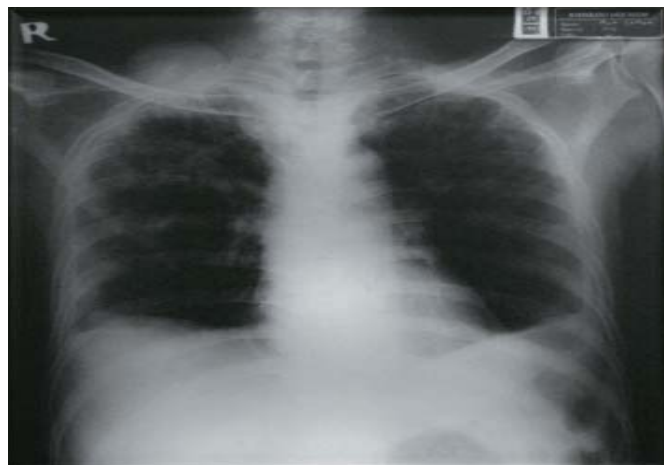

Figure 1. Bilateral Pleural Effusion

Plain film of right manus region gave an impression of septic arthritis of the right wrist joint with subluxation of distal segment of radiocarpal-ulnecarpal joint to the volar and ulnar sides, deformity of distal phalang of third finger, disused osteoporosis of manus bone, and calcification of soft tissues in volar side of distal antebrachii. There was also destruction in a third distal part of radius-ulnar (epi-metaphysis), carpal, and metacarpal, with less defined borders. Joint space was narrowing. These appearances were concluded as osteomyelitis (Figure 2).

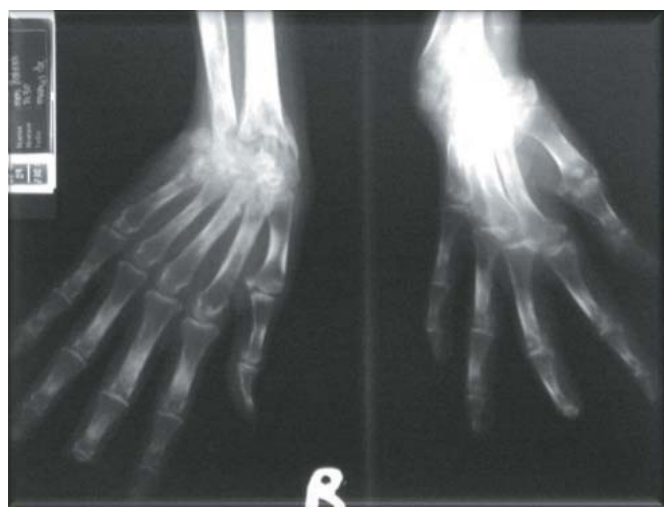

Figure 2. Radiologic photo of hands with osteomyelitis

Based on clinical manifestations and initial workup, the patient was diagnosed with: osteomyelitis of wrist joint and pulmonary tuberculosis. He was treated with antimicrobial cefotaxime iv 1 gram tid and levofloxacin iv 500 mg qd, sucralfate 100 mg qid, omeprazole 1x40 mg iv, ondansetron 3x4 mg iv, and NaCl 0,9% 500 cc/8 hours. Antituberculosis drugs (ATD) were temporarily discontinued because of severe vomiting.

During follow-up, gram staining of sputum specimen

showed the presence of positive cocci and negative bacilli. Acid-fast staining of sputum resulted negative. Sputum culture could not be done at the moment for technical reason. AntiHIV screening test gave out negative result. CD4 cells count was low (198 cells/mm³).

TB drugs were then given by titration. After several days of titration the patient received full dose of antituberculosis drugs, which consisted of rifampicin 300 mg, isoniazid 300 mg, and ethambutol 1000 mg. Patient could not tolerate pyrazinamide because nausea and vomiting recurred with 500 mg of pyrazinamide. Streptomycin 750 mg im qd was then added into the regimen.

The hypopigmented macules were diagnosed as pityriasis versicolor and were given ketoconazole solution. After nearly three weeks of therapy, exfoliation of the skin became more visible. No itch, redness, or blisters. The skin disorder was diagnosed as pityriasis versicolor and was treated with ketoconazole and selenium sulfide 1,8% solution. During follow up, the skin lesions did not improve. Specimen from toe nails were also taken. KOH smears of skin specimen resulted negative, but acid-fast staining gave out positive result with bacterial index 15/6 and morphology index 0%. Patient was classified as lepromatous leprosy with grade II deformity and acute neuritis. He was treated with clofazimin 300 mg daily and dapson 100 mg daily. KOH smears of nails specimen discovered the presence of hyphae and arthrospore. Culture grew colonies of candida and *fusarium sp.*

Surgery was conducted during hospitalization. Surgical procedure included debridement, arthrodesis, and installation of T-plate. Intraoperative biopsy of the bone was performed, but bone culture could not be done. Histopathologic examination of biopsy specimen revealed bone tissues, necrotic bone/ sequestrum, and infiltration of chronic inflammatory cells and neutrophil. No signs of specific inflammation. The conclusion was chronic osteomyelitis (Figure 3). Patient was discharged after his condition improved.

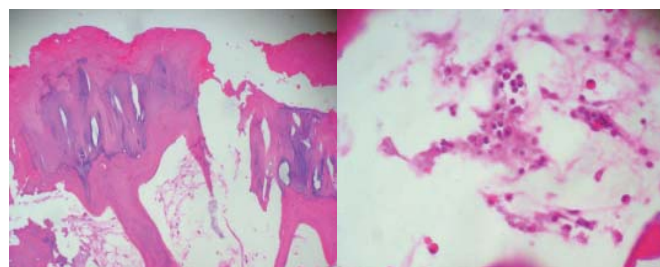


Figure 3. Histopathologic appearance

DISCUSSION

Diagnosis of chronic osteomyelitis was based on medical history, physical examination and diagnostic tests. According to patient's signs and symptoms, osteomyelitis had probably started 1.5 years ago when the swelling occurred. Osteomyelitis should be suspected in anyone with bone pain who has a past history of trauma or orthopedic surgery. Patients generally exhibit malaise, anorexia, weight loss, fever, night sweats, and often complain of persistent pain and drainage through sinus tract. Walenkamp described a classic history as cyclical pain, increasing to "severe deep tense pain with fever" that

often subsides when pus breaks through in a fistula.³ In our patient, the presence of structural deformities of the right hand was noted. The hand looked swelled and erythematous. There were three atrophic scars, which were said to have been drained of pus on the dorsal side. Classically, the cardinal signs of inflammation are redness, tenderness, heat, and swelling. If these signs are noted on physical examination, it be concluded that an infection is present. However, as with the history, signs of an actual osteomyelitis are often difficult to be distinguished from those of an overlying soft tissue infection. Suspicion of a bone infection may be confirmed by the presence of exposed necrotic bone, surgical hardware, or active fistulas.³ At the moment, there were no exposed bone, surgical hardware, or active fistulas found. Pus secretion had ceased to flow approximately ten days before admission.

Laboratory test indicating systemic inflammation should be a sensitive marker for infection. However, this should not be the case in chronic osteomyelitis, which is a disease characterized by devitalized tissues and a muted inflammatory response. The WBC counts and acute-phase reactants, such as ESR, ferritin, and CRP, are often normal in cases of chronic osteomyelitis.³ His leukocyte, ferritin, and CRP were elevated, but his ESR was within normal limit. Nutritional parameters such as albumin, prealbumin, and transferrin, are helpful in the workup of a patient with suspected chronic osteomyelitis so that malnutrition can be identified and managed.³

Plain radiographs play a significant role in the workup of chronic osteomyelitis. Plain radiography has a reported sensitivity and specificity of 43% to 75% and 75% to 83% respectively. Radiographic findings of chronic osteomyelitis can be subtle and include osteopenia, thinning of the cortices, and loss of the trabecular architecture in cancellous bone. Sequestra appears radiodense relative to normal bone.³ In our case, findings that were suggestive for osteomyelitis had been obtained from plain radiographs, so that other imaging modalities, such as CT or MRI, were considered unnecessary. In cases where plain radiographs failed to show characteristic features of osteomyelitis, a more sophisticated imaging modality should be pursued. Choices include CT, bone scintigraphy, and MRI (table 1). Ultrasound examination may also be helpful in detecting abscess and surface abnormalities of bone.

Table 1 Accuracy of diagnostic imaging for the assessment of chronic myelitis⁴

Diagnostic methods	Sensitivity	Specificity
FDG-PET	96%	91%
Bone scintigraphy	82%	25%
Leukocyte scintigraphy	61%	77%
Bone + Leukocyte	78%	84%
MRI	84%	60%

According to Waldvogel, osteomyelitis can be classified into hematogenous or contiguous-focus, acute or chronic, and with or without vascular insufficiency. An alternative classification by Cierny and Mader (Cierny-Mader Staging

System) considers the quality of the host, the bone's anatomic nature, treatment factors, and prognostics factors. This classification system is helpful in determining if treatment should be simple or complex, curative or palliative, and limb sparing or ablative (table 2).⁵

Table 2 Cierny-Mader Staging System of Osteomyelitis⁵

Anatomic type	Physiologic class
Stage 1: Medullary osteomyelitis	A host healthy
Stage 2: Superficial osteomyelitis	B host
Stage 3: localized osteomyelitis	Bs: systemic compromise
Stage 4 : diffuse osteomyelitis	Bl: local compromise
	Bls : local and systemic compromise

Factors affecting immune surveillance, metabolism and local vascular

Systemic factor (Bs): malnutrition, renal or hepatic failure, diabetes mellitus, chronic hypoxia, immune disease, extremes of age, immunosuppression or immune deficiency

Local factors (Bl): chronic lymphedema, venous stasis, major vessel compromise, arteritis, extensive scarring, radiation fibrosis, small vessel disease, neuropathy, tobacco abuse

In this case, the type of osteomyelitis was diffuse so it was classified into stage 4. Etiology of diffuse osteomyelitis includes trauma, hematogenous, or contiguous soft tissue infection. Chronic osteomyelitis in this patient was considered to be hematogenous because of the absence of open fracture or wounds in the hand. Patient was classified into physiologic class B because he had systemic compromised condition (malnutrition and immunodeficiency). Stage 4 requires debridement, stabilization, dead-space management, second-stage reconstruction, and antibiotics. The goal of treatment for a B host is to remove the compromising factors that distinguish them from an A host.⁶

Bone infection in the adult population is much more likely to be exogenous in origin than hematogenous because the predilection for bacterial seeding of bone ceases with closure of the epiphyses. For this reason, hematogenous osteomyelitis is rare in people beyond their teens, occurring only in immunocompromised hosts.³ The possibility of patient having immune deficiency syndrome has been considered early on the course of treatment. The patient was undernutrition with low body mass index and hypoalbuminemia, but his HIV screening tests return negative though his CD4 cells count was low. Immunosuppression may occur as a biologic complication of another disease process. Diseases in which immunodeficiency is a common complicating element include malnutrition, neoplasms, and infections. Our patient was underweight and suffered for chronic infection. Deficient intake of protein, fat, vitamins, and minerals will cause some metabolic derangements that inhibit lymphocyte maturation and function. Deficient humoral immunity usually results in increased susceptibility to infection by pyogenic bacteria (otitis, pneumonia, meningitis, osteomyelitis), whereas defects in cell-mediated immunity lead to infection by viruses, atypical mycobacteria and other intracellular microbes. Immunodeficiency state is a significant predisposing factor

for lung tuberculosis, fungal infection, and leprosy suffered by the patient. On the contrary, chronic infection gives large contribution to the generation of immunodeficiency state.⁷

Mycobacterium tuberculosis is a very possible pathogenic cause of osteomyelitis of wrist joint in this patient. This form of TB presents typically 3-5 years after the initial respiratory infection, with the haematogenous spread at that initial infection. The infection usually originates in the metaphyseal bone marrow and crosses the epiphysis to the joint.⁸ In this patient, chest x-ray is suggestive for tuberculosis with bilateral infiltrates and effusion. Those with CD4 counts < 200 cells/mm³ are more likely to have atypical infiltrates (lower lobe predominance, adenopathy, absence of cavities), extrapulmonary disease in up to 60%, or disseminated disease.^{9, 10} Acid-fast staining of sputum resulted negative for three samples. Negative smears are more likely to occur in person with low CD4 counts since organism-laden cavities are less likely to occur at low CD4 counts.¹⁰ The fact that patient's condition improved after administration of antituberculosis drugs was a supporting evidence in the consideration of tuberculosis as the etiology. Once considered, a clinical diagnosis should be supported by mycobacterial culture from the affected area. Synovial fluid culture for *M. tuberculosis* reported a sensitivity of 79%, whereas synovial tissue culture had a sensitivity of 94%.¹¹

Other potential agents are pathogens that commonly cause hematogenous osteomyelitis. A solitary pathogenic organism is usually recovered from bone. In adults, *Staphylococcus aureus* is the most common cause. It is isolated in 50% cases of hematogenous osteomyelitis.⁶ We gave empirical antibiotic treatment with cefotaxime and levofloxacin. The available literatures on the treatment of osteomyelitis is inadequate to determine the best agent, route or duration of antibiotic therapy. Most studies treated patients for six weeks.¹²

Leprosy is another possible cause of osteomyelitis. The type of leprosy is lepromatous leprosy, in which the cell-mediated response to the organism is poor. It is well explained by the immune status of the patient. Bone changes in leprosy are divided into two groups, specific and secondary changes. Specific lesions are due to the direct involvement of bone by the organism, whereas secondary lesions are the result of trauma and infection. Specific bony lesions in leprosy are rare with an incidence of 3% to 5% among hospitalized patients.¹³ Various studies have shown incidence of overall bone changes in leprosy to be ranging from 82.9 percent to 91 percent. The common sites of predilection for bone damage in leprosy are the small bones of hands and feet followed by bones of the face. Bone involvement is more common in lepromatous type.¹⁴ But, leprosy mainly involves the proximal and the middle phalanges.

Confirmation of the presence of osteomyelitis requires a combination of radiologic, microbiologic and histopathologic tests. Histopathologic and microbiologic examination of bone is the gold standard for diagnosing osteomyelitis. In this patient, plain radiograph of wrist joint is sufficient to diagnose osteomyelitis of wrist joint. Unfortunately, microbiologic examination has never been performed. Specimen for microbiologic examination is planned to be taken at the same

time with debridement procedure. *Debridement* is delayed because of TB. Effective antibiotic therapy should be started before surgery for tuberculosis. ATD should be started at least three weeks before surgery. Dissemination of the disease has been reported when surgery was done without adequate chemotherapeutic coverage.^{15, 16} In this case, postponement of surgical procedure takes longer than three weeks because the administration of antituberculosis drugs was interrupted due to drug induced hepatitis.

Diagnosis of chronic osteomyelitis can be definitively made only by intraoperative biopsy. Biopsy in our patient revealed chronic osteomyelitis without signs of specific inflammation. Histologic evidence of mycobacterial infection will need the presence of granulomatous inflammation, although its presence is not specific for mycobacterial infection. Granuloma formation is induced by interferon gamma, which is secreted by the CD4 + T cells. In HIV-infected people whose CD4+ T cells are progressively destroyed, the ability to form granulomas is occasionally retained with no apparent CD4+ T cells available. This patient was not infected by HIV, but his CD4+ T cells are below 200. It could be an explanation for the absence of granuloma in this patient. Culture of bone biopsy should have been done because it yields a microbiologic diagnosis in 94% of cases.¹⁷ But this time it could not be done because of technical reasons.

SUMMARY

This unusual case of osteomyelitis became more complicated because of the patient's immunodeficient condition. Regrettably, the case lacked of microbiological evidence. Despite the absence of granulomas in bone biopsy specimen, we could not decide whether osteomyelitis was caused by common microorganism or by *Mycobacterium sp.* Clinically, the patient's condition improved with the administration of ATD.

REFERENCE

1. Hatzenbuehler J, Pulling TJ. Diagnosis and Management of Chronic Osteomyelitis. *Am Fam Physician*. 2011;84(9):1027-33.
2. Lew DP, Waldvogel FA. Osteomyelitis. *Lancet*. 2004;364:369-79.
3. Rodner CM, Browner BD, Pesanti E. Chronic Osteomyelitis. In: Jupiter JB, Browner BD, Levine AM, Trafton PG, eds. *Skeletal Trauma: Basic Science, Management and Reconstruction*. 3 ed. Philadelphia: Saunders; 2003:483-506.
4. Termaat MF, Rajmakers PGHM, Scholten HJ, Bakker FC ea. The Accuracy of Diagnostic Imaging for the Assessment of Chronic Osteomyelitis: Systematic Review and Meta-Analysis. *Journal of Bone and Joint Surgery*. 2005;87:2464-71.
5. Lipsky BA, Berendt AR. Osteomyelitis. *ACP medicine*; 2010.
6. Calhoun JH, Manring MM. Adult Osteomyelitis. *Infect Dis Clin N Am*. 2005;19:765-86.
7. Congenital and Acquired Immunodeficiencies In: Abbas AK, Lichtman AH, Pillai S, eds. *Cellular and Molecular Immunology*. 6th ed. Philadelphia: Saunders; 2007.
8. Vuyst DD, Vanhoenacker F, Gielen J, Bernaerts A, Schepper AMD. Imaging features of musculoskeletal tuberculosis. *Eur Radiol*. 2003;13:1809-19.

9. JE Kuhlman. Imaging pulmonary disease in AIDS: state of the Art. *Eur. Radiol.* 1999;9:395-408.
10. Johnson MD DC. Tuberculosis and HIV Infection. *Dis Mon.* 2006;52:420-7.
11. Gardam M, Lim S. Mycobacterial Osteomyelitis and Arthritis. *Infect Dis Clin N Am.* 2005;19:819-30.
12. Lazzarini L, Lipsky BA, Mader JT. Antibiotic treatment of osteomyelitis: what have we learned from 30 years of clinical trials? *Int J Inf dis.* 2005;9:127-38.
13. P Moonot, N Ashwood, Lockwood D. Orthopaedic complications of leprosy. *J Bone Joint Surg.* 2005;87-B:1328-32.
14. Choudhuri H, Thappa DM, Kumar RH, Elangovan S. Bone changes in leprosy patients with disabilities/deformities (a clinico-radiological correlation). *Indian J Lepr.* 1999;71:203-15.
15. Salem B. Disseminated tuberculosis following the placement of ureteral stents: a case report. *Cases Journal.* 2008;1(383):1-4.
16. Marschall J, Evison JM, Droz S, Studer UC, S. Z. Disseminated tuberculosis following total knee arthroplasty in an HIV patient. *Infection.* 2008;36:274-8.
17. Sia IG. Osteomyelitis. *Best Practice & Research Clinical Rheumatology* 2006;20:1065-81.

