

EFFECT OF PLATELET RICH PLASMA (PRP) TO AUTOGENOUS BONE GRAFT

Iswinarno Doso Saputro, Magda Rosalina Hutagalung, Siti Isya Wahdini

Department of Plastic Reconstructive and Aesthetic Surgery, Faculty of Medicine,
Universitas Airlangga, Dr. Soetomo Hospital, Surabaya, Indonesia

ABSTRAK

Penggunaan cangkok tulang dalam bedah maksilofasial saat ini sedang mengembangkan, meskipun beberapa masalah masih bertahan. Salah satu solusi yang menjanjikan untuk masalah adalah penerapan platelet plasma kaya yang dapat mempercepat penyembuhan jaringan lunak dan pembentukan tulang. Penelitian ini bertujuan untuk memberikan pemahaman dasar untuk pengembangan aplikasi PRP dalam penyembuhan tulang di mana cangkok tulang diterapkan pada maksila manusia. cacat tulang dilakukan pada maksila kelinci albino, dengan penerapan cangkok tulang di kelompok kontrol dan cangkok tulang ditambah PRP pada kelompok perlakuan. Analisis histopatologi dilakukan pada kedua kelompok untuk menilai kepadatan osteoblas dan daerah jaringan kolagen. Pada hari ke-21, lebih kepadatan osteoblas dan daerah kolagen pada kelompok perlakuan diamati secara signifikan ($p < 0,05$, 95% confidence interval). Pengamatan dilakukan pada pembentukan kalus keras. Dalam kesimpulan, trombosit plasma kaya dapat meningkatkan kepadatan osteoblas di kelinci rahang atas cangkok tulang

Kata kunci: trombosit plasma kaya, cangkok tulang, penyembuhan tulang

ABSTRACT

Bone graft use in maxillofacial surgery is currently developing, though some problems still persist. One of promising solutions to the problems is application of platelet rich plasma which may accelerate soft tissue healing and bone formation. This study aims to provide basic understanding to the development of PRP application in bone healing where bone graft is applied on human maxillae. Bone defects were made on maxillae of albino rabbits, with an application of bone graft in control group and bone graft plus PRP in treatment group. Histopathological analysis was performed in both groups to assess osteoblast density and collagen tissue area. On day 21st, more osteoblast density and collagen area in treatment group are significantly observed ($p < 0.05$, 95% confidence interval). Observations were made on hard callus formation. In conclusions, platelet rich plasma may increase density of osteoblast in rabbit maxillary bone graft

Keywords: Platelet rich plasma, bone graft, bone healing

Correspondence: Iswinarno Doso Saputro, Department of Plastic Reconstructive and Aesthetic Surgery,
Faculty of Medicine, Universitas Airlangga, Dr. Soetomo Hospital, Surabaya, Indonesia

INTRODUCTION

Bone graft in craniomaxillofacial surgery is developing extreme and radical technique (Polley et al 1994). One of the technique is bone graft in bone defect due to trauma, cleft lip and palate, and facial cleft. In Dr. Soetomo District Hospital, there were 53 trauma patient who were reconstructed using bone graft from illiac bone or ribs during 2012 - 2013. Problem arose were bone graft absorption, surgical site infection, and chronic pain in donor site.

In actively growing bone, osteoblast, osteocyte, osteoclast, and osteoprogenitor cells continue to perform (Kalfas 2001) (Fawcett 2002) (Buckwalter 1999). About 98% of bone matrix is collagenous tissue, while the rest are glycosaminoglycans and proteoglycans (Lawrence et al 2000). Collagen is protein in extracellular matrix which is composed by three poly-

peptide chain forming triple helix. Type 1 collagen is the most abundant and almost seen in every connective tissue (Viguet-Carrin et al 2006).

Bone metabolism is affected by local and hormonal factors. Parathyroid hormone triggers cytoskeletal and osteoblast changes. Vitamin D stimulates bond between calcium ion and protein then facilitates active calcium transport and calcitonin which in turn prohibit calcium metabolism activity. Local activities that influence bone metabolism are protein clusters, growth factor, platelet release, macrophage, and fibroblast. Proteins that induce bone healing are bone morphogenic protein, insulin-like growth factors, transforming growth factors, platelet-derived growth factor dan fibroblast growth factor (Kalfas 2001). Generally, there are four bone healing phase: inflammation, soft callus forming, hard callus forming, and reshaping. There are two kinds of bone healing in craniomaxillofacial region: primary healing

or direct healing and secondary healing or healing by callus (Simpson 1995).

Bone graft is simply a process of removing bone tissue and replace it in another region. Bone graft, may be autograft, allograft, and xenograft, can be used to correct deformities due to surgery, accident, or diseases (Darwono 2001) (Ferdiansyah 2001). Autograft is more preferable for its low bone graft absorption (Ferdiansyah 2001). Meanwhile, autologous bone graft is regarded as gold standard for its low immunological rejection properties, greater osteoconduction, easy to apply, and less expensive (Roffi 2013).

Non vascularized bone graft will not be viable. Osteoclast has morphogenic protein to trigger osteoinduction and osteoconduction. These will eventually trigger neovascularization to stimulate granulation in the bone where mesenchymal cells (precursor of osteoblasts and osteoclasts) reside. Granulation tissue covers the graft while osteoclasts in granulation tissue remove non-viable graft so that cancellous bone may be replaced by new bone tissue (Simpson 1995).

Back in 1915, Albee described important basic principle to achieve success in various bone graft surgery still in use today (Polley et al 1994). Those principles are adequate vascularization of donor site, good fixation of bone graft, optimal biomechanical stimulation to bone graft, and careful tissue harvest intraoperatively. Platelet rich plasma in bone graft is expected to accelerate soft tissue and bone healing so as bone graft absorption is minimized (Ouyang & Qiao 2006) (Carlson 2002). This may be related to clot acidity (pH 6.5-6.7) thus inhibit bacterial growth and infection risk, accelerate wound healing, and minimize pain.

Several researches indicate that PRP and bone graft combination increase healing quality and bone formation (Garcia 2010), increase bone density post odontectomy of impacted molar (Liddelow & Klineberg 2011), and increase osteogenesis process in alveolar cleft (Oyama 2004). Administration of PRP in broken rat's femoral bones increased TGF- β 1 and BMP-2 on first and fourth week, followed by plateau phase and decrease of BMP-2 and increase of TGF- β 1 on fourth and sixth week.

Platelet rich plasma is one of blood derivatives where highest level of platelet concentration may be found. Platelet is one of blood cells descended from megakaryocyte cytoplasm fragment, 2 μ m in diameter, 150.000 – 450.000/ μ l (Guyton 2006), and has 10 days of lifespan before destruction on reticuloendothelial system (Robinder 2012).

Platelet rich plasma contains various growth factor such as Platelet Derived Growth Factor (PDGF), Transforming Growth Factor- β (TGF- β), Vascular Endothelial Growth Factor (VEGF), Endothelial Growth Factor (EGF), IGF1, and ECGF. PDGF is mitogen which in turn becomes chemotactic agent for fibroblast and smooth muscle cells to stimulate angiogenesis and collagen synthesis. TGF- β is released from granule alpha platelet and regulates its product by autocrine means. It may inhibit bone resorption in bone graft while stimulates fibroblast proliferation and produces proteoglycan, collagen, and fibrin. This factor also stimulates accumulation of extracellular matrix and fibrosis. In vivo, PDGF dan TGF- β in PRP may enhance soft tissue and bone tissue healing. Degranulation from alpha granule in platelet activates secretion of growth factors, especially PDGF dan TGF- β . TGF- β , VEGF, three isomers of PDGF and EGF accelerate chemotactic, mitogenesis, angiogenesis, and collagen matrix synthesis (Ouyang & Qiao 2006) (Albanese 2013).

PRP may be applied for therapies of various disorders, including musculoskeletal, cartilage, bone, muscle, tendon, ligament regeneration and some procedures of augmentation to enhance healing in surgery with implant, even though report in this field is still minimal (Roffi 2013). PRP may also enhance periodontal cell function and osteoblasts, short term or long term through DNA synthesis and osteoblast migration (Creep 2009).

Application of PRP may lower post surgical complication, and potentially stimulates regeneration in bone defect, ginggiva, and connective tissue damage. It also contains more natural growth factor so as to mimic in vivo circumstances (Lipross & Alini 2007). Gel of PRP was introduced initially as an alternative to fibrin glue in maxillofacial reconstructive surgery that needed bone graft.

The facts mentioned above posed a research opportunity and raised a question whether PRP may accelerate new bone formation in bone graft of maxillae as seen as osteoblast density and collagen density in bone matrix. The research was expected to provide basic understanding to the development of PRP application in bone healing where bone graft is applied on human maxillae. This in turn may change basic protocol of bone grafting in maxillae and may reduce complication rate and post operative cost.

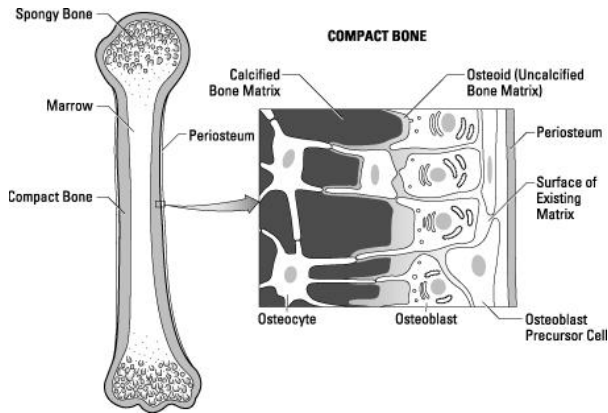


Fig. 1. Osteoblast secretes uncalcified bone matrix which in turn calcified around osteocytes (Source: National Institutes of Health Cells)

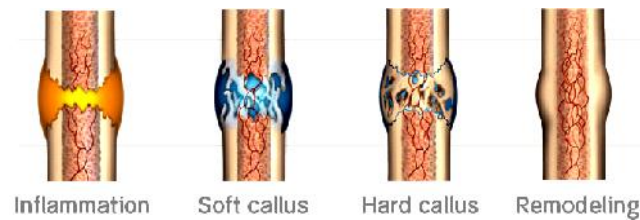


Fig. 2. Four phase of bone healing (<http://www.exogen.com/physicians/how-it-works/>)

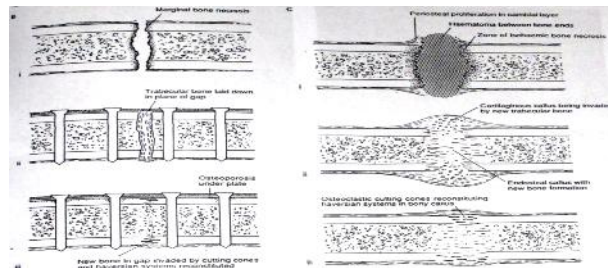


Fig. 3. Primary bone healing (B) and secondary bone healing (A) (Simpson et al 1995)

MATERIALS AND METHODS

This is a quasi experimental research with post test only design with control. Twelve 1 year-old albino male New Zealand rabbit (*Oryctolagus cuniculus*) were used in this research. All rabbits were 1-2 kilograms, kept in the same cage with same amount and kind of food. Room temperature was kept around 22 degree celcius by limiting sun shine access and ventilation.

After premedicated using atropin 0.02 mg/kgbw and acipromasin 0.1 mg/kgbw, ketamine 20-50 mg/kgbw was administered. Incisions were made intraorally to reach left and right maxillae. Six rabbits left maxillae in

control group were drilled using no. 07 burr, less than 10,000 rpm while normal saline irrigated to get bone defect with 5 mm in diameter and 3 mm deep. The drilled bone was put again in the defect as bone graft. These procedures were repeated in right maxillae of the other six rabbits in treatment group. In treatment group, PRP was administered. Post operatively, all rabbits were given 60 mg/kgbw of paracetamol.

On the 21st day, pentobarbital 60-100 mg/kgbw was administered intraperitoneally between processus xyphoideus and tuberculum pubicum. Maxillae specimens were fixated in 10% formaline and sent to pathology laboratorium to be processed before histopathological reading. Osteoblast density was observed using hematoxylin-eosin staining while Masson's trichrome staining was used to measure collagen tissue area.

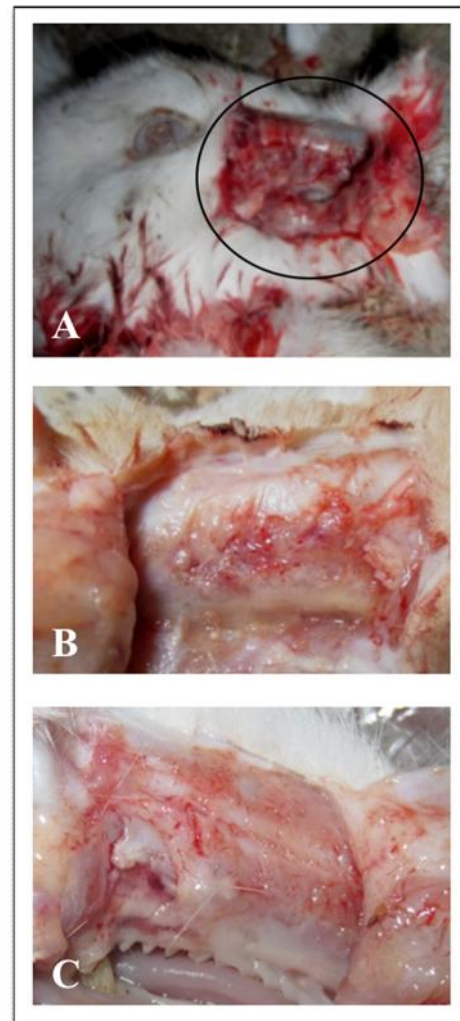


Fig. 4. Clinical feature: A) Defect in rabbit; B) Bone graft in control group (left maxillae); C) Bone graft in treatment group (right maxillae)

On the day 21st (hard callus formation phase) in control group, cracks were observed. Osteoblasts were observed by microscope with high power field 400x magnification and were more numerous than those in control group. Collagen density was measured based on tissue area percentage by microscope with 40x magnification and more collagen density was also observed in treatment group than in control group.

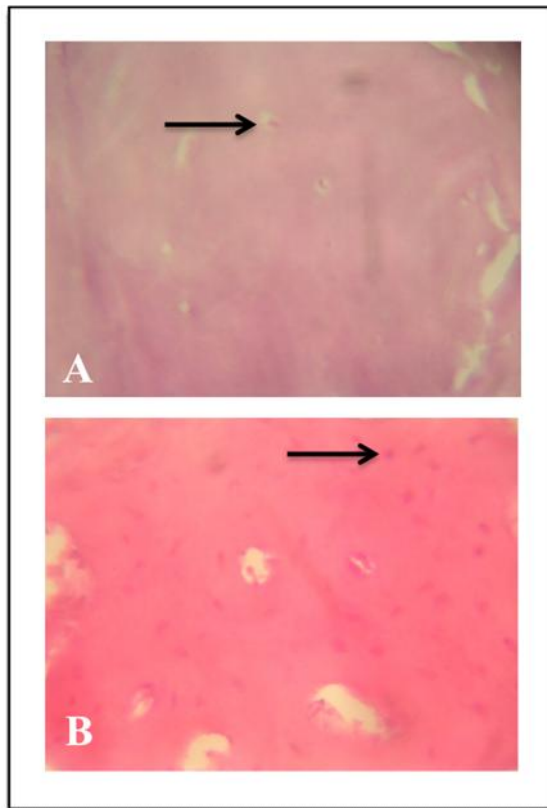


Fig. 5. Histopathological observation, 400x magnification, haematoxylin-eosin staining. Arrows show osteoblast: A) Control group; B) Treatment group

Quantitative data was first analyzed using One-Sample Kolmogorov-Smirnov test to determine normal distribution. Data was further examined with independence sample T-test with 95% confidence interval. There was more osteoblasts on day 21st (hard callus formation phase) in the group of bone graft with PRP (treatment group) as shown in Fig. 6. In the same period, collagen density was higher in treatment group as shown in Fig. 7. Mean density of osteoblast and collagen tissue percentage are statistically significant ($p < 0.05$, 95% confidence interval) between both groups as presented in Table 1.

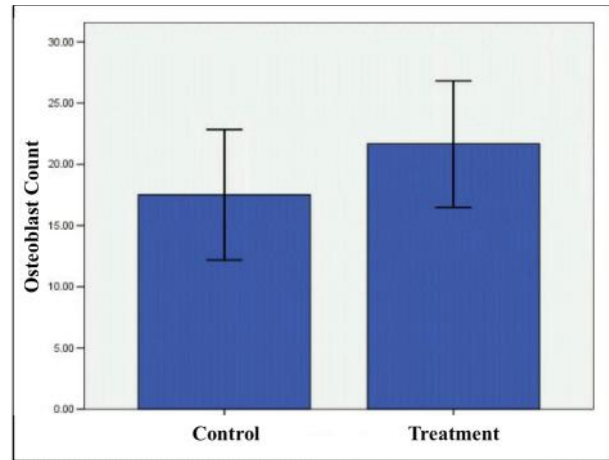


Fig. 6. Osteoblast count in both groups reflects osteoblast density

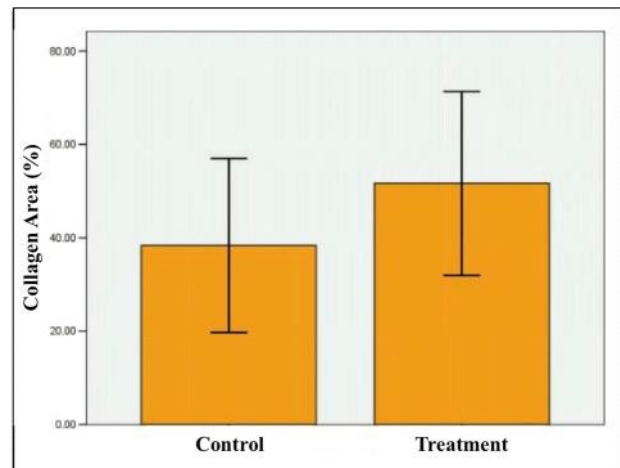


Fig. 7. Collagen area in both groups

Table 1. Mean density of osteoblast and collagen tissue percentage

Variables	Treatment Group	Control Group	p value
Osteoblasts (/field of view)	21.66±2.58	17.50±2.66	0.02
Collagen (/field of view)	51.66±9.83	38.33±9.30	0.03

DISCUSSION

In iliac bone graft with PRP to dog's mandible showed an increase in osteoblast number significantly on first and second month but not on the third and sixth month (Gerart et al 2007). In earlier research, PRP and iliac bone graft in alveolar cleft showed significant increase in osteogenesis by 3D CT-scan observation after 5-6 months (Oyama 2004).

Another research proved that PRP in human alveolar mandible after bilateral third molar extraction showed more density radiographically on first, second, and third month (Liddelow & Klineberg 2011). Also, more dense callus formation radiographically and TGF- β 1 increase were observed on fourth week after PRP administration of broken rat femoral bones.

This findings are also supported by previous research which concluded that mean platelet number in bone graft of human bone was around 111,000 – 523,000, whereas platelet concentration in PRP-enriched bone graft may increase to 595,000 – 1,100,000. This may enhance platelet ability to produce PDGF dan TGF- β . Both substance then activate angiogenesis and mitogenesis in marrow cell and perosteoblast, followed by stimulation of differentiation and deposition of osteoblast matrix protein. PRP may also enhance activity of alkaline phosphatase, a marker in bone formation (Marx 1999).

However, previous study once found that PRP application provide significant result. Human PRP which was mixed with bone matrix implanted in rats' gastrocnemius muscle for five days did not induce osteoinduction (Ranly 2007). Other previous study found that no significant effect was observed in rats' calvaria healing process on 4th and 8th week radiographically (Pryor 2005). Unsuccessfulness of both studies might be caused by non-autologous PRP or substandard PRP processing.

CONCLUSION

This research concludes that platelet rich plasma may increase density of osteoblast in rabbit maxillary bone graft. Collagen and osteoblast in early stage of hard callus forming were both affected by PRP and eventually trigger osteogenesis in rabbit maxillary bone graft.

REFERENCES

Albanese A. Platelet Rich Plasma (PRP) in Dental and Oral Surgery: From the Wound Healing to Bone Regeneration. *J Immunity And Ageing*. 2013; 10(23).
Buckwalter JA. *Orthopedic Basic Science Biology and Biomechanics of the Musculoskeletal Sistem*. 2nd ed.: American Academy of Orthopedic Surgeons; 1999.
Carlson NF. Platelet Rich Plasma: Clinical Application in Dentistry. *J Am Dent Assoc*. 2002; 133: p. 1383-1386.
Creeper F. The Effect of Platelet Rich Plasma on Osteoblast: A Periodontal Ligament Cell Migration,

Proliferation, and Differentiation. *J Periodontal Res*. 2009 April; 44(2): p. 258.
Darwono B. Pengalaman Graft Tulang di RSPAD Gatot Soebroto. In *The 1st Indonesian Tissue Bank Scientific Meeting and Workshop on Biomaterial Application*; 2001; Surabaya. p. 42a-42h.
Fawcett DW. *A Textbook of Histology* Jakarta: 2002, EGC.
Ferdiansyah. Standar Produksi Biomaterial. In *The 1st Indonesian Tissue Bank Scientific Meeting and Workshop on Biomaterial Application*; 2001; Surabaya. p. 19-23.
Garcia RV. Effect of Platelet Rich Plasma on Peri-Implant Bone Repair: A Histologic Study in Dogs. *J of Oral Implanology*. 2010; XXXVI: p. 281-290.
Guyton AC. *Physiology of the Human Body*. 11th ed. Philadelphia: Saunders College Publishing; 2006.
Kalfas IH. Principles of Bone Healing. *J Neurosurgery Focus*. 2001; 10(4): p. 1-4.
Lawrence WT, Kashyap A. Healing of Nerves, Blood Vessels, Muscle, Tendon, Cartilage, and Bone. In Achauer BM, E. E, editors. *Plastic Surgery Indication, Operation, and Outcomes*. London: Mosby; 2000. p. 92-96.
Liddelow G, Klineberg I. Patient-Related Risk Factors for Implant Therapy: A Critique of Pertinent Literature. *J Austral Dent*. 2011; 56: p. 417-426.
Lipross S, Alini M. Platelet Rich Plasma for Bone Healing: To Use or Not to Use? *AO Dialogue*. 2007; 01: p. 25-29.
Marx RE. Platelet Rich Plasma: A Source of Multiple Autologous Growth Factor for Bone Graft. In Lynch SE, Genco RJ, Marx RE, editors. *Tissue Engineering: Application in Maxillofacial Surgery and Periodontics*. Chicago: Quintessence; 1999. p. 71-82.
Ouyang XY, Qiao J. Effect of platelet-rich plasma in the treatment of periodontal intrabony defects in humans. *Chinese Medical Journal*. 2006; 119(18): p. 1511-1521.
Oyama T. Efficacy of Platelet Rich Plasma in Alveolar Bone Grafting. *J Oral Maxillofac Surg*. 2004; 62(555).
Polley JW. Bone Graft. In Cohen M. *Mastery of Plastic and Reconstruction Surgery*. London: Little Brown and Company; 1994. p. 102-112.
Pryor ME. Regenerative Potential of Platelet Rich Plasma Added to Xenogenic Bone Grafts in Peri-Implant Defects: A Histomorphometric Analysis in Dogs. *J Periodontol*. 2005; 76: p. 1287-1292.
Ranly DM. Platelet Rich Plasma Inhibits Demineralized Bone Matrix Induced Bone Formation in Nude Mice. *J Bone Joint Surg Am*. 2007; 89: p. 139-147.
Robinder SD. Platelet Rich Plasma Therapy: Future or Trend? *J Arthritis Research and Therapy*. 2012; 14(219).
Roffi A. Does PRP Enhance Bone Integration with Graft, Graft Substitutes, or Implants? A Systematic

Review. *BMJ Musculoskeletal Disorders*. 2013; 14(330).
Simpson DA. Pathology of Injury and Repair. In David DJ, editor. *Craniofacial Trauma*. Melbourne: Churchill Livingstone; 1995. p. 199-132.

Viguet-Carrin S, Garnero P, Delmas PD. The Role of Collagen in Bone Strength. *J of Osteoporosis*. 2006; XVII: p. 319-336.