

Hypoglycemic Activity and Pancreas Protection of Combination of *Morinda citrifolia* Linn. Juice and *Curcuma xanthorrhiza* Roxb. Juice on Streptozotocin-Induced Diabetic Rats

Bilal SA Santoso^{1,3*}, Sudarsono², Agung E Nugroho², Yosi B Murti²

¹Doctoral program, Faculty of Pharmacy, Universitas Gadjah Mada, Yogyakarta 55281, Indonesia

²Faculty of Pharmacy, Universitas Gadjah Mada, Yogyakarta 55281, Indonesia

³Academy of Pharmacy of Putra Indonesia Malang, Malang 66126, Indonesia

Submitted: 8-12-2017

Revised: 10-02-2018

Accepted: 11-03-2018

*Corresponding author
Bilal SA Santoso

Email:
bilalsas67@gmail.com

ABSTRACT

Mengkudu fruit and *temulawak* rhizome which contains scopoletin and curcumin, respectively, were used traditionally as antidiabetic. Both compounds have strong antioxidant activity. This research aimed to determine the antihyperglycemic and pancreas protection of combination of *mengkudu* fruit juice (MFJ) and *temulawak* rhizome juice (TRJ) on streptozotocin (STZ) induced diabetic rats. Rats were divided into 7 groups, each group consist of 5 rats. All groups, except normal group were treated accordingly for 28 days. Blood samples were taken from the plexus retroorbitalis for examination of blood glucose levels on day-8th, 15th, 22nd, and 29th. On the day-29th, blood samples were examined for malondialdehyde (MDA) levels. At the end of the experiment, the rats were sacrificed for examination of pancreatic morphological conditions. The results showed that diabetic rats given MFJ-TRJ combination experienced a significant decrease in blood glucose levels, a significant decrease in MDA levels and improvement pancreas morphology when compared with the negative control group. The conclusion of this research showed the combination of MFJ-TRJ has hypoglycemic activity and can fix condition of pancreas morphology.

Key words: hypoglycemic, pancreas protection, combination juice, *mengkudu*, *temulawak*

INTRODUCTION

Diabetes mellitus is a metabolic disease which is marked by a hyperglycemia condition. Hyperglycemia occurs due to pancreatic damage or failure of insulin secretion (Rathinam and Pari, 2016) causes interference of glucose metabolism, the degradation of the glucose entry into cell and increase of glucose release from liver into circulation (Huang *et al.*, 2016). This condition can lead to lipid metabolism failure (Kumar *et al.*, 2016). Hyperglycemia related to disfunction or damages on β pancreas cells.

Alkaloid in *mengkudu* fruit was able to revitalize and regenerate death cells until they are regenerated, it naturally can increase immune system, increase function of cells and fix damage cells in body that are caused of disease or aging process (Sayuti and Yenrina, 2015). Compound that has responsible toward pharmacology effect of *temulawak* rhizome is

curcumin, a main chemical constituent in *temulawak* rhizome (Itokawa *et al.*, 2008; Kant *et al.*, 2014).

MATERIALS AND METHODS

Materials

Mengkudu fruit and *temulawak* rhizome were obtained from *Materia Medika Batu* office, East Java Province, Indonesia. Male rats Wistar strain were obtained from Pharmacology Laboratory, Faculty of Pharmacy, Universitas Gadjah Mada (UGM). Scopoletin standart (Fluka), curcumin standart (isolat 95%, TLC), reagent Lipid Peroxidation (MDA) Colorimetric /Fluorometric Assay Kit, reagent Glucose Oxidase-Phenol Aminoantipyrine (GOD-PAP) from Diagnostic System International (Diasys), Hematoxylin and Eosin.

Ethical clearance

Ethical clearance number: 445/KEC-LPPT/IV/ 2016 was obtained from the ethical

committee in Integrated Research and Testing Laboratory - LPPT UGM.

Preparation of Juice

On 1200g *Mengkudu* fruit were washed until they are clean with running water and drained. They were entered in juicer extractor then pressed which produces MFJ 210mL and weight 600g. The result was thick *mengkudu* fruit juice and pulp that were separated. It is the same to do with *temulawak* rhizome juice, 1080 g *temulawak* produces TRJ 345mL and weight 560g.

Phytochemical Qualitative Analysis

Alkaloid

On 1mL MFJ and 1mL TRJ was inserted into each 4 reaction tubes and added chloroform 5 drops on each tube. Tube 1 as control, tube 2 added Mayer's reagent and positive if produce white precipitate, tube 3 added Dragendorff's reagent and positive if produce orange precipitate, tube 4 added Wagner's reagent and positive if produce brown precipitate.

Flavonoid

On 1mL MFJ and 1mL TRJ was inserted into different reaction tubes. Then each test tube was added 3 drops HCl 2N, a few Magnesium powder, 1 mL amyl alcohol, shaken ad homogeneous. Reaction is positive if produce yellow to red solution.

Phenolic

On 1mL MFJ and 1mL TRJ was inserted in different reaction tubes. Then each test tube was added 2-3 drops FeCl₃ 1%. Reaction is positive if produce black precipitate.

Saponin

On 1mL MFJ and 1mL TRJ was inserted in different reaction tubes. Then each test tube was added aquadest and shaken strongly. Reaction is positive if there was a foam on the surface.

Tannin

On 1mL MFJ and 1mL TRJ was inserted in different reaction tubes. Then each test tube was added 2-3 drops FeCl₃ 1% and 1% solution of gelatin. Reaction is positive if produce white precipitate.

Triterpenoid

On 1mL MFJ and 1mL TRJ was inserted in different reaction tubes. Then each test tube was added Libermann-Burchard's reagent

slowly along the sides of the test tube. Reaction is positive if produce dark red solution.

Quantitative Analysis with TLC-Densitometry Method

Scopoletin

TLC-densitometry method was performed on aluminium plates precoated with silica gel 60F₂₅₄ as the stationary phase using ether-toluene-10% acetic acid (55:44:1, v/v/v) as mobile phase. Densitometric analysis was carried out at $\lambda=343\text{nm}$ (Djatkiko *et al.*, 2006).

Curcumin

TLC-densitometry method was performed on aluminium plates precoated with silica gel 60F₂₅₄ as the stationary phase using ether-toluene-10% acetic acid (55:44:1, v/v/v) as mobile phase. Densitometric analysis was carried out at $\lambda=426\text{ nm}$ (Pothitirat and Gritsanapan, 2005).

In vivo experiment

Animal diabetic was done by inducing with single dose of 60mg/kgBW STZ intraperitoneally (*i.p*) (Ragbetli and Ceylan, 2010). In day 4, blood glucose level was measured to confirm diabetic condition ($>200\text{mg/dL}$) (Muhtadi *et al.*, 2015). Animal experiment were divided into 7 groups (normal, negative control, positive control, and four tests groups), each group consists of 5 rats. Glibenclamide 4.5mg/kg BW was used as positive control. Test groups consist of combination juice 1 (MFJ-TRJ ($1/8:1/8$)), combination juice 2 (MFJ-TRJ ($1/4:1/4$)), combination juice 3 (MFJ-TRJ ($1/2:1/2$)), combination juice 4 (MFJ-TRJ (1:1)). Dose of MFJ was 3.6mL/kg BW and dose of TRJ was 10mL/kg BW.

Blood glucose level

Blood glucose measurements were performed several times after STZ induction, the day-4th, day-11th, 18th, 25th, and 32nd. Blood glucose measurement using GOD-PAP method with Trinder's reaction principle. In this method, glucose was measured after enzymatic oxidation using the GOD (glucose oxidase) enzyme. The hydrogen peroxide (H₂O₂) formed then reacts with phenol and 4-aminoquinone with a POD (peroxidase) enzyme catalyst that forms quinonimine. The intensity of the pink color formed was

proportional to the glucose level in the sample at $\lambda=546\text{nm}$ used on spectrophotometry (Barham and Trinder, 1972).

Lipid peroxidase

Plasma MDA measurement was done using TBARS method. This examination was based on condensation reaction between one MDA molecule with two molecules of TBA on low pH that happened in acid, temperature of 90-100°C. Thiobarbituric Acid would give pink-chromogen color which could be read with spectrophotometer (Held, 2012).

The complete procedure, 0.5mL of the sample or standard Tetraethoxypropane (TEP) was added 2mL of 0.25 N cold HCl containing 15% Trichloro Acetic Acid (TCA), 0.38% Thio Barbituric Acid (TBA) and 0.5% Butylated Hydroxytoluen (BHT). This mixture was heated at 90-100°C for 1h. After cooling, the solution mixture and standard were centrifuged 3500rpm for 10min. Absorbance was measured at $\lambda=532\text{nm}$.

Histological study

The depiction of histopathological in pancreas system from many groups of rats in this research was conducted with the purpose to find out effect from examination sample toward animal experiment after being inducted with streptozotocin (Murthy *et al.*, 2002). Tissue preparation of pancreas was colored with Hematoxylin-Eosin (HE). Hematoxylin would give blue color on cell nucleus and eosin gave red color on cytoplasm and extracellular matrix (Fischer *et al.*, 2008). Furthermore, histology preparations were observed with microscope to find out morphology of the Langerhans insulai pancreas.

Statistical analysis

Analisis data was processed using IBM SPSS 23 statistical program. The data distribution test was done by Shapiro-Wilk test and the homogeneity test of the data was done by Levene's test so it was followed by Anova test. If data was not normally distributed and or not homogeneous, $p<0.05$ was considered statistically significant. Then Anova test could not be done so that it was followed by Non-parametric Kruskal Wallis test. If the Kruskal Wallis Non-parametric test results indicate that

at least one treatment differed significantly between treatment groups so that it was used the Mann Whitney test.

RESULT AND DISCUSSION

Phytochemical analysis

Qualitative phytochemical analysis of MFJ revealed the presence of alkaloids, flavonoids, phenolic, saponin, and triterpenoids while TRJ contains alkaloids, flavonoids, phenolics, and tannins. Scopoletin content of MFJ was $103.50\mu\text{g/mL}$, while curcumin content in TRJ was $553.64\mu\text{g/mL}$.

Malondialdehyde analysis

The result of MDA level measurement showed that MDA level from the lowest to the highest were normal group, positive control group, MFJ-TRJ group (1:1), MFJ-TRJ group ($1/2:1/2$), MFJ-TRJ group ($1/4:1/4$), MFJ-TRJ group ($1/8:1/8$), and negative control group. Data shows that the combination juice of MFJ-TRJ treatment could decrease lipid peroxidase activity.

MDA was one of last products from lipid peroxide cell membrane of free radical which excess or reactive oxygen species (ROS) so that MDA was used as measurement index of free radical activity in body (Hussain, 2002). The result of measurement of MDA level showed that MDA level in diabetic rats' blood increased high enough toward normal control rats (Coskun *et al.*, 2005). MDA level in diabetic rats' blood showed lowest level of positive control group as well as giving combination juice. It showed that STZ induction in rats increased free radical in body because of radical nitrogen oxide (NO) released from STZ (Anwar and Meki, 2003). Diabetic rats that were given combination of MFJ-TRJ juice in 28 days showed degradation of MDA level significantly (Figure 1).

Blood glucose analysis

On the 28th day, after treatment, there was a significant normalization of fasting blood glucose, observed in diabetic experimental animals treated with combination juice and the diabetic standard with reference hypoglycaemic drug, glibenclamide as compared to diabetic untreated animals (Figure 2). In evaluation of the decrease of blood glucose level, glibenclamide administer gave decrease fasting

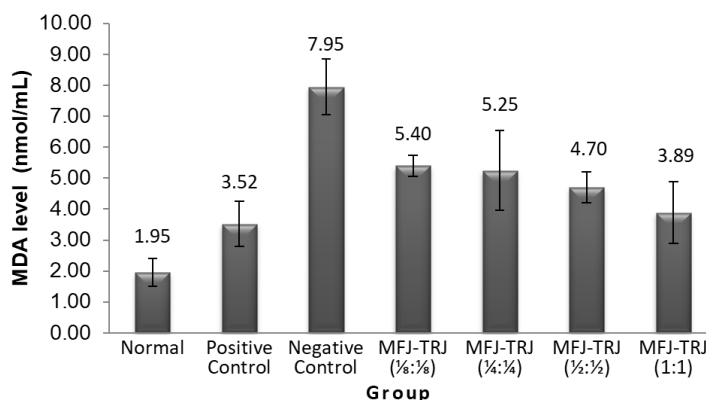


Figure 1. Variation of MDA level in normal rat and diabetic rats

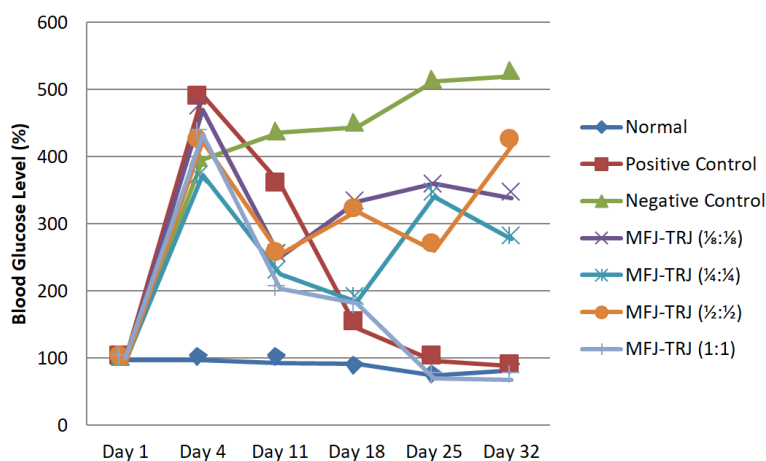


Figure 2. Effect of combination juice on blood glucose of rats

blood glucose that had $p > 0,05$ from giving combination juices MFJ-TRJ (1:1).

The reduction of blood glucose was caused by compound content of scopoletin and curcumin in combination of MFJ-TRJ juice. Scopoletin was derivate coumarin that could protect from hyperglycemia condition and resistance insulin (Chang *et al.*, 2015). Scopoletin had hypotensive activity, anti-depressant, hypolipidemic and hypoglycemic. Scopoletin could decreased blood glucose level and lipid level significantly rather than glibenpiride (Verma *et al.*, 2013). All active compound of *mengkudu* works synergistic in making antioxidant effect and antihyperglycemic (Rao and Subramanian, 2008). Curcumin had antioxidant activity and antiradical (Borra *et al.*, 2013) so that it could prevented free radical. Free radical can caused

oxidation reaction through metabolism process in body and response toward effect outside the body such as pollution exposure. Efficacy of curcumin in *temulawak* was to increase immune system (Kim *et al.*, 2007; Yadav *et al.*, 2005) and antidiabetic (Wu *et al.*, 2014).

Histological analysis

In evaluation of the improvement of pancreatic morphology, glibenclamide could improve pancreatic morphology like administering combination MFJ-TRJ (1/8:1/8). The administering combination of MFJ-TRJ (1/8:1/8) have better involvement rather than the other combination juices or there was no pathological changes in insula Langerhans. It indicates that combination juice of MFJ-TRJ administering has activity as good as glibenclamide (Figure 3).

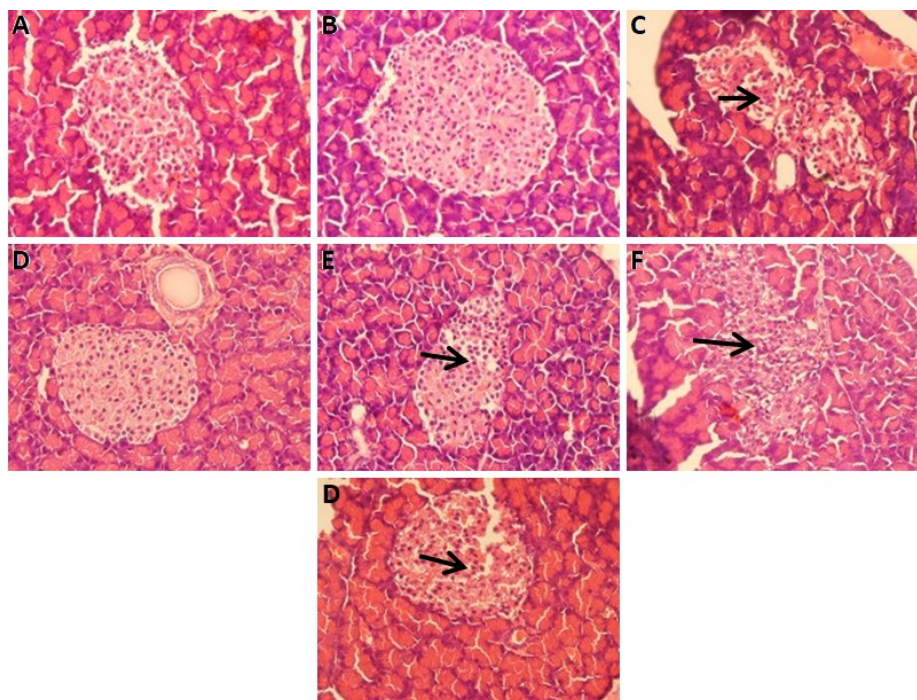


Figure 3. Histology of pancreas with HE staining. (A) Normal group (B) Positive control group, (C) Negative control group, (D) MFJ-TRJ group (1/8:1/8), (E) MFJ-TRJ group (1/4:1/4), (F) MFJ-TRJ group (1/2:1/2), (G) MFJ-TRJ group (1:1). Magnification 10x40. The arrows indicate the presence of vacuolization.

Glibenclamide as positive control has an effect of improved Langerhans cellular proliferation so that cell density in the Langerhans initiates was high. Glibenclamide worked by stimulating the release of insulin (Fuhlendorff *et al.*, 1998) and increased insulin secretion due to glucose stimulation (Proks *et al.*, 2002) so that glibenclamide could repaired pancreatic β cells because it could increased insulin secretion (Song, 2017). In contrast to the negative control, Langerhans insulai cells many occur vacuolisation signify the degeneration of endocrine cells due to induction of STZ. It says vacuolisation occurs when there was an empty space in the Langerhans insulai parenchyma, which was thought to be due to necrosis of cells in the Langerhans insulai (Yusarini and Darmayanti, 2016).

CONCLUSION

Based on research that has been done, it can be concluded that combination of MFJ-TRJ (1:1) has hypoglycemic activity and MFJ-

TRJ (1/8:1/8) can fix condition of pancreas morphology.

ACKNOWLEDGEMENT

I thank you to Director of Academy of Pharmacy of Putra Indonesia Malang, The Head of Pharmacy Science Study of Postgraduate Program and The Dean of Pharmacy Faculty of Universitas Gadjah Mada who have given opportunity for me to finish dissertation research in taking doctoral program.

REFERENCES

- Anwar MM., Meki ARM., 2003. Oxidative stress in streptozotocin-induced diabetic rats: effects of garlic oil and melatonin. *Comp. Biochem. Physiol. A. Mol. Integr. Physiol.* 135, 539–547.
- Barham D., Trinder P., 1972. An improved colour reagent for the determination of blood glucose by the oxidase system. *Analyst* 97, 142–145. <https://doi.org/10.1039/AN9729700142>

- Borra SK., Gurumurthy P., Mahendra J., others, 2013. Antioxidant and free radical scavenging activity of curcumin determined by using different in vitro and ex vivo models. *J. Med. Plants Res.* 7, 2680–2690.
- Chang WC., Wu SC., Xu KD., Liao BC., Wu, JF., Cheng, AS., 2015. Scopoletin Protects against Methylglyoxal-Induced Hyperglycemia and Insulin Resistance Mediated by Suppression of Advanced Glycation Endproducts (AGEs) Generation and Anti-Glycation. *Molecules* 20, 2786–2801. <https://doi.org/10.3390/molecules20022786>
- Coskun O., Kanter M., Korkmaz A., Oter S., 2005. Quercetin, a flavonoid antioxidant, prevents and protects streptozotocin-induced oxidative stress and β -cell damage in rat pancreas. *Pharmacol. Res.* 51, 117–123 <https://doi.org/10.1016/j.phrs.2004.06.002>
- Djatmiko W., Kusumawati I., Sholehah DN., 2006. Quantitative Analyses of Scopoletin in Various Maturation Degree of *Morinda citrifolia* Linn Fruits Using TLC - *Densitometry*. *J. Bahan Alam Indones.* 6.
- Fischer AH., Jacobson KA., Rose J., Zeller R., 2008. Hematoxylin and eosin staining of tissue and cell sections. *CSH Protoc.* 2008, pdb.prot4986.
- Fuhlendorff J., Rorsman P., Kofod H., Brand CL., Rolin B., et al., 1998. Stimulation of insulin release by repaglinide and glibenclamide involves both common and distinct processes. *Diabetes* 47, 345–351. <https://doi.org/10.2337/diabetes.47.3.345>
- Held P., 2012. An introduction to reactive oxygen species. *Tech Resour.-App Guid.* 802, 5–9.
- Huang DW., Chang WC., Wu JSB., Shih R.W., Shen SC., 2016. Gallic acid ameliorates hyperglycemia and improves hepatic carbohydrate metabolism in rats fed a high-fructose diet. *Nutr. Res.* 36, 150–160. <https://doi.org/10.1016/j.nutres.2015.10.001>
- Hussain HEMA., 2002. Reversal of diabetic retinopathy in streptozotocin induced diabetic rats using traditional Indian anti-diabetic plant, *Azadirachta indica* (L.). *Indian J. Clin. Biochem.* 17, 115–123. <https://doi.org/10.1007/BF02867983>
- Itokawa H., Shi Q., Akiyama T., Morris-Natschke SL., Lee KH., 2008. Recent advances in the investigation of curcuminoids. *Chin. Med.* 3, 11.
- Kant V., Gopal A., Pathak NN., Kumar P., Tandan SK., Kumar D., 2014. Antioxidant and anti-inflammatory potential of curcumin accelerated the cutaneous wound healing in streptozotocin-induced diabetic rats. *Int. Immunopharmacol.* 20, 322–330. <https://doi.org/10.1016/j.intimp.2014.03.009>
- Kim AJ., Kim YO., Shim J-S., Hwang JK., 2007. Immunostimulating activity of crude polysaccharide extract isolated from *Curcuma xanthorrhiza* Roxb. *Biosci. Biotechnol. Biochem.* 71, 1428–1438.
- Kumar V., Bhatt PC., Kaithwas G., Rashid M., Al-abbasi FA., et al., 2016. α -Mangostin Mediated Pharmacological Modulation of Hepatic Carbohydrate Metabolism in Diabetes Induced Wistar Rat. *Beni-Suef Univ. J. Basic Appl. Sci.* <https://doi.org/10.1016/j.bjbas.2016.07.001>
- Muhtadi, Primarianti AU., Sujono TA., 2015. Antidiabetic Activity of Durian (*Durio Zibethinus* Murr.) and Rambutan (*Nephelium Lappaceum* L.) Fruit Peels in Alloxan Diabetic Rats. *Procedia Food Sci.* 3, 255–261. <https://doi.org/10.1016/j.profoo.2015.01.028>
- Murthy KNC., Jayaprakasha GK., Singh RP., 2002. Studies on Antioxidant Activity of Pomegranate (*Punica granatum*) Peel Extract Using in Vivo Models. *J. Agric. Food Chem.* 50, 4791–4795. <https://doi.org/10.1021/jf0255735>
- Pothitirat W., Gritsanapan W., 2005. Quantitative analysis of curcumin, demethoxycurcumin and bisdemethoxycurcumin in the crude curcuminoid extract from *Curcuma longa* in Thailand by TLC-densitometry. *Mahidol Univ. J. Pharm. Sci.* 32, 23–30.
- Proks P., Reimann F., Green N., Gribble F., Ashcroft F., 2002. Sulfonylurea stimulation of insulin secretion. *Diabetes* 51, S368–S376.

- Ragbetli C., Ceylan E., 2010. Effect of streptozotocin on biochemical parameters in rats. *Asian J. Chem.* 22, 2375.
- Rao USM., Subramanian S., 2008. Biochemical evaluation of antihyperglycemic and antioxidative effects of *Morinda citrifolia*. *Med. Chem. Res.* 18, 433–446. <https://doi.org/10.1007/s00044-008-9140-1>
- Rathinam A., Pari L., 2016. Myrtenal ameliorates hyperglycemia by enhancing GLUT2 through Akt in the skeletal muscle and liver of diabetic rats. *Chem. Biol. Interact.* 256, 161–166. <https://doi.org/10.1016/j.cbi.2016.07.009>
- Sayuti K., Yenrina R., 2015. *Antioksidan Alami dan Sintetik*, 1st ed. Andalas University Press, Padang.
- Song Z., 2017. Dietary curcumin intervention targets both white adipose tissue inflammation and brown adipose tissue thermogenesis (Thesis).
- Verma A., Dewangan P., Kesharwani D., Kela SP., 2013. Hypoglycemic and hypolipidemic activity of scopoletin (coumarin derivative) in streptozotocin induced diabetic rats. *Int J Pharm Sci Rev Res* 22, 79–83.
- Wu W., Geng H., Liu Z., Li H., Zhu Z., 2014. Effect of curcumin on rats/mice with diabetic nephropathy: a systematic review and Meta-analysis of randomized controlled trials. *J. Tradit. Chin. Med.* 34, 419–429. [https://doi.org/10.1016/S0254-6272\(15\)30041-8](https://doi.org/10.1016/S0254-6272(15)30041-8)
- Yadav VS., Mishra KP., Singh DP., Mehrotra, S., *et al.*, 2005. Immunomodulatory effects of curcumin. *Immunopharmacol. Immunotoxicol.* 27, 485–497.
- Yusastrini NLA., Darmayanti LPT., 2016. The effect of dietary seaweed of *Caulerpa* sp. and *Gracilaria* sp. on blood glucose levels and histological pancreas of diabetic rats. *Media Ilm. Teknol. Pangan Sci. J. Food Technol.* 3, 53–61.