

Simple Bone Cyst Management: Percutaneous Steroid Injection Versus Curettage With Hydroxyapatite

ACHMAD FAUZI KAMAL, RIZA APRIZAL, YOGI PRABOWO

Department of Orthopaedic and Traumatology, Cipto Mangunkusumo National Central Hospital/Faculty of Medicine University of Indonesia

Diterima: 20 Juni 2017; Direview: 23 Juni 2017; Disetujui: 5 Juli 2017

ABSTRACT

The main goals of the therapy of simple bone cyst (SBC) are to get the bone healing, prevent pathological fractures, and management of pain symptom. There are various methods of the SBC treatments, however they still remain controversial because of their healing rate and invasiveness of surgery.

A total of 10 SBC patients were divided into two groups namely curettage with hydroxyapatite (HA) and decompression and percutaneous steroid injection (PSI). PSI was performed three times at intervals of each month. The mean follow-up of 12-26 months. Evaluation of functional outcome by Musculoskeletal Tumour Society (MSTS) score and supported with radiologically based on Chang criteria.

There were 5 patients (proximal femur 2; proximal humerus 2, radius 1) performed curettage with HA therapy. Remaining 5 patients (proximal femur 3; proximal humerus 1; calcaneus 1) were performed PSI therapy. PSI group had better MSTS score, particularly at month 3 (55%) and month 6 (84%) than curettage with HA therapy (47% and 69.3%). Complete bone healing was found in both group at month 12 follow up, however solid union occurred faster in PSI group. PSI tends to have faster and better functional outcome than curettage and HA. Curettage with HA and PSI have similar complete bone healing at month 12 follow up.

Keyword: Simple bone cyst, steroid injection, curettage, hydroxyapatite

ABSTRAK

Target utama penatalaksanaan *simple bone cyst* (SBC) adalah mencapai penyembuhan tulang yang sempurna, mencegah fraktur patologis dan mengatasi gejala nyeri. Ada beberapa metode penatalaksanaan SBC, namun demikian masih menjadi perdebatan dikarenakan perbedaan angka penyembuhannya dan jenis pembedahan yang invasif.

Sepuluh pasien yang didiagnosis SBC dikelompokkan menjadi kelompok yang mendapat tindakan *curettage* dan pengisian defek dengan *hydroxyapatite* (HA) dan kelompok dekompresi dan *percutaneous steroid injection* (PSI). Prosedur PSI dilakukan sebanyak 3x dengan interval waktu satu bulan. Follow up dilakukan selama 12 – 26 bulan. Evaluasi luaran fungsional menggunakan Musculoskeletal Tumour Society (MSTS) score dan secara radiologi sesuai criteria Chang.

Terdapat 5 pasien (2 femur proksimal, 2 humerus proksimal, dan 1 radius) yang dilakukan prosedur *curettage* dan pengisian defek dengan HA. Lima pasien sisanya (3 femur proximal, 1 humerus proximal dan 1 calcaneus) dilakukan prosedur PSI. Luaran fungsional Kelompok PSI memiliki MSTS score yang lebih baik, khususnya pada bulan ke-3 (55%) dan bulan ke-6 (84%) daripada kelompok *curettage* dengan HA (47% dan 69.3%). Penyembuhan tulang sempurna menunjukkan hasil yang sama pada evaluasi bulan ke-12, tetapi solid union didapatkan lebih cepat pada kelompok PSI. Kelompok PSI memiliki kecenderungan solid union dan luaran fungsional yang lebih cepat daripada kelompok *curettage* dengan HA. Kedua kelompok mencapai penyembuhan sempurna pada bulan ke-12 follow up.

Kata Kunci: Simple bone cyst, steroid injection, curettage, hydroxyapatite

KORESPONDENSI:

Achmad Fauzi Kamal

Department
of Orthopaedic
and Traumatology,
Cipto Mangunkusumo
National Central Hospital/
Faculty of Medicine
University of Indonesia.
e-mail:
fauzikamal@yahoo.com

INTRODUCTION

The simple bone cyst (SBC) is a benign fluid-filled lesion which is located mainly in the metaphysis of the long bones, seen in patients before skeletal maturity.¹⁻⁴ It is the most common benign lytic lesion and mainly occurs in the first two decades of life with boy and girl ratio 2:1.⁵ Sometimes, SBC is classified as a tumor-like lesion. The cavity of the cyst usually contains clear yellowish sero-sanguinous fluid.¹⁻³

The radiological appearance of SBCs is characteristic.⁴ On radiograph, the SBC demonstrates a well-localized lytic lesion with sclerotic margins in the medullary canal without periosteal reaction. However, periosteal reaction may be seen at the fracture-healing stage when the SBC has a pathological fracture. The cyst may expand concentrically but never penetrates bone cortex.¹⁻⁴

Uncomplicated SBCs are painless and are diagnosed when a pathological fracture takes place or we incidentally find on a radiograph.⁴ However, the cysts close to the growth plate show biological activity recur more often than those which move away from the growth plate. An active cyst near the physics may cause retardation of longitudinal growth in up to 14% of patients.⁴ Fortunately, they might heal spontaneously in adulthood.³ The treatment is indicated in pain, pathological fracture, or risk of a fracture.^{1-3, 6}

The main goal of SBC therapy is to obtain complete bone healing, prevent pathological fractures and symptom management (pain or fracture). There are several alternative treatments for SBC such as curettage combined with bone graft or synthetic graft such as hydroxyapatite (HA), calcium phosphate or calcium sulfate, decompression combined with percutaneous steroid injection (PSI), aspiration and injection of autologous bone marrow, and continuous decompression with flexible intramedullary nail and cannulated screw.^{7,8}

Intralesional curettage combined with bone graft or synthetic graft is the most common procedure for SBC treatment.^{9,10} It is also to be a standard treatment in all SBC patients in our hospital before 2013. Curettage eradicates the source of enzymes that destroy bone by cleaning the cyst membrane and bone/synthetic graft acts as an osteoconductive for bone healing process. HA is often used to fill bone defects and effectively used in the SBC.^{6,7}

PSI was initially stated to give favorable results in 90% of cases with no growth arrest or secondary deformity, but Campanacci et al (1986) reported a 15% recurrence rate, with only 50% of cysts showing

complete healing.⁴ The low morbidity and simplicity of steroid injection made it popular and as treatment option instead of curettage combined with bone graft or synthetic graft. In our hospital, decompression and PSI has been a treatment option since 2013. We have investigated the functional outcomes of SBCs treated by curettage combined with HA and PSI. It is expected to be applied in the management for SBC patients and provide clinical decision making.

MATERIAL AND METHODS

This study is a retrospective cohort of SBC patients who underwent curettage combined with HA or PSI. The lesions had a typical radiographic appearance diagnosed without needle or open biopsy before the definitive treatment.

We conducted PSI three times with a month period between an injection to another one. PSI was also performed in one case of SBC with pathological fracture which applied after the occurrence of fracture healing. The PSI in our hospital was performed with the following procedure:

1. With the patient under general anesthesia, we visualize the lesion with C-arm guidance.
2. Core bone needles no 11 are introduced in the proximal and the distal pole of the cystic lesion.
3. We evaluate the fluid (color) which came out from the cavity without force and send it to histopathologic examination.
4. After the characteristic fluid of SBC is empty, we aspirate haemorrhagic one from the cavity and also send it to histopathologic examination.
5. The cavity was flushed with normal saline from proximal core bone needle.
6. With closed distal core bone needle, we perform PSI 80–120 mg.
7. Functional outcome using musculoskeletal tumor society (MSTS) score was evaluated on month 1, 3, 6, and 12 after surgery.

Statistical analysis was conducted using SPS and a p value of < 0.05 was considered significant.

RESULTS

Of the 10 patients, 5 had curettage and HA and others received PSI as their treatment. The mean age of the patients was 13.0 ± 5.8 years with the highest incidence in the second decade 6 of 10 patients were male. Five of 10 lesions were located in the proximal femur and 3 of 10 patients had

lesions in the proximal humerus. Other lesions recorded was in radius and calcaneous bone (1 case each). Seven of 10 lesions were located in metaphyses and left-sided (6 of 10). Four patients presented with pathologic fractures. We followed up 19.6 ± 8.4 months for each patient. The curettage group had significantly longer follow-up time ($p = 0.008$) compared to PSI group. The overall characteristic features of this study are shown in table 1.

Table 1: Demographic and clinical characteristic SBC patient

	Treatment options		p-value*
	PSI N ₁ =5	Curettage + HA N ₂ =5	
Age , years–mean(SD)	11.6 ± 5.2	14.4 ± 6.7	
Age Group , years			
0–10	2	2	
11–20	3	2	
21–30	0	1	
Sex			
Male	4 (80)	2 (40)	
Female	1 (20)	3 (60)	
Time of follow-up months (SD)	12,6 (5,55)	26,6 (2,07)	0.008
Tumor Location			>0.999
Proximal femur	3 (60)	2 (40)	
Proximal humerus	1 (20)	2 (40)	
Radius	0 (0)	1 (20)	
Calcaneus	1 (20)	0 (0)	
Tumor Location			
Metaphyseal	4 (80)	3 (60)	
Diaphyseal	1 (20)	2 (40)	
Pathological Fracture			
Yes	1 (20)	3 (60)	
No	4 (80)	2 (40)	

*P-value is analyzed using exact Fisher Test for proportional data, and parametric independent-T Test for numerical data

Both groups showed improvement of MSTS score from month to month. MSTS score was higher in the PSI group than in curettage group and showed statistically significant difference at month 3 ($p = 0.032$) and month 6 ($p = 0.008$) after surgery. (Table 2).

Table 2: Functional outcome of SBC patient on the 1st month, 3rd month, 6th month, and 12th month after surgery

	All subjects	PSI N1=5	Curettage + HA N2=5	p-value*
MSTS score, median				
Month 1	9.0 (7.8–10.0)	9.0 (7.5–10.5)	9.0 (7.5–9.5)	0.548
Month 3	15.0 (13.8–16.3)	16.0 (15.0–18.0)	14.0 (13.0–15.0)	0.032
Month 6	22.5 (20.8–26.0)	26.0 (23.5–26.5)	21.0 (19.5–22.0)	0.008
Month 12	28.0 (29.5–30.0)	28.0 (30.0–30.0)	26.5 (29.0–30.0)	0.690

*P-value is analyzed using exact Fisher Test for proportional data, and Mann-Whitney U for numerical data

DISCUSSION

SBC or unicameral bone cyst also known as solitary bone cyst is a benign unilocular tumor or partially septed fluid-filled cyst. The combination of substance inside the fluid containing prostaglandins, free oxygen radical, interleukins, cytokines and metalloproteinases as well as the pressure of the fluid inside the cyst which is higher compared to pressure on the bone marrow result in bone necrosis. Although some SBCs will spontaneously recover, the other lesions may enlarge until causing symptoms that require treatment.^{8,10,11}

Male and female ratio patient is 1.5 : 1 with a peak incidence in the second decade of age (5 of 10) followed by the first decade (4 of 10) and the third decade (1 of 10). Yandow reported that the male to female ratio is 3 : 1 and Dorman stated male to female ratio is 1 : 1.⁸ In previous studies, the relationship between basic characteristics with bone healing and SBC recurrence remains controversial. Those confirm that there is a significant relationship between the size of the cyst and the patient's age but not on gender, location and type of cyst, and pathologic fracture.^{12,13}

PSI has been used for long in SBC and still a recommendation on SBC treatment. It was firstly performed by Scaglietti et al. In 1979, which reported a high rate of bone healing after injection.^{14,15} The role of methylprednisolone in enhancing bone healing is by reducing the cyst fluid production from the inner cyst wall with its anti-prostaglandin effect or by decreasing the cyst pressure after initially drilling a hole and aspirating the fluid.^{14,16-18} In other hand, SBCs were initially treated with curettage and bone grafting, but the recurrence rate was 40-60%. Curettage may eradicate the source of osteolytic enzymes by ridding the cyst membranes. Either autograft or allograft or HA may be used to fill the cavity. HA as a bone graft substitute also serves as an osteoconductive for bone healing process.^{18,19}

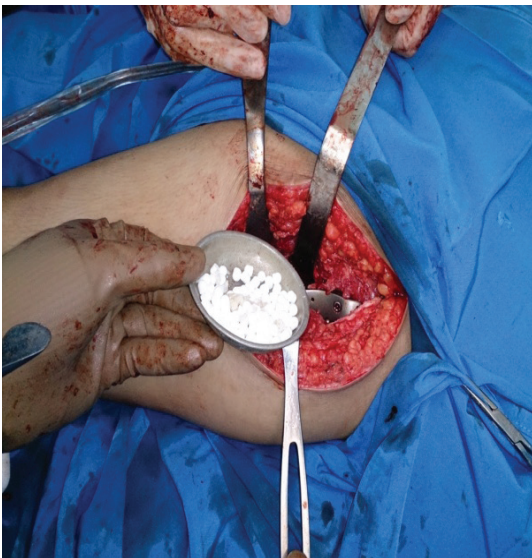
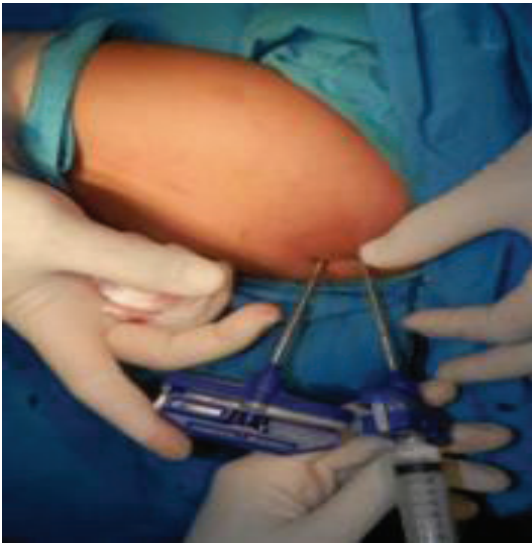
Figure 1: Intra-operative therapy with: A. PSI and B. Curettage with HA

In the PSI group, 3 of 5 subjects had SBC in the proximal femur, 1 in proximal humerus and 1 in calcaneus. All subjects in this group showed a complete bone healing. Complete bone consolidation was evaluated radiographically (figure 2).^{12,13} This result was similar to study conducted by A. Hashemi-Nejad and Cole.¹³ However, they concluded that the healing response of PSI is unpredictable and usually incomplete even after the repeated injections. Some studies reported that PSI highly reduced the amount of the cyst volume.^{12,20,21}

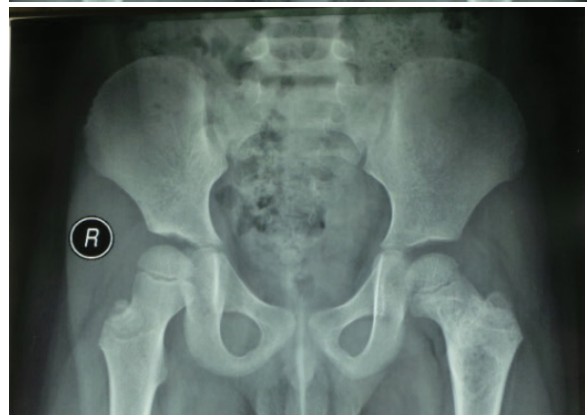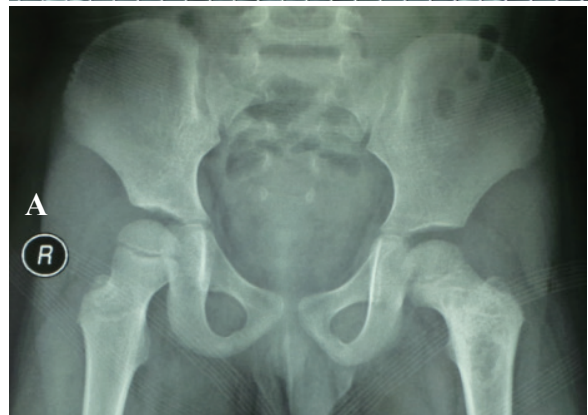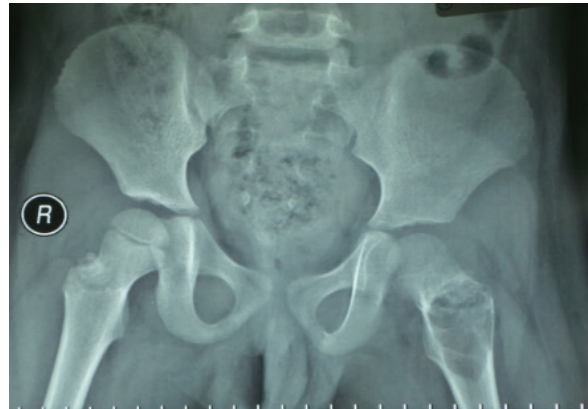


Figure 2: Hip X-Ray of PSI therapy in SBC patient: A. Before surgery, B. Month 6 after surgery, C. Month 12 after surgery.

Three of 5 patients in curettage combined with HA came to us with pathological fracture. After having curettage and HA, the fracture was stabilized with internal fixation. All cases in this group with or without pathologic fracture demonstrated complete bone healing (figure 3). This result was supported by previous study which showed 100% complete healing with this treatment.²⁰

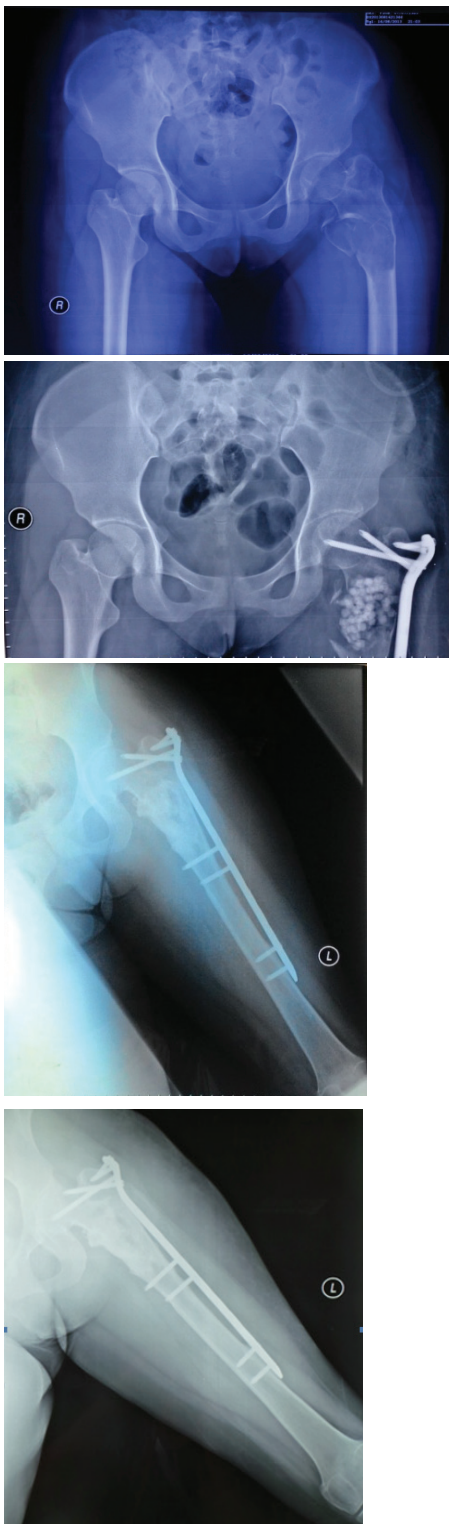


Figure 3: Hip and Femur X-Ray of Curettage therapy in SBC patient: A. Before surgery; B. Month 1 after surgery; C. Month 6 after surgery; D. Months 12 after surgery.

Several predictive factors for therapy such as age, cyst size, sex, location of the cyst, and the type (active/latent), the presence of pathological fracture has been investigated. Hashemi-Nejad and Cole said that there was no significant relationship between radiological result and cyst size, type of cyst or age of the patient.²⁰ Chang et al., reported significant relationship between the size of the cyst and the patient's age, but not on gender, location, type of cyst, and pathologic fracture.²¹ A meta-analysis of SBC therapy showed that the curettage therapy had higher bone healing (98.7%) compared to steroid therapy (77.4%).¹⁷ While, some studies recommended steroid therapy as a method of choice because it was easier, effective, and safe.^{12,20}

The functional outcome MSTs is into upper and lower extremity with a maximum score of 30. In this study the total amount presented in the form of a percentage was divided into four categories, namely: poor if < 25%, fair when 25-49%, good 50-75% and excellent > 75-100%. The MSTs score on PSI group was higher than curettage group. All patients treated by PSI could walk without supported aids at month 4 after surgery. In contrast, the patients treated by curettage and HA walked full weight bearing at month 12. From the small number of those cases, it may be concluded that PSI therapy has outcome than the curettage and HA therapy. It was radiologically supported with complete solid union. PSI group tended faster solid union than curettage group. Fortunately, at month 12 after surgery both groups demonstrated the excellent functional outcome and complete bone healing (Table 2).

CONCLUSIONS

As a conclusion, PSI tended to faster and had similar functional outcome than curettage and HA. Considering the simplicity of procedure, low cost, and high availability, PSI can be used as a choice of treatment for patients with SBC. However, further studies with larger sample are needed.

CONFLICT OF INTERESTS

The authors declare that there is no conflict of interests regarding the publication of this paper.

ETHICAL APPROVAL

This study had been approved by Health Research Ethic Committee.

AUTHOR CONTRIBUTION

AFK and YP write the paper, performed the operation and scientific analysis. RA performed the documentation of the patient and follow up care, assisted in operation and draft writing.

REFERENCES

- Milan Kokavec , Martina Frištakova , Peter Polan, Gadi M. Bialik. Surgical options for the treatment of simple bone cyst in children and adolescents. *IMAJ* 2010 February;12Capanna R, Dal Monte A, Gitelis S, Campanacci I. M. The natural history of unicameral bone cyst after steroid injection. *Clin Orthop Relat Res.* 1982;166: 204-11.
- Lokiec F, Ezra E, Khermosh O, Wientroub S. Simple bone cysts treated by percutaneous autologous marrow grafting. A preliminary report. *J Bone Joint Surg Br* 1996;78-B:934-7.
- Lokiec F, Ezra E, Khermosh O, Wientroub S. Simple bone cysts treated by percutaneous autologous marrow grafting A preliminary report. *J Bone Joint Surg [Br]* 1996;78-B:934-7.
- Ulici A, Balanescu R, Topor L, Barbu M. The modern treatment of simple bone cysts. *J Medicine Life* 2012;5:469-473
- Kao ST, Scott DD. A Review of Bone Substitutes. *Oral Maxillofacial Surg Clin N Am.* 2007;19:513-21.
- Sakamoto A, Matsuda S, Yoshida T, Iwamoto Y. Clinical outcome following surgical intervention for a solitary bone cyst: emphasis on treatment by curettage and steroid injection. *J Orthop Sci.* 2010;15:553-9
- Yandow S. What is the Best Treatment for Simple Bone Cysts. In: James G. Wright, editor. Evidence-Based Orthopaedics: Elsevier; 2009. p. 683-702.
- Blokhuis TJ, Chris JJ. Bioactive and osteoinductive bone graft substitutes: Definitions, facts and myths. *Injury. Int J Care Injur* 2011;42:26-9.
- Mylle J, Burssens A, Fabry G. Simple Bone Cysts. *Arch Orthop Trauma Surg.* 1992;111:297-300.
- Suei Y, Taguchi A, Nagasaki T, Tanimoto K. Radiographic findings and prognosis of simple bone cysts of the jaws. *Dentomaxillofac Radiol.* 2010;39(2):65-72.
- Glowacki M, O'Byrne AI, Ignys I, Mankowski P, Melzer P. Evaluation of Volume and Solitary Bone Cyst Remodeling using Conventional Radiological Examination. *Skeletal Radiology* 2010;39:251-
- Hashemi-Nejad A, Cole WG. Incomplete Healing of Simple Bone Cysts after Steroid Injections. *J Bone Joint Surg.* 1997;79-B(5).
- Ozturk A, Yetkin H, Memis L, Cila E, Bolukbasi S, Gemalmaz C. Demineralized bone matrix and hydroxyapatite/tri-calcium phosphate mixture for bone healing in rats. *International Orthop (SICOT)* 2006;30:147-52.
- Nilsson M, Wang JS, Wielanek L, Tanner KE, Lidgren L. Biodegradation and biocompatibility of a calcium sulphate-hydroxyapatite bone substitute. *J Bone Joint Surg.* 2004;86:120-5
- Enneking WF. A system for the functional evaluation of reconstructive procedures after surgical treatment of tumors of the musculoskeletal system. *Clin Orthop Relat Res.* 1993-(286):241-6.
- Hou H-Y, Wu K, Wang C-T, Chang S-M, Lin W-H, Yang R-S. Treatment of Unicameral Bone Cyst. *J Bone Joint Surg.* 2010;92:855-62.
- Ramachandran M. Bone grafting Basic orthopaedic sciences. London: Hodder Arnold; 2007. p. 128-32.
- Ozdemir MT, Kir MC. Repair of long bone defects with demineralized bone matrix and autogenous bone composite. *Indian J Orthop.* 2011;45(3):226-30.
- Aliabadi A, Esfandiari A, Farahmand M, Mahjoor A, Mojaver S. Evaluation of the effects of bovine demineralized bonematrix and coralline hydroxyapatite on radial fracture healing in rabbit. *J Cell Animal Biology* 2012;6(7):109-14.
- Chang C, Stanton R, Glutting J. Unicameral bone cyst treated by injection of bone marrow or methylprednisolone. *J Bone Joint Surg.* 2002;84:407-12.