

Edge Detection on Objects of Medical Image with Enhancement multiple Morphological Gradient Method

Jufriadif Na'am

Computer Science Faculty
Universitas Putra Indonesia YPTK
Padang, Indonesia
jufriadifnaam@gmail.com

Abstract—Medical image is an invaluable tool in the detection of diseases or abnormalities in human organs. The low quality of medical images cause difficulty in observing the objects contained in the image, causing errors in detection. This research develops a method for improving the quality of medical images so that the edges of objects more clearly. This method is called Enhancement multiple Morphological Gradient Enhancement (EmMG). The method used at medical images had different formats, that as Computed Tomography Scan (CT-Scan) with format type Windows bitmap (bmp), Chest X-Ray with format type Joint Photographic Experts Group (jpg) and Panoramic X-Ray with format type Portable Network Graphics (png). The method developed produces images that can further clarify the edge of the object in the medical image, making it easier to detect diseases or abnormalities in the human body. This method can be used as one of the solutions in medical help to improve the accuracy in detecting objects in medical images because the edge of the objects seen clearly.

Keywords— *CT-Scan; chest X-Ray; Panoramic X-Ray; edge detection; Enhancement multiple Morphological Gradient (EmMG).*

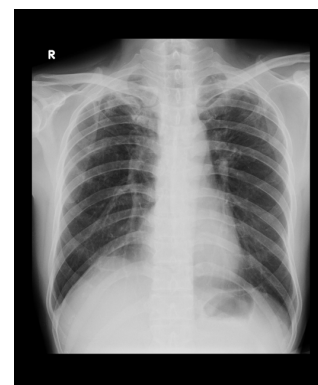
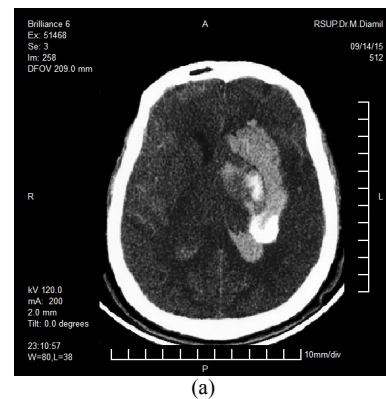
I. INTRODUCTION

Medical image is created by using Computed Radiography equipment. It is showing of human organs. Medical image used for clinical purpose to diagnose and visually express diseases in the fields of medicine, including studies about the anatomy and physiology [1]. Some types of medical images are stored directly on Computed Radiography. The medical image type was CT-Scan, Chest X-Ray and Panoramic X-Ray.

CT-Scan is a procedure which is used to obtain two-dimensional grayscale images that a depiction of various small area of bone, including the skull and brain. Image acquisition or recording the results of a CT-Scan can help to clarify the reasonable suspicion of abnormalities that occur in the brain, such as a shows of a tumor lesion, hematoma, abscess, bleeding in the brain and changes in the form of vascular malformations as well as the rise and fall of vascularization and infarction.

Chest x-ray is a two-dimensional grayscale image obtained from the examination of a diagnostic x-rays. Chest x-ray shows of the heart, lungs, airways, blood vessels, spine and ribs.

Panoramic X-Ray is a two-dimensional grayscale images from Computed Radiography equipment that shows the entire tooth along the bone and surrounding soft tissue. Panoramic X-ray image can show cavities (caries), the hidden teeth, and bones that can show on visual examination. Fig. 1. below shows three medical images to be processed:



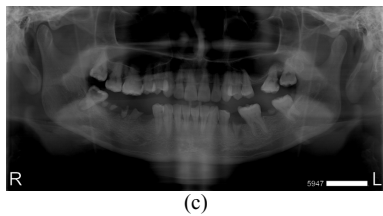


Fig. 1. Type of Medical Image (a) CT-Scan, (b) Chest X-Ray and (c) Panoramic X-Ray

To further facilitate the examination of medical images, it would require a process to clarify the object contained in the image. Image modification can improve image quality [2]. The purpose of this process is further clarify the edge of objects contained in the image. More details, the edge of objects will further clarify the information contained in the image so that it can provide a picture or object in the image reconstructed by the human visual system.

The edge of objects that difference in intensity or color of one pixel by pixel closest neighbors. The higher the intensity, the more visible differences clearly the difference object.

The edge of objects is also one of the basic image processing that important in recognizing the objects contained in the image. Basic methods of image edge detection consists of Prewitt, Sobel, Canny, Roberts, Laplacian, Kirsch and Morphology [3][4].

The following table (Table I) presents a comparative study of the different methods used edge detection in medical images (CT scans, Chest X-Ray and Panoramic X-Ray).

TABLE I. COMPARATIVE STUDY ON EDGE DETECTION IN MEDICAL IMAGE

Researcher (Year)	Edge Detection Method/ Algorithm	Type of Medical Image	Result
Divya and Lasrado (2016)	Prewitt and Sobel	CT Scan	Edge detection used for segmentation, feature extraction, measuring tumor size or volume etc [5].
Jadwa (2016)	Canny	Brain and Lung	More efficiency and better performance [6].
Yu-qian, Wei-hua, Zhen-cheng, Jing-tian and Ling-yun (2005)	Mathematical Morphology	Lungs CT Scan	Better than template-based and general morphological [7].
Kumar and Singh (2012)	Novel Mathematic Morphological	CT Scan	Better than Algorithm Sobel, Canny and morphology that uses a single structure element (fixed) [8].
Bharathi and Kabilan (2016)	Canny	CT Scan	Good to reduce errors in the early detection of lung cancer [9].

Grafova, Kasparova, Kakawand, Prochazka and Dostalova (2013)	Roberts, Prewitt, Sobel, Laplacian of the Gaussian and Canny	Panoramic X-Ray	Value Edge Mismatch Error (EME) and Modified Hausdorff Distance (MHD) is still above 0.1 (unsatisfactory) [10].
Candemir, Jaeger, Antani, Bagci, Folio, Xu and Thoma (2016)	Canny	Chest X-Ray	The various types of ribs clearly visible [11].
Goswami and Misra (2016)	Sobel, Canny, Prewitt and Roberts	X-Ray tulang	Depending on the type of image [12]

Many current research shows that the medical image is processing still evolve by the ease diagnose medical illnesses. In this study a development of the modify morphological gradient as an alternative method of edge detection object in medical images called Enhancement multiple Morphological Gradient Method (EmMG).

II. THE MATERIAL AND METHOD

This study aims to sharpen the image of the edge object of several types and file formats with the same method implemented in Matlab 2013a. The process flow in this study at the follow diagram in Fig. 2.:

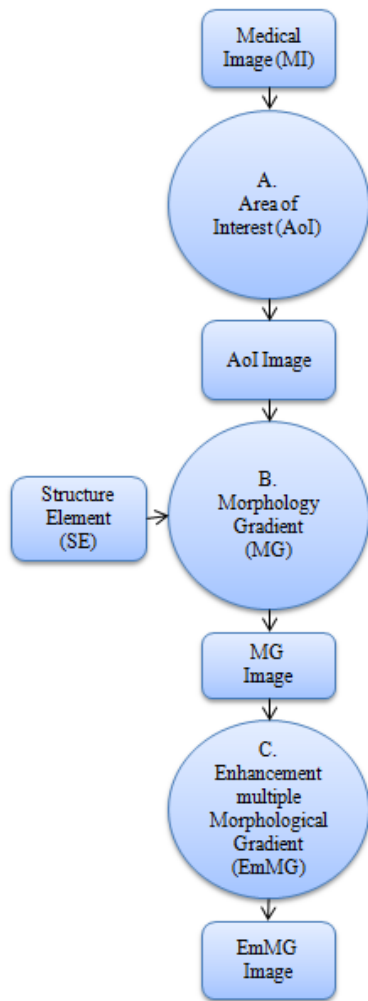


Fig. 2. Stages of process

The data-set of medical images used in this research were obtained from Department of Radiology, General Hospital Center Dr. M. Djamil Padang. Medical images had used by some researchers to examine specific topics section and shown in Table III below.

TABLE II. THE DATA-SET OF MEDICAL IMAGE

Type	Format	Total	Ref
CT-Scan	Windows bitmap (bmp)	5	[13]
Chest X-Ray	Joint Photographic Experts Group(jpg)	42	[14]
Panoramic X-Ray	Portable Network Graphics (png)	27	[15]

III. RESULT AND DISCUSSION

Stages of the research process develops from morphological methods commonly used to assist in clarifying the edge of objects in medical images based stages of process in Fig 1.

A. Area of Interest (AoI)

Area of Interest (AoI) is the process of cutting the image to retrieve the observed object only. This process will save an area defined by two diagonal points, namely point diagonal starting and ending diagonal. Diagonal point of this image can be:

- Point the top left to the bottom right point.
- Point the top right to bottom left point.
- bottom left point to the right point on.
- Point the bottom right to top left point.

The results of the second election this point get the rectangular area, as needed for subsequent processing. An illustrative example of the formation of AoI in the following Fig. 3.

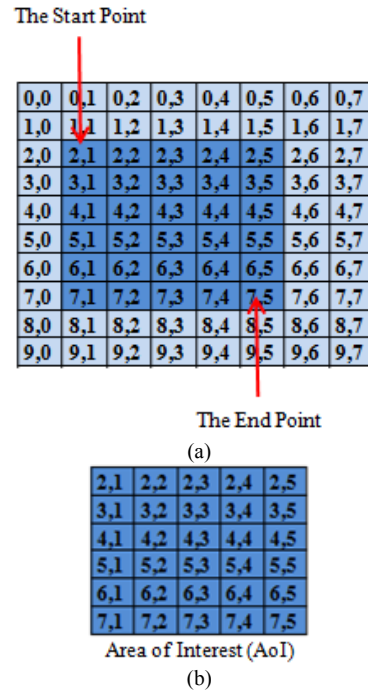


Fig. 3. Illustration Processes of AoI (a) Original Pixel, (b) AoI Pixel

The algorithm is as follows:

The AoI Algorithm

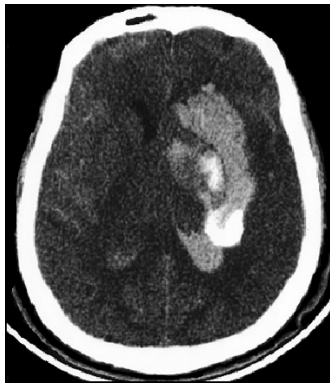
Input: $MI(i,j)$

Output: $AoI(i,j)$

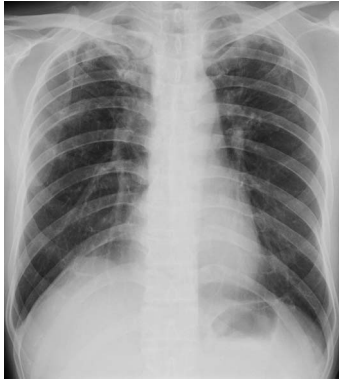Get: $linX, colX, linY, colY$

$AoI(i,j) = MI(linX:linY, colX: colY)$

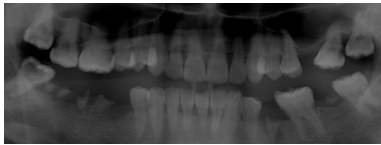
The results image of the AoI algorithm implementation in the following Fig. 4. below:



(a)



(b)



(c)

Fig. 4. Result Image of Area of Interest Illustration Processes of AoI (a) CT-Scan, (b) Chest X-Ray and (c) Panoramic X-Ray

In Fig. 4. are showing the area free from unneeded for further processing. The images saved into a file with the same format as the input image file.

B. Morphology Gradient (MG)

Morphology of the object into the image represents a mathematical set of two-dimensional shapes which are also called mathematical morphology. Morphology Gradient is an application that uses multiple processes of mathematical morphology operations against the basic operation of mathematical morphology, namely dilation and erosion.

Morphological gradient used in this study was the morphological erosion as a deduction from the image AoI. Elements required in the morphological gradient in this study consists of the image of the AoI, Structure Element and Morphology Erosion. AoI image has obtained from the above process and subsequent elements are:

1. Structure Element (SE): Structure element is a two-dimensional images as a lookup on the image of the operation.

Forms of structural elements used type of disk with size 2x2 as follows:

1	1
1	1

Fig. 5. SE type of disk 2x2

The SE does not eliminate and not shrink the size of the object to next process.

2) Morphology Erosion (ME): Morphology erosion is the process of shrinking or diluting the image objects. The illustration of ME can be seen in Fig. 6.

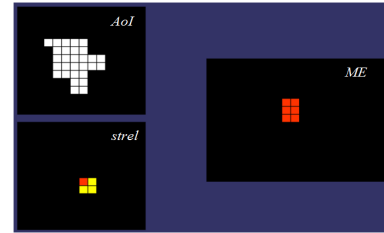


Fig. 6. Illustration ME

The number of white pixels are scaled to the image AoI based structure element above the disk image stored in ME. The formula used is as follows:

$$ME = \{z | (strel)_z \subseteq AoI\} \tag{1}$$

Where z is a shift mapping.

Morphological Gradient process to reduce the AoI image to image ME. The formula is as follows:

$$MG = AoI - ME \tag{2}$$

The algorithm is as follows:

Morphology Gradient Algorithm

Input: AoI

Output: MG

Initialization: SE = strel('disk',2)

MG = IoA - (IoA ⊖ SE)

The result image stored in the MG image. The image result of MG is shown in Fig. 7.

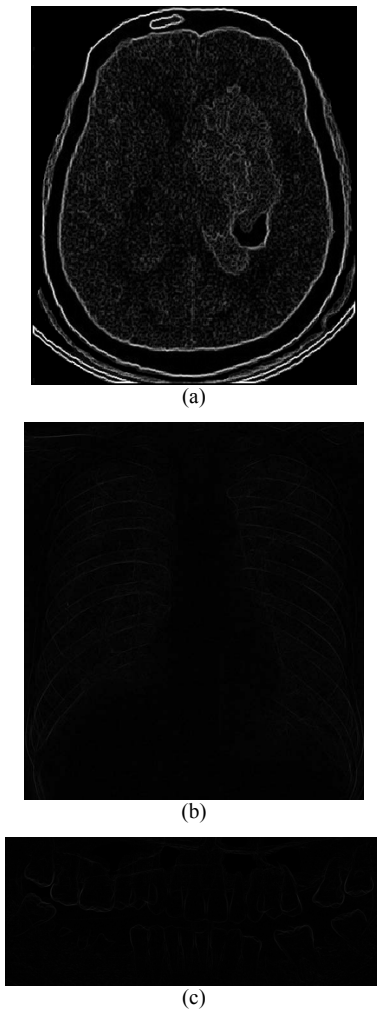


Fig. 7. Result Image of Morphological Gradient (a) CT-Scan, (b) Chest X-Ray and (c) Panoramic X-Ray

The results from the formation of the edge of objects in the morphological gradient has formed, but not clearly. To clarify this require next process to improve the quality margin (Enhancement).

C. Enhancement multiple Morphological Gradient (EmMG)

EmMG is processing to increase the value of the edge object in the image. EmMG has some elements, that is:

1) *bit Depth (bD)*: bit depth is added to the bit value contained in one image pixel. The greater the value of the pixel image into bits, the more combinations of color values that make up each pixel image and the better the image quality. The purpose of the use value of the bit depth get value multiple (multiplier) of pixels that have a higher value gray (white) so as to further clarify the boundary edge.

2) *maximum Pixel(mP)*: Maximum Pixel is the highest pixel values in the image. The higher value was even greater multiple, so it will affect the value of multiple. Highest pixel is processing the result of Morphological Gradient image.

$$mP = \max_{lin=1}^i \max_{col=1}^j MG(lin, col) \quad (3)$$

3) *multiple(m)*: multiple is a value multiplier to increase the value of a particular pixel in the image [16]. By improving a particular pixel was able to clarify the edge objects contained in the image of the morphological gradient. The formula is:

$$m = mP / bD \quad (4)$$

4) *minimum Multi Threshold (mMT)*: Multi Threshold is a histogram partition dividing an image into several groups based on certain thresholds.

The formula is:

$$MT_A(MG) = \begin{cases} 1, A < mP \\ : \\ bD, A \geq mP \end{cases} \quad (5)$$

Minimum Multi Threshold is the threshold value of the lowest partition or partition level 1 to the value of the lowest gray partitions, so that each pixel has a value above grayish partition 1 increased in value. The formula to get the lowest partition limit values are as follows:

$$mMT = MT_1(MG) \quad (6)$$

Having obtained the minimum Multi Threshold value, then the pixels in the image Gradient Morphology results that have a higher value than the mMT multiplied by the value of m [17]. The formula is as follows:

$$EmMG_{lin=1, col=1}^{i,j} = m * MG_{lin=1, col=1}^{i,j}, \quad (7)$$

$$\text{if } MG_{lin=1, col=1}^{i,j} \geq mMT$$

EmMG with the algorithm as follows:

EmMG Algorithm

Input: $MG(i,j)$

Output: $XmMG$

Initialization: $m, min=1, lin, col, mP$

Get: bD, mMT

$mP=0$

for $lin=1:i$ do

 for $col=1:j$ do

 if $mP < MG(lin, col)$ then

$mP = MG(lin, col)$

 end if

 end do

end do

```

m=mP/bD
for lin=1:i do
  for col=1:j do
    if MG(lin,col) >=mMT then
      XmMG(lin,col)=MG(lin,col)*m
    end if
  end do
end do
end do

```

After this EmMG obtained the image with gray pixel values that form the edge object is higher (white), so that the edge clearly [18]. The results EmMG image in the following Fig. 8. below:

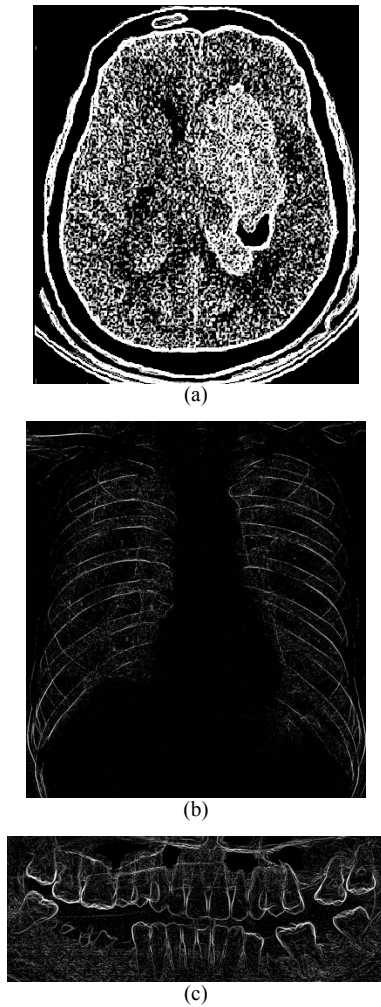


Fig. 8. Result Image of Enhancement multiple Morphological Gradient (a) CT-Scan, (b) Chest X-Ray and (c) Panoramic X-Ray

The edge objects in image is more clearly, so it can easy to detect objects that are contained in the medical image

IV. CONCLUSIONS

The results of this study can improve the quality of information in medical image. EmMG image is clearly of objects contained in medical image. This study is alternative to improve the quality of the image so that it is using in medicine to detect diseases or objects in medical images

because the edge of the objects seen clearly. In this regard I feel that this survey would be useful for researchers.

Acknowledgment

We would like to thank the Head of Department of Radiology, General Hospital Center M. Djamil Padang, which has allowed the use of the data in this study.

References

- [1] Madenda S., *Pengolahan Citra & Video Digital*, Jakarta: Erlangga, p. 16, 2015.
- [2] Supriyanti R., Suwitno, Ramadhani Y., Widodo H.B and Rosanti T.I, "Brightness and Contrast Modification in Ultrasonography Images Using Edge Detection Results", *TELKOMNIKA*, Vol.14, No.3, pp. 1090-1098, 2016.
- [3] Kasi M. K., Rao J. B. and Sahu V. K, "Identification of Leather Defects Using an Autoadaptive Edge Detection Image Processing Algorithm", *IEEE*, 2014.
- [4] Baoming Q., Liu J. and Yufan Y., "An Adaptive Algorithm for Grey Image Edge Detection Based on Grey Correlation Analysis", *12th International Conference on Computational Intelligence and Security*, pp. 470-474, 2016.
- [5] Divya and Lasrado S., "Medical Image Analysis on Software and Hardware System", *International Journal of Innovative Research in Science, Engineering and Technology*, Vol. 5, No. 9, 2016, pp. 414-419.
- [6] Jadwa S. K., "Canny Edge Detection Method for Medical Image Retrieval", *International Journal of Scientific Engineering and Applied Science*, Vol. 2, No. 8, 2016, pp. 54-59.
- [7] Yu-qian Z., Wei-hua G., Zhen-cheng C., Jing-tian T. and Ling-yun L., "Medical Images Edge Detection Based on Mathematical Morphology", *IEEE Engineering in Medicine and Biology 27th Annual Conference Shanghai, China*, 2005.
- [8] Kumar M. and Singh S., "Edge Detection and Denoising Medical Image Using Morphology", *International Journal of Engineering Sciences & Emerging Technologies*, Vol. 2, No. 2, 2012, pp. 66-72.
- [9] Bharathi C. J. and Kabilan P., "Analysis and Edge Detection of Lung Cancer – Survey", *International Journal on Recent and Innovation Trends in Computing and Communication*, Vol. 4, No. 5, pp.390-392, 2016.
- [10] Grafova L., Kasparova M., Kakawand S., Prochazka A. and Dostalova T., "Study of edge detection task in dental panoramic radiographs", *Dentomaxillofacial Radiology*, Vol 42, paper 202120391, pp. 1-12, 2013.
- [11] Candemir S., Jaeger S., Antani S, Bagci U., Folio R.B., Xu Z. and Thoma G., "Atlas-based rib-bone detection in chest X-rays", Vol. 51, pp. 32-39, 2016.
- [12] Goswami B. and Misra S.K., "Analysis of Various Edge Detection Methods for X-ray Images", *International Conference on Electrical, Electronics, and Optimization Techniques (ICEEOT)*, pp. 2694-2699, 2016.
- [13] Sumijan, Madenda S, Harlan J. and Wibowo E.P, "Hybrids Otsu method, Feature region and Mathematical Morphology for Calculating Volume Hemorrhage Brain on CT-Scan Image and 3D Reconstruction", *TELKOMNIKA*, Vol 15, No 1, pp. 283-291, 2017.
- [14] Santony J. and Na'am J, "Infiltrate Object Extraction in X-ray Image by using Math-Morphology Method and Feature Region Analysis", *International Journal on Advanced Science, Engineering and Information Technology*, vol. 6, no. 2, pp. 239-244, 2016
- [15] Na'am J., "Accuracy of Panoramic Dental X-Ray Imaging in Detection of Proximal Caries with Multiple Morphological Gradient (mMG) Method", *International Journal on Informatics Visualization*, vol. 1, no. 1, pp. 6-12, 2017.
- [16] Na'am J., Harlan J., Madenda S. and Wibowo E.P., "Identification of the Proximal Caries of Dental X-Ray Image with Multiple Morphology Gradient Method", *International Journal on Advanced Science*,

Engineering and Information Technology, vol. 6, no. 3, pp. 343-346, 2016.

- [17] Na'am J., Harlan J., Madenda S. and Wibowo E.P., "The Algorithm of Image Edge Detection on Panoramic Dental X-Ray Using Multiple Morphological Gradient (mMG) Method", *International Journal on Advanced Science, Engineering and Information Technology*, vol. 6, no. 6, pp. 2012-2018, 2016.
- [18] Na'am J., Harlan J., Madenda S. and Wibowo E.P., "Image Processing of Panoramic Dental X-Ray for Identifying Proximal Caries", *TELKOMNIKA*, Vol 15, No 2, pp. 702-708, 2017.