

Research Report

Stimulation of type I collagen activity in healing of pulp perforation

Sri Kunarti

Department of Conservative Dentistry
Faculty of Dentistry Airlangga University
Surabaya - Indonesia**ABSTRACT**

Background: TGF- β 1 is a connective tissue stimulant, potential regulator for tissue repair, and promoter in wound healing. The healing of pulp perforation is decided by quantity and quality of new collagen deposition. TGF- β 1 upregulates collagen transcription. However, after several weeks production of type I collagen synthesis is stopped and enzymatic degradation of collagen matrix will occur. **Purpose:** Observe synthesis type I collagen during the process of pulp perforation healing in 7, 14, and 21 days after being treated using TGF- β 1. **Methods:** This research in vivo from orthodontic patients indicated for premolar extraction, between ages 10–15 years. A class V cavity preparation was created in the buccal aspect 1 mm above gingival margin until pulp exposure. Cavity was irrigated slowly with saline solution and dried with a sterile small cotton pellet. The sterile absorbable collagen membrane used, soaked with 5 μ l of TGF- β 1. It was covered by teflon pledge to separate from glass ionomer cement as restoration. Evaluated on day 7th, 14th, and 21st. All samples were extracted and prepared for immunohistochemical examination. **Result:** Data were analyzed by *t*-test. There was significant difference in synthesis type I collagen compared between 7–14 days and 7–21 days after treatment by TGF- β 1 also Ca(OH)₂. There was significant difference compared between TGF- β 1 and Ca(OH)₂ in 14–21 days after treatment (means TGF- β 1 > Ca(OH)₂). **Conclusion:** Elevation of synthesis type I collagen by TGF- β 1 in 20 mg/ml.

Key words: type I collagen, TGF- β 1, calcium hydroxide, pulp perforation

Correspondence: Sri Kunarti, c/o: Departemen Konservasi Gigi, Fakultas Kedokteran Gigi Universitas Airlangga. Jl. Mayjend. Prof. Dr. Moestopo no. 47 Surabaya 60132, Indonesia. E-mail: attybp@yahoo.com

INTRODUCTION

Remarkable vascularized granulation tissue is shown in the initial recovery process followed by fibroblast proliferation and decreasing proportion of vascularized and fibroblast tissue of collagen formation. Granulation tissue is gradually replaced by more elastic and regular extra cellular matrix containing most component of type I collagen. During transitional period from granulation tissue to scar, collagen remodeling depends on the balance between synthesis catabolism and further deposition.^{1,2} Epithelial tissue is not found in pulp structure, therefore, there is no epithelial response in pulp recovery process but the response of fibroblast tissue is similar to both tissues and collagen as the product of scar tissue formation and continued by mineralization to form reparative dentin.³ Collagen family is at least consisting of 30 different gens

which producing 19 types of collagen. Mesenchim cell and its derivates (fibroblast, odontoblast, and cementoblast) are the major collagen producers. The other types of cell (epithel, endothel and muscle) also synthesize collagen although in little amount and few types. Type I, II, III, IV, and XI collagen are combined in extra cellular to form febrile. Fibroblast tissue is mostly containing type I collagen, then, type III (reticular fibroblast) and type V is usually found between type I and III expected to regulate fibrile's diameter. Type I collagen is the most dominant collagen in dentine (86%), while type I and II collagen could be found in pulp. Type I collagen is synthesized and secreted by odontoblast, then, penetrates into dentine matrix, while fibroblast produces type I and III collagen in pulp.^{3,4}

The information on the application of exogenous TGF- β 1 to stimulate reparative dentinogenesis is still not much

available. The combination of TGF- β 1 has the capability to stimulate reactive response if it is administered directly on the odontoblast layer. However, only part of dentine matrix containing TGF- β 1 shows positive response if it is applied in imperforated cavity.⁵ The application of exogenous TGF- β 1 is expected as a booster on endogenous TGF- β 1 to increase the existing character such as: to stimulate fibroblast proliferation, to regulate cell attachment, to increase transcription of new collagen, to trigger inactive cell in G₀ phase entering G₁ active phase, to overcome healing disturbance.⁶ The regulation of bioactivity of TGF- β 1 in the inside part of dentin matrix is important due to the presence of TGF- β 1 inside dentine matrix is capable to influence cell behavior surrounding dentine-pulp complex.⁷ TGF- β 1 is secreted as latent precursor molecule which could be activated by various factors. Approximately half of TGF- β 1 is isolated from dentine matrix has been reported to be active form although the presence of other molecules inside ECM modulating the capability and activity of TGF- β 1. For examples: proteoglycan and betaglycan can stimulate TGF- β 1 and make the appearance easier in cell surface, while decorine can bind and inhibit the activity of growth factor.⁷ The aim of this study is to observe synthesis type I collagen during the process of pulp perforation healing in 7, 14, and 21 days after being treated using TGF- β 1.

MATERIALS AND METHODS

First premolar extraction was done for orthodontic treatment prepared for the sample of this study and fulfilling the requirement of having vital condition, non caries and intact, aged 10-20 years old, having positive result of cold test using ethyl chloride, percussion and compression test is negative, clinically healthy and having good general condition.

The total number of samples was 48 classified into TGF- β 1 and Ca(OH)₂ groups which were divided into three subgroups. Extraction was performed 7 days after treatment in subgroup 1, 14 days after treatment in subgroup 2 and 21 days after treatment in subgroup 3. Firstly, anesthesia was done in buccal fold using 0.6 ml xylestesin F, rubber dam and saliva suction were applied and continued by tooth disinfected using 70% alcohol in buccocervical region. Cavity preparation on buccal side was done 1 mm above the gingival margin, intermittent bur with light pressure was used, preparation was slantingly done toward apical using round bur no 3 with 1.5 mm diameter until closed to pulp, then, followed by using round bur no 1 with 0.5 mm to penetrate thin dentine layer until perforation reached pulp region. Cavity was slowly irrigated using 0.5 ml saline solution⁷ and dried by sterile cotton pellet. TGF- β 1 group was treated using 20 mg/ml concentration of TGF- β 1 applied by dropping 5 μ l in 1 mm² absorbable collagen membrane as carrier (done in laminar flow hood) put into eppendorf tube and kept in nitrogen liquid at -80°C. The membrane was applied on the perforation, covered by Teflon pledged and filled by restorative material type II

glass ionomer cement then varnish. For Ca(OH)₂ group (visible light group), Ca(OH)₂ was applied in 1 mm diameter tube and visible light cured tool was prepared. 1mm Ca(OH)₂ was administered in the bottom of cavity and illuminated for 40 sec in the shortest distant and covered by Teflon pledged, filled type II glass ionomer cement and polished by varnish.

The preparation of immunohistochemistry initiated since tooth extraction was done. Fixation was performed using 10% buffer formalin for 48 hours followed by decalcification applying AlCl₃, formic acid, 37% HCl and aquadest. Further process was dehydration to extract the water from the tissue and replaced by paraffin, continued by clearance using xylene. After the paraffin was hardened, the tissue could be cut using microtome in 4 μ m thickness. Deparaffin and rehydration were subsequently performed: slide was soaked in xylol for 5 minutes and in absolute ethanol for 5 minutes. Followed by being soaked in 95% ethanol for 5 minutes and it was all done twice; then, washed by flowing aquadest minimally for 30 sec. Slide was then soaked in 0.01 M citrate buffer and put into the microwave for 30 minutes at 60°C. Trypsine was done in 15 minutes at room temperature with 0.025% (w/v) trypsin (1 : 250) in Phosphate Buffer Saline (PBS). The sample was washed using PBS than incubated in 3% hydrogen peroxide for 5 minutes to eliminate endogenous peroxide, than, washed by PBS.

Primary antibody type 1 collagen monoclonal antibody was diluted by antibody diluent (containing 0.05 M Tris-HCl buffer pH 7.2-7.6, 1% bovine serum albumin) with ratio 1 : 200. Incubation was done for 12 hours, next, it was washed by PBS. Secondary antibody biotinylated link human anti rabbit was dropped, incubated for 10 minutes, was wash by PBS. Streptavidin HRP was dropped and incubated for 10 minutes, washed by PBS. Substrate-chromogen solution: DAB chromogen (0.05% 3-3'-diaminobenzidine) diluted by substrate buffer with ratio 1 : 50, incubated for 10 minutes. Counterstained using haematoxyline Mayer for 1-2 minutes until the color was blue, washed by flowing water and dried. It was given entelan, and covered by cover glass. Light microscope was applied and the evaluation was done by two observers.

RESULT

The region which would be evaluated was dark brown observed and magnified 40 times of the perforation region located between two dentin walls using graticule. The number of graticules in perforation region was observed and the evaluation was done 400 times magnification in all sub groups. Figure 1-A and 1-B showing the sample of type I collagen synthesis 14 days and 21 days after being given TGF- β 1.

The mean and standard deviation of each group resulting from immunohistochemistry study done in 7, 14, and 21 days (Table 1).

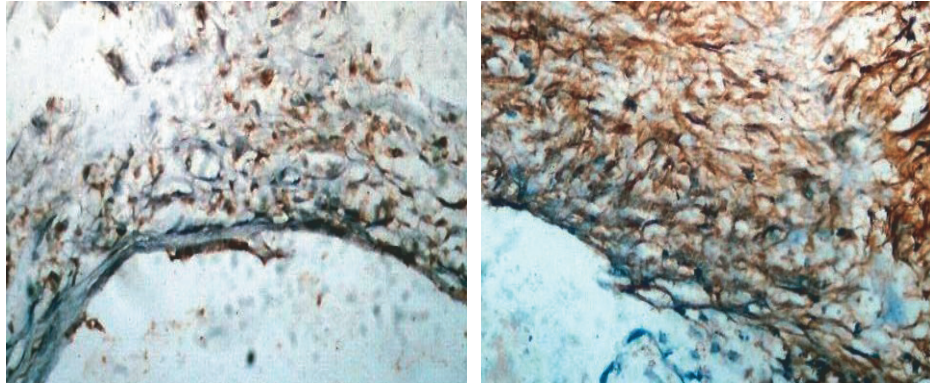


Figure 1. (A) Pulp tissue with the elevation of type I collagen synthesis, 14 days after being given TGF-β1 (400× magnification); (B) Pulp tissue with the elevation of type I collagen synthesis, 21 days after being given TGFβ1 (400× magnification).

Table 1. The mean and standard deviation of TGF-β1 and Ca(OH)₂ groups on day 7th, 14th, 21st after treatment

Variable	Material	7 days		14 days		21 days	
		Mean	S.D	Mean	S.D	Mean	S.D
Type Collagen	TGF-β1	6.6250	2.3867	27.2500	8.1372	30.6250	11.1604
	Ca(OH) ₂	3.3750	3.6621	18.8750	7.2592	17.1250	6.7493

The main of type 1 collagen in 7, 14 and 21 days after treatment showing TGF-β1 was higher compared to Ca(OH)₂ group. Either TGF-β1 group indicating the elevation of mean in 7, 14, 21 days after treatment using Kolmogorov-Smirnov statistical test showed normal distribution ($p > 0.05$) in which fulfilling the requirement of parametric test. The result of homogeneity test using Levene test in TGF-β1 and Ca(OH)₂ groups as well as between TGF-β1 groups ($p < 0.05$). ANOVA test showed there were significant difference between Ca(OH)₂ groups, and also between TGF-TGF-β1 groups. Dunnet T3 test and t-test performed between TGF-β1 as well as between Ca(OH)₂ groups (Table 2). T-test was also done comparing between TGF-β1 and Ca(OH)₂ groups (Table 3).

Table 2. Level of significance showed in 7–14 days, 14–21 days and 7-21 days between TGF-β1 and Ca(OH)₂ groups

Variable	Period of time	P	
		TGF-β1	Ca(OH) ₂
Type 1 collagen	7–14 days	0.000*	0.000*
	7–21 days	0.001*	0.000*
	14–21 days	0.866	0.572

Note: * = significant difference

Significant difference of p value in TGF-β1 group of type I collagen comparing between 7–14 days and 7–21 days while significant difference of p value in Ca(OH)₂ group of type collagen comparing between 7-14 days and 7–21 days.

Table 3. Level of significance in comparison between TGF-β1 and Ca(OH)₂ groups in 7, 14, 21 days

Variable	P value		
	TGF-β1 - Ca(OH) ₂ groups		
	7 days	14 days	21 days
Type I collagen	0.057	0.047*	0.011*

Note: * = significant difference

There was no significant difference in p value between TGF-β1 and Ca(OH)₂ in period of 7 days ($p > 0.05$) while significant difference was found in 14-21 days ($p < 0.05$).

DISCUSSION

In this study, the role of TGF-β1 was clearly seen in synthesis type I collagen. Formation of type I collagen in perforation region occurred in the whole samples of TGF-β1 on day 7, comparing to Ca(OH)₂ group, significant difference was found in TGF-β1 group in comparison between 7–14 days and 7–21 days while significant difference was not found in 14–21 days. This study also showed progressive elevation on day 7 until day 14 meanwhile a little elevation was shown on day 14 until day 21. due to the lower concentration of TGF-β1 on wound healing.¹ Soon after the wound occurred in an hour, the concentration of TGF-β1 actively increased until 9 times higher, in which it was the peak concentration of TGF-β1, then, decreasing in 24 hour period however it was still higher

than normal condition. The second peak concentration would occur 5 days after the occurrence of wound and 14 days the wound the active concentration of TGF- β 1 would return to normal. The addition of exogenous TGF- β 1 would increase the total number of active TGF- β 1 resulting in more remarkable effect. During healing process, some kinds of cells including macrophage, fibroblast, endothelial cell, keratinocyte would migrate to the wound region in which they would produce and active TGF- β 1. the second peak concentration of active TGF- β 1 which is present on day 5 would contribute the elevation of wound healing.⁸ TGF- β 1 is stimulant of fibroblast tissue cell, a potent regulator as well as a promoter in wound healing, in addition TGF- β 1 has unique character and stimulates ECM deposition by increasing matrix protein synthesis and decreasing matrix degradation in which both conditions could be achieved by decreasing protease synthesis and increasing protease inhibitor synthesis. TGF- β 1 also increased synthesis integrin receptor, therefore there is an increase interaction between cells and ECM.⁹ The healing of perforation wound would be determined by the number and the quality of new collagen deposition. After some weeks synthesis collagen is stopped and enzymatic degradation of collagen matrix would occur, this condition would contribute the balance of collagen formation. Synthesis and lysis are strictly controlled by cytokine and growth factor. TGF- β 1 plays the role of increasing new collagen transcription and the production of collagen would be lowered by tissue inhibitors of metalloproteinase (TIMP). The balance between deposition and degradation of collagen would determine the integrity and the strength of tissue.¹⁰ Mechanism of collagen degradation would occur through enzyme secretion done by cell and extra cellular matrix molecule or collagen fibril selection and intra cellular degradation by fibroblast.³ Triple helix collagen is really resistant against proteolytic reaction. Matrix metalloproteinase (MMP) family is proteolytic enzyme is capable of degrading collagen and other macromolecule matrix to be small extra cellular peptide. MMP is synthesized and secreted by fibroblast, inflammation cell and other cells. A number of cells secrete MMP inhibitor in active condition, then, through proteolytic process becoming active. Intracellular degradation is most important mechanism in physiologic condition and remodeling collagen fibroblast tissue.⁴ The application of topical TGF- β 1 would increase breaking strength which could be clearly seen in ECM especially synthesis and deposition collagen.¹ The formation of collagen occurs on day 3 and more extensive after day 7.¹¹ Well arranged fibres, collagen formation, mesenchim cell and fibroblast would develop to be cell-rich layer. Cell would proliferate and differentiate to be preodontoblast and columnar shape odontoblast.^{3,12} TGF- β 1 would directly stimulate matrix production including to enhance collagen synthesis, fibronectin and other matrix molecule. TGF- β 1 indirectly regulates fibroblast proliferation.¹ In the previous study¹³ it was reported that angiogenesis occurred before day 7 of TGF- β 1 application meaning the increase of

vascularization was faster consequently synthesis type I collagen occurring faster than Ca(OH)₂ group. As it has been understood that lowering the number of capillar will be running simultaneously with continuing healing process, decreasing the ratio between vascularized and fibroblast tissue, followed by the elevation of collagen production.¹⁴

Further process initiated by the formation of reparative dentinogenesis consisting of odontoblast like cell layer is formed in connection to superficial calcification and tubule matrix which has been mineralized secreted in predentin like pattern. Many studies have proved that early formation of fibrodentin with osteotypic appearance in trauma affected region¹⁵ frequently happens in the mechanism of wound healing. It is concluded that TGF- β 1 administration will increase synthesis type I collagen.

REFERENCES

- Chettibi S, Ferguson MWJ. Wound repair: An overview. In: Gallin JI, Snyderman R, eds. *Inflammation basic principles and clinical correlates*. 3rd ed. Philadelphia: Lippincott Williams & Wilkins; 1999. p. 865–77.
- McMahon RFT, Sloan P. Inflammation. In: *Essentials of pathology for dentistry*. 1st ed. Edinburgh: Churchill Livingstone; 2000. p. 26–31.
- Nanci A. Repair and regeneration of oral tissue. In: Ten Cate's oral histology: Development, structure and function. 6th ed. St Louis: Mosby; 2003. p. 397–415.
- Trownbridge HO, Kim S, Suda H. Structure, and function of the dentin and pulp complex. In: Cohen S, Burns RC, eds. *Pathways of the pulp*. 8th ed. St Louis: Mosby Inc; 2002. p. 411–447.
- Sloan AJ, Smith AJ. Stimulation of the dentine-pulp complex of rat incisor teeth by transforming growth factor- β isoform 1–3 in vitro. *Archs Oral Biol* 1999; 44: 149–56.
- Wahl SM. Transforming growth factor- β (TGF- β) in the resolution and repair of inflammation. In: Gallin JI, Snyderman R, eds. *Inflammation basic principles and clinical correlates*. 3rd ed. Philadelphia: Lippincott Williams & Wilkins; 1999. p. 837–42.
- Smith AJ, Matthews JB, Hall RC. Transforming growth factor- β 1 (TGF- β 1) in dentin matrix: ligand activation and receptor expression. *Eur J Oral Sci* 1998; 106(suppl 1): 179–84.
- Yang L, Qiu CX, Ludlow A, Ferguson MWJ, Brunner G. Active transforming growth factor- β in wound repair. *Am J Pathol* 1999; 154: 105–11.
- Krakauer T, Vilcek J, Oppenheim JJ. Proinflammatory cytokines TNF and IL-1 families, chemokines, TGF- β and others. In: Paul WE, editor. *Fundamental immunology*. 4th ed. Philadelphia: Lippincott-Raven; 1999. p. 800–3.
- Efron DT, Witte MB, Barbul A. Wound healing: Physiology, clinical progress, growth factor and the secret of the fetus. In: Baue AE, Faist E, Fry DE, eds. *Multiple organ failure pathophysiology, prevention and therapy*. Springer; 2000. p. 553–7.
- Kitasako Y, Shibata S, Pereira PN, Tagami J. Short-term dentin bridging of mechanically-exposed pulps capped with adhesive resin systems. *Oper Dent* 2000; 25: 155–62.
- Stanley HR. Pulp capping: Conserving the dental pulp-can it be done? Is it worth it? *Oral Surg Oral Med Oral Pathol* 1989; 68: 628–39.
- Kunarti S. Pulp tissue inflammation and angiogenesis after direct pulp capping with transforming growth factor β 1. *Dental Journal (Majalah Kedokteran Gigi)* 2008; 41(2): 92–5.
- McMahon RFT, Sloan P. Inflammation. In: *Essentials of pathology for dentistry*. 1st ed. Edinburgh: Churchill Livingstone; 2000. p. 26–31.
- Tziafas D. The future role of a molecular approach to pulp-dentinal regeneration. *Caries Res* 2004; 38: 314–20.