

## Case Report

## Treatment of recurrent aphthous stomatitis major with metronidazole and ciprofloxacin

M. Jusri<sup>1</sup> and Nurdiana<sup>2</sup>

<sup>1</sup>Department of Oral Medicine

<sup>2</sup>Resident of Oral Medicine

Faculty of Dentistry, Airlangga University  
Surabaya - Indonesia

### ABSTRACT

**Background:** Recurrent aphthous stomatitis (RAS) are painful oral ulcerations that recur from days to months or even years. It represents the most common lesion of the oral mucosa with prevalence ranging from 15% to 30%. Although the clinical characteristics of RAS are well defined, the precise etiopathogenesis of RAS remains unclear. Since the etiology of RAS remains unknown, there is no definitive treatment. RAS responds quite well to the use of topical or systemic antiinflammatory drugs, particularly corticosteroids.

**Purpose:** The objective of this paper is to discuss the treatment of RAS with secondary infection. **Case:** This paper reported a case of 22-year-old man with multiple oral ulcers that did not heal for 7 months. **Case Management:** These ulcers were diagnosed as RAS major with secondary infection that caused by normal oral flora (aerobic and anaerobic bacteria) and treated with metronidazole (topical and oral) and ciprofloxacin (oral). These lesions healed in 3 weeks with scars. **Conclusion:** Large ulcer without signs of malignancy that contaminated with normal oral flora will delayed in healing, but with rational treatment RAS mayor with secondary infection has good prognosis.

**Key words:** recurrent aphthous stomatitis, major ulcer, metronidazole, ciprofloxacin

**Correspondence:** M. Jusri, c/o: Departemen Oral Medicine, Fakultas Kedokteran Gigi Universitas Airlangga. Jl. Mayjend. Prof. Dr. Moestopo 47 Surabaya 60132, Indonesia. E-mail: m\_jusri@yahoo.com

### INTRODUCTION

Of all the non-traumatic ulcerations that affect oral mucosa, recurrent aphthous stomatitis (RAS) are the most common lesions found and observed by physicians and dentists.<sup>1,2</sup> The term "recurrent aphthous stomatitis" should be reserved for recurrent ulcers confined to the mouth and seen in the absence of systemic disease.<sup>3</sup>

The disease is characterized by recurring painful ulcers of the mouth that are round or ovoid and have inflammatory halos.<sup>3</sup> The condition ranges in severity from RAS minor, characterized by occasional and self-limited ulcerations, to a very debilitating form, called RAS major. RAS minor heal in about one week without scarring. RAS major can last from weeks to months and, rarely, extend out to years.<sup>4</sup>

RAS are typically classified as minor, major, and herpetiform types. RAS major (also referred as periaadenitis mucosa necrotica recurrens or Sutton's

disease) is the most severe expression of aphthous stomatitis.<sup>1</sup> RAS major develop deep lesions that are larger than 1 cm in diameter and may reach 5 cm.<sup>5</sup> In this type, 1–10 major apthae may be present simultaneously. Ulcers are large and deep, they may coalesce, and they often have a raised and irregular border. On healing, which may take as long as 6 weeks, the ulcers leave extensive scarring.<sup>2</sup> Occasionally, patients may experience an unremitting course with significant morbidity; systemic health may be compromised secondary to difficulty in eating and psychological stress.<sup>1</sup>

Cross-sectional studies suggest that recurrent aphthous stomatitis is more common in women, in people under the age of 40 years, whites, nonsmokers, and in people of high socioeconomic status.<sup>3</sup> RAS is the most common oral mucosal disease in North America. RAS affect 2–66% of the international population.<sup>2</sup> Although the lesions may appear at any age, they usually present during the second

and third decades of life.<sup>6</sup> Development of RAS minor usually begins in childhood or adolescence. The onset of RAS major is after puberty, and recurrent episodes may continue to develop for up to 20 years or more.<sup>7</sup> RAS herpetiform first occurs in the second decade of life, 67–85% of persons have onset under 30 years.<sup>2</sup> More than 42 percent of patients with RAS have first-degree relatives with RAS. The likelihood of RAS is 90 percent when both parents are affected, but only 20 percent when neither parent has RAS.<sup>8</sup>

Treatment of RAS should relate to the severity of the disease. Pain relief of minor ulcers can be obtained with use of a topical anesthetic agent or topical NSAID. In more severe cases, the use of high-potency topical steroid preparation, such as fluocinonide, betamethasone or clobetasol, placed directly to the lesion after meals and at bedtime. This agent shortens healing time and reduces the size of the ulcers. Other topical preparation include amlexanox paste and topical tetracycline, which can be used either as a mouth rinse or applied on gauze sponges.<sup>5</sup> Systemic corticosteroids, such as prednisone (20–30 mg/day) and betamethasone (2–3 mg/day) for 4–8 days are very helpful for major or herpetiform ulcers.<sup>6</sup>

This case reports a patient suffering RAS major that did not heal for approximately 7 months. Clinically, the lesion showed multiple ulcerations which consist of RAS major and RAS minor. Even though patient has seen several dentists, and use different kind of drugs, such as mefenamic acid, clindamycin, chlorhexidine mouthwash, another mouthwash, and vitamin, but the lesion did not heal. The authors assumed that there was a secondary infection from normal oral flora that caused RAS difficult to heal.

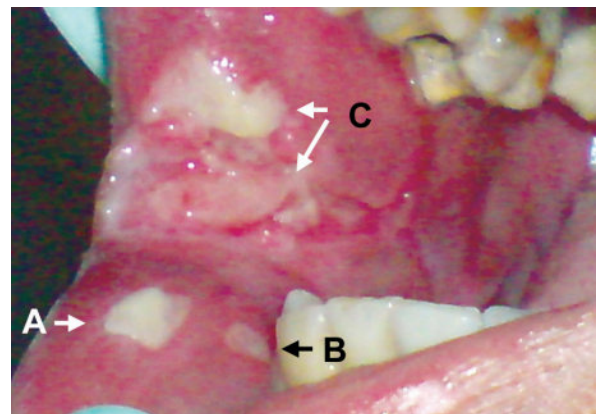
This case report discusses management of RAS major with secondary infection that is treated with antibiotic.

## CASE

A 22-year-old man was referred to Oral Medicine Department Faculty of Dentistry Airlangga University Surabaya by a dentist from Madiun with ulcers in right buccal mucosa that did not heal for a long time. From anamnesis known that about 7 months ago the patient had an ulcer in his right backside buccal mucosa. After consuming 'Adem Sari' the ulcer healed. One week later, an ulcer appeared in the same area but at different place. The patient then took 'Adem Sari' again but the ulcer did not heal. In a few days several ulcers appeared in this areas and very painful. The lesion was treated by several dentists and given several drugs. Afterward, the lesion became smaller and the pain decreased but then the lesion enlarged again and painful. The patient then visited a dentist in Haji Hospital and treated with mefenamic acid, clindamycin, and chlorhexidine mouthwash, afterward the pain decreased but the lesion remains the same. Before this ulcers appeared the patient often experienced an ulcer approximately once in a month, but the patient did not remember when it was.

Clinical examination revealed that general condition of the patient was good. The patient had smoking habit since approximately 5 years ago. There's no known disorder in patient's medical history and family history.

Extra oral examination showed mild swelling on right cheek, fissure and desquamation at corner of the lips, and chronic lymphadenitis on the right submandibular gland. Intra oral examination showed two ulcers on right lower labial mucosa, irregular shaped ulcer with diameter approximately 8 mm, raised border, surrounded by erythematous base, covered by white pseudomembrane, and painful (Figure 1-A) and round shaped ulcer with diameter approximately 6 mm, raised border, surrounded by erythematous halo, covered by white pseudomembrane, and painful (Figure 1-B). Irregular shaped ulcer, was found on right buccal mucosa size approximately 4 × 10 mm, raised center, surrounded by erythematous base, covered by white pseudomembrane, and painful. Erosions, fissures and scars (Figure 1-C) were also found in this area. On lower buccal fold mucosa appeared ulcer with round irregular shape with diameter approximately 10 mm, clear and raised border, surrounded by erythematous halo, covered by white pseudomembrane, and painful (not seen at Figure 1). Beside these ulcers, intra oral examination also revealed radix of lower right first molar, dental plaque and calculus on upper and lower right teeth.

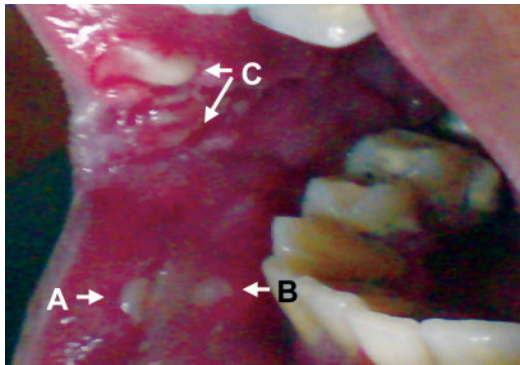


**Figure 1.** Visit 1: multiple ulcers and scars on lower labial mucosa and right buccal mucosa.

## CASE MANAGEMENT

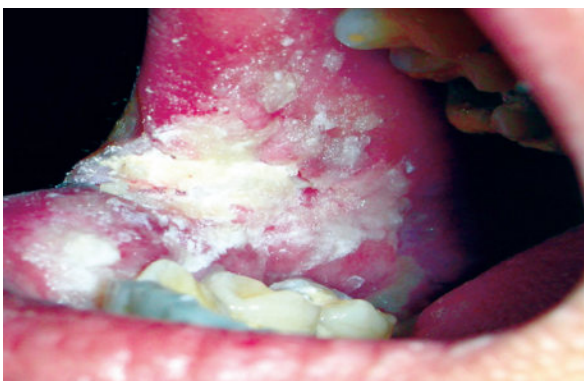
On first visit, according to anamnesis and clinical examination, the clinical diagnosis of this case was RAS major with squamous cells carcinoma and noma as the differential diagnosis. Scrapping for cytology examination and swab for bacteriology examination were done. The patient was instructed to take examination of complete blood, SGOT, SGPT, and blood glucose. Then the patient was given 5% extract sanguine + 0.1% polidocanol gel applied to the lesion 3 times daily, chlorhexidine mouthwash 3 times daily, and H<sub>2</sub>O<sub>2</sub> solution as mouthwash twice daily.

On second visit (two days later), the patient came for the first control. According to anamnesis it was known the pain has decreased. The result from cytology examination showed eosinophilic amorphous material, squamous cells spread, and cells with round nucleus degeneration. Bacteriological examination result found gram (+) cocci, gram (-) rods, and *Candida*. The result of complete blood examination showed an erythrocyte sedimentation rate (ESR) value elevation is (33). Intra oral examination revealed smaller ulcers on lower labial mucosa with diameter approximately 6 mm (Figure 2-A) and 5 mm (Figure 2-B). Ulcer on buccal mucosa had become smaller, approximately 4 × 8 mm, while erosions, fissures, and scars (Figure 2-C), and ulcer on lower labial fold mucosa did not change.



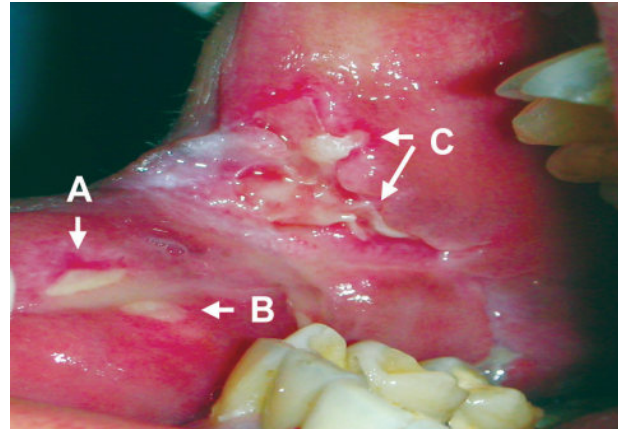
**Figure 2.** Second visit showed, smaller ulcers but erosions, fissures, and scars did not change.

The patient treated with 500 mg metronidazole 3 times daily, and 500 mg ciprofloxacin twice daily. Two tablets of 500 mg metronidazole made into powder and divided into 20 doses, then the powder placed on the ulcers and covered with 5% extract sanguine + 0.1% povidone iodine gel applied 3 times daily (Figure 3). Chlorhexidine mouthwash was continued.



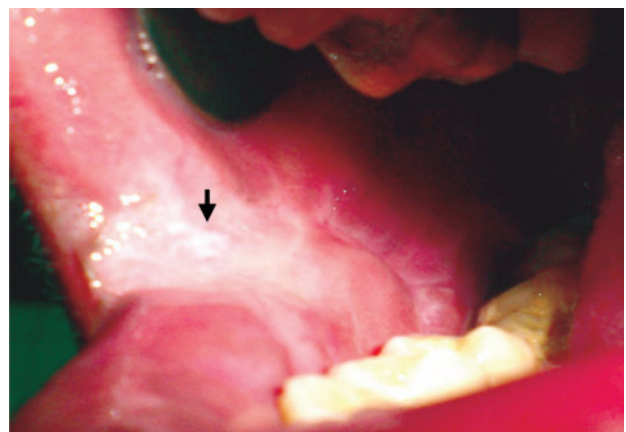
**Figure 3.** Second visit (3<sup>rd</sup> day) showed ulcers after being given metronidazole powder and covered with 5% extract sanguine + 0.1% povidone iodine gel.

On third visit, according to anamnesis there was no pain. Intra oral examination revealed ulcers on lower labial mucosa with diameter approximately 5 mm (Figure 4-A) and 4 mm (Figure 4-B) with erythematous halos. Ulcer on buccal mucosa had become smaller, 2 × 6 mm, while erosions, fissures, and scars were still remained but the erythema had decreased (Figure 4-C). Ulcer on lower labial fold mucosa became smaller with diameter approximately 8 mm. Patient was instructed to continue the therapy.



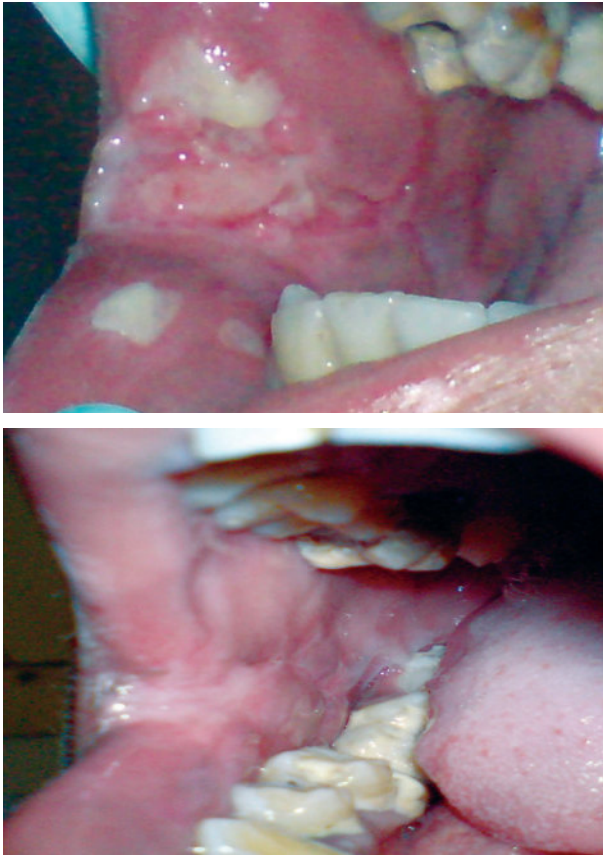
**Figure 4.** Third visit showed: (4<sup>th</sup> day) (A) Ulcer became smaller (5 mm), (B) Ulcer became smaller with erythematous halos (4 mm), (C) erosions, fissures, scars, and decreased erythema.

On fourth visit (the third control), eight days later, intra oral examination revealed that all ulcers, erosion and fissure were healed, except irregular shaped ulcer on buccal mucosa, diameter approximately 2 mm, flat border, covered by white pseudomembrane (Figure 5). The patient instructed to continue the therapy, added with multivitamin once daily and H<sub>2</sub>O<sub>2</sub> solution as mouthwash twice daily.



**Figure 5.** Fourth visit showed: (12<sup>th</sup> day) all ulcers had healed, except ulcer on corner of buccal mucosa (2 mm), flat border, covered by white pseudomembrane, and without erythematous halo (arrow).

On fifth visit (the fourth control): Intra oral examination revealed all ulcers, erosion, and fissure had healed with scars. The patient instructed to continue taking multivitamin once daily.



**Figure 6.** Comparison of the lesion on the first visit and the fifth (18<sup>th</sup> day). All lesions had healed with scars.

## DISCUSSION

Intra oral examination of this patient revealed several ulcers with variation of clinical features. Some ulcers had RAS characteristic. RAS major usually appeared after puberty, they are round or ovoid with clearly defined margins, and the ulcers usually are deeper and larger and last significantly longer than RAS minor. These ulcers have a raised irregular border and frequently exceed 1 centimeter in diameter and painful that last for weeks or months and often leave a scar after healing.<sup>8</sup> RAS usually confined to movable nonkeratinized or poorly keratinized oral mucosa, e.g., buccal mucosa, labial mucosa, tongue, floor of the mouth, soft palate, and uvula.<sup>6</sup>

Another lesion found in intra oral examination was ulcerations without erythematous halo, which is an indication of chronic lesion. Extra oral examination found no other lesion. On examination, it was known that ulcer had happened previously, about once a month.

According to the clinical features, multiple ulcers with RAS characteristic and ulcerations with sign of chronic

infection, as well as history of recurrency, the clinical diagnosis of the disease was RAS major with squamous cell carcinoma and noma as the differential diagnosis.

The cytological examination of this case showed no malignant cells, so the possibility of squamous cells carcinoma can be ruled out. Noma also considered as differential diagnosis in this case. Noma is rapidly progressive, opportunistic infection caused by components of the normal oral flora that become pathogenic during periods of compromised immune status. Noma often begins on the gingiva as necrotizing ulcerative gingivitis, which may extend to involve the adjacent soft tissue and form areas called necrotizing ulcerative mucositis. The necrosis can extend into deeper tissues, over the next few days zones of bluish-black discoloration of the overlying skin surface may develop. These discolored zones break down into areas of yellowish necrosis that also frequently spreads into adjacent bones, with large area of osteomyelitis possible.<sup>7</sup> Diagnosis of noma was inappropriate because clinically there's neither necrotic area nor bones destruction.

Histological findings, showed nonspecific ulcers with chronic mixed inflammatory cells. The pseudomembrane covering of ulcer was a combination of oral bacteria and fungi, as well as necrotic keratinocytes and sloughed oral mucosa.<sup>2</sup>

The result from cytology examination showed eosinophilic amorphous material, squamous cells spread, and cells with round nucleus degeneration, which lead to assumption of chronic infection. The result of complete blood examination showed an erythrocyte sedimentation rate (ESR) value elevation, with value of 33 from the normal of less than 15. This result supports the assumption of chronic infection. Bacteriology examination result found gram (+) cocci, gram (–) rods, and *Candida*. *Candida* found on this examination did not show *Candida* involvement but more there was lesion contamination by *Candida* which also available in normal oral flora.

According to clinical features, history, no involvement of other disease shown by normal complete blood examination, and chronic infection signs shown by cytology examination and elevation of ESR value, the final diagnosis for this case was RAS major with secondary infection from normal oral flora.

We assumed these lesions did not heal for 7 months because there's contamination of the lesion by normal oral flora. This theory supported by the result of bacteriology examination. The bacteria found in bacteriology examination were normal oral flora. Normal oral flora consists of aerobic and anaerobic bacteria. The aerobic bacteria found in oral cavity were primarily aerobic gram (+) cocci, and aerobic gram (–) rods. Two major groups of anaerobic bacteria in oral cavity are anaerobic gram (+) cocci and anaerobic gram (–) rods.<sup>9</sup>

Typical oral infection is caused by mixture of aerobic and anaerobic bacteria; approximately 70% of these infections are caused by this mixed flora. This fact has major clinical implications. The useful antibiotic for oral

infection must be effective against aerobes and anaerobes bacteria.<sup>9</sup>

Ciprofloxacin has 6-fluoro substituent which greatly improve antibacterial potency against gram (+) and gram (-) aerobes organisms.<sup>10</sup> These agents interfere with bacterial enzyme critical for DNA transcription.<sup>8</sup> Side effects of ciprofloxacin such as nausea, vomiting, rash, dizziness, and headache are rare.<sup>10</sup> The usual adult dose for ciprofloxacin is 500 to 750 mg orally every 12 hours. Metronidazole is effective only against anaerobic bacteria including those in the oral cavity.<sup>8</sup> These agents diffused into the bacteria where nitro component is reduced. During this reduction process, chemically reactive intermediate component is formed, which inhibit DNA synthesis and/or destroying DNA resulting in disruption of DNA function.<sup>10</sup> Metronidazole is available for oral, intravenous, intravaginal, and topical use.<sup>5</sup> Metronidazole is administered orally with usual dosage of 500 mg every 8 hours.<sup>8</sup> In this case oral and topical metronidazole were used. Because there is no topical metronidazole available we ground powdering metronidazole tablet. This powder then placed on the ulcers and covered with 5% extract sanguine + 0.1% polidocanol gel to get continuous direct contact.

Treatment of this case was done according to the treatment of RAS and secondary infection control. The patient was treated with systemic metronidazole and ciprofloxacin to treat the infection. Topical treatment that we used was metronidazole that made into powder and applied to the lesions to get the bactericidal effect through direct contact with the lesions to help improving infection healing. Five percent of extract sanguine + 0.1% polidocanol gel were applied as covering agent to reduced pain and improving epithelialization. The author has already used this method to treat several similar cases. Treatment with metronidazole powder that applied to the lesions also had been used in the wound treatment of a patient in Ear Nose Throat Department RSUPN-CM.<sup>11</sup> Chlorhexidine mouthwash was used to help eliminating and healing the infection.

It was concluded that RAS major in this case was contaminated by normal oral flora that causing secondary infection of the lesions. So, the treatment of this case was directed to treat the secondary infection. After proper therapy, the lesions healed in 3 weeks. To avoid recurrent of the disease, the patient was suggested to improve the oral condition. The patient was instructed to extract lower right first molar, scaling to remove plaque and calculus, and maintenance his oral hygiene.

## REFERENCES

1. Sciubba JJ. Oral mucosal disease in the office setting—Part I: aphthous stomatitis and herpes simplex infections. Available from: <http://www.agd.org/publications/articles/?ArtID=1858>. Accessed January 4, 2008.
2. Casiglia JM, Mirowski GW. Aphthous stomatitis. Available from: <http://www.emedicine.com/derm/topic486>. Accessed January 8, 2008.
3. Scully C. Aphthous ulceration Available from: [http://members.tripod.com/enotes/aphthous\\_ulcer](http://members.tripod.com/enotes/aphthous_ulcer). Accessed August 8, 2007.
4. Melamed F. Aphthous stomatitis. Available from: <http://www.med.ucla.edu>. Accessed January 4, 2008.
5. Laskaris G. Treatment of oral disease. A concise textbook. 1<sup>st</sup> ed. Stuttgart: Thieme; 2005. p. 15–7.
6. Scully C, Gorsky M, Lozada-Nur F. The diagnosis and management of recurrent aphthous stomatitis. Available from: <http://jada.ada.org/cgi/content/full/134/2/200>. Accessed January 4, 2008.
7. Neville BW, Damm DD, Allen CM, Bouquot JE. Oral and maxillofacial pathology. 2<sup>nd</sup> ed. Philadelphia: Saunders Co; 2002. p. 178–9.
8. Peterson LJ. Principles of surgical and antimicrobial infection management. In: Topazian RG, Goldberg MH, Hupp JR. Oral and maxillofacial infections. 4<sup>th</sup> ed. Philadelphia: WB Saunders Company; 2002. p. 101–3, 121.
9. Greenberg MS. Ulcerative, vesicular, and bullous lesions of the oral mucosa. In: Greenberg MS, Glick M, editors. Burket's oral medicine diagnosis & treatment. 10<sup>th</sup> ed. Hamilton: BC Decker; 2003. p. 63–5.
10. Neal MJ. 2005. At a glance pharmacology medis. Surapsari J, Safitri A, editors. Jakarta: Penerbit Erlangga; 2006, p. 80–1.
11. Irna S. Identifikasi dan pengendalian faktor resiko mukositis oral selama radioterapi kanker nasofaring. Available from: [http://resources.unpad.ac.id/unpad-content/uploads/publikasi\\_dosen/Identifikasi\\_dan\\_pengendalian\\_faktor\\_resiko\\_mukositis\\_oral.pdf](http://resources.unpad.ac.id/unpad-content/uploads/publikasi_dosen/Identifikasi_dan_pengendalian_faktor_resiko_mukositis_oral.pdf). Accessed June 12, 2009.