

Research Report

The combination of miacalcic, calcium lactate, and vitamin C as post-extracted alveolar bone resorption inhibitor

Sri Kentjaningsih

Department of Biology, Surabaya State University
Surabaya - Indonesia

ABSTRACT

Background: Tooth extraction can cause alveolar resorption, and will reduce the denture retention. The process of bone resorption looks like the process of osteoporosis. Calcium and vitamin D supplementation is the rational therapy for minimizing bone loss. Miacalcic is the drug of choice for osteoporotic patient. **Purpose:** This study is aimed to know whether the combination of miacalcic, calcium lactate, and vitamin C are effective in inhibiting post extracted alveolar resorption. **Methods:** Thirty three healthy postmenopausal women were chosen as samples and they were classified randomly into control group (without treatment), 1st experiment group (treatment was started 3 months post extraction), and 2nd experiment group (treatment was started at the 2nd day post extraction). The treatment was done by giving miacalcic nasal spray, calcium lactate 500 mg and vitamin C 100 mg tablets every morning in 10 days every month for 3 months. X-ray photo of the post extracted area were taken an hour, 3 months, and 6 months post-extraction. **Results:** After 6 month, there was significant difference in buccolingual thickness decreasing among three groups ($p < 0.05$). The maximum mean difference of buccolingual thickness decreasing was 0.72 mm, between control and 2nd experiment groups. There was no significant difference about decreasing bone density among them ($p > 0.10$). The maximum difference of the mean of density decreasing was 1,906 g/cm²/mm between control and 2nd experiment groups. The increasing density mostly occurred in the 2nd experiment group. **Conclusion:** The combination of miacalcic, calcium lactate, and vitamin C are effective for inhibiting alveolar resorption, although statistically there was no significant difference about bone density decreasing. The sooner this treatment is given the better result will be achieved.

Key words: Miacalcic, calcium lactate, vitamin C, alveolar resorption

ABSTRAK

Latar belakang: Pencabutan gigi menyebabkan resorpsi tulang alveolaris, dan akan mengurangi retensi geligi tiruan. Proses resorpsi tulang alveol pada osteoporosis mirip dengan proses resorpsi tulang pada penyembuhan luka bekas pencabutan. Miacalcic adalah obat utama untuk penderita osteoporosis. Kalsium dan vitamin D merupakan terapi yang rasional untuk meminimalkan resorpsi tulang. **Tujuan:** Membuktikan apakah kombinasi miacalcic, kalsium laktat, and vitamin C juga efektif menghambat resorpsi tulang alveol pasca pencabutan. **Metode:** Sampel 33 wanita postmenopause yang sehat, terbagi secara acak ke dalam kelompok kontrol (tanpa perlakuan), kelompok eksperimen 1 (perlakuan mulai 3 bulan pasca pencabutan) dan kelompok eksperimen 2 (perlakuan mulai hari kedua pasca pencabutan). Perlakuannya yaitu: pemberian miacalcic semprot hidung, tablet kalsium laktat 500 mg dan vitamin C 100 mg setiap pagi, 10 hari dalam sebulan, selama tiga bulan. Foto sinar-X dari regio pasca pencabutan dibuat satu jam, 3 bulan, dan 6 bulan pasca pencabutan. **Hasil:** 6 bulan pasca-cabut, ada beda bermakna perihel selisih tebal buccolingual tulang alveol antar ketiga kelompok ($p < 0,05$). Rerata penurunan ketebalan ini maksimal sebanyak 0.72 mm, antara kelompok kontrol dan kelompok eksperimen 2. Penurunan kepadatan tulang antar ketiga kelompok tidak bermakna ($p > 0,10$). Beda maksimum rerata kepadatan tulang antara kelompok kontrol dan kelompok eksperimen 2 sebesar 1,906 g/cm²/mm. Peningkatan kepadatan terbanyak dialami anggota kelompok eksperimen 2. **Kesimpulan:** Kombinasi miacalcic, kalsium laktat, vitamin C efektif menghambat resorpsi tulang alveolaris, walaupun secara statistik beda penurunan kepadatan tidak bermakna. Makin awal pemberian perlakuan, hasilnya akan lebih baik.

Kata kunci: Miacalcic, kalsium laktat, vitamin C, resorpsi tulang alveolaris

Correspondence: Sri Kentjaningsih, Jurusan Biologi Universitas Negeri Surabaya. E-mail: sri_kentjaningsih@yahoo.co.id

INTRODUCTION

Tooth extraction is often chosen by patients because of strong pain or the unwillingness to visit their dentist several times, although dental conservative science and technology are continually developing. The consequence of tooth extraction is alveolar resorption. It occurs fast in the first three months in mesiodistal, apico-occlusal, bucco lingual directions and it influences its density. After that it occurs slowly but progressively during our life until the alveolar process is lost. This condition is related to minimum physiological pressure during wound healing.¹

There are some other factors influence the resorption rate, such as general health, local condition, the quality of food intake, medicine usage, and some hormones concentration such as parathyroid hormone (PTH), blood calcium concentration, sex hormone, and calcitonin.² If most of the factors can be controlled, the influence of each factor can be proved. Due to this reason, healthy postmenopausal women, who have the lowest concentration of sex hormone and calcitonin were chosen as samples. In this condition, the osteoclasts' activity are 20–40 times more efficient than osteoblasts, so the density of the bone is fastly reduced.² The food's quality in unstarvation person is considered normal, because in adult, the more protein intake, the faster bone resorption will occur.² Hypocalcemia will stimulate PTH secretion and further high PTH concentration will stimulate calcium deposition from our bone. Calcium and vitamin D supplementation is rational therapy for minimizing bone loss.³ During post extraction wound healing, vitamin C as the cofactor for prolylhydroxylation is needed in hidroxyprolin forming to get better bone quality.¹

Miacalcic is a salmon calcitonin, a calcitropic hormone, which inhibits bone resorption by a direct inhibiting action on osteoclast activity via its receptors. It is the physiological treatment of choice for osteoporotic patients, because it inhibits the bone resorption process and its minimum side effect as compared to estrogen.^{4,5} Its nasal spray makes it easily used. It still works several days after being exposed in several minutes. It increases calcium excretion, which needed in osteoclasts' activities, so that the bone resorption is reduced,⁶ even it can increase the bone's mass and density^{6–8} and enhance the healing process.^{7,9} In two weeks administration, it had effectively inhibited the reducing bone mass,⁹ but with 15 IU/kg dose, calcitonin can not prevent the reducing calcium incorporation that happened in immobilized bone.¹⁰ Administration more than one year caused the lost of calcitonin receptors.⁶ It could reduce pain disturbance.¹¹ Conversely, Duarte *et al.*,¹² found that it could not prevent bone loss caused by estrogen deficient. Thamsboro *et al.*,¹³ got significant bone mass density (BMD) increasing, but no significant BMD difference. Gurkan *et al.*,¹⁴ found that giving miacalcic without calcium would increase the bone resorption process.

This research will prove whether miacalcic, calcium-lactate and vitamin C treatment was effective in inhibiting post extracted alveolar resorption. It will help to overcome the decreasing denture retention.

MATERIALS AND METHODS

The samples were found in Puskesmas Tambakrejo with the inclusion criteria: normal in finger articulation; posture; body mass index; range of completely hematology and urine laboratory test; glucose, thyroid stimulating hormone (TSH), T₄ and alkaline phosphatase concentration, and normal backbone photos. They have their mandibular's second premolar, first molar, or second molar been extracted. They would not wear the denture. The exclusion criteria were: irregular period during one year; malignant process; hypertension, asthma, prolong using glucocorticosteroid, prostaglandin, and analgesic, tetracycline and chloramphenicol; unwillingness to be observed for at least 6–12 months. For this, each of them should sign an inform consent.

This research was a clinical trial using completely randomized design, with three groups. They were control group, without treatment; 1st experiment group, who received treatment 3 months post extracted; and 2nd experiment group, who received treatment at the following day post extracted. After being extracted she was taken her alveolar X-ray photos. At that day she should fast from 7 pm to get a series laboratory test at following day. At the same day her body weight and body height were measured; her backbone X-ray photo was taken. The impression result was held in a plastic sac, which can be tightly bound for inhibiting the impression shrinkage. In the afternoon it was filled with gypsum. If her laboratory result was good, she became the sample of one of the three groups randomly. Depended on which experiment group's member she was, at that day or three month later or never, she was given one calcium-lactate 500 mg (Kimia Farma) and one vitamin C 100 mg tablets (Kimia Farma) to be swallowed, then one spray of miacalcic (Sandoz) for each nostril, every morning, 10 days continually in a month for three months at her home. At the end of the 3rd month X-ray photo at her post extracted area and mandible impression were taken again and those was repeated three monthly until one year.

Alveolar X-ray photo, was taken when the patient sat vertically, lean on the back of the chair, with straight vision to front direction, the cone was arranged horizontally as high as the root part of the posterior teeth, and the duration had been already arranged. The patients were not using an apron protection while their X-ray photos were taken, because each of them was given X-ray exposure each of kind three months. Before processing the film, both of the poured processing solution were into two small bowls. The film was opened in dark room, shaken 23 seconds in the developer solution and 30 seconds in fresh water, then it was shaken 5 minutes in the fixation solution. Finally the film was washed in flowing fresh water for several minutes until it cleaned from the fixation solution. The film was dried in the air. The target regions were circled not less than 1 mm² wide by ink pen.

The darkness of the target area in the film was measured with calibrated densitometer type 07–424 (Figure 1). For this, turn on the switch for at least 10 minutes, then close

the arm and the digital should show 0, by arranging the small wheel at the right side. The target area in the film should be located on the window of densitometer and the stable number showed on the digital was recorded. This was repeated three times and then the mean was counted. The mean number was converted to the bone density, through the formula.¹⁵ The density difference of the target area could then be counted.

The buccal and lingual parts of the plaster model was signed as in figure 2. The buccolingual thickness of this model was measured by a caliper, as the distance of the buccal's and lingual's signs. This was repeated in 6 month's model. The alveolar resorption was counted as the width difference.

RESULTS

The data of the alveolar thickness difference and the alveolar density difference of the 33 sample were provided in table 1 and table 2.

Table 1. The alveolar thickness differences (mm) of the three groups after six months

atd.CG	atd.1 st EG	atd.2 nd EG
2.27	1.24	0.73
2.26	0.99	1.01
0.98	2.19	0.65
2.09	1.25	2.31
2.29	0.71	2.04
2.34	1.69	2.40
2.40	3.47	1.35
3.38	2.82	2.30
3.06	1.25	2.30
2.70	0.15	1.50
3.34	0.75	2.40
Mean: 2.446	1.501	1.726
Var. Coef.: 27.72%	65.29%	40.38%

atd.CG : Alveolar thickness difference of the control group
 atd.1st EG : Alveolar thickness difference of the 1st experiment group
 atd.2nd EG : Alveolar thickness difference of the 2nd experiment group

Table 2. The alveolar density difference (g/cm³/mm) of the three groups after 6 months

add.CG	add.1 st EG	add.2 nd EG
1.134	1.810	6.351
3.755	3.856	-2.167
1.991	0.328	3.325
3.730	5.141	-1.965
9.601	6.048	1.814
1.109	7.686	-1.159
7.661	3.024	2.344
0.806	1.033	5.544
8.871	2.591	4.058
2.999	-3.553	-1.984
-0.554	0.690	3.982
Mean: 3.737	2.605	1.831
Var. Coef.: 92.86%	118.77%	172.86%

add.CG : Alveolar density difference of the control group
 add.1st EG : Alveolar density difference of the 1st experiment group
 add.2nd EG : Alveolar density difference of the 2nd experiment group

The ANOVA of this result showed a significant decreasing thickness difference among those groups (p<0.05), while the difference between both experiment groups was non significant (p=0.519). It means that the significant difference is only happens between control group and both experiment groups. The samples of the control group got 0.72 mm reduction more than the two others. This means that the treatment can inhibit the alveolar resorption.

The ANOVA of this result showed that there wasn't significant bone density difference among those groups (p>0.05), although the mean value of both experiment group was lesser than the control group. The bone density of some patients in those three groups increase, four members of the 2nd experiment group and one member in each of two other groups.

DISCUSSION

The exclusion factors have been fulfilled here. One thing that contrary to public idea is, the more protein




Figure 1. Target areas in one member's of 1st experiment group (1st EG) X-ray photos. 1st EG.0 was taken soon after tooth extraction; 1st EG.3 was taken 3 months after tooth extraction, and 1st EG.6 was taken 6 months after tooth extraction. The cervical points of the neighboring teeth were related and the center of the circle line was put 3 mm below the line. The circle line above the edentulous was used as the guidance in measuring the blackened degree; while the circle between two other teeth was made to know whether this treatment had influenced another area of alveolar bone.

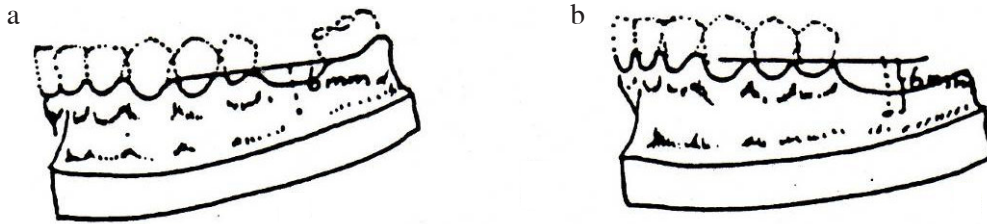


Figure 2. The way to sign the points to be measured in Plaster model of mandibular. a) Mandibular model of a patient who has been extracted her 1st molar, b) Mandibular model of a patient has been extracted her 1st molar which was the most distal tooth.

intake, especially animal protein in adult will cause loss of calcium from the bone, because it will increase blood uric acid and urea concentration.^{2,16,17} They store in the body as toxins and fats.¹⁸ For excreting them in urine the water will much loss and our bones tend to release calcium.¹⁹ Excess protein may be associated with negative calcium balance.¹⁷ Our body needs only about 35–50 grams protein per day, either from animal, plant, or their combination.¹⁷ As far as someone is not at starvation condition, he was in normal food quality, because our body needs balance nutrition, consists of carbohydrate, protein, fat, minerals and vitamin.^{17,20}

Postmenopausal women were chosen, so that the calcitonin could be controlled at the lowest concentration. Through this treatment, their calcitonin concentration would enable the precipitation of calcium and phosphate on the bone,² but this was unproved by Tuukkanen *et al.*¹⁰ Although bone wound healing usually has completed in 3 months,² even in young rats, it needed only 4 weeks,¹⁴ but it's calcification can progressively occur until 6 months.¹ It was the reason that the 1st experimental group was treated 3 months after extracted.

There are two reasons of choosing micalcalc in this research. The first reason is, there are only two medications which currently approved by Federation Dental Association (FDA) for osteoporosis treatment, they are estrogen and salmon calcitonin.⁵ Estrogen tends to raise breast cancer,⁵ in contrary calcitonin has slight side effect.⁶ The second reason is, calcitonin is a first-line choice in several bone diseases treatment.⁴ Placebo was unneeded in this research, because each sample was treated individually at her home.

Calcium-lactate was given because calcitonin without calcium will increase the bone resorption process.¹⁴ This condition is related to the decreasing blood calcium concentration soon after calcitonin administration, while calcium is needed for spouting chemical and electric signal from cellular membrane into the cell.⁶

Vitamin C is a cofactor of prolylhydroxylation, it helps the hydroxyprolin forming.² For getting better new bone quality, it is important to give it during wound healing process. If this vitamin is given after the wound healed, it will not give much effect to the new bone quality.¹

Alveolar resorption can happen in mesiodistal, buccolingual, and occlusoapical directions, besides the reduction of bone density.¹ In this research the data were

only the buccolingual thickness and the bone density reduction differences, because the occlusoapical resorption made irregular occlusal surface of the alveolar bone, so it could not be measured; while mesiodistal distance wasn't completely gotten, because some of the extracted teeth were the most distal teeth.

There was only a slight thickness-decreasing difference (mean difference was 0.72 mm). This was supporting the research findings of Canavero *et al.*,⁷ that there was no larger amount of new bone at the end of 21 days observation and there was no significant clinical size.⁶ This slight difference was worthy enough for denture retention, especially if it occurs at the whole maxilla or mandible.

There was not significant alveolar density difference, although the maximum difference of the mean density-decreasing difference was 1.906 g/cm²/mm. Actually this slight increase is also worthy, because it will better maintain the physiological resorption. From these data, some members of the experimental group got slight increased their alveolar density. It supports the previous study, that although there is significant increase in cortical bone mass density with calcitonin treatment, but calcium and vitamin D administration is more effective in preventing bone loss.¹¹ Furthermore, calcitonin could not prevent the effect of estrogen deficiency,¹² and nasal salmon calcitonin 200 IU daily produces only a minor increase in bone mass.¹³ Alveolar density was increased more on the samples who begin the treatment at the following day after extracted, which the wound healing starts. This was easily understood, because micalcalc enhanced the wound healing in early stage,¹⁰ although Gurkan *et al.*,¹⁴ found no significant effect on it. It may be caused by the inability to hinder the food intake activity of the rat that may cause slight infection, so the healing was postponed. Micalcalc will help much more calcium precipitating in the bone matrix.¹⁰ Salmon calcitonin had no significant effect on mineralization of the alveolar bone.¹⁴ Furthermore, two weeks immobilization will cause bone mass reduction, so that the postponed micalcalc treatment will cause their bone density lower than the ones who directly got the treatment.¹⁰

About the increasing bone density in one member of the control group, the most possible reason is they have got enough calcium from their food, so that the higher calcium blood concentration will prevent the bone calcium

release.¹² It might also be caused by the difference of gut epithelial capability in calcium and phosphorus absorption, the difference of personal vitamin D concentration, or the difference of their body mass index.

Because there were many exclusion criterias to be fulfilled, the samples were not so easy to get. It needed almost four years to get 33 samples to fulfill the sample size. During this time there are many patients failed to be the samples, although they had signed the inform consent; because each member had her own activity and business. This research needs special social skill in holding the good relationship to the samples, and to get their data in the exact schedule. A good schedule should be arranged for the researcher's daily activity. This means that besides the main result, the researcher got another advantage.

The conclusion of this research was the combination of miacalcic calcium lactate, and vitamin C are effective for inhibiting alveolar resorption, although statistically there was no significant difference about bone density decreasing. The sooner this treatment is given the better result will be achieved.

REFERENCES

- Peterson LJ, Indresano AT, Marciani RD, Roser SM. Principles of oral and maxillofacial surgery. Vol. 2. Philadelphia: JB Lippincott Co; 1992. p. 1173.
- Guyton AC. Textbook of medical physiology. 7th ed. Philadelphia, London, Toronto, Mexico City-Rio de Janeiro, Sydney, Tokyo, Hongkong: WB Saunders Company, 1996. p. 732, 782-6, 861, 868-83, 891-2, 905, 910.
- Buckley LM, Leib ES, Kathryn S, Cartularo RN, Vacek PM, Cooper SM. Calcium and vitamin D₃ supplementation prevents bone loss in the spine secondary to low-dose corticosteroids in patients with rheumatoid arthritis. Article. Available at: <http://www.annals.org/content/125/12/961.full>. Accessed December 31, 2010.
- Reginster JY. Calcitonins: newer routes of delivery. Osteoporosis Int 1993; 3(Suppl 2): 53-6. discussion S6-7.
- Cosman F, Nieves J, Walliser J, Lindsay R. Postmenopausal osteoporosis: Patient choices and outcomes. Maturitas 1995; 22(2): 137-43.
- Vered M, Shohat I, Buchner A, Dayan D, Taicher S. Calcitonin nasal spray for treatment of central giant cell granuloma: Clinical, radiological, and histological findings, and immunohistochemical expression of calcitonin and glucocorticoid receptors. Netter Oral Surgery, Oral Medicine, Oral Pathology, Oral Radiology, and Endodontology 2007; 104(2): 226-39.
- Canavero E, Januario AL, Sallum EA, Novaes PD, Nociti FH Jr. Histometric evaluation of local action of salmon calcitonin on bone repair: A study in rats. Pesqui Odontol Bras 2000; 14(2): 183-7.
- Kaskani E, Lyritis GP, Kosmidis C, Galanos A, Andypas G, Chorianopoulos K, Giagiosis A, Iliadou K, Karagianis A, Katsimichas K, Koskinas A, Matsouka K. Effect of intermittent administration of 200 IU intranasal salmon calcitonin and low doses of 1alpha(OH) vitamin D3 on bone mineral density of the lumbar spine and hip region and biochemical bone markers in women with postmenopausal osteoporosis: A pilot study. Clin Rheumatol 2005; 24(3): 232-8.
- Dogan H, Ozcelik B, Gediko G, Senel S. The effect of calcitonin on osseous healing in guinea pig mandible. J Endod 2001; 27(3): 160-3.
- Tuukkanen J, Jalovaara P, Vaananen K. Calcitonin treatment of immobilization osteoporosis in rats. Acta Physiologica Scandinavica 1991; 141(91): 119-24.
- Kopaliani M. Effectiveness of intranasal salmon calcitonin treatment in post-menopausal osteoporosis. Georgian Med News 2005; 121: 38-42.
- Duarte PM, Goncalves P, Sallum AW, Sallum EA, Casati MZ, Nociti JrFH. Effect of an estrogen-deficient state and its therapy on bone loss. J Period 2004; 39(2): 107-10.
- Thamsboro G, Jensen JEB, Kollerup G, Hauque EM, Melsen F, Sarensen OH. Effect of nasal salmon calcitonin on bone remodelling and bone mass in postmenopausal osteoporosis. Bone 1996; 18(2): 207-12.
- Gurkan L, Ekeland A, Langeland N, Ronningen H, Solheim LF. Effect of salmon-calcitonin on growth of teeth and on extraction socket healing in young rat. Wiley online library Oct 1st 2007. Available at: <http://onlinelibrary.wiley.com/doi/10.1111/j.1600-0722.1983.tb00841.x/abs-tract>. Accessed Aug 16, 2010.
- Kentjananingsih S. Penghambatan penyusutan tulang alveol daerah bekas cabut oleh kalsitonin, ditambah kalsium dan vitamin C. Disertasi. Surabaya: Pascasarjana Universitas Airlangga; 1997.
- Preventing osteoporosis using natural methods. p 1-4. Available at: <http://www.healingdaily.com/conditions/osteoporosis.htm>. Accessed December 28, 2010.
- Stevemark. Health problems and side effects that has been Associated with too much high protein. p. 1-7. Available at: <http://hubpages.com/hub/Health-Concerns-Regarding-High-Proteins-Diets>. Accessed December 28, 2010.
- Hannan MT, Tucker KL, Dawson-Hughes B, Cupples LA, Felson DT, Kiel DP. Effect of dietary protein on bone loss in elderly men and women: the Framingham Osteoporosis Study. J Bone Miner Res 2000 Dec; 15(12): 2504-12.
- Hopkins S. Could high protein diets prove harmful for people with liver or Kidney disease. Article. p. 1-3. Available at: <http://www.diethealthclub.com/articles/42/diet-and-wellness/could-high-protein-diets-pro>. Accessed December 28, 2010.
- Heaney R. The protein and calcium paradox in osteoporosis. Am J Clin Nutr 2002; 75(4): 609-10.