



Consumption of Cassava Extract (*Manihot Esculenta*) Improves Pancreatic Histology and Seminiferous Tubules in Wistar Rats Induced Diabetes Mellitus with Streptozotocin

Mohamad Rizki Adi Prasetyo¹, Qoit Muhammad Abdul Ghalib¹, Dwi Nur Ahsani², Ika Fidianingsih^{2*}

¹ Faculty of Medicine, Universitas Islam Indonesia

² Department of Histology, Faculty of Medicine, Universitas Islam Indonesia

ARTICLE INFO

Article history:

Received 21 January 2023

Accepted 1 April 2023

Published 10 June 2023

Keyword:

Cassava Extract
Diabetes mellitus
Pancreas
Seminiferous Tubules

ABSTRACT

Diabetes Mellitus (DM) can damage various organs, which are the pancreas and the testes, which cause infertility. Therefore, alternative treatment is needed, including cassava (*Manihot Esculenta*) which contains polyphenol antioxidants that can reduce free radicals caused by hyperglycemia. The objectives of the study were to determine the effect of cassava consumption on the histological pancreas and testes of Wistar rats induced with streptozotocin. This study was an experimental study posttest only control group design. Experimental animals were divided into four treatment groups, namely healthy controls (K1), DM aqua dest (K2), DM metformin (K3), and DM cassava (K4). The treatment was given after successful DM induction. The histology of the pancreas was the area of the islets of Langerhans. The histology of the testes was the thickness of the seminiferous tubule epithelium. The analysis used a one-way ANOVA test. The average area of Langerhans Island, respectively, namely $6482,95 \pm 117,71 \mu\text{m}^2$, $2597,49 \pm 137,25 \mu\text{m}^2$, $2746,93 \pm 172,07 \mu\text{m}^2$, and $3307,00 \pm 368,51 \mu\text{m}^2$ (p-value = 0.000). The mean epithelial thickness of the seminiferous tubules was $19,62 \pm 1,12 \mu\text{m}$, $15,59 \pm 0,46 \mu\text{m}$, $17,05 \pm 1,42 \mu\text{m}$, and $18,09 \pm 0,52 \mu\text{m}$ (K4) (p-value = 0.000). In conclusion, the consumption of cassava extract (*Manihot esculenta*) can improve the histological picture of the pancreas and increase the thickness of the seminiferous tubule.

This open access article is under the [CC-BY-SA](https://creativecommons.org/licenses/by-sa/4.0/) license.



Kata kunci:

Singkong
Diabetes Melitus
Pankreas
Tubulus Seminiferus

*) *corresponding author*

Ika Fidianingsih

Universitas Islam Indonesia
Fakultas Kedokteran UII, Jl. Kaliurang Km
14,5 Yogyakarta

Email: 18711116@students.uui.ac.id

DOI: 10.30604/jika.v8i2.1929

Copyright 2023 @author(s)

ABSTRAK

Diabetes Mellitus (DM) dapat merusak berbagai organ yaitu pankreas dan testis yang menyebabkan kemandulan. Oleh karena itu, diperlukan pengobatan alternatif antara lain ubi kayu (*Manihot Esculenta*) yang mengandung antioksidan polifenol yang dapat meredakan radikal bebas akibat hiperglikemia. Tujuan penelitian adalah untuk mengetahui pengaruh konsumsi singkong terhadap gambaran histologi pankreas dan testis tikus Wistar yang diinduksi dengan streptozotocin. Penelitian ini merupakan penelitian eksperimental post-test only control group design. Hewan coba dibagi menjadi empat kelompok perlakuan yaitu kontrol sehat (K1), DM aqua dest (K2), DM metformin (K3), dan DM singkong (K4). Perlakuan diberikan setelah induksi DM berhasil. Histologi pankreas yang akan diamati adalah area pulau Langerhans. Histologi testis adalah ketebalan epitel tubulus seminiferus. Analisis menggunakan uji one way ANOVA. Rata-rata luas Pulau Langerhans berturut-turut yaitu $6482,95 \pm 117,71 \mu\text{m}^2$, $2597,49 \pm 137,25 \mu\text{m}^2$, $2746,93 \mu\text{m}^2 \pm 172,07$, dan $3307,00 \mu\text{m}^2 \pm 368,51$ (p-value = 0,000). Ketebalan epitel rata-rata tubulus seminiferus adalah

19.62±1.12µm, 15.59±0.46 µm, 17.05±1.42µm, and 18.09±0.52 µm (K4) (p-value = 0,000). Kesimpulannya, konsumsi ekstrak singkong (*Manihot esculenta*) dapat memperbaiki gambaran histologis pankreas dan meningkatkan ketebalan epitel tubulus seminiferus.

This open access article is under the [CC-BY-SA](https://creativecommons.org/licenses/by-sa/4.0/) license.



INTRODUCTION

Diabetes mellitus (DM) is still a significant problem worldwide. The prevalence of DM is very high. DM complications cause high mortality and morbidity (Chan, 2016). The highest number of diabetics is in China (114.4 million), while Indonesia (10.3 million) is in seventh place (Mekala & Bertoni, 2020). Based on Basic Health Research (Riskesmas), in 2018, 8.5% of Indonesia's population suffered from DM (Ma'ruf et al., 2020). DM prevalence increases every year. According to WHO, in 1980, the world's diabetics reached 108 million, and in 2014 it increased to 422 million. According to the International Diabetes Federation (IDF), in 2019, 463 million people suffered from DM.

Comprehensive DM management requires time and discipline for sufferers. DM management aims to eliminate complaints, improve quality of life and reduce the risk of complications. Management needs a long time to prevent microangiopathy and macroangiopathy complications (Soelistijo et al., 2019). Management of DM consists of education, medical nutrition, physical exercise and pharmacology. Medical nutritional therapy recommends food composition and calorie regulation (Setiati et al., 2014). Pharmacological administration must accompany dietary arrangements and physical exercise (Departemen Farmakologi dan Terapeutik FK UI, 2007).

Diet modification is a form of treatment that is easy and affordable for diabetes mellitus patients. Cassava (*Manihot Esculenta*) might be recommended for DM patients' diet. Cassava is a tuber plant that is often found in everyday life. Studies show cassava contains pyrrolic antioxidants and can clean radicals (Zekarias et al., 2019). The chemical content of cassava is also rich in antioxidants such as polyphenols (Hasim et al., 2016). These polyphenol antioxidants can inhibit reactive oxygen acts due to hyperglycemia in DM patients so that tissue destruction can be minimized (Abbas, Aster & Kumar, 2015; Hasim et al., 2016). In addition, cassava is a food source with a low glucose content but is high in fibre, so cassava has the potential to be a substitute for staple foods for people with DM (Onodu et al., 2018).

Parameters of the severity of diabetes mellitus can be seen from changes in the structure of the pancreas. The islets of Langerhans in the pancreas are where insulin is produced. A decrease in the hormone insulin production can increase glucose concentration in the blood (Da Silva Xavier, 2018). DM can cause systemic complications and morphological changes in arteries (macrovascular), basement membrane of small vessels (microangiopathy), diabetic nephropathy, retinopathy, neuropathy and infertility (Abbas, Aster & Kumar, 2015). The incidence of infertility in DM sufferers reaches 35.1% (Bener et al., 2009). This infertility occurs because hyperglycemia causes inflammation, increased oxidative stress, DNA fragmentation, mitochondrial damage, and decreased sperm motility (Glazer et al., 2017). In addition, a state of hyperglycemia causes a decrease in VEGF expression through regulation of the PI3K/Akt pathway, causing testicular microvascular damage and seminiferous

tubules (Long et al., 2018). Conversely, giving antioxidants to diabetic rats can improve testicular morphology (Jannah et al., 2018). Therefore, this study aims to determine the effect of cassava consumption on changes in the histological structure of the pancreas and testes of rats induced by diabetes mellitus.

METHODS

Research design

Experimental research used a posttest-only control group design. This research has obtained Etichal Clearance from the Faculty of Medicine, Islamic University of Indonesia, with no. Ref: 16/Ka.Kom.Et/7 O /KE/IX/ 2021. The research was conducted from November 2021 – February 2022. The research was conducted at the Research Laboratory of the Faculty of Medicine, Islamic University of Indonesia (FK UII).

Research subject

The research subjects were *Rattus novergicus* Wistar rats obtained from the Research Laboratory of the Faculty of Medicine, Islamic University of Indonesia. Inclusion criteria were male rats, 3-4 months old, 125-170 gram body weight, healthy, agile movements, no wounds on the skin, no fleas, and no discharge found from the body. Exclusion criteria were sick or dead rats that were not caused by research. Subjects were randomly divided into four groups, namely the healthy control group and given distilled water (K1), the group induced diabetes mellitus with streptozotocin and given distilled water (K2), the group induced with streptozotocin and given metformin (K3), and the group induced with streptozotocin and given cassava. 200 mg/kg BW (K4).

Sample size

The sample size for this experimental study refers to the Charan and Biswas formula (2013), namely, the total number of mice used minus the number of groups equals 10-20. The number of groups is four, so the total number of rats used is a maximum of 24 and a minimum of 16. This study used 20 rats, 5 in each group.

Production of cassava extract

Cassava (*Manihot esculenta*) is taken in the form of cassava flour. Cassava flour was macerated with 95% ethanol in a ratio of 1: 4 for 48 hours and stirred every 24 hours. Furthermore, the solution was concentrated with a rotary evaporator with a rotational speed of 90 rpm and a temperature of 50 °C to become cassava extract (Meilawaty, 2013)

Streptozotocin induction

After the adaptation process for seven days, blood sugar levels were measured in groups K1, K2, K3, and K4. Experimental animals in groups K2, K3, and K4 were induced by STZ at a dose of 60 mg/kg BW intraperitoneally on the day of measuring blood sugar levels to ascertain whether the experimental animals had DM.

Histological Preparation

On the 47th day, the experimental animals were anaesthetized using ketamine at 100 mg/kgBW intramuscularly before termination. Pancreatic and testicular tissues were fixed with 10% PBS formalin, and then tissue processing was performed using alcohol and xylene. The tissue was made of paraffin blocks and cut using a microtome with a thickness of 5 µm. Staining used Hematoxylin Eosin (HE).

Histology Reading

The histological appearance of the pancreas observed was the average area of five Langerhans islets, randomly selected throughout the preparation field and expressed in µm² units. The area of the islets of Langerhans was measured using the Image J application. The histological appearance of the testes observed was the epithelial thickness of the seminiferous tubules which were round or nearly round and had no epithelial rupture. Then the epithelium of the seminiferous tubules is measured by drawing the line at the

boundary between the layers of spermatogonia cells to the lumen surface of the seminiferous tubules. Measurements were carried out four times at each of the 4 points facing each other. The results of measuring the thickness of the epithelium in 15 seminiferous tubules for each preparation were then averaged for each sample (Munaya et al., 2018). Observation of histological images using a light microscope with a magnification of 400x over the entire field of view. The preparations were photographed using an optilab camera and analyzed.

Data analysis

The data normality test uses the Shapiro-Wilk and Levene Test for homogeneity tests. Analysis of data on differences in research subject groups used the One Way Anova test and the posthoc Tukey test. The confidence level used is 95%.

RESULTS AND DISCUSSION

Pancreas histology

Three days after being given Streptozotocin, the blood sugar levels of all rats increased by more than 200mg/dl. The mice in the DM group looked thinner, the husks looked wetter, and they looked more limp compared to the control group. During the intervention process, one rat in the DM group died.

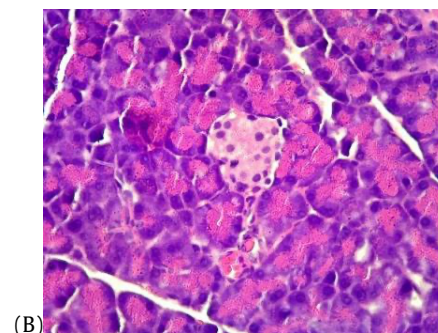
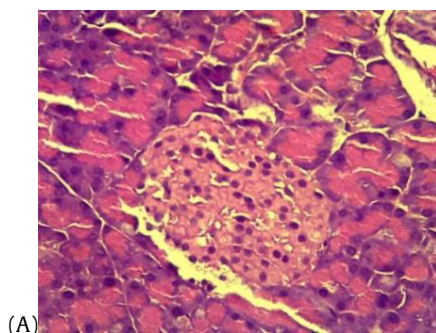
Table 1. The average area of Langerhans islands

Group	N (Number of rats)	Mean ±SD	p-value (ANOVA test)
Health control	5	6492.95 µm ² ± 117.71	p=0,00
Diabetes & Aquades	4	2611.80 µm ² ± 137.25	
Diabetes & Metformin	5	2746.93 µm ² ± 172.07	
Diabetes & Cassava	5	3307.00 µm ² ± 368.51	

Table 2. Post hoc Tukey test of Histology of the pancreas

Group	Comparison group	p-value
Health control	Diabetes & Aquades	0.00*
	Diabetes & Metformin	0.00*
	Diabetes & Cassava	0.00*
Diabetes & Aquades	Diabetes & Metformin	0,83
	Diabetes & Cassava	0,003*
Diabetes & Metformin	Diabetes & Cassava	0.01*

The control group has the largest average area of Langerhans islands compared to the other groups (Table 1). In contrast, the DM group given the aqua dest had the smallest average area of Langerhans Island (Figure 1). The DM group given metformin had a larger size than the one given aqua dest, but the difference was insignificant. Meanwhile, the DM group given cassava extract 200 mg/kgBW had a larger area of Langerhans islands than the DM group given aqua dest or metformin (Table 2).



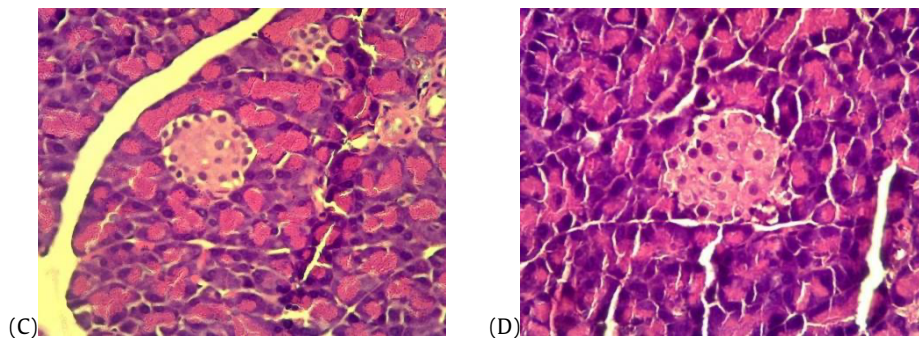


Figure 1. Histological of the pancreas.
(A) Control group; (B) DM control group; (C) DM & metformin group; (D) Cassava extract group 200 mg/kgBW.

Langerhans islands in the untreated DM group were the smallest and significantly different from healthy control rats. Furman (2015) explained that injection of streptozotocin (STZ) in mice causes selective damage to pancreatic β -cells. Islets of Langerhans are dominated by pancreatic β -cells, 70% located in the islets' centre. Destruction of pancreatic β -cells will reduce the area of Langerhans islets in STZ-induced mice. Wu & Yan (2015).

The average area of the Langerhans islands in the group given cassava extract (*Manihot Esculenta*) was larger than the DM group and even wider than the group given metformin. Statistical test results showed significant differences. This shows that the administration of cassava extract affects the area of Langerhans Island. It is supported by Subeki et al. (2016), who conducted a study on the effect of the consumption of cassava products processed into siger rice on the histological picture of the pancreas of rats with diabetes mellitus induced by alloxan. As a result, siger rice, a processed cassava product, can lower blood sugar levels and repair Langerhans β -cells damaged by alloxan induction. *Cassava* is a tuber plant that is often found in everyday life. Cassava contains pyrrolic antioxidants, which have been tested for their antioxidant effectiveness and ability to clean up radicals (Zekarias et al., 2019).

Cassava also contains relatively high soluble fibre, which is 14% (Onodu et al., 2018). Soluble fibre causes a slower gastric emptying rate and increases the viscosity of digested food in the intestine, thereby reducing glucose absorption. As a result, the amount of glucose that reaches the portal vein is lower (Santoso et al., 2020). In addition, fibre can also be fermented by intestinal microbes to produce short-chain fatty acids, including acetate, butyrate, and propionate. Short-chain fatty acids affect glucagon-like peptide 1 (GLP-1), a hormone that increases insulin sensitivity. In addition, short-chain fatty acids can fight oxidative stress. Chronic oxidative stress can cause cell apoptosis in the pancreas and abnormalities in insulin secretion. Therefore, a high amount of fibre in cassava correlates with protection against structural and functional damage to the pancreas (Christiansen et al., 2018).

Administration of metformin in this study did not affect the histological appearance of the pancreas of the STZ-induced diabetes rat model. *Metformin* is a biguanide anti-diabetic drug that works by reducing the process of gluconeogenesis (the formation of glucose from non-carbohydrate substances) and increasing insulin sensitivity. When viewed from the mechanism of action, metformin does not affect the pancreas organ. The research conducted (Yanti et al., 2019) stated that metformin administration did not affect the histological picture of the pancreas. Metformin

only works to decrease blood glucose levels in the periphery, so the histological results of the pancreas in the group given metformin found that pancreatic cells continued to experience necrosis and cell degeneration, as happened in the diabetes mellitus control group. In addition, research conducted by Nurdiana et al. (2017) stated that the effect of metformin on the histological appearance of the pancreas of the diabetic rat model was inconclusive. Similar to the diabetic group, the group that was given metformin also showed extensive destruction of the islets of Langerhans.

Histology of the seminiferous tubule

The results of measuring the average thickness of the seminiferous tubule epithelium of each treatment group can be seen in Table 3. The control group had the highest thickness of the seminiferous tubule epithelium compared to the other groups (Figure 2). The group of rats induced by DM and given distilled water had the thinnest epithelial thickness. In the K3 group, the size of the epithelium was found to be larger than in the K2 group. The cassava extract (*Manihot esculenta*) 200 mg/kgBB intervention group had thicker seminiferous tubular epithelium than the DM group given aqua dest or metformin.

The thickness of the seminiferous tubule epithelium in the DM rat group without intervention was the thinnest compared to the other groups. It shows that streptozotocin can cause complications in the form of thinning of the seminiferous tubular epithelium. In a study conducted by Sisman et al. (2014), induction of streptozotocin could increase blood glucose levels > 240 mg/dL in just 24 hours after injection and showed signs of apoptosis and testicular tissue damage. Hyperglycemia will cause vascular damage and increase oxidative stress, one of which is in the testes (Abbas, Aster & Kumar, 2015). It will cause damage to the seminiferous tubules due to decreased nutrient and oxygen intake and increased oxidative stress (Tobias et al., 2015). Microstructural damage to the seminiferous tubules is characterized by the release of germ cells into the lumen, increased nucleus size and germ cell atrophy, decreased number of spermatids in the lumen and increased number of vacuoles in germ cells and Sertoli cells (Sampanang et al., 2018). Various damages in the seminiferous tubules can cause thinning of the seminiferous tubule epithelium.

The group with DM intervention and given cassava extract (*Manihot esculenta*) had a higher average thickness of the seminiferous tubule epithelium than the DM group, who were given regular food and the DM group, who were given metformin. Cassava (*Manihot esculenta*) contains polyphenols which have antioxidant effects. In fulfilling their role, polyphenolic components reduce several free radicals,

such as superoxide anions, hydroxyl radicals, and other free radicals. Intervention by giving cassava (*Manihot esculenta*) which contains polyphenol antioxidants, can reduce the effects of vascular damage caused by hyperglycemia and

reduce the thinning of the seminiferous tubular epithelium. Research conducted by Opuwari and Monsees (2020) found that the antioxidant content of polyphenols in green tea can improve sperm parameters.

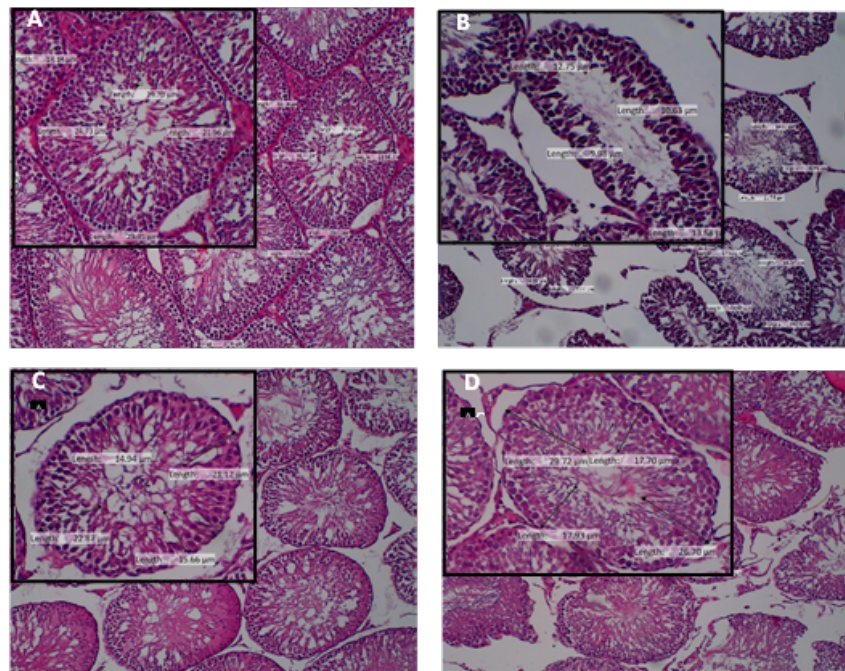


Figure 2. Histological view of the seminiferous tubules. (A) Control group; (B) DM group; (C) DM + metformin induction group; (D) DM group + cassava extract 200 mg/kg BW

Table 3. Average of the thickness of the seminiferous tubule epithelium

Group	N (Number of rats)	Mean ±SD	p-value (ANOVA test)
Health control	5	19.6234 ±1.12 µm	p=0,00
Diabetes & Aquades	4	15.5947 ±0.46 µm	
Diabetes & Metformin	5	17.0502 ±1.42 µm	
Diabetes & Cassava	5	18.0944 ±0.52 µm	

Table 4. Post hoc Tukey test of Histology of tubules seminiferous

Group	Comparison group	p value
Health control	Diabetes & Aquades	0,000
	Diabetes & Metformin	0,005*
	Diabetes & Cassava	0,117
Diabetes & Aquades	Diabetes & Metformin	0,178
	Diabetes & Cassava	0,010*
Diabetes & Metformin	Diabetes & Cassava	0,383

Statistically, the administration of metformin could not increase the thickness of the seminiferous tubule epithelium in rats with DM induction. A study conducted by Behdarvand-Margha (2020) showed that metformin was effective in improving testicular vascularization of DM-induced experimental animals but not as well as in the group with gallic acid intervention, which contains phenolic acid, which is an antioxidant. This study is in line with this study which showed that metformin could minimize the thinning of the thickness of the seminiferous tubule epithelium but was not as effective in the group with the intervention of cassava extract (*Manihot esculenta*), which contains polyphenols as antioxidants.

LIMITATION OF THE STUDY

The limitation of this study is that the histology reading is only done with one slice and two dimensions to represent the entire testicular organ.

CONCLUSIONS AND SUGGESTIONS

Consumption of cassava extract (*Manihot esculenta*) can improve the histological picture of the pancreas and increase the thickness of the seminiferous tubule epithelium in Streptozotocin (STZ)-induced diabetes mellitus rats. The consumption of cassava can be an alternative food substitute besides rice. Further research, namely the genetic mechanism of cassava as a functional food, is needed.

Acknowledgment

The authors would like to thank Ernadita dan Edi Fitriyanto for helping with this study.

ETHICAL CONSIDERATIONS

This research has received approval from the Ethics Committee Faculty of Medicine, Islamic University of Indonesia with ethical number 16/Ka.Kom.Et/70/KE/IX/2021.

Conflict of Interest Statement

There is no conflict of interest.

REFERENCES

- Abbas, A., Aster, J. and Kumar, V. (2015). *Buku Ajar Patologi beliiis*. 9th edn. Singapura: Elsevier Inc.
- Bener, A. Al Anshari. A., Zirie, M., & Al-Hamaq, A. O. (2009). Is male fertility associated with type 2 diabetes mellitus?. *International urology and nephrology*, 41(4), 777–784. <https://doi.org/10.1007/s11255-009-9565-6>
- Chan, M. (2016). Global report on diabetes. *World Health Organization*, 58(12), 1-88.
- Christiansen, C. B., Gabe, M. B. N., Svendsen, B., Dragsted, L. O., Rosenkilde, M. M., & Holst, J. J. (2018). The impact of short-chain fatty acids on GLP-1 and PYY secretion from the isolated perfused rat colon. *American Journal of Physiology-Gastrointestinal and Liver Physiology*, 315(1), G53-G65.
- Da Silva Xavier, G. (2018). The cells of the islets of Langerhans. *Journal of clinical medicine*, 7(3), pp. 54. doi: 10.3390/jcm7030054.
- Departemen Farmakologi dan Terapeutik FK UI. 2007. *Farmakologi dan Terapi* Edisi 5. Jakarta: Bagian Farmakologi FK UI
- Soelistijo et al.. (2019). *Pedoman Pengelolaan Dan Pencegahan Diabetes Melitus Tipe 2 Dewasa Di Indonesia-2021*. Perkeni. Penerbit PB. PERKENI.
- Furman, B. L. (2015). Streptozotocin-Induced Diabetic Models in Mice and Rats' *Current Protocols in Pharmacology*, 70(1), pp. 5.47.1-5.47.20. doi: 10.1002/0471141755.ph0547s70.
- Glazer, C. H. et al. 2017. 'Risk of diabetes according to male factor infertility: A register-based cohort study', *Human Reproduction*, 32(7), 1474–1481. doi: 10.1093/humrep/dex097.
- Hasim et al., 2016. 'Effect of Boiled Cassava Leaves (Manihot esculante Crantz) on Total Phenolic, Flavonoid and its Antioxidant Activity'. Departement of Biochemistry. Bogor Agricultural University.
- Jannah, R., Luh Eka Setiasih, N., Suastika, P., Hewan Praktek di Kabupaten Karumbu, D., & Tenggara Barat, N. (2018). Histopathological Of Diabetes Mellitus White Rat Testicle After Given Moringa Leaf Extract. *Buletin Veteriner Udayana*, 176–182. <https://doi.org/10.24843/BULVET.2018.V10.I02.P11>
- Long, L. et al. (2018). Hyperglycemia induced testicular damage in type 2 diabetes mellitus rats exhibiting microcirculation impairments associated with vascular endothelial growth factor decreased via PI3K/Akt pathway', *Oncotarget*, 9(4), pp. 5321–5336. doi: 10.18632/oncotarget.23915.
- Ma'ruf, A. et al. (2020). Tetap Produktif Cegah, dan Atasi Diabetes Mellitus. Infodatin Pusat Dana dan Informasi Kementerian Kesehatan RI.
- Meilawaty, Z. (2013). 'Efek ekstrak daun singkong (Manihot utilissima) terhadap ekspresi COX-2 pada monosit yang dipapar LPS E.coli (The effect of Manihot utilissima extracts on COX-2 expression of monocytes induced by LPS E. coli)', *Dental Journal Majalah Kedokteran Gigi*, 46(4), p. 196.
- Mekala, K. C., & Bertoni, A. G. (2020). Epidemiology of diabetes mellitus. *Transplantation, Bioengineering, and Regeneration of the Endocrine Pancreas: Volume 1*, 49–58. <https://doi.org/10.1016/B978-0-12-814833-4.00004-6>
- Munaya, N. et al. (2018). Efek Stres Puasa terhadap Ketebalan Epitel dan Diameter Tubulus Seminiferus Rattus norvegicus, *Mutiara Medika: Jurnal Kedokteran dan Kesehatan*, 18(1), pp. 1–7.
- Nurdiana, S., Goh, Y. M., Ahmad, H., Dom, S. M., Syimal' ain Azmi, N., Noor Mohamad Zin, N. S., & Ebrahimi, M. (2017). Changes in pancreatic histology, Insulin secretion and oxidative status in diabetic rats following treatment with Ficus deltoidea and vitexin. *BMC complementary and alternative medicine*, 17(1), pp. 1-17.
- Onodu, B. C. et al. (2018). *Facts About Dietary Fibre in Cassava: Implication for Diabetes' Medical Nutrition Therapy, Integrative Food, Nutrition and Metabolism*.
- Opuwari, C. dan Monsees, T. 2020. 'Green tea consumption increases sperm concentration and viability in male rats and is safe for reproductive, liver and kidney health', *Nature*.
- Sampannang, A. et al. (2018). 'Testicular histopathology and phosphorylated protein changes in mice with diabetes induced by multiple-low doses of streptozotocin: An experimental study', *International Journal of Reproductive BioMedicine*, 16(4), pp. 235–246. doi: 10.29252/ijrm.16.4.235.
- Setiati, S. et al. (2014). *Buku ajar ilmu penyakit dalam jilid I*. VI. Jakarta: InternaPublishing.
- Tobias, D. K. et al. 2015. 'History of infertility and risk of type 2 diabetes mellitus: a prospective cohort study', *Diabetologia*, 58(4), pp. 707–715. doi: 10.1007/s00125-015-3493-z.
- Santoso, P., Maliza, R., Rahayu, R., & Amelia, A. (2020). Pancreoprotective Effect of Jicama (Pachyrhizus erosus, Fabaceae) Fiber against High-Sugar Diet in Mice. *Open Access Macedonian Journal of Medical Sciences*, 8(A), 326–332.
- Subeki, S., Satyajaya, W., Murhadi, M., & Yuliadi, E. (2016). Effect of siger rice from cassava on blood glucose level and the pancreas in mice induced alloxan.
- Wu, J., & Yan, L. J. (2015). Streptozotocin-induced type 1 diabetes in rodents as a model for studying mitochondrial mechanisms of diabetic β cell glucotoxicity. *Diabetes, metabolic syndrome and obesity: targets and therapy*, 8, 181.
- Yanti, E. D., Dewi, N. W. S., & Jawi, I. M. (2019). Kombinasi Ekstrak Sambiloto Dengan Metformin Lebih Baik Dalam Memperbaiki Sel Beta Pulau Langerhans Dari Pada Metformin Tunggal pada Tikus Diabetes. *E-Jurnal Medika*, 8(2), 1-5.
- Zekarias, T., Basa, B. and Herago, T. (2019). Medicinal, Nutritional and Anti-Nutritional Properties of Cassava (Manihot esculenta): A Review. 8(3), pp. 34–46. doi: 10.5829/idosi.ajrn.2019.34.46.