

# THE EFFECT OF COGON GRASS ROOT ETHANOL EXTRACT ON REPRODUCTIVE ORGAN AND EPIDIDYMAL SPERM QUALITY OF MOUSE WITH DIFFERENT AGES

Jaqueline Sudiman<sup>1</sup>, Rini Widyastuti<sup>2\*</sup>, Alkaustariyah Lubis<sup>3</sup>, Tyagita Hartady<sup>4</sup>, Mas Rizky Anggun Adipurna Syamsyunarno<sup>5</sup>, and Sony Heru Sumarsono<sup>6</sup>

<sup>1</sup>Obstetrics and Gynaecology Department, Udayana University, Denpasar, Bali, Indonesia

<sup>2</sup>Laboratory of Animal Reproduction and Artificial Insemination, Department of Animal Production, Animal Husbandry Faculty, Universitas Padjadjaran, West Java, Indonesia

<sup>3</sup>Undergraduate Faculty of Medicine, Universitas Padjadjaran Jatinangor Sumedang, West Java, Indonesia

<sup>4</sup>Veterinary Medicine Program, Faculty of Medicine, Padjadjaran University, West Java, Indonesia

<sup>5</sup>Departemen of Biomedical Science, Faculty of Medicine, Padjadjaran University, West Java, Indonesia

<sup>6</sup>Research Groups of Physiology, Developmental Biology and Biomedical science, School of Life Science and Technology, Bandung Institute of Technology, Labetex XI, Bandung, Indonesia

\*Corresponding author: [r.widyastuti@unpad.ac.id](mailto:r.widyastuti@unpad.ac.id)

## ABSTRACT

This study aims to determine changes related to epididymal sperm parameters in mice given cogon grass root ethanol extract (CGREE). The experiment was carried out by dividing three groups of mice aged 4-week old (early pubertal), 8-week old (adult), and 24-week old (old) as control and treatment groups. The treatment groups were given 115 mg/kg body weight of CGREE for 14 days. The mice were sacrificed on day 15 to assess reproductive organ indexes and quality of the epididymal sperm. Index of epididymis and ductus deferens indices significantly reduced in the 4-week old treatment group compared to control (0.23 vs 0.33; 0.08 vs 0.16, respectively), and vesical seminal significantly reduced in 8-week old treatment group compared to control (0.76 vs 0.68). The epididymal sperm quality significantly decreased in all treatment groups, but the sperm concentration in early pubertal group showed an increase. These results indicate that CGREE can enhance several semen parameters in prepubertal and adult mice but this effect is not apparent in old mice.

Key words: cogon grass root extract, epididymal sperm, reproductive organ

## ABSTRAK

Penelitian ini bertujuan menentukan perubahan yang terjadi pada sperma yang berasal dari epididimis mencit yang diberi ekstrak etanol akar alang-alang (EAAA) secara oral. Eksperimen dilakukan dengan membagi mencit menjadi tiga kelompok yaitu mencit usia 4 minggu (awal pubertas), 8 minggu (dewasa) dan 24 minggu (tua) sebagai grup kontrol maupun yang diuji. Kelompok uji diberi 115 mg/kg bb EAAA selama 14 hari. Mencit kemudian dikorbankan pada hari ke-15 untuk dinilai indeks organ reproduksi dan kualitas sperma epididimis. Indeks epididimis dan duktus deferens berkurang secara signifikan pada kelompok perlakuan 4 minggu (0.23 vs 0.33; 0.08 vs 0.16), dan vesikal seminalis berkurang secara signifikan pada kelompok mencit usia 8 minggu dibandingkan dengan kontrol (0.76 vs 0.68). Kualitas sperma epididimis menurun secara signifikan pada semua kelompok perlakuan, tetapi konsentrasi sperma pada kelompok pubertas awal menunjukkan peningkatan. Hasil ini menunjukkan bahwa EAAA dapat meningkatkan beberapa parameter semen pada tikus prapubertas dan dewasa tetapi efek ini tidak berlaku pada tikus tua.

Kata kunci: ekstrak akar alang-alang, sperma epididimis, organ reproduksi

## INTRODUCTION

In this modern era, almost all big pharmaceutical companies take part in the mass production of chemically synthesized medicine. However, in some parts of the world especially in developing countries, access to traditional practicing and utilization of herbal medicine is very popular. World Health Organization (WHO) estimates that 80% population of developing countries are using herbs for health care and therapy (De, 1994; WHO, 2002). African, Indian, and Chinese count on traditional medicine up to 90%, 70%, and 40% of their population, respectively (Benzie and Watchel-Galor, 2011). This phenomenon could be due to the affordable price, ease of access, and side effect, and lower toxicity compared to synthetic chemical medicine (Koger and Bryson, 2004; Parkavi *et al.*, 2012). The use of traditional medicine is not limited only to developing countries. In the United States, almost 40% of the adult population and 11.8% of

children use traditional medicine as a remedy (Benzie and Watchel-Galor, 2011; Yakubu *et al.*, 2008a).

Many common traditional herbs such as turmeric (*Curcuma longa*), papaya (*Carica papaya*), mondia (*Mondia whitei*), Chinese hibiscus (*Hibiscus rosa Sinensis*), neem (*Azadirachta indica*), black pepper (*Piper nigrum*), and celery (*Apium graveolens*) are used as supplementary medicine and also have anti-spermatogenic and anti-fertility for men. Cogon grass (CG) is a herbal medicine that has been traditionally used widely to relieve symptoms occurred in children and adults such as urinary tract infection and intestinal disorders including dysentery and diarrhea (Okwu and Josiah, 2006) myalgia, night sweats, piles, and common cold (Koger and Bryson, 2004) and antibacterial activity (Parkavi *et al.*, 2012).

The previous research reported that CG exhibits various results in infertility (Zhou *et al.*, 2013; Lubis *et al.*, 2018). The difference in results encourages us to evaluate the effect of cogon grass root ethanol extract

(CGREE) administration on reproductive organs and epididymal sperm quality of mice at different ages. Finally, the result could enhance the general understanding of whether CG could only affect mice fertility in certain age or all level of ages. This issue may become a consideration as preventive medicine to solve infertility problems.

## MATERIALS AND METHODS

Cogon grass was purchased from Solo, Central Java, Indonesia. Cogon grass roots was macerated with 95% ethanol for 72 hours, filtrated with a vacuum filter, and concentrated in a vacuum evaporator. The concentrated extracts was then suspended with 0.5% carboxymethyl cellulose (CMC) and separated to a concentration of 115 mg/kg body weight. The extract was subjected to preliminary phytochemical screening and the results were presented in Table 1.

Thirty six male mice of DDY with different ages (4-week old, early pubertal), 8-week old, adult, and 24-week old, (old) purchased from PT Bio Farma, Indonesia were used in this experiment. Animals were housed in cages equipped with tap water under 24 hours light and fed with standard feed. The study was approved by the Ethics Review Committee of the Faculty of Medicine, Universitas Padjadjaran (1263/UN6.C10/PN/2017). This study was performed in the Mouse Animal Laboratory, Faculty of Medicine and Laboratory of Animal Reproduction and Artificial Insemination Faculty of Husbandry, Universitas Padjadjaran.

Animals were divided into three groups according to animal ages. Animals in group I, II, and III aged 4-week-old (12 mice), 8-week-old (12 mice) and 24-week-old (12 mice) respectively. Six of 12 animals in each group were treated orally with CGREE of 115 mg/kg body weight for 14 days, while the rest (six mice) was not fed by CGREE (control). The animal was weighed and sacrificed using anesthetic isoflurane on the day 15. The reproductive organ body weight ratio was calculated according to the previous research (Yakubu *et al.*, 2008b). The cauda epididymis was used to evaluated sperm characteristics.

### Epididymal Sperm Concentration

Epididymal sperm was collected by mincing 100 times of the cauda epididymis in 1 mL of NaCl, The 10  $\mu$ L of semen sample was then diluted with aqua dest up to 300  $\mu$ L of final solution (dilution factor = 30). Subsequently, 10  $\mu$ L of the final solution was loaded into hemocytometer and allowed to stand for 5 minutes.

The number of existed sperm in 5 random squares of hemocytometer (SN) was counted on 200x magnification using phase-contrast microscope. Finally, the sperm concentration was estimated by multiply sperm number (SN), multiplication factor (50000) and dilution factor (30).

### Sperm Motility

The percentage of motile sperm was evaluated visually in each sample by viewing a drop of sperm suspension diluted with Tris buffer solution (3.63 g of Tris-hydroxymethyl aminomethane, 0.50 g glucose, 1.99 g of citric acid, and 100 mL of distilled water) on a pre-warmed (37° C) slide under a pre-warmed coverslip with a phase-contras microscope at 400x magnification. A total of 200 sperm were counted and categorized as motile and immotile, scored between 0-100%.

### Sperm Morphology

Sperm with abnormal morphology have head or tail defects such as no hook and double head or no tail, bent, short tail, and double tail. A drop of eosin-nigrosin and sperm were smeared in a glass slide and then allowed to dry and flushed with methanol. A total of 200 sperm cells evaluated using a phase-contras microscope at 1000x magnification.

### Data Analysis

All the analyses were carried out using Prism software version 8 (GraphPad Inc, San Diego, CA, USA). Data presented as average  $\pm$  standard deviation and compared using the T-test. Different in mean was considered at  $P < 0.05$ .

## RESULTS AND DISCUSSION

The extracts obtained by successive solvent subjected to preliminary phytochemical screening, which revealed the presence of alkaloids, flavonoid, steroid, saponin, tannin, and phenol (Table 1). Generally, oral administration of CGREE for 14 days caused a decrease of testis index in all treatment groups (Figure 1A), although the treatments had no significant effect. The epididymis and ductus deferens indexes was significantly reduced in 4-week old treated animals compared to control (0.23 vs 0.33; 0.08 vs 0.16, respectively, Figure 1C and 1D). On the contrary, the seminal vesicle index showed a different pattern, it tends to increase in all treatment groups and was significantly increased in the 8-week-old treatment group compared to control group (0.76 vs 0.68, Figure 1B).

**Table 1.** Preliminary phytochemical analysis of cogon grass root ethanol extract

Test	A	B	C	D	E	F	G
Phenolic	+						
Tanin	+						
Flavonoid			+	+			
Saponin					+		
Triterpenoid and steroid						+	
Alkaloid							+

A= FeCl<sub>3</sub> 5%, B= FeCl<sub>3</sub> 1%, C= HCL+ Mg, D= NaOH 10%, E= Heating, F= H<sub>2</sub>SO<sub>4</sub>+CH<sub>3</sub>COOH, G= Dragendorff

The sperm concentration was significantly increased in the early pubertal treated group compared to control group ( $0.68 \pm 0.25 \times 10^6/\text{mL}$  vs  $7.24 \pm 1.92 \times 10^6/\text{mL}$ ,  $P < 0.05$ , Figure 2A). On the contrary, adult mice treated group showed significant decreased in sperm concentration compared to control ( $9.02 \pm 1.38 \times 10^6/\text{mL}$  vs  $14.57 \pm 2.3 \times 10^6/\text{mL}$ , Figure 2A). Our experiment also indicated a significant decreased in sperm motility of all treatment groups compared to control (Figure 2B). On the other side, abnormal sperm morphology was increased significantly about two-fold in all treatment groups compared to control (Figure 2C).

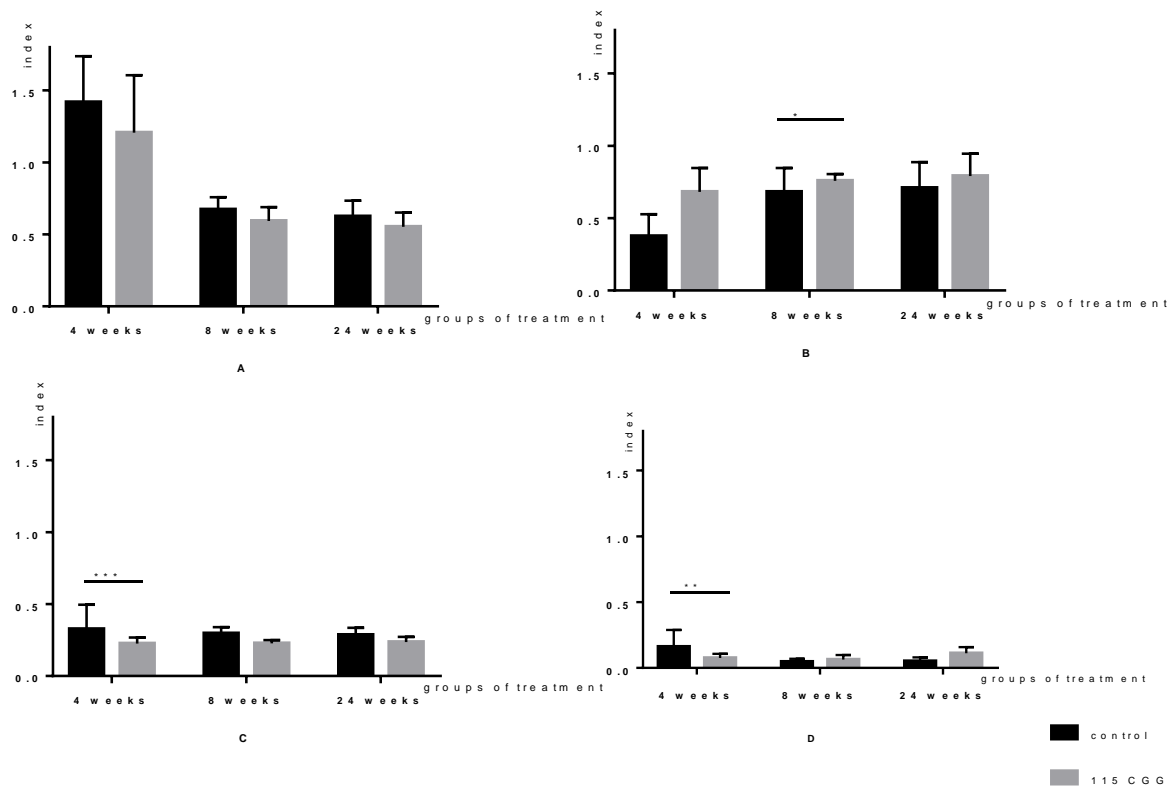
Figure 3 presented the detail of abnormal sperm morphology from control and treatment groups. The result showed a decrease in head abnormal morphology in all treated animals compared to control although it was not significant. Interestingly, the neck and tail abnormality was increased in all treated animals. The neck abnormality was increased significantly in 4-week old group and the tail abnormality was increased significantly in 8-week old group.

The results also showed that CGREE contained saponin, alkaloid, phenolic, and steroid in their substance. The previous research reported that alkaloids, steroids, phenolic acids, and flavonoids have a noticeable anti-fertility potential (Chakravarty *et al.*, 2003; Russo and Borrelli, 2005; Manthri *et al.*, 2013). Therefore, the presence of saponin, alkaloid, phenolic, and steroid in CGREE, which act either alone or in combination, may play a role as antifertility. The

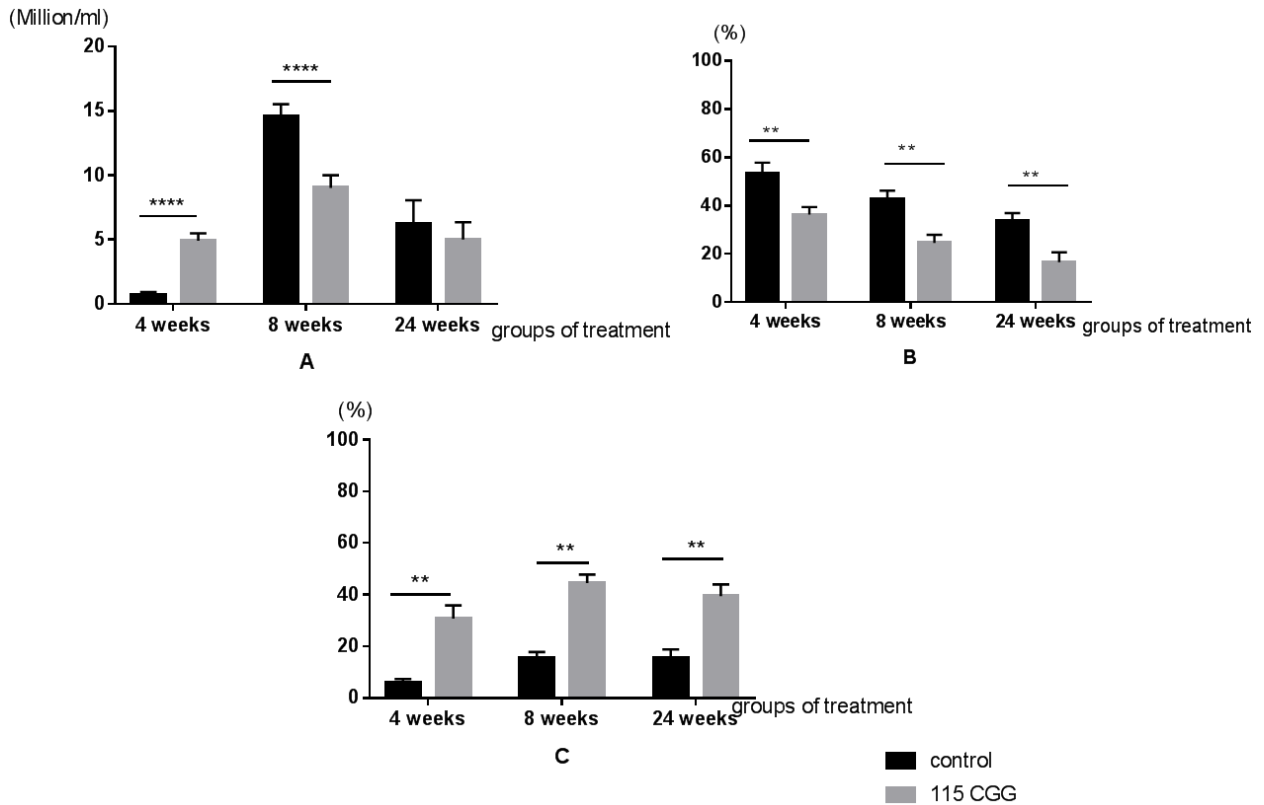
activity of saponin as anti-fertility and abortifacient (Dande and Patil, 2012) as well as sperm immobilization (Dubey and Dubey, 2019) have been sufficiently confirmed in animals model. In the present study, the CGREE was tested for its anti-fertility activities at different age of male mice by observing reproductive organ and epididymal sperm quality.

Moreover, CGREE administration indicated a significant effect on reproductive organ indexes, mainly in early pubertal and adult treatment groups. The phenomena indicated that the administration of CGREE may induce disturbance production and bioavailability of androgen which influences the function and growth of androgen-dependent organs, mainly testes, epididymis, seminal vesicles, and ventral prostate (Klinefelter *et al.*, 2008). There was a pattern that seminal vesicles, testes, and epididymal indexes in a mature animal treatment group was decreased which may correlate with bodyweight gain. The present study showed that the weight of adult and old mice was slightly increased or constant. The seminal vesicle will reach its peak size so the index tends to decline. On the other hand, the early pubertal mice given CGREE had a double-up weight gain compared to control group. The increased in organ weight was followed by an increased in body weight which in turn caused an increased in organ-body weight index.

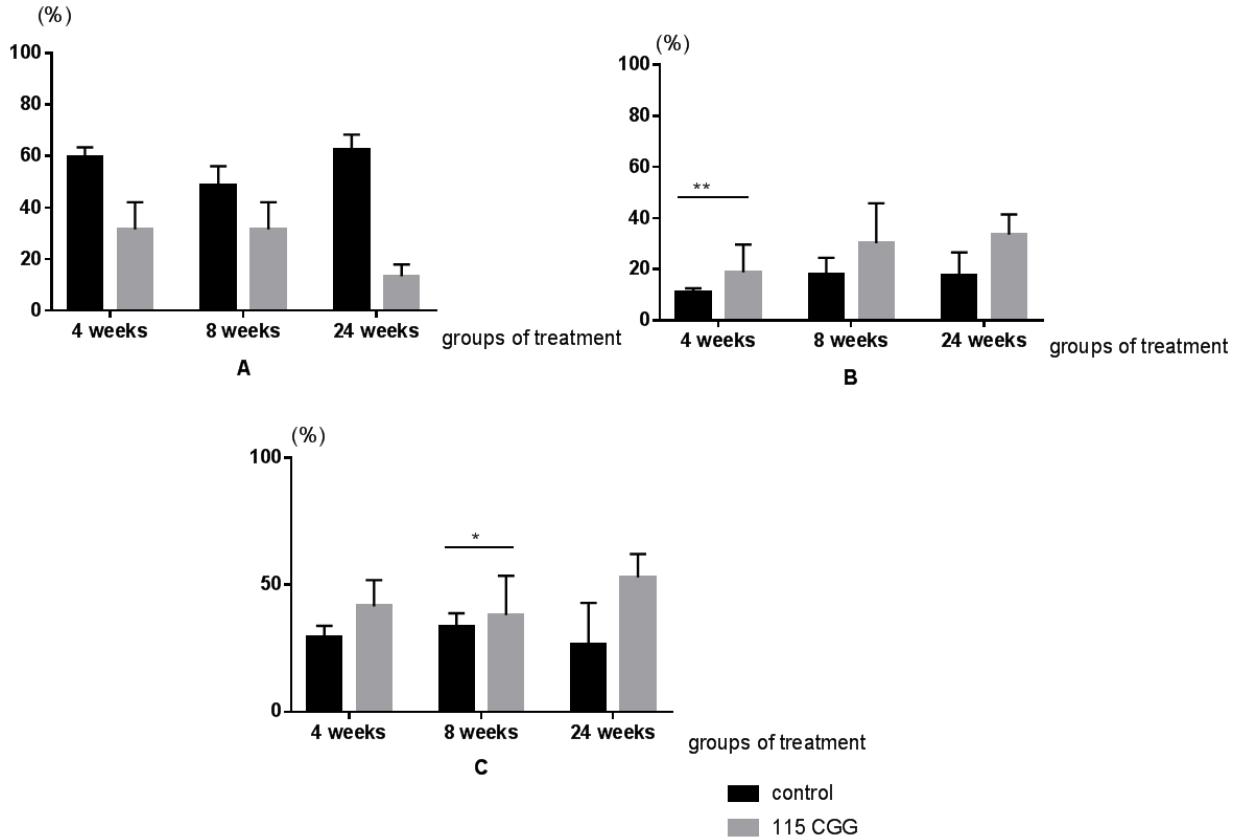
Generally, the result showed that the epididymal sperm quality was reduced in all treatment groups compared to control group except for early pubertal



**Figure 1.** Reproductive organ indexes of control and treatment groups. A= Testis index, B= seminal vesicles index, C= Epididymis index, [D] ductus deferens index. \* (asterisk) indicates statistically significant differences ( $P < 0.05$ ) between control and treatment groups



**Figure 2.** Sperm concentration [A], motility [B] and abnormality (C) of control and cogon grass root extract treatment groups after 14 days. \* (asterisk) indicates statistically significant differences ( $P < 0.05$ ) between control and treatment groups



**Figure 3.** Sperm abnormalities types of control and cogon grass root extract treatment groups after 14 days. A= Head abnormal morphology, B= Neck abnormal morphology, C= Tail abnormal morphology. \* (asterisk) indicates statistically significant differences ( $P < 0.05$ ) between control and treatment groups

mice group which showed an increase in sperm concentration. The reduction of sperm concentration may correlate with the decreased of testis index which had detrimental effect on spermatogenesis. The administration of CGREE may induce the disturbance of germ cells in tubules and intra tubules as organs for maintaining sperm production.

Reduction in sperm motility in this present study indicated a disturbance in epididymis or disruption during the maturation process. Epididymis damage caused alteration on luminal epididymal fluid containing ion which contributed directly to control cAMP concentration and leads to activation of protein phosphorylation. The disruption of protein phosphorylation causes the reduction of ATP production that is crucial as energy for sperm movement (Gervasi and Visconti, 2017). The decreased of sperm motility in all treatment groups also strongly correlated to the increased of abnormal sperm morphology, mainly in the neck area where mitochondria are located to provide energy source for the sperm's motility.

The primary defect of sperm such as head abnormal morphology was decreased in all treatment groups compared to control. On the other side, the increased of neck and tail abnormal morphology indicated that the administration of CGREE orally induced secondary sperm abnormality. Secondary sperm abnormality could happen in epididymis where maturation takes place after sperm exit from seminiferous tubules. Based on the results, it might be possible that the disruption of sperm development occurred during maturation in the epididymis.

The present research also indicated that the gavage of CGREE in a short time induced alteration of reproductive organs followed by a decreased of epididymal sperm quality. Since CGREE contained alkaloids it had detrimental effect on sperm quality. Yakubu (2012) reported that alkaloid extracts from *Chromolaena odorata* deteriorate sperm quality and hormones in male mice, decrease sperm count, motility, and density as well as increase abnormal sperm morphology. Kumar and Sachin (2013) also reviewed that plants contained alkaloids have anti-ovulatory, abortifacient, and contraceptive effect. Another study about ginseng (*Panax*) which contained an abundant of ginsenosides (saponin) and flavonoid caused a significant decrease in total sperm abnormalities, increase in sperm numbers and motility as well as an increase in plasma concentration of testosterone, FSH, and LH (Leung and Wong, 2013). In this present study, combination of these substances in CGREE may deteriorate sperm quality, decrease sperm count and motility, as well as increase abnormal sperm morphology. However, the most affected and accurate change observed in 8-week-old mice (adult). It was predicted that those phenomena may cause by maturation and sufficient function of sexual organs evaluated in this age. A CGREE effect in early mature age (early pubertal group) could be biased because of pubertal changes such as increasing organ weight and

hormonal concentration until they physiologically sufficient. On the other side, old mice group organ function was also physiologically deteriorated due to many factors such as external environment exposure, decrease in hormonal production or decrease the sensitivity of hormones receptor thus the CGREE effect may not adequate to revert to its normal value. In conclusion, the most accurate disruption in all parameters observed in 8-week-old mice.

## CONCLUSION

The orally administration of CGREE enhance several reproductive organ indexes in prepubertal in adult mice but does not affect the old mice.

## ACKNOWLEDGMENTS

Many thank to animals laboratory staff for excellent technical assistance. This study was supported by PDUPT KEMRISTEKDIKTI 2019.

## REFERENCES

- Benzie, I.F.F. and S. Watchel-Galor. 2011. Herbal Medicine: An Introduction to Its History, Usage, Regulation, Current Trends, and Research Needs. In **Herbal Medicine: Biomolecular and Clinical Aspects**. Benzie, I.F.F. and S. Watchel-Galor (Eds). 2<sup>nd</sup> ed. CRC Press Taylor & Francis Group, London.
- Chakravarty, A.K., S. Garai, K. Masuda, T. Nakane, and N. Kawahara. 2003. Bacopasides III-V: Three new triterpenoid glycosides from *Bacopa monniera*. **Chem. Pharm. Bul.** 51(2):215-217.
- Dande, P. and S. Patil. 2012. Evaluation of saponin from *Trigonella foenum graecum* seeds for its antifertility activity. **Asian J. Pharm. Clin. Res.** 5(3):154-157.
- De, T.S. 1994. Traditional medicine. **J. Indian Med. Assoc.** 92(6):207.
- Dubey, R. and K. Dubey. 2019. Sperm immobilization potential of saponin extract of *Ziziphus mauritiana*. **J. Drug Deliv. Ther.** 9(2-A):78-80.
- Gervasi, M.G. and P.E. Visconti. 2017. Molecular changes and signaling events occurring in sperm during epididymal maturation. **Andrology.** 5(2):204-218.
- Kumar, C. and P.J. Sachin. 2013. Pharmacological action of plant alkaloids in female reproductive system of test animals and/or human beings: A review. **Int. J. Pharm. Sci. Rev. Res.** 23(2):98-107.
- Koger, C.H. and C.T. Bryson. 2004. Effect of cogon grass (*Imperata cylindrica*) extracts on germination and seedling growth of selected grass and broadleaf species. **Weed Technol.** 18(2):236-242.
- Klinefelter, G.R., U. States, E. Protection, and R.A. Hess. 2008. Toxicity of the excurrent ducts and accessory organs in the male. In **Reproduction and Developmental Toxicology**. Korach, K.S. (Ed.). Marcel Dekker Inc., Newyork.
- Lubis, A., R. Widyastuti, S. Robianto, M. Priscilla, and M.R.A.A. Syamsunarno. 2018. Old mice epididymal sperm quality after short term gavage of cogon grass root ethanol extract. **Majalah Kedokt. Bandung.** 50(2):120-126.
- Leung, K.W. and A.S. Wong. 2013. Review: Ginseng and male reproductive function. **Spermatogenesis.** 3(3):e26391-1-e26391-6.
- Manthri, S., C.S. Kota, and M. Tallur. 2011. Review: Phytochemical and pharmacological review of *dendrophthoe falcata*. **J. Phyto.** 3(3):18-25.
- Okwu, D.E. and C. Josiah. 2006. Evaluation of the chemical composition of two Nigerian medicinal plants. **African J. Biotechnol.** 5(4):357-361.
- Parkavi, V., M. Vignesh, K. Selvakumar, J.M. Mohamed, and J.J.Ruby. 2012. Antibacterial activity of aerial parts of *Imperata*

- cylindrica* (L) Beauv. **Int. J. Pharm. Sci. Drug Res.** 4(3):209-212.
- Russo, A. and F. Borrelli. 2005. *Bacopa monniera*, a reputed nootropic plant: An overview. **Phytomedicine.** 12(4):305-317.
- WHO. 2002. Traditional Medicine Strategy 2002-2005, Traditional Medicine Strategy 2002-2005. World Health Organization, Geneva. <https://doi.org/WHO/EDM/TRM/2002.1>.
- Yakubu, M.T., M.A. Akanji, A.T. Oladiji, A.W.O Olatinwo, A.A Adesokan, M.O. Yakubu, B.V. Oweyele, T.O. Sunmonu, and M.S. Ajao. 2008a. Effect of *Cnidoscoulous aconitifolius* (Miller) I.M. Johnston leaf extract on reproductive hormones of female rats. **Iran. J. Reprod. Med.** 6(3):149-155.
- Yakubu, M.T., M.A. Akanji, and A.T. Oladiji. 2008b. Effects of oral administration of aqueous extract of *Fadogia agrestis* (Schweinf. Ex Hiern) stem on some testicular function indices of male rats. **J. Ethnopharmacol.** 115(2):288-292.
- Yakubu, M.T. 2012. Effect of a 60-day oral gavage of a crude alkaloid extract from *Chromolaena odorata* leaves on hormonal and spermatogenic indices of male rats. **J. Androl.** 33(6):1199-1207.
- Zhou, X.R., J.H. Wang, B. Jiang, J. Shang, and C.Q. Zhao. 2013. A study of extraction process and in vitro antioxidant activity of total phenols from *Rhizoma Imperata*. **African J. Tradit. Complement Altern. Med.** 10(4):175-178.