

## ACUTE TOXICITY TEST OF ETHANOLIC EXTRACT OF *Acalypha hispida* LEAVES IN FEMALE RATS: A PHYSIOLOGICAL AND HISTOLOGICAL STUDY

Hamzah Alfarisi<sup>1</sup>, Mawar Subangkit<sup>2</sup>, Siti Sa'diah<sup>3</sup>, and Tutik Wresdiyati<sup>3\*</sup>

<sup>1</sup>Postgraduate Student of Department of Anatomy, Physiology, and Pharmacology, Faculty of Veterinary Medicine, IPB University, Bogor, Indonesia

<sup>2</sup>Laboratory of Veterinary Pathology, Faculty of Veterinary Medicine, IPB University, Bogor, Indonesia

<sup>3</sup>Department of Anatomy, Physiology, and Pharmacology, Faculty of Veterinary Medicine, IPB University, Bogor, Indonesia

\*Corresponding author: [tutikwr@gmail.com](mailto:tutikwr@gmail.com)

### ABSTRACT

This research aims to evaluate the safety of ethanolic extract of *Acalypha hispida* (*A. hispida*) leaves with acute toxicity test using 15 female rats strain Sprague-Dawley. A single dose of different doses of extract (2, 4, 8, and 16 g/kg body weight) was administered orally, and the observation was conducted for 14 days. The results revealed that the ethanolic extract of *A. hispida* leaves was relatively harmless ( $LD_{50} > 16$  g/kg BW), did not affect body weight, and did not show clinical signs of toxicity during the observation periods. The parameters of blood serum biochemistry of all extract-treated groups (alanine aminotransferase, aspartate aminotransferase, creatinine, and urea) did not change significantly compared to the control group. The histological observation of the liver showed a significant increase in eosinophilic cytoplasm and basophilic nuclei at all doses. However, the ethanolic extract of *A. hispida* leaves did not significantly affect glomerulus/Bowman's capsule ratio, glomerular cell density, and the proportion of normal cell tubule. In conclusion, the ethanolic extract of *A. hispida* leaves was relatively harmless with  $LD_{50} > 16$  g/kg BW and seems to be safe in low doses ( $< 2$  g/kg BW).

Key words: *Acalypha hispida*, acute toxicity, female rats, histology, serum biochemistry

### ABSTRAK

Penelitian ini bertujuan mengevaluasi keamanan ekstrak etanol daun *Acalypha hispida* (*A. hispida*) dengan uji toksisitas akut menggunakan 15 ekor tikus betina galur Sprague-Dawley. Ekstrak diberikan secara oral pada dosis tunggal (2, 4, 8, dan 16 g/kg bobot badan) dan pengamatan dilakukan selama 14 hari. Hasil penelitian menunjukkan bahwa ekstrak etanol daun *A. hispida* relatif tidak berbahaya ( $LD_{50} > 16$  g/kg bobot badan) dan tidak menimbulkan efek terhadap bobot badan dan gejala klinis toksik selama periode pengamatan. Parameter biokimia serum darah (alanin aminotransferase, aspartat aminotransferase, kreatinin, dan urea) pada semua kelompok perlakuan tidak menunjukkan perubahan yang signifikan dibandingkan kelompok kontrol. Gambaran histologi jaringan hati menunjukkan peningkatan sitoplasma eosinophilia dan inti basophilia pada semua dosis perlakuan. Namun, ekstrak daun *A. hispida* tidak memengaruhi rasio glomerulus/kapsula Bowman, densitas sel di glomerulus, dan proporsi sel normal pada tubulus ginjal. Ekstrak etanol daun *A. hispida* bersifat relatif tidak berbahaya, namun aman pada dosis rendah ( $< 2$  g/kg bobot badan), dengan nilai  $LD_{50} > 16$  g/kg bobot badan.

Kata kunci: *Acalypha hispida*, toksisitas akut, tikus betina, histologi, biokimia serum

### INTRODUCTION

*Acalypha hispida* (*A. hispida*) Burm. L belongs to the family of Euphorbiaceae and traditionally used as the herbal drug. The leaves poultice of *A. hispida* is used for leprosy, whereas the decoction of leaves and flowers is used for gonorrhoea, laxative, and diuretic (Bokshi *et al.*, 2012; Seebaluck *et al.*, 2015). The ethanolic extract of *A. hispida* leaves also showed antimicrobial and antifungal (Ejечи and Souzey, 1999; Bokshi *et al.*, 2012). Indeed, the strong antioxidant activity was exhibited by the aqueous and ethanolic extract of *A. hispida* leaves with the half-maximal inhibitory concentration ( $IC_{50}$ ) value of 14  $\mu$ g/mL and 17  $\mu$ g/mL, respectively (Siraj *et al.*, 2016). The phytochemical assay showed that ethanol and aqueous extract of *A. hispida* leaves contained glycosides, flavonoids, steroids, phlobatin, saponin, and hydroxyanthraquinone (Iniaghe *et al.*, 2009; Okorundu *et al.*, 2014). Polyphenolic compounds, including ellagic acid, gallic acid, quercetin, p-coumaric acid, and rutin, were also detected in ethanolic and aqueous extract of *A. hispida* leaves (Siraj *et al.*, 2016).

The cytotoxicity assay of seven (from 14) hexane fraction of *A. hispida* leaves was found to be toxic using

brine shrimp lethality test. The ethanolic crude extract of *A. hispida* leaves was toxic with lethal concentration ( $LC_{50}$ ) was 19.95  $\mu$ g/mL (Bokshi *et al.*, 2012). However, the acute toxicity assay of a combined extract of *A. hispida*, *A. fruticosa*, and *A. nervosa* did not show mortality and adverse effect at a dose of 200 mg/kg BW during seven days treatments. In the subacute toxicity study, the combination of these extracts did not result in death, and a significant changes of body weight, hematology, and blood biochemistry (Manikanta *et al.*, 2014). The present research aimed to evaluate the safety dose range of ethanolic extract of *A. hispida* leaves by toxicity study on animal model

### MATERIALS AND METHODS

#### Sample Preparation and Extraction

*A. hispida* leaves were obtained from Tropical Biopharmaca Research Center (TropBRC), IPB University, in the rainy season. The leaves were dried in the oven at 50° C for three days. Dried leaves were grounded and filtered with the help of 60 mesh strainer. Powdered samples were macerated in 96% ethanol, with a ratio of 1:10. The maceration was kept for 72 hours with shaking and stirring every 12 hours. Finally,

the solvent was filtered and evaporated to obtain dry extract using a rotary evaporator.

### Animal Experiments

A total of 15 female Sprague-Dawley rats (weight 120-160 g; nullipara; not pregnant) were used in this study. The acclimatization was conducted for 14 days. The room temperature (22-25° C), air exchange, photoperiod (12 hours in the dark; 12 hours in the daylight), and relative humidity (55-63%) were controlled. Free access to food and water was given to animals. The protocol was approved by the Animal Ethics Committee, Faculty of Veterinary Medicine, IPB University (approval number: 143/KEH/SKE/VI/2019).

### Acute Toxicity Test

Acute toxicity test used 15 female Sprague-Dawley rats. They were divided into five groups; one control group and four treatment groups that were given with 96% ethanolic extract of *A. hispida* (AH) leaves. Control group was given the solvent of extract (carboxymethyl cellulose), and four treatment groups (AH2, AH4, AH 8, and AH16) were given different doses of extract: 2 g/kg BW, 4 g/kg BW, 8 g/kg BW, and 16 g/kg BW, respectively. The extract was orally administrated with a single dose. Before treatment, rats were fasted for 14 hours. The weight was recorded on the 0<sup>th</sup>, 7<sup>th</sup>, and 14<sup>th</sup> days. The observation for 14 days included fear and behavior, skin and fur, regular respiratory, eye, feces, tremor, convulsion, salivation, and paralysis (OECD, 2001; BPOM, 2014). The rats mortality and moribund were also calculated.

### Collection of Blood and Organ

On 16<sup>th</sup> days, all animals were anesthetized using ketamine-xylazine (70 mg/kg-20 mg/kg BW). Blood samples were collected via cardiac puncture, then blood serum was separated for biochemical analysis. The liver and kidney were collected and fixed with Bouin's fixative for histological analysis.

### Blood Biochemical Analysis

The function of the liver was determined by evaluating the activity of alanine aminotransferase (ALT) and aspartate aminotransferase (AST) enzyme in the blood. The function of the kidney was investigated by observing the level of creatinine dan urea in the blood. The analysis was conducted with SELECTRA JUNIOR Autoanalyzer (Vital Scientific, The Netherlands).

### Liver and Kidney Histological Analysis

After fixation, the liver and kidney tissues were trimmed. The tissues were then processed using the

paraffin embedding standard method with a tissue embedding console (Tissue-Tek, SAKURA) and sectioned (5 µm) using a rotary microtome. The tissue sections were stained with hematoxylin-eosin (Kiernan, 2008). The slide histology was examined under a light microscope (Olympus BX 31) equipped with a CCD10 USB Camera. Histological analysis of liver and kidney was captured using ImageJ 1.05i. The cytoplasmic intensity, nuclear cell size, and nuclear intensity of the liver were investigated. The kidney was analyzed for the ratio of a glomerulus/Bowman's capsule (%), glomerular cell density, and the proportion of normal cell tubule (%).

### Data Analysis

All data were analyzed and visualized using the R program and R studio. The effect of treatment was analyzed using one-way analysis of variance (ANOVA) with  $P < 0.05$ . Post hoc analysis conducted with Duncan's Multiple Range Test (DMRT).

## RESULTS AND DISCUSSION

### Body Weight and Clinical Signs of Toxic

Acute toxicity test is used to evaluate the toxic effect of substance for a short period at a single or repeated dose, which is no more than 24 hours. It is used to calculate LD<sub>50</sub> value, a dose that causes death in 50% of animal experiments with oral administration. The present study revealed that there were no mortalities of female rats at all dose treatments for 14 days (Table 1). The highest dose (16 g/kg BW) of extract did not cause mortalities and moribund so that, the LD<sub>50</sub> value of ethanolic extract of *A. hispida* leaves is > 16 g/kg BW. According to Hodge and Sterner (1949), the LD<sub>50</sub> value of more than 16 g/kg is relatively harmless. The present result was contradictory from previous research that observed that the ethanolic extract of *A. hispida* leaves was toxic (LC<sub>50</sub>= 19.95 µg/mL) to brine shrimp (Bokshi et al., 2012). The present finding indicated that the ethanolic extract of *A. hispida* leaves was non-toxic in female rats.

The control and treatment groups showed an increase trend in the body weight every seven days. Nonetheless, these increased body weights were not significant (Figure 1). In addition, the body weight between control and treatment groups did not exhibit significantly different on the 0<sup>th</sup>, 7<sup>th</sup>, and 14<sup>th</sup> days. The present result implied that the ethanolic extract of *A. hispida* leaves did not alter the physiological conditions related to growth.

The observation of the clinical behavior of extract treated-rats for 14 days was displayed in Table 2. The

**Table 1.** The mortality percentage (%) of female rats after the administration of *A. hispida* leaves extract

Groups	Doses (g/kg)	The number of animals	The number of death	Mortalities (%)
Control	0	3	0	0
AH2	2	3	0	0
AH4	4	3	0	0
AH8	8	3	0	0
AH16	16	3	0	0

rats in control and treatment groups after the administration of the extract did not show clinical signs of toxicity which indicate that the ethanolic extract of *A. hispida* leaves did not cause clinical signs of toxicity.

### Blood Biochemistry Profile

The commonly organs susceptible to the toxicity effect of the substance are liver and kidney. One of the major actions of the liver is to detoxify potential toxic and waste products via biotransformation and excretion (Dukes, 2015). The function of the kidney is to remove metabolic waste products and foreign chemicals from the blood and their excretion in urine (Widmaier et al., 2015). Therefore, blood biochemical assay aimed to evaluate the function of both organs. The functional indicator of the liver was determined based on the level of ALT and AST enzyme. At present study, the average level of ALT and AST are 73.67-89.67 U/L and 136-146 U/L, respectively (Figure 2a and Figure 2b). Increased doses of treatment were followed by increased ALT and decreased AST. However, these changes of both enzymes were no statistically different. The previous study showed that the average level of ALT and AST enzyme of the female rat under normal physiological conditions are 76.6 U/L and 150 U/L, respectively (Kim et al., 2010; Kanife et al., 2012).

The kidney function was evaluated through the level of creatinine and urea. At present study, the average level of creatinine and urea were 0.63-0.66 mg/dL and 54.50-73.25 mg/dL, respectively (Figure 2c

and Figure 2d). The changes in the level of creatinine and urea were not significant. According to the previous study, the average level of creatinine and urea of female rats under normal physiological conditions are 66.6 mg/dL and 0.7 mg/dL, respectively (Han et al., 2008; Kim et al., 2010). The result exhibited that the administration of *A. hispida* leaf extract did not disturb the liver and kidney functions

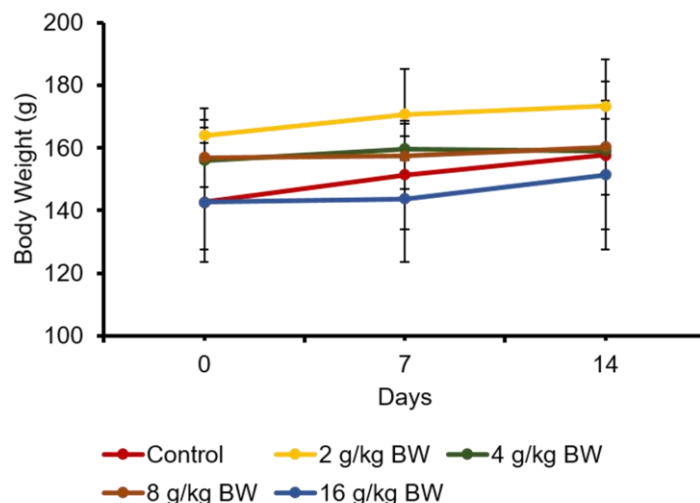
### Histological Analysis of Liver and Kidney

Histological analysis was conducted on the liver and kidney tissue to evaluate the cellular effect of *A. hispida* leaf extract. The liver and kidney tissue were stained using hematoxylin-eosin (HE) to study the morphology of cells. The principal of HE staining is an acid-basic reaction. Hematoxylin, which is a cationic dye, stained nuclei by bluish-black. Eosin, an anionic dye, is used as a counterstain of cytoplasm by red-pink (Dey, 2018). The reaction capability of the cells on HE stain, which is represented in color intensity, is used to be the indicator of cell metabolism change in the nucleus and cytoplasm. The color intensity was measured with a gray value, in which the darker the color, the lower the gray value.

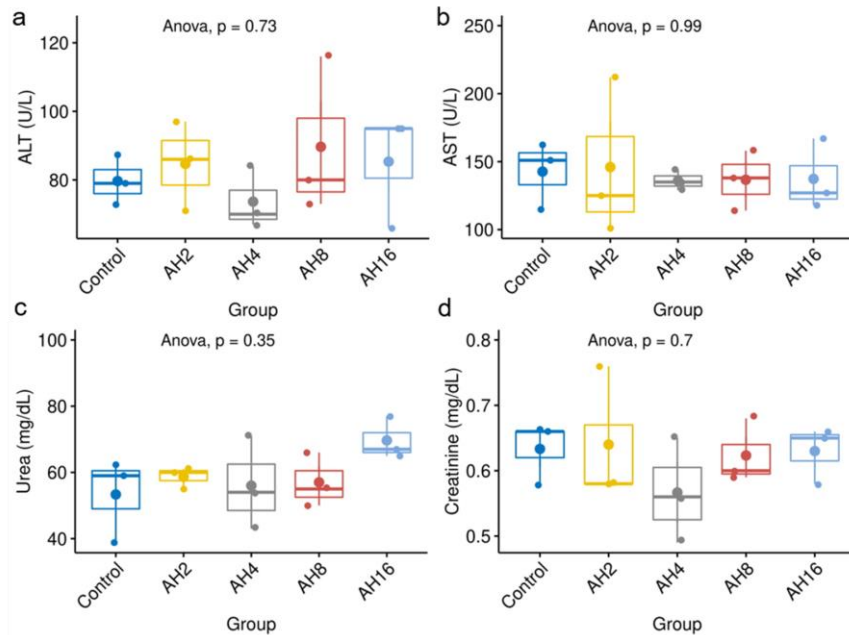
The photomicrograph of the liver is shown in Figure 3a. The cytoplasmic intensity of the liver section significantly decreased at all doses of treatment groups compared with that of the control group (Figure 3b). A present study indicated that the *A. hispida* leaf extract increased cytoplasmic eosinophilia of liver in HE

**Table 2.** The percentage of clinical signs of toxic in female rats after the administration of *A. hispida* leaf extract

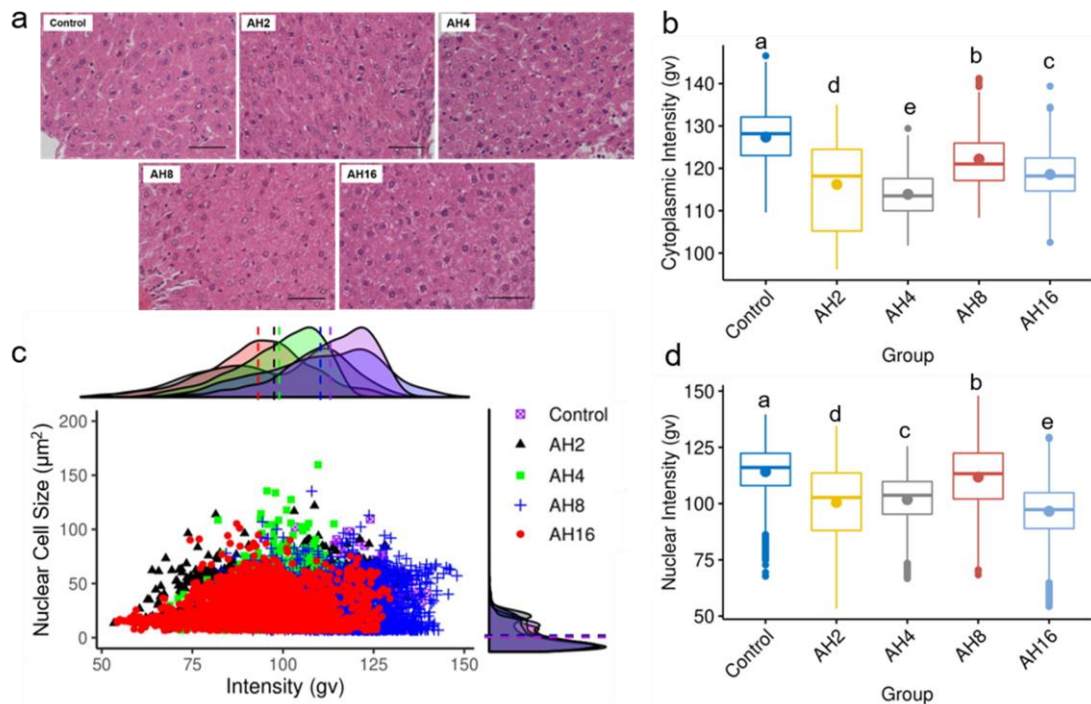
Parameter	Control (%)	AH2 (%)	AH4 (%)	AH8 (%)	AH16 (%)
No fear and normal behavior	100	100	100	100	100
Normal skin and fur	100	100	100	100	100
Regular respiratory	100	100	100	100	100
Normal eyes	100	100	100	100	100
Normal feces	100	100	100	100	100
No tremors	100	100	100	100	100
No convulsions	100	100	100	100	100
No salivation	100	100	100	100	100
No paralysis	100	100	100	100	100



**Figure 1.** The body weight of female rats after *A. hispida* leaves extract administration in acute toxicity assay for 14 days



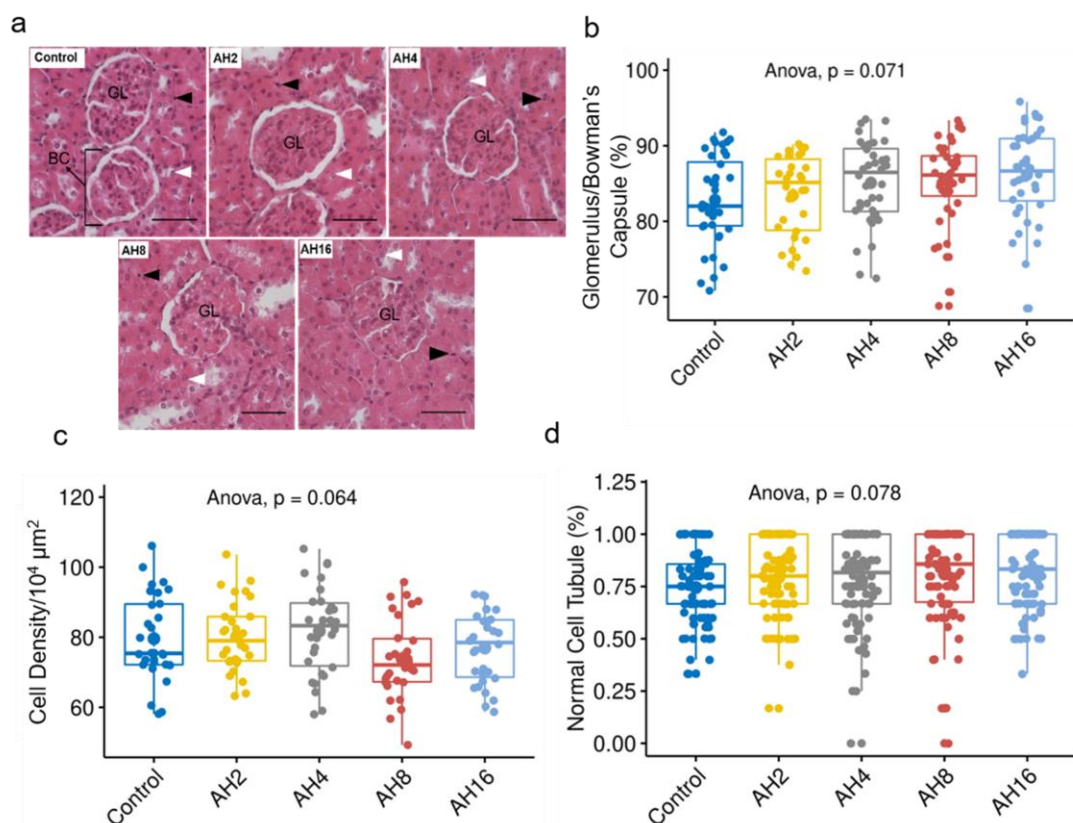
**Figure 2.** The profile of blood biochemistry of rats treated by *A. hispida* leaf extract. a= The level of ALT, b= AST, c= Urea, and d= Creatinine, AH2= 2 g/kg BW, AH4= 4 g/kg BW, AH8= 8 g/kg BW, AH16= 16 g/kg BW



**Figure 3.** Histological analysis of the rat's liver tissues after *A. hispida* leaf extract administration. a= Photomicrograph of the liver (bar= 50 µm). b= The cytoplasmic intensity of the hepatocyte significantly decreased at all doses compared with that of control. c= A scatterplot of nuclear cell size and intensity of the liver. The dots by shape and color were the distribution of the cell by size and intensity. Nuclear cell size was the same between the control and treatment groups (dash line on the right of scatterplot); however, the nuclear intensity of all groups was significantly lower than that of the control group (dash line on the top of scatterplot). d= The nuclear intensity of the treatment groups significantly decreased compared with that of the control group. AH2= 2 g/kg BW, AH4= 4 g/kg BW, AH8= 8 g/kg BW, AH16= 16 g/kg BW

stains. This condition may be caused by the loss of cytoplasmic ribose nucleic acid (RNA), which binds to the bluish-black dye (hematoxylin). Moreover, the denatured cytoplasmic protein led to the eosinophilic cytoplasm, which binds to the red-pink dye (eosin). The lack of RNA cytoplasm and denatured cytoplasmic was characterized as ongoing apoptosis and necrosis (Fujita and Nagashima, 2002).

The distribution of nuclear cell size and nuclear intensity of liver tissue was displayed in a scatterplot graph (Figure 3c). The dashed line overlapping on the right of scatterplot at all groups implied the same nuclear cell size, relatively. Nonetheless, the nuclear intensity of the liver tissue significantly decreased at all treatment groups (Figure 3d). The present study exhibited that the ethanolic extract of *A. hispida* leaves



**Figure 4.** Histological analysis of the rat's kidney treated by *A. hispida* leaf extract. a= Photomicrograph of the kidney (bar= 50  $\mu\text{m}$ ), b= The treatments did not change the ratio of glomerulus per bowman's capsule (%), c= There is no significant change in the cell density per  $10^4 \mu\text{m}^2$  of the glomerulus, d= The percentage of normal cell tubule did not significantly increase at all the treatment groups, GL= Glomerulus, BC= Bowman's capsule, Black arrowhead= Nuclei pyknosis, White arrowhead= Normal cell, AH2= 2 g/kg BW, AH4= 4 g/kg BW, AH8= 8 g/kg BW, AH16= 16 g/kg BW

increased basophilic nuclei of the liver in HE stain. The basophilic nuclei indicated the presence of chromatin condensation (pyknosis), early-stage apoptotic nuclei (Stillwell, 2016; Ali *et al.*, 2018). The apoptosis is the programmed cell death due to increased mitochondrial injury or dysfunction (Karch and Molkentin, 2015). Mitochondrial injury and dysfunction lead to the inability to generate ATP (Campbell and Mahad, 2018). Thus, the increasing basophilic nuclei and eosinophilic cytoplasm of the liver in HE stain were early-stage apoptotic cells.

The photomicrograph of the kidney section was demonstrated in Figure 4a. The administration of *A. hispida* leaf extract did not change the ratio of the glomerulus and Bowman's capsule (G/B ratio), statistically (Figure 4b). In addition, the cell density of glomerulus did not significantly decrease, compared with the control group (Figure 4c). The *A. hispida* extract increased the proportion of normal cell tubule at all doses, but it was not significantly different (Figure 4d). The result demonstrated that the ethanolic extract of *A. hispida* leaves did not affect the G/B ratio, glomerular cell density, and the proportion of normal cell tubule.

Physiologically, glomerulus produces primary urine through glomerular capillary filtration. The glomerulus density change can disturb glomerular filtration, which maintained by ultrafiltration such as plasma osmotic pressure, glomerular capillary pressure, and Bowman's

capsule pressure (Kriz *et al.*, 1995; Scott and Quaggin, 2015). The chronic of glomerular filtration can be characterized in enlargement of glomerular tuft volume and glomerular diameter (Kriz *et al.*, 1995; Sasaki *et al.*, 2018). The change of glomerular cell density did not increase glomerular diameter, which represented by the absence of a changing G/B ratio. On the other hand, increasing normal cell proportion in tubule showed proper regeneration.

The photomicrograph of the kidney section was demonstrated in Figure 4a. The administration of *A. hispida* leaf extract did not change the ratio of the glomerulus and Bowman's capsule (G/B ratio), statistically (Figure 4b). In addition, the cell density of glomerulus did not significantly decrease, compared with the control group (Figure 4c). The *A. hispida* extract increased the proportion of normal cell tubule at all doses, but it was not significantly different (Figure 4d). The result demonstrated that the ethanolic extract of *A. hispida* leaves did not affect the G/B ratio, glomerular cell density, and the proportion of normal cell tubule.

## CONCLUSION

The ethanolic extract of *A. hispida* leaves is relatively harmless with  $\text{LD}_{50} > 16 \text{ g/kg BW}$ . There is no significant change in body weight, clinical signs of toxicity, and blood biochemistry. Histological

examination shows that *A. hispida* extract significantly affects the liver, but it does not affect the kidney. These results suggest that the ethanolic extract of *A. hispida* leaves safe in low doses (<2 g/kg BW).

## REFERENCES

- Ali, D.M., O.A. Hassan, M.M. Ramzy, and N.N. Zenhom. 2018. Estimation of postmortem interval from mRNA degradation and autolytic changes in the brain and adrenal gland. **Mansoura J. Foren. Med. Clin. Toxicol.** 26(2):125-142.
- Bokshi, B., M.A.S. Sayeed, M.I. Ahmed, U.K. Karmakar, and S.K. Sadhu. 2012. Assessment of antimicrobial and cytotoxic activities of ethanolic extract of leaves of *Acalypha hispida*. **Int. J. Pharm. Sci. Res.** 3(6):1705-1708.
- BPOM. Badan Pengawas Obat dan Makanan Republik Indonesia. 2014. **Pedoman Uji Toksisitas Nonklinis Secara In Vivo**. Edisi ke-7. BPOM, Indonesia.
- Campbell, G. and D.J. Mahad. 2018. Mitochondrial dysfunction and axon degeneration in progressive multiple sclerosis. **FEBS Letters.** 592(7):1113-1121.
- Dey, P. 2018. Haematoxylin and Eosin Stain of the Tissue Section. In **Basic and Advanced Laboratory Techniques in Histopathology and Cytology**. Springer, Singapore.
- Dukes, H. 2015. **Dukes's Physiology of Domestic Animals**. 13<sup>th</sup> ed. Wiley Blackwell, US.
- Ejechi, B.O. and J.A. Souzey. 1999. Inhibition of biodeterioration of yam tuber *Dioscorea rotundata* Poir in storage with phenolic extract of *Acalypha hispida* Burm.f. leaves. **J. Stored. Prod. Res.** 35(2):127-134.
- Fujita, M. and K. Nagashima. 2002. Immunohistochemical detection of hepatocellular radiofrequency ablation. **Modern Pathol.** 15(2):2-7.
- Han, C.J., A.H. Hussin, and S. Ismail. 2008. Toxicity study of orthosiphon stamineus benth (misai kucing) on Sprague Dawley rats. **Trop. Biomed.** 25(1):9-16.
- Hodge, H.C., and J.H. Sterner. 1949. Tabulation of toxicity classes. **Am. Ind. Hyg. Assoc. Q.** 10(4):93-96.
- Iniaghe, O., O. Malomo, and J. Adebayo. 2009. Proximate composition and phytochemical constituents of leaves of some acalypha species. **Pak. J. Nutr.** 8(3):256-258.
- Kanife, U.C., O.S. Odesanmi, A.A. Adekunle, and V.F. Doherty. 2012. Effects of ethanol extracts of healthy and infected *Panicum maximum* (Jacq.) Floret on liver and kidney function profile and histopathology in Sprague-Dawley rats. **Res. J. Recent. Sci.** 1(5):8-13.
- Karch, J. and J.D. Molkenin. 2015. Regulated necrotic cell death: The passive aggressive side of bax and bak. **Circulation Res.** 116(11):1800-1809.
- Kiernan, J.A. 2008. **Histological and Histochemical Methods**. 5<sup>th</sup> ed. Scion Publishing, Banbury.
- Kim, K.J., O.H. Lee, H.H. Lee, and B.Y. Lee. 2010. A 4-week repeated oral dose toxicity study of fucoidan from the sporophyll of *Undaria pinnatifida* in Sprague-Dawley rats. **Toxicology.** 267(1-3):154-158.
- Kriz, W., M. Elger, P. Mundel, and K.V Lemley. 1995. Structure-stabilizing forces in the glomerular tuft. **J. Am. Soc. Nephrol.** 5(10):1731-1739.
- Manikanta, K.B., P.R Varma, P.V. Krishna, A.R. Kumar, and K.S. Rathinam. 2014. Toxicity studies of combined extracts of *Acalypha hispida*, *Acalypha nervosa*, *Acalypha fruticosa*. **Indian J. Res. Pharm. Biotechnol.** 7(3):200-201.
- OECD. Organisation for Economic Co-operation and Development. 2001. Test No 423. Acute Oral Toxicity. [https://ntp.niehs.nih.gov/icevram/suppdocs/fedddocs/oced/oced\\_gl423.pdf](https://ntp.niehs.nih.gov/icevram/suppdocs/fedddocs/oced/oced_gl423.pdf).
- Okorondu, S., T. Sokari, M. Okorondu, and E. Chinakwe. 2014. Phytochemical and antibacterial properties of *Acalypha hispida* leaves. **Int. J. Nat. Appl. Sci.** 5(2):191-194.
- Sasaki, T., N. Tsuboi, K. Haruhara, Y. Okabayashi, G. Kanzaki, K. Koike, A. Kobayashi, I. Yamamoto, M. Ogura, and T. Yokoo. 2018. Bowman capsule volume and related factors in adults with normal renal function. **Kidney. Int. Rep.** 3(2):314-320.
- Scott, R.P. and S.E. Quaggin. 2015. The cell biology of renal filtration. **J. Cell. Biol.** 209(2):199-210.
- Seebaluck, R., A. Gurib-Fakim, and F. Mahomoodally. 2015. Medicinal plants from the genus *Acalypha* (Euphorbiaceae)-A review of their ethnopharmacology and phytochemistry. **J. Ethnopharmacol.** 159:137-157.
- Siraj, M.A., J.A. Shilpi, M.G. Hossain, S.J. Uddin, M.K. Islam, I.A. Jahan, and H. Hossain. 2016. Anti-inflammatory and antioxidant activity of *Acalypha hispida* leaf and analysis of its major bioactive polyphenols by HPLC. **Adv. Pharm. Bull.** 6(2):275-283.
- Stillwell, W. 2016. **An Introduction to Biological Membranes**. 2<sup>nd</sup> ed. Elsevier Science, Cambridge.
- Widmaier, E.P., H. Raff, and K.T. Strang. 2015. **Vander's Human Physiology The Mechanisms of Body Function**. 18<sup>th</sup> ed. McGraw-Hill Hinger Education.