

# THE POTENTIAL OF TOMATO EXTRACT (*Lycopersicon esculentum* L.) IN INCREASING THE SERTOLI CELLS AND SPERMATOGENIC CELLS COUNT OF THE CONTRALATERAL TESTICULAR SEMINIFEROUS TUBULES OF RATS (*Rattus norvegicus*) THAT HAVE TESTICULAR TORSION

Dasrul<sup>1\*</sup>, Cut Nila Thasmi<sup>1</sup>, Triva Murtina Lubis<sup>2</sup>, Awaluddin<sup>3</sup>, Winaruddin<sup>4</sup>, Rosmaidar<sup>5</sup>, and Yola Alifa<sup>6</sup>

<sup>1</sup>Reproduction Laboratory, Faculty of Veterinary Medicine, Universitas Syiah Kuala, Banda Aceh, Indonesia

<sup>2</sup>Physiology Laboratory, Faculty of Veterinary Medicine, Universitas Syiah Kuala, Banda Aceh, Indonesia

<sup>3</sup>Patology Laboratory, Faculty of Veterinary Medicine, Universitas Syiah Kuala, Banda Aceh, Indonesia

<sup>4</sup>Parasitology Laboratory, Faculty of Veterinary Medicine, Universitas Syiah Kuala, Banda Aceh, Indonesia

<sup>5</sup>Pharmacology Laboratory, Faculty of Veterinary Medicine, Universitas Syiah Kuala, Banda Aceh, Indonesia

<sup>6</sup>Study Program Veterinary Medicine, Faculty of Veterinary Medicine Universitas Syiah Kuala, Banda Aceh, Indonesia

\*Corresponding author: [dasrul.darni@yahoo.com](mailto:dasrul.darni@yahoo.com)

## ABSTRACT

The purpose of this study was to analyze the potential of tomato extract (*Lycopersicon esculentum* L.) in increasing the Sertoli and spermatogenic cells count of the contralateral testis in white rats (*Rattus norvegicus*) with unilateral torsion. A total of 24 male Wistar white rats, aged 3-4 months old with a weight of 180-200 g were used in this study. The rat samples were randomly divided into 4 treatment groups: Group 1 as a negative control (NC) which consisted of rats without testicular torsion and given tomato extract; Group 2 as a positive control (PC) which consisted of rats with unilateral testicular torsion 720° for 6 hours without given tomato extract; Group 3 as treatment 1 (T1) consisted of rats that were subjected to unilateral testicular torsion 720° for 6 hours and were given tomato extract at a dose of 100 mg/kg BW/day; and Group 4 as treatment 2 (T2) consisted of rats that were subjected to unilateral testicular torsion 720° for 6 hours and were given tomato extract at a dose of 200 mg/kg BW/day. Each group consisted of six rats. Tomato extract was administered orally for 30 days. The observations of the number of Sertoli cells and spermatogenic cells (spermatogonia cells, spermatocytes, and spermatids) were carried out histologically with Hematoxylin-Eosin (HE) staining and the slides were examined with a light microscope. The data obtained was analyzed by ANOVA and continued with Duncan's test. The results showed that the administration of tomato extract significantly increased ( $P < 0.05$ ) the number of Sertoli cells and spermatogenic cells of the contralateral testicular seminiferous tubule. Giving tomato extract 100 mg/kg BW/day resulted in an increase in the number of Sertoli cells and better spermatogenic cells than tomato extract 200 mg/kg BW/day. In conclusion the administration of tomato extract after detorsion can increase the number of Sertoli cells and spermatogenic cells of the contralateral testicular seminiferous tubules in white rats subjected to unilateral torsion of 720° for 6 hours.

Key words: Sertoli cells, spermatogenic testicular contralateral cells, unilateral testicular torsion, white rats

## ABSTRAK

Penelitian ini bertujuan mengetahui potensi ekstrak tomat (*Lycopersicon esculentum* L.) untuk meningkatkan jumlah sel Sertoli dan spermatogenik testis kontralateral pada tikus putih (*Rattus norvegicus*) yang mengalami torsio unilateral. Sebanyak 24 ekor tikus putih strain Wistar berjenis kelamin jantan, usia 3-4 bulan dengan bobot 180-200 g digunakan dalam penelitian ini. Sampel tikus dibagi secara acak menjadi 4 kelompok perlakuan yakni kelompok 1 sebagai kontrol negatif (KN), tikus normal tanpa dilakukan torsio testis; kelompok 2 sebagai kontrol positif (KP) tikus dilakukan torsio testis unilateral 720° selama 6 jam setelah detorsi tanpa diberi ekstrak tomat; kelompok 3 sebagai perlakuan 1 (P1) tikus dilakukan torsio testis unilateral 720° selama 6 jam setelah detorsi diberi ekstrak tomat 100 mg/kg bobot badan/hari dan kelompok 4 sebagai perlakuan 2 (P2) tikus dilakukan torsio testis unilateral 720° selama 6 jam setelah detorsi diberi ekstrak tomat 200 mg/kg bobot badan/hari. Masing-masing kelompok terdiri atas enam ekor tikus. Pemberian ekstrak tomat dilakukan secara oral selama 30 hari. Pengamatan jumlah sel Sertoli dan sel-sel spermatogenik (sel spermatogonia, spermatosit dan spermatid) dilakukan secara histologis dengan pewarnaan Hematoksilin-Eosin (HE) dan slide diperiksa dengan mikroskop cahaya. Data yang diperoleh dianalisis dengan ANOVA dan dilanjutkan dengan uji Duncan. Hasil penelitian menunjukkan pemberian ekstrak tomat dapat meningkatkan secara nyata ( $P < 0,05$ ) jumlah sel Sertoli dan sel spermatogenik tubulus seminiferus testis kontralateral. Pemberian ekstrak tomat 100 mg/kg bobot badan/hari menghasilkan peningkatan jumlah sel Sertoli dan sel spermatogenik lebih baik dibandingkan dengan ekstrak tomat 200 mg/kg bobot badan/hari. Disimpulkan bahwa pemberian ekstrak tomat setelah detorsi dapat meningkatkan jumlah sel Sertoli dan sel spermatogenik tubulus seminiferus testis kontralateral pada tikus putih yang mengalami torsio unilateral 720° selama 6 jam.

Kata kunci: sel Sertoli, sel spermatogenik testis kontralateral, torsio testis unilateral, tikus putih

## INTRODUCTION

Testicular torsion is one of the most common medical cases seen in veterinary practices. It is especially common in horses (De Bock *et al.*, 2007), cats (Giuliano, 2013), and dogs (Viliotti *et al.*, 2018). Testicular torsion is an important condition for a veterinarian to understand because it is so often encountered. Testicular torsion is the twisting of the spermatic cord which results in strangulation of the blood vessels which leads to ischemia in the testes (Viguera *et al.*, 2004; Karaguzel *et al.*, 2014). About

50% of cases of testicular torsion are the result of trauma (Visser and Heyns, 2003). Testicular torsion can occur at any age, but most often occurs at a young age when a rapid increase in testicular mass occurs due to the maturation of the reproductive organs and the process of spermatozoa maturation (Yang *et al.*, 2011; Boettcher *et al.*, 2012).

Testicular torsion can have negative impacts on the testes and the surrounding tissue. These impacts can include but are not limited to: disruption of the spermatogenesis process, decreased quality of spermatozoa, and histopathological changes in the

tissues around the testes, especially the seminiferous tubules and interstitial tissue (Mohammad *et al.*, 2012). From these negative impacts, testicular torsion can result in damage to the testes and subfertility (Vigueras *et al.*, 2004). In addition to having an impact on the testicle affected by the torsion, it can also affect the contralateral testicle (Sukhotnik *et al.*, 2005; Yildiz *et al.*, 2011). Experimental studies in animals have shown that torsion in the contralateral testis can cause Leydig cell atrophy, physiological changes in Sertoli cells, a decreased sperm count, and rapid apoptotic processes in the germinal epithelium (Lorenzini *et al.*, 2004; Vigueras *et al.*, 2004; Mohammad *et al.*, 2012). Other reports have also found degeneration, desquamation and disorganization of the germinal epithelium and edema of the interstitial tissue and a decrease in the diameter of the seminiferous tubules of the contralateral testis (Özkan *et al.*, 2000).

Many theories state that contralateral testicular damage due to unilateral testicular torsion can be triggered by various mechanisms, including various auto-immune processes (Lorenzini *et al.*, 2012), reflex vasoconstriction in the contralateral testicular blood vessels (Filho *et al.*, 2004), and an increased production of reactive oxygen species (ROS) which are released after the reperfusion process (Gnimaraes *et al.*, 2007; Dokmeci, 2012). Increased production of ROS can cause damage to lipids, proteins and deoxyribonucleic acid (DNA) cells, which in turn causes necrosis or apoptosis of testicular germ cells (Filho *et al.*, 2004; Mogilner *et al.*, 2006; Gnimaraes *et al.*, 2007). Various studies have been conducted to try and learn how to avoid testicular tissue damage after testicular torsion and reperfusion has occurred. These studies included the provision of antioxidants such as vitamin E (Ranade *et al.*, 2011), vitamin C (Ranade *et al.*, 2018), and the use of antioxidant compounds derived from herbal plants (Afamefuna *et al.*, 2012; Motamedi *et al.*, 2019; Masoumeh *et al.*, 2020) to treat testicular torsion.

Tomato (*Lycopersicon esculentum* L.) is a vegetable that contains many antioxidants such as vitamin E, vitamin C, lycopene, and  $\beta$ -carotene, solanine alkaloids, saponins, tannins, folic acid, citric acid, and bioflavonoids, which are all beneficial for health (Davies, 2000; Kailaku, 2007; Pinella *et al.*, 2016). Apart from being a source of food, tomatoes are also widely used to treat several diseases including: hypertension (Sabilu *et al.*, 2017), inflammation (Hernayanti *et al.*, 2017), cancer, especially prostate cancer (Campbell *et al.*, 2004), hypercholesterolemia (Basuny *et al.*, 2009) and infertility (Anas and Asterina, 2011; Dasrul *et al.*, 2013; Yamamoto *et al.*, 2017). Administering tomato extract at 40-80 mg/kg BW/day for 4 weeks has been shown to improve the sperm quality of hypercholesterolemic rats (Dasrul *et al.*, 2013). Although there have been many studies that have shown the efficacy of tomatoes, both for infertility due to increased ROS by cigarette smoke and hypercholesterolemia, research on the use of tomato extract as a therapeutic agent to increase the number of Sertoli cells and spermatogenic cells (spermatogenic

cells, spermatocytes and spermatids) in the seminiferous tubules of the testes contralateral to testicular torsion has not been reported.

## RESEARCH METHODS

This study was an experimental study of the post test only control group design using a one-way completely randomized design (CRD) with 4 treatment groups. A total of 24 white rats (*Rattus norvegicus*) Wistar strain male, healthy, and with a weight of 180-200 g were randomly divided into 4 treatment groups. Group 1 was classified as a negative control (NC) and consisted of rats without testicular torsion and were given tomato extract. Group 2 was classified as a positive control (PC) which consisted of rats with unilateral testicular torsion 720° for 6 hours without given tomato extract. Group 3 was classified as treatment 1 (T1) and consisted of rats that were subjected to unilateral testicular torsion 720° for 6 hours and were given tomato extract at a dose of 100 mg/kg BW/day. Lastly, group 4 was classified as treatment 2 (T2) and consisted of rats that were subjected to unilateral testicular torsion 720° for 6 hours and were given tomato extract at a dose of 200 mg/kg BW/day. Each treatment group consisted of 6 white rats.

### Experimental Animal Preparation and Adaptation

Prior to treatment, all experimental rats were adapted for seven days by being fed 20 g/head pellets and provided with drinking water *ad libitum*. The rats were placed in individual cages which had been specially designed with plywood and wire mesh walls and equipped with drinking water and feed containers. During preparation the cages were maintained under standard room conditions at a constant temperature (25-27° C) and 30-70% humidity with 12 hours light and 12 hours dark.

### Tomato Extract Production

A total of 1000 g of ripe apple tomatoes were washed and blanched (or soaked) in 100 mL of hot water at 82-93° C for 5-10 minutes. Furthermore, the tomatoes were processed in a blender for 15 minutes and then transferred to a beaker and stored in an incubator at 40-50° C for 8-10 hours for drying. Tomato coarse flour was then extracted by the maceration method with 90% ethanol solvent at room temperature with a ratio of tomato flour to solvent of 1:5 for 3 x 24 hours with continuous stirring. The filtrate was then taken and concentrated with a rotary evaporator at 60° C for 3 hours. The viscous extract obtained was packaged in a vacuum sterile tube and stored at 5° C.

### Induction of Testicular Torsion and Administration of Tomato Extract

Induction of testicular torsion was carried out according to the model of testicular torsion rats developed by Ranade *et al.* (2011) and Bo *et al.* (2020). After the grouping, rats in the NC group underwent

sham/placebo surgery, while those in the PC, T1, and T2 groups were anesthetized with a ketamine injection (Ilium, NSW, 100 mg ketamine/mL) at a dose of 10 mg/kg BW and xylazine (Ilium, NSW, 20 mg xylazine/mL) dose of 2 mg/kg BW. After the experimental animals were anesthetized, a 1 cm incision was made in the lower-left scrotum to look for the testes. Once found, the testes were separated by fascia to the head of the epididymis and the gubernaculum testis was tied and cut. The left testicle was rotated 720° clockwise and fixed, then the incision was sutured and the torsion was left for 6 hours. After 6 hours, anesthesia was performed and the scrotum was re-incised and the testicle was repositioned 720° in the opposite direction of torsion (testicular torsion) and fixed. Once this procedure was complete, the incision wound was closed again using absorbable sutures. Tomato extract was administered over the course of 30 days orally using a gastric probe with a volume of 1.0 mL/head. On the 31<sup>st</sup> day, an incision was made again and the contralateral testis was taken, weighed and observed for color changes. Furthermore, the testes were fixed with 10% neutral buffered formalin (NBF) solution at room temperature in order to make histological preparations.

### Histological Preparation

The contralateral testes of experimental animals that had been treated in the form of torsion were observed according to time. A series of stages were used to make preparations by following the Hematoxylin and Eosin (HE) staining process. In making histology preparations, the first step was fixation. At this stage, the testicles that had been cut to the size of 0.5 cm were placed on a glass film and then immersed in a formalin solution for 24 hours. This was proceeded with the second step of dehydration. At this stage, the testicle pieces were immersed in an 80% alcohol solution for 2 hours, then soaked again in alcohol with a concentration of 90%, 95%, 100% I, and 100% II respectively for another 2 hours. The third stage was called clearing, which consisted of soaking the samples in xylol solution 3 times for 30 minutes each in a different bottle. Subsequently, the infiltration process was carried out in an incubator at a temperature of 56-58° C. The testicles were then immersed in paraffin 3 times for 30 minutes each, followed by embedding, which is dipping the testicle pieces in liquid paraffin that has been poured into a basket. Next, the container was put in water and then placed in a refrigerator. After a time, the paraffin solidified and the testicles were incised in a paraffin block.

The testes in paraffin blocks were attached to a microtome plate. The desired slice thickness was 2-4 µm. Slices were taken with tweezers and placed in warm water (38-40° C) to straighten out any fine wrinkles and to unfold any wedges or creases that might occur on the slides. Perfectly stretched slices were then taken with an object-glass. The selected pieces were then air-dried until they became fully dry. The preparations were then stained with HE which consisted of several steps using

various solutions such as xylol, graded alcohol, running water, and finally Canadian balm was added to make the preparations firmly attach to the slide and cover. Then the preparations were observed under a microscope and DP 12 micrographs were taken using a scale of 20 µm and 30 µm.

### Sertoli Cell Count and Spermatogenic Cell Count

Measurement of the number of Sertoli cells and spermatogenic cells (spermatogenic cells, spermatocytes, and spermatids) was carried out on a 400x magnification light microscope (Nikon E200) equipped with Optilab Viewer Software Version 2.2. The number of spermatogenic cells and Sertoli cells was counted in the seminiferous tubules. Calculations were carried out on 5 cross sections (vertical) of the testes which were divided into 4 sections (top right, bottom right, top left, bottom left). Each section was taken from 5 tubules and then the number of Sertoli cells and spermatogenic cells (spermatogenic cells, spermatocytes, and spermatids) were counted. Observations were made randomly with five replications to average the value of these variables.

### Data Analysis

Observational data on the number of Sertoli cells and spermatogenic cells (spermatogenic cells, spermatocytes, and spermatids) of the seminiferous tubules were analyzed using one-way analysis of variance (ANOVA) to determine whether or not there were differences in the treatment groups.

## RESULTS AND DISCUSSION

From the results of phytochemical testing, it can be seen that the tomato extract used in this study contained alkaloids, saponins, flavonoids, phenolics and tannins, while steroids and triterpenoids were not found in the tomato extract (Table 1). These results are in line with the results of phytochemical tests conducted by Agustina *et al.* (2017), that tomatoes contain terpenoid compounds, flavonoids, saponins, tannins, and polyphenols.

### Histological Images of the Seminiferous Tubules of the Testes

From the observation of histopathological images of the contralateral testicular seminiferous tubule (Figure 1) in the NC group, the stages of development and arrangement of spermatogenic cells towards the tubular lumen were clear and dense. The seminiferous tubules were completely filled with components of spermatogenic cells and Sertoli cells which were located according to their respective positions. Spermatogonia cells were seen to be located on the basement membrane of the seminiferous tubules, primary spermatocyte cells were located in the middle space of the seminiferous tubules, and spermatid cells themselves were seen to fill some of the adluminal space and also the tubular lumen. This showed that the process of spermatogenesis was running normally.

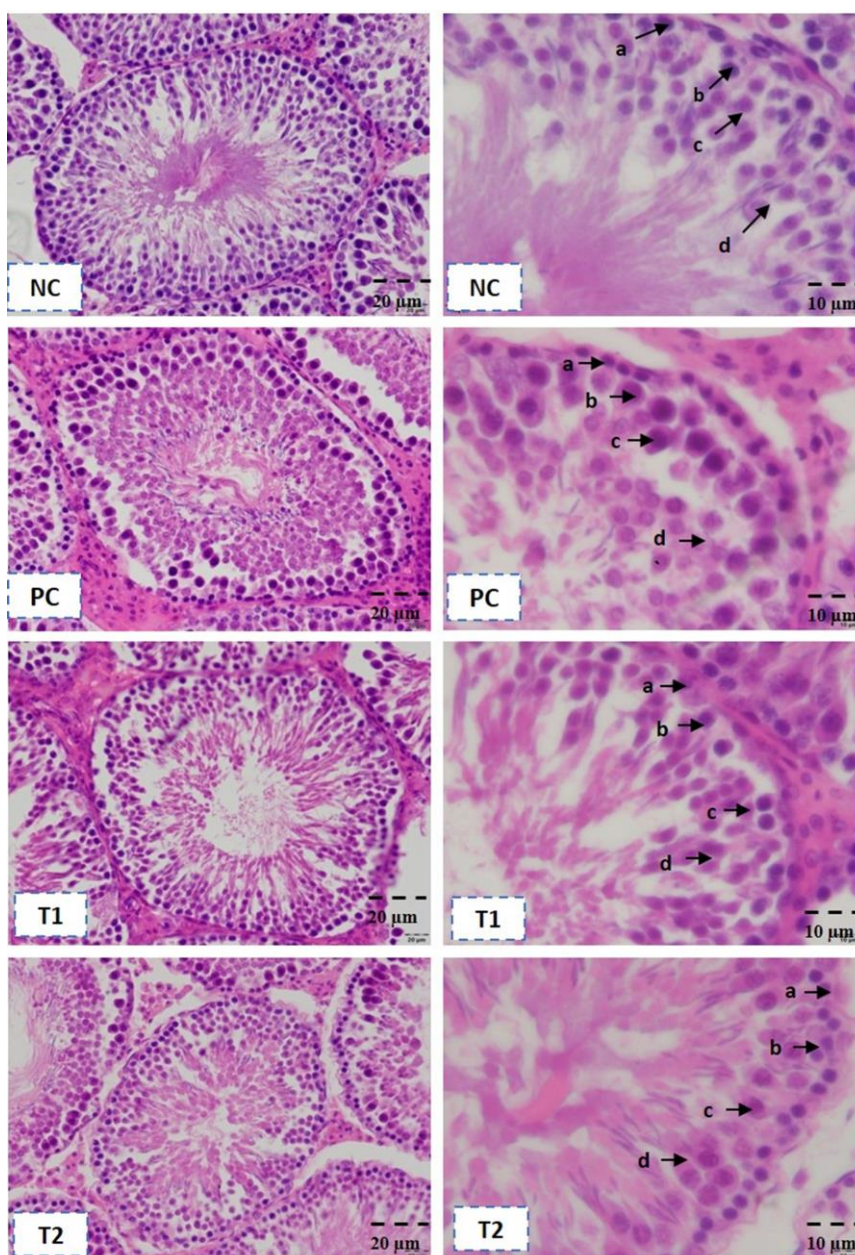
In the PC group, unilateral testicular torsion was performed at 720° for 6 hours. The presence of spermatogenic cells was very rare, and only a small

number of cells were observed loosely spread about. The seminiferous tubule lumen itself was completely empty. The loose arrangement of cells and damage to

**Table 1.** Phytochemical test results of tomato (*Lycopersicon esculentum* L.) extract

Metabolite content	Reagent	Test results	Observation results
Alkaloids	Mayer	+	White precipitate formed
	Waner	+	Brown precipitate formed
	Dragendorff	+	Red precipitate formed
Steroids	Liebermann-Burchard test	-	No bluish color formed
Triterpenoids	Liebermann-Burchard test	-	No red color formed
Saponins	Shaking	+	Foaming
Flavonoids	HCl and Metal Mg	+	Reddish color formed
Phenolic	FeCl <sub>3</sub>	+	Bluish black color formed
Tannins	FeCl <sub>3</sub>	+	Bluish black color formed

(+)= Showing positive results, (-)= Showing negative results



**Figure 1.** Histopathology of contralateral testicular seminiferous tubules in white rats in various treatment groups. a= Spermatogonia; b= Spermatocytes; c= Spermatids; d= Sertoli; NC= Normal white rats without torsion, PC= White rats that underwent unilateral testicular torsion for 6 hours; T1= White rats that underwent unilateral testicular torsion for 6 hours and were given a dose of tomato extract 100 mg/kg BW/day; and T2= White rats that underwent unilateral testicular torsion for 6 hours and were given 200 mg/kg BW/day. HE 100x (left) and 400x (right)

**Table 2.** The mean ( $\pm$ SD) number of Sertoli cells and spermatogenic cells per seminiferous tubule of the contralateral testis of white rats (*Rattus norvegicus*) in various treatment groups

Treatment	Sertoli cell count	Spermatogenic cell count		
		Spermatogonia	Spermatocytes	Spermatids
NC	84.83 $\pm$ 5.04 <sup>a</sup>	124.50 $\pm$ 19.37 <sup>a</sup>	210.17 $\pm$ 34.63 <sup>a</sup>	350.17 $\pm$ 61.21 <sup>a</sup>
PC	65.17 $\pm$ 6.27 <sup>c</sup>	102.33 $\pm$ 5.57 <sup>c</sup>	156.50 $\pm$ 25.56 <sup>c</sup>	286.83 $\pm$ 31.72 <sup>c</sup>
T1	82.83 $\pm$ 4.22 <sup>ab</sup>	120.50 $\pm$ 8.41 <sup>a</sup>	209.83 $\pm$ 19.73 <sup>a</sup>	335.67 $\pm$ 60.41 <sup>a</sup>
T2	75.67 $\pm$ 3.50 <sup>b</sup>	112.67 $\pm$ 7.37 <sup>b</sup>	194.17 $\pm$ 13.45 <sup>b</sup>	315.83 $\pm$ 20.83 <sup>b</sup>

<sup>a, ab, b, c</sup>Different superscripts within the same column indicated significant differences ( $P < 0.05$ ). NC= Normal white rats without testicular torsion; PC= White rats that underwent unilateral testicular torsion 720° for 6 hours without administration of tomato extract; T1= White rats that underwent unilateral testicular torsion 720° for 6 hours and were given tomato extract 100 mg/kg BW/day; and T2= White rats underwent unilateral testicular torsion 720° for 6 hours and were given tomato extract 200 mg/kg BW/day

the seminiferous tubule cell structure of the testes in the PC group was caused by the disruption of the spermatogenesis stages in the testes. Meanwhile, in the T1 treatment group, white rats that underwent unilateral testicular torsion 720° for 6 hours and were given a dose of tomato extract 100 mg/kg BW/day, the arrangement of the seminiferous tubules was almost the same as the NC group and different from the seminiferous tubules which were found in the PC group. The arrangement of spermatogenic cells was denser and densely filled with spermatogenic cells with a clearly visible structure lined up towards the lumen. In the T2 treatment group, white rats that underwent unilateral testicular torsion for 6 hours and were given 200 mg/kg BW/day, the spermatogenic cells were not much different from T1.

#### Sertoli Cell Count and Spermatogenic Cell Count of the Seminiferous Tubules

The results of the calculation of the number of Sertoli cells and spermatogenic cells (spermatogonia cells, primary spermatocytes, round spermatid cells) per seminiferous tubule (Table 1), showed that unilateral testicular torsion treatment of 720° for 6 hours caused a significant decrease in the number of Sertoli cells and spermatogenic cells (spermatogonia cells, spermatocytes, and spermatids) ( $P < 0.05$ ). In treatment T1 and T2 there was a recovery effect, because the number of Sertoli cells, spermatogonia cells, spermatocytes and spermatid cells of the two treatments were significantly different ( $P < 0.05$ ) with the positive control group (PC). Even in treatment T1 the number of Sertoli cells, spermatogonia, spermatocytes and spermatids were not significantly different from the control ( $P > 0.05$ ).

The mean number of Sertoli cells in the contralateral seminiferous tubules of the PC group was significantly different ( $P < 0.05$ ) compared to T1, T2 and NC. The number of Sertoli tubular seminiferous cells in group T1 was significantly different ( $P < 0.05$ ) with NC, but not different ( $P > 0.05$ ) with T2, while the number of Sertoli tubular seminiferous cells in group T2 was not different ( $P > 0.05$ ) compared to NC. These results proved that unilateral testicular torsion of 720° for 6 hours was able to reduce the number of Sertoli cells in the contralateral seminiferous tubules. While the administration of tomato extracts 100 mg/kg BW/day and 200 mg/kg BW/day (T2), was able to increase the number of Sertoli cells in the contralateral testicular seminiferous tubule in rats with a unilateral testicular torsion of 720° for 6 hours.

The mean number of seminiferous tubular spermatogonia cells in the PC group was not significantly different ( $P > 0.05$ ) with T1, but both were significantly different ( $P < 0.05$ ) with NC and T2. The number of spermatogenic tubules in the seminiferous tubules in T2 was not significantly different ( $P > 0.05$ ) with NC, while the number of spermatocytes and spermatids in the seminiferous tubules in the PC group was significantly different ( $P < 0.05$ ) with T1, T2 and NC. The number of spermatocytes and spermatids in the seminiferous tubules in T1 was significantly different from T2 and NC ( $P < 0.05$ ). However, the number of spermatocytes and spermatids in the seminiferous tubules at T2 was not significantly different ( $P > 0.05$ ) with NC. These results revealed that unilateral testicular torsion of 720° for 6 hours could reduce the number of spermatogenic cells, spermatocytes and spermatids of the contralateral testicle seminiferous tubules in white rats, and the administration of tomato extract at a dose of 100-200 mg/BW/day was able to increase the number of spermatogenic cells, spermatocytes and spermatids in these rats. The results of this study are in line with the results of a study reported by Lysiak *et al.* (2001), where white rats also underwent unilateral testicular torsion 720° for 2 hours which resulted in damage to the seminiferous tubules, significantly decreased testicular mass, and impaired spermatogenesis and spermatozoa production of the contralateral testis. The same thing was also reported by Yildiz *et al.* (2011), in rats that underwent unilateral torsion 720° for 2 hours, it was found that in the contralateral testicular seminiferous tubules there was degeneration, desquamation, and disorganization of tubular epithelial cells but no reduction in the number of the tubular epithelium was found. The results of this study were different from the research by Hardjowijoto *et al.* (2005), who performed 360° torsion for 4 hours on rats and found no disturbances in the spermatogenesis process in the contralateral testis.

The decrease in the number of Sertoli cells, spermatogenic, spermatocytes, and spermatids of the contralateral seminiferous tubule after treatment of unilateral torsion 720° for 6 hours may occur because testicular torsion can cause ischemia. Ischemia leads to a drastic decrease in testicular microvascular blood flow and oxygen tension in the contralateral testis due to twisting of the spermatic cord. The ischemic state followed by reperfusion can trigger an increase in the production of ROS by the mitochondria of macrophage cells, neutrophils, and various other cell types that are in

pathological conditions (Filho *et al.*, 2004). Furthermore, Burtcher *et al.* (2004), stated that if hypoxia conditions occur continuously, it will cause excessive intracellular calcium ions to build up and decrease antioxidant enzymes which will stimulate the production of ROS in the mitochondria. This is in line with the results of a study by Yildiz *et al.* (2011) who performed unilateral torsion of 720° for 2 hours. It was found that the average value of nitric oxide (NO) compounds, a form of ROS in the contralateral testes, was  $33.10 \pm 0.22$   $\mu\text{mol/g}$ , which was significantly higher compared to the mean NO value in the control testes, which was  $31.11 \pm 0.49$   $\mu\text{mol/g}$ . Reactive oxygen species are products of normal cellular metabolism, and include free radicals such as the hydroxyl radical (OH<sup>-</sup>), superoxide anion (O<sub>2</sub><sup>-</sup>), and peroxy radical (RO<sub>2</sub>) and non-radical groups such as hydrogen peroxide (H<sub>2</sub>O<sub>2</sub>) organic peroxide. Both hydroperoxide (ROOH) and NO can cause lipid peroxidation of proteins and in the DNA of cells, causing death or apoptosis in the cells of testicular tissue, which includes Sertoli cells and spermatogenic cells (Agarwal *et al.*, 2008). In severe ischemic conditions in testicular torsion, ROS production can exceed the body's antioxidant defense system in a condition known as oxidative stress in the testes (Agarwal *et al.*, 2008). Under conditions of oxidative stress, the normal balance between ROS production and the body's natural antioxidant performance to eliminate ROS will be disturbed resulting in a disruption in the normal functioning of the oxidation-reduction chain. This leads to oxidative damage to Sertoli cells and spermatogenic cells of the testicular tissue (Evans, 2000). Increased ROS production will result in cell membrane lipid peroxidation which leads to cell membrane organization being damaged, and eventually cellular function is lost completely (Agarwal *et al.*, 2008). Malondialdehyde (MDA) is one of the toxic products produced by lipid peroxidation in cell membranes (Aitken and Baker, 2006). MDA can react with lipoproteins in cells which can cause interference with cell permeability, cell integrity and cause damage to cell organelles. MDA can also interfere with the DNA transcription process, causing damage to testicular spermatogenic cells (Agarwal *et al.*, 2008; Aitken and Roman, 2008).

The results of this study proved that the administration of tomato extract at a dose of 100 mg/kg BW/day (T1) and 200 mg/kg BW/day (T2) could increase the number of Sertoli cells and spermatogenic cells of the contralateral testis seminiferous tubules in rats that had undergone unilateral torsion 720° for 6 hours. This is due to the presence of active ingredients in tomato extracts that act as antioxidants such as vitamin C, vitamin E, lycopene,  $\beta$ -carotene, flavonoids, saponins, phenolics, and tannins (Kailaku *et al.*, 2007; Mohammed and Al-Bayati, 2014; Ribeiro *et al.*, 2014). The presence of antioxidant substances in tomato extract reduces ROS activity inhibiting the occurrence of lipid peroxidation and damage to testicular cells, including Sertoli cells and spermatogenic cells. These results are in accordance with those reported by Motamedi *et al.* (2019), that the administration of

*Echinacea purpurea* extract, which contains large quantities of antioxidants, can increase the number of spermatogenic cells in rats with ischemia/reperfusion.

Vitamin C is an antioxidant contained in tomato extract that is easily soluble in water and able to reduce the action of ROS in cell membranes so as to minimize cell damage that occurs under conditions of oxidative stress (Guerriero *et al.*, 2014). Testicular tissue contains a large amount of polyunsaturated lipids which makes it vulnerable to damage by ROS. By administering antioxidants, this will help to maintain the integrity of testicular cells and germ cells in the testes. It was reported that the administration of vitamin C can improve spermatogenesis, prevent damage to the seminiferous tubules and the thickness of the torsion of the seminiferous tubules of the testis (Moghimian *et al.*, 2017; Ranade *et al.*, 2018). The antioxidant properties of vitamin C are mainly related to its ability to react with many ROS, and the fact that the resulting semidehydro ascorbate is converted back to ascorbate at the expense of Nicotinamide Adenine Dinucleotide (NADH) or reduced glutathione (Ribeiro *et al.*, 2014). Vitamin C also contributes to the redox mechanism by saving other antioxidants such as vitamin E, urate, and  $\beta$ -carotene from their oxidized forms (Angelo *et al.*, 2011). Other studies have also proven that the administration of vitamin C can ensure that steroidogenic Leydig cells are not affected by increased ROS (Guerriero *et al.*, 2014) so that the regulation of the hormone testosterone is maximized during the spermatogenesis process. The presence of vitamin E in tomato extract is able to inhibit the occurrence of damage due to ROS reactions on cell membranes, prevent lipid peroxidation and increase the activity of other antioxidants. This is in line with research conducted by Ranade *et al.* (2011), who demonstrated that the administration of vitamin E can repair the contralateral testicular seminiferous tubule damage in white rats with testicular torsion. Lycopene is a carotenoid pigment that acts as an antioxidant with the ability to bind reactive oxygen compounds, with results twice as high as  $\beta$ -carotene and ten times higher than  $\alpha$ -tocopherol (Palozza *et al.*, 2012).

Lycopene is an antioxidant that plays a role in counteracting cell damage due to ROS activity through an oxidative mechanism, namely by giving electrons to free electrons contained in ROS so that it will produce more stable compounds (Story *et al.*, 2010). Lycopene protects DNA from oxidative stress by inactivating hydrogen peroxidase and nitrogen dioxide and protecting lymphocytes from nitrite dioxide (NO<sub>2</sub>) which damages membranes resulting in cell death (Agarwal and Rao, 2000). This result is different from that reported by Güzel *et al.* (2019) that lycopene administration can only prevent negative I/R effects in the initial period, but is not potent enough to repair tissue injury in the long term.

Tomato extract besides containing vitamin C, vitamin E and lycopene, also contains many flavonoids, phenolic, saponin, alkaloid and tannin compounds which are also antioxidants (Pinella *et al.*, 2016;

Agustina *et al.*, 2017). Flavonoids, as antioxidants contained in tomato extract, are thought to be able to interfere with the lipid peroxidation stage in the initiation phase so that reactive oxygen compounds are unable to turn into new reactive oxygen compounds (Murray *et al.*, 2009). One of the antioxidants that contribute to hydrogen atoms is flavonoids, which oxidize and react with reactive oxygen compounds so that the compound becomes stable. Phenolics are free radical scavengers as well as active redox metal ion chelators. These metal ions work to catalyze lipid peroxidation reactions. Phenolics inhibit the oxidation of lipids and other molecules by donating hydrogen atoms to reactive oxygen compounds to produce phenoxyl radical intermediates. This compound is relatively stable so that other radical reactions cannot be re-initiated (Nzaramba, 2008). Alkaloids can act as reactive oxygen scavengers and can inhibit the formation of lipid peroxidation in the microsomal hepatic phase. One of the advantages of alkaloid compounds, especially indole, is that it can efficiently inhibit the reaction of free radical compounds. In addition, other alkaloid compounds, such as caffeine, work as hydroxyl radicals (Dinara *et al.*, 2007). However, in this study, it is not known with certainty the type of alkaloid that has an effect on antioxidant bioactivity. Triterpenoids as antioxidants will react with HOO\* radicals which can bind quickly to peroxy radicals until the reaction enters the termination stage (Grassman, 2005). Saponins and tannins can work as antioxidants and have the advantage of balancing the ROS imbalance in the body (Kumari and Jain, 2012).

The results also showed that the number of Sertoli cells, spermatogenic cells, spermatocytes, and spermatid cells of the contralateral testicular seminiferous tubules in the unilateral testicular torsion white rat group (T1), was significantly higher ( $P < 0.05$ ) compared to a group of white rats with unilateral testicular torsion (T2). This condition is caused by differences in the number of active ingredients that act as antioxidants in the tomato extract. As reported by several previous researchers, higher doses of tomato extract will be more difficult to absorb because it is too concentrated, so the onset of the active ingredients in the tomato extract will be slower. These results agree with the research of Suryani *et al.* (2013), which proves that by giving lycopene, vitamin C, vitamin E, flavonoid compounds, saponins, and alkaloids at high concentrations of antioxidant activity, they will turn into prooxidants that can damage cells. In conditions where antioxidants are not balanced with prooxidants or when oxidant levels are high while prooxidants are low, the body will produce prooxidants to balance the levels of antioxidants. This condition will result in the increased production of free radical compounds. Increased prooxidant activity can reduce the levels of antioxidant enzymes in the body such as glutathione peroxidase and catalase (Durgo *et al.*, 2007). An imbalance between antioxidant and prooxidant enzymes in the body will damage spermatogenic cells, which will cause a decrease in the formation of spermatozoa (Agarwal *et al.*, 2014).

## CONCLUSION

In conclusion the administration of tomato extract after detorsion can increase the number of Sertoli cells and spermatogenic cells of the contralateral testicular seminiferous tubules in white rats subjected to unilateral torsion of 720° for 6 hours.

## REFERENCES

- Afamefuna, D.I., O.E. Yama, F.I.O. Duru, and S.A. Oyebadejo. 2012. Experimental testicular torsion in a rat model: Effects of treatment with *Pausinystalia macroceras* on testis functions. **J. Reprod. Infertil.** 13(4):218-224.
- Agarwal, A. and T.M. Said. 2005. Oxidative stress, DNA damage and apoptosis in male infertility: A clinical approach. **BJU Int.** 95(4):503-507.
- Agarwal, A., G. Virk, C. Ong, and S.S. du Plessis. 2014. Effect of oxidative stress on male reproduction. **World J. Mens Health.** 32(1):1-17.
- Agarwal, A., H. Abdelrazik, and R. Sharma. 2008. Oxidative Stress Measurement in Patients with Male or Female Factor Infertility. In **Handbook of Chemiluminescent Methods in Oxidative Stress Assessment**. Popov, I. And G. Lewin (Eds.). Transworld Research Network, Kerala, India.
- Agustina, L., M. Yulianti, F. Shoviantari, and I.F. Sabban. 2017. Formulasi dan evaluasi sabun mandi cair dengan ekstrak tomat (*Solanum lycopersicum* L.) sebagai antioksidan. **J. Wiyata.** 4(2):104-110.
- Aitken, R.J. and S.D. Roman. 2008. Antioksidant systems and oxidative stress in the testes. **Oxid. Med. Cell. Longev.** 1(1):15-24.
- Aitken, R.J. and Baker, M.A. (2006). Oxidative stress, sperm survival and fertility control. **Mol. Cell. Endocrinol.** 250(1-2): 66-69.
- Anas, E. and A. Asterina. 2011. Efek pemberian just tomat (*Lycopersicum pyriforme*) terhadap spermatogenesis pada tikus putih (*Rattus norvegicus*) jantan dewasa hyperkholestolemia. **J. Majalah Kedokteran Andalas.** 35(1):27-36.
- Angulo, C., R., Maldonado, E. Pulgar, H. Mancilla, A. Córdova, F. Villarroel, M.A. Castro, and I.I. Concha. 2011. Vitamin C and oxidative stress in the seminiferous epithelium. **Biol. Res.** 44(2):169-80.
- Basuny, A.M., A.M. Gaafar, and S.M. Arafat. 2009. Tomato lycopene is a natural antioxidant and can alleviate hypercholesterolemia. **Afr. J. Biotechnol.** 8 (23):6627-6633.
- Bo, X., P. Wang, Y. Nie, R. Li, J. Lu, and H. Wang. 2020. Protective effect of hypothermia and vitamin E on spermatogenic function after reduction of testicular torsion in rats. **Exp. Ther. Med.** 20(2):796-801.
- Boettcher, M., R. Bergholz, T.F. Krebs, K. Wenke, and D.C. Aronson. 2012. Clinical predictors of testicular torsion in children. **J. Urol.** 79:670-674.
- Burtscher, M., O. Pachinger, I. Ehrenbourg, G. Mitterbauer, M. Faulhaber, R. Pühringer, and E. Tkatchouk. 2004. Intermittent hypoxia increases exercise tolerance in elderly men with and without coronary artery disease. **Inter. J. Cardiol.** 96(2):247-254.
- Campbell, J.K., K.C. Adams, B.L. Lindshield, T.W. Boileau, S.K. Clinton, and J.W. Erdman. 2004. Tomato phytochemicals and prostate cancer risk. **J. Nutr.** 134(12):3486-3492.
- Dasrul, Sugito, and Nurliana. 2013. Pemanfaatan Ekstrak Tomat (*Lycopersicum esculentum* Mill) sebagai Antioksidan dan Antiinfertilitas serta Potensinya dalam Pencegahan Infertilitas Tikus Putih (*Rattus norvegicus*) Strain Wistar Hiperkolestolemik. **Laporan Hasil Penelitian Hibah Pasca Sarjana.** Universitas Syiah Kuala. Banda Aceh.
- Davies, J. 2000. Tomatoes and health. **J. Soc. Health.** 120(2):81-82.
- De Bock, M., J. Govaere, A. Martens, M. Hoogewijs, C. De Schauwer, K. Van Damme, and A. de Kruif. 2007. Torsion of the spermatic cord in a warmblood stallion. **Vlaams Diergeneeskundig Tijdschrift.** 76:443-446.
- Dinara, J.M., F.R. Marc, M.B. Jane, A.P.A.H. Joã'o, and S. Jenifer. 2007. Antioxidant properties of b-carboline alkaloids are related to their antimutagenic and antigenotoxic activities. **Mutagenesis.** 22(4):293-302.

- Dokmeci, D. 2012. **Oxidative Stress and Testicular Torsion: Studies on Mens Health and Fertility**. Humana Press, United States.
- Durgo, K., L. Vukovi, G. Rusak, M. Osmak, and J. Franeki. 2007. Effect of flavonoids on glutathione level, lipid peroxidation and cytochrome p450 cyp1a1 expression in human laryngeal carcinoma cell lines. **Food Technol. Biotechnol.** 45(1):69-79.
- Evans, W.J. 2000. Vitamin E, vitamin C, and exercise. **Am. J. Clin. Nutr.** 72(2):647S-652S.
- Filho, D.W., M.A. Torres, A.L. Bordin, T.B. Crezcynski-Pasa, and A. Boveris. 2004. Spermatic cord torsion, reactive oxygen and nitrogen species and ischemic reperfusion injury. **Mol. Aspects Med.** 25(1-2):199-210.
- Giuliano, A. 2013. Testicular torsion in a normally descended testicle in a cat. **J. Small Anim. Pract.** 54:164.
- Gnimaraes, S.B., A.A. Aragao, J.M.V. Santos, O.S. Kimura, P.H.U. Barbosa, and P.R.L. Vasconcelos. 2007. Oxidative stress induced by torsion of the spermtic cord in young rats. **Acta Cir. Bras.** 22(1):30-33.
- Grassman, J. 2005. Terpenoids as plant antioxidant. **Vitam. Horm.** 72:505-535.
- Guerriero, G., S. Trocchia, F.K. Abdel-Gawad, and G. Ciarcia. 2014. Roles of reactive oxygen species in the spermatogenesis regulation. **Front. Endocrinol.** 5(56):1-4.
- Güzel, M., M.F. Sönmez, O. Bastuğ, N.F. Aras, A.B. Öztürk, M. Küçükaydin, and C. Turan. 2015. Effectiveness of lycopene on experimental testicular torsion. **J. Pediatr. Surg.** Doi:10.1016/j.jpedsurg.2015.11.008.
- Hardjowijoto, S. 2005. The effect of ipsilateral testicular torsion upon immunity modulatorin and apoptosis of germinal cells int the contralateral testis. **Folia Medica Indonesiana.** 41(1):9-17.
- Hernayanti, H., S. Santoso, and A. Muntafiah. 2017. Likopen dalam Tomat sebagai Antiinflamasi dan Antinefrotoksitas pada Tikus Putih Terpapar Kadmium. **Prosiding Seminar Nasional dan Call for Papers "Pengembangan Sumber Daya Perdesaan dan Kearifan Lokal Berkelanjutan VII"**. Purwokerto:615-622.
- Kailaku, S.I., T.D. Kun, and Sunarmani. (2007). Potensi likopen dalam tomat untuk kesehatan. **Bul. Teknologi Pascapanen Pertanian.** 3(1):50-58.
- Karaguzel, E., M. Kadihasanoglu and O. Kutlu. 2014. Mechanisms of testicular torsion and potential protective agents. **Nat. Rev. Urol.** 11(7):391-399.
- Kumari, M. and S. Jain. 2012. Tannins: An antinutrient with positive effect to manage diabetes. **Res. J. Recent Sci.** 1(12):1-8.
- Lorenzini, F., R.T. Filho, R.P.X. Gomes, A.J. Martino-Andrade, T.R. Erdmann, and J.E.F. Matias. 2012. Long-term effect of the testicular torsion on the spermatogenesis of the contralateral testis and the preventive valie of the twisted testis orchiepidymectomy. **Acta Cir. Bras.** 27(6):388-395.
- Lysiak, J.J., S.D. Turner, Q.A.T. Nguyen, K. Singbartl, K. Ley, and T.T. Turner. 2001. Essential role of neutrophils in germ cell-specific apoptosis following ischemia/reperfusion injury of the mouse testis. **Biol. Reprod.** 65(3):718-725.
- Masoume, M.O., J. Sara, and T.N. Hossein. 2020. Antioxidant property of *Plantago major* leaf extracts reduces testicular torsion/detorsion-induced ischemia/reperfusion injury in rats. **Vet. Res. Forum.** 11(1):27-33.
- Moghimian, M., M. Soltani, H. Abtahi, and M. Shokoohi. 2017. Effect of vitamin C on tissue damage and oxidative stress following tunica vaginalis flap coverage after testicular torsion. **J. Pediatr. Surg.** 52(10):1651-1655.
- Mogilner, J.G., Y. Elenberg, M. Lurie, E. Shiloni, A.G. Coran, and I. Sukhotnik. 2006. Effect of dexamethasone on germ cell apoptosis in the contralateral testis after testicular ischemia-reperfusion injury in the rat. **Fertil. Steril.** 85(1):1111-1117.
- Mohammad, H.S., H. Farshad, A. Shahyar, and M.S. Habibollah. 2012. Histological evidence and proliferative potential of the contralateral testis and epididymis in rats with unilateral testicular torsion. **J. Reprod. Endocrinol. Infertility.** 1(2):19-376.
- Mohammed, A.I. and M.A. Al-Bayati. 2014. Comparative study among watermelon crud extract, citrulline and lycopene on some reproductive indices in male mice. **Int. J. Res Med. Health Sci.** 3(6):7-14.
- Motamedi, S., A. Ahmad, J. Alireza, A. Gholamreza, and M. Pejman. 2019. Effects of *Echinacea purpurea* extract on testicular ischemia/reperfusion (I/R) injury in rat. **Iranian J. Vet. Med.** 13(3):303-313.
- Murray, R.K., D.K. Granner, and V.W. Rodwell. 2009. **Biokimia Harper.** 27<sup>th</sup> ed. EGC., Jakarta.
- Nzaramba, M.N. 2008. Relationships among antioxidants, phenolics, and specific gravity in potato cultivars, and evaluation of wild potato species for antioxidants, glycoalkaloids, and anti-cancer activity on human prostate and colon cancer cells in vitro. **Dissertation.** A&M University, Texas.
- Özkan, K.U., M. Küçükaydin, S. Muhtaroglu, and O. Konaş. 2000. Evaluation of contralateral testicular damage after unilateral testicular torsion by serum inhibin b levels. **J. Pediatr. Surg.** 36(7):1050-1053.
- Palozza, P., A. Catalano, R.E. Simone, M.C. Mêle, and A. Cittadini. 2012. Effect of lycopene and tomato products on cholesterol metabolism. **Ann. Nutr. Metab.** 61(2): 126-134.
- Pinella, J., M.B.P.P. Oliveira, and I.C.F.R. Ferreira. 2016. Bioactive Compounds of Tomatoes as Health Promoters. In **Natural Bioactive Compounds from Fruits and Vegetables**. L.R da-Silva and B.M. Silva (Eds.). 2<sup>nd</sup> ed. Bentham Science Publishers, Portugal.
- Ranade, A.V., T. Yogesh, C.V. Raghuvver, and R. Rajalakshmi. 2018. Role of ascorbic acid in ameliorating testicular tissue damage induced by testicular torsion and detorsion: An animal model study. **J. Clin. Diagn. Res.** 12(4):1-4.
- Ranade, A.V., Y. Tripathi, R. Rajalakshmi, N.A. Vinodini, R.N. Soubhagya, A.K. Nayanatara, D.K. Rekha, and M. Kumari. 2011. Effect of vitamin E administration on histopathological changes in rat testes following torsion and detorsion. **Singapore Med. J.** 52(10):742-746.
- Ribeiro, C.T., R. Milhomem, D.B. De Souza, W.S. Costa, F.J. Sampaio, and M.A. Pereira-Sampaio. 2014. Effect of antioxidants on outcome of testicular torsion in rats of different ages. **J. Urol.** 191(5):1578-1585.
- Sabilu, Y., Nuziyati, A.F. Fachlevi, S.K. Saptaputra, and H. Hidayanty. 2017. Tomato juice (*Lycopersicum commune*) reduces blood pressure in elderly hypertensive Indonesians in Kulisusu, North Buton. **Asian J. Clin. Nutr.** 9(3):111-117.
- Story, E.N., R.E. Kopec, S.J. Schwartz, and G.K. Harris. 2010. An update on the health effects of tomato lycopene. **Annu. Rev. Food Sci. Technol.** Doi:10.1146/annurev.food.102308.124120.
- Sukhotnik, I., I. Miselevich, M. Lurie, O. Nativ, A.G. Coran, and J.G. Mogilner. 2005. The time relationship between ipsilateral testicular ischemia and germ cell apoptosis in the contralateral testis in rat. **Pediatr. Surg. Int.** 21(7):512-516.
- Suryani, N., T.E. Hernowati, and Aulanni'am. 2013. Pengaruh ekstrak metanol biji mahoni terhadap peningkatan kadar insulin, penurunan ekspresi tnf- $\alpha$  dan perbaikan jaringan pankreas tikus diabetes. **J. Kedokteran Brawijaya.** 27(3):137-145.
- Vigueras, R.M., G. Reyes, J. Rojas-Castañeda, P. Rojas, and R. Hernández. 2004. Testicular torsion and its effects on the spermatogenic cycle in the contralateral testis of the rat. **Lab. Anim.** 38(3):313-320.
- Viliotti, T.A.A., R.E.O. Ferraz, L.V. de Lucena, C.L.B. Monteiro, and A.C.M. Filho. 2018. Torção testicular em saco escrotal de canino jovem. **Acta Sci. Vet.** 46(1):268-274.
- Visser, A.J. and C.F. Heyns. 2003. Testicular function after torsion of the spermatic cord. **BJU Int.** 92(3):200-203.
- Yamamoto, Y., K. Aizawa, M. Mieno, M. Karamatsu, Y. Hirano, K. Furui, T. Miyashita, K. Yamazaki, T. Inakuma, I. Sato, H. Suganuma, and T. Iwamoto. 2017. The effects of tomato juice on male infertility. **Asia Pac. J. Clin. Nutr.** 26(1):65-71.
- Yang, C., B. Song, J. Tan, X. Liu, and G.H. Wei. 2011. Testicular torsion in children: A 20-year retrospective study in a single institution. **Sci. World J.** 11:362-368.
- Yildiz, H., A.S. Durmus, H. Simsek, and I. Yaman. 2011. Effects of sildenafil citrate on torsion/detorsion-induced changes in red blood cell and plasma lipid peroxidation, antioxidants, and blood hematology of male rats. **Eur. J. Obstet. Gynecol. Reprod. Biol.** 159(2):359-363.