

## PREVALENCE OF MARES' GRANULOSA THECA CELL TUMOR (GTCT) IN INDONESIA

Amrozi<sup>1</sup>, Luci Parwati<sup>1</sup>, Juli Melia<sup>2\*</sup>, and Ligaya I.T.A. Tumbelaka<sup>1</sup>

<sup>1</sup>Department of Veterinary Clinic, Reproduction and Pathology, Faculty of Veterinary Medicine, IPB University, Bogor, Indonesia

<sup>2</sup>Laboratory of Reproduction, Faculty of Veterinary Medicine, Universitas Syiah Kuala, Banda Aceh, Indonesia

\*Corresponding author: julimelia@unsyiah.ac.id

### ABSTRACT

This study was conducted to determine the prevalence rate of mares' GTCT in Indonesia. Ultrasound examination of ovaries were performed on mares in Java and Madura Island of Indonesia. Thirteen mares had been affected by GTCT from 2913 number of examinations. The prevalence rate of GTCT during year 2006 and 2007 were 4.71% and 5.56%, respectively followed by a decrease in prevalence rate of GTCT during 2008-2014. The reproductive cycle in a mare with GTCT had returned to normal 6 months after ovariectomy.

Key words: granulosa theca cell tumor, mares, ovariectomy, prevalence rate

### ABSTRAK

Penelitian ini bertujuan untuk mendeterminasi angka prevalensi GCTC kuda betina di Indonesia. Pemeriksaan ultrasound ovarium kuda betina dilakukan di Pulau Jawa dan Madura Indonesia. Sejumlah tiga belas betina mengalami GCTC dari 2913 yang diperiksa. Angka prevalensi GCTC sejak tahun 2006 dan 2007 secara berurutan adalah 4,71% dan 5,56%, kemudian diikuti dengan penurunan angka prevalensi GCTC selama 2008-2014. Siklus reproduksi kuda betina yang GCTC menurun menjadi normal 6 bulan terakhir setelah ovariectomi.

Kata kunci: granulosa theca cell tumor, kuda betina, ovariectomi, angka prevalensi

### INTRODUCTION

Reproductive failure in mares could be caused by various factors. Granulosa theca cell tumor (GTCT) is one of the reproductive organ abnormality in mares. The prevalence rate of GTCT was 2.5% of all neoplasia in horses (Sundberg *et al.*, 1977). GTCT developed on granulosa and theca cells of the ovary and usually occurred only at one side of the ovaries. The proliferative granulosa cells or theca cells secrete high level of inhibin or testosterone, leading estrus cycle. Increasing serum testosterone concentration in the mares with GTCT also showed specific behavioral changes, such as "stallion-like behavior" (Ellenberger *et al.*, 2007).

Nymphomania has correlation with oestradiol and anestrus caused by high concentration inhibin which reduce the release of follicle stimulating hormone (Ellenberger *et al.*, 2007). Changes in the characteristics of the estrous behaviour is confusing farmers to breed the mares in Indonesia. This study was conducted to determine the prevalence rate of mares' GTCT in Indonesia.

### MATERIALS AND METHODS

Ultrasound examination of ovaries were performed in 2913 numbers of mares in Jawa and Madura islands of Indonesia during year 2006-2014. The mares included local breed, warmblood, thoroughbred, and crossbred (local mares x thoroughbred stallions), without concern to the stage of reproductive period. The prevalence of GTCT was calculated based on number of examined mares annually. The mares detected with GTCT in the first examination were not included in the following years. Mares were examined

with transrectal ultrasound using Sonoscape Vet A6 equipped with linear probe 7.5 MHz. Ultrasonographic examination of GTCT typically shows the presence of multiple cystic compartments, resulting in the so-called honey-comb appearance or occasionally a single large central cyst containing hypoechoic fluid (Maurice, 2005). It was also confirmed with the present of stallion-like behavior and contralateral ovarian hypofunction (Zelli *et al.*, 2006; Ellenberger *et al.*, 2007).

Right flank ovariectomy was carried out as a treatment on a mare which had a GTCT on the right ovary. The mare was under general anesthesia using xylazine and ketamine. Local anesthesia was given using lidocaine applied in between 1<sup>st</sup> lumbar and 2<sup>nd</sup> lumbar vertebrae and on flank. Antibiotic penicillin-streptomycin and dexamethasone were given as post-surgery treatment.

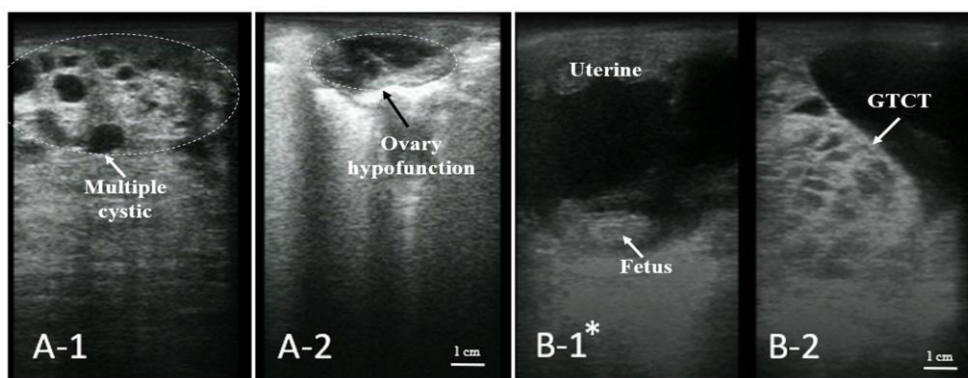
### RESULTS AND DISCUSSION

Throughout the examination that was carried out during the period of 2006-2014, 13 out of 2913 examinations were diagnosed with GTCT by ultrasound imaging. During year 2006 and 2007, 4.71% and 5.56% GTCT cases were found respectively. The number of examinations were increased the following years due to a high prevalence rate of GTCT found in year 2006 and 2007. However, the prevalence rate of GTCT decreased during 2008-2014 (Table 1).

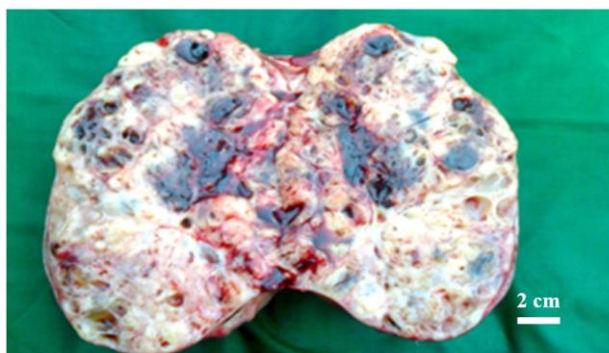GTCT was seen to be a main neoplasm case occurs in mares (McCue *et al.*, 2006) which decreases reproduction performance. Hypofunction of the contralateral ovary characterized by small hypoechoic follicle seen on ultrasound imaging (Figure 1). This was consistent with the findings of many researchers

**Table 1.** Prevalence of granulosa theca cell tumor on mares in Indonesia during 2006-2014

Year	Number of examinations	Total GCTC case	Prevalence (%)
2006	85	4	4.71
2007	38	2	5.56
2008	280	1	0.36
2009	371	0	0.00
2010	394	3	0.76
2011	408	1	0.25
2012	506	0	0.00
2013	608	1	0.16
2014	223	1	0.45



**Figure 1.** Sonogram on a mare with granulosa theca cell tumor shows the presence of multiple cystic compartments, resulting in the so-called honey-comb appearance (A-1) and hypofunction of the contralateral ovary (A-2). A fetus in the uterine of pregnant mare (B-1\*) with GTCT (B-2)



**Figure 2.** Multiple cystic compartments on the cross section of ovariectomized ovary with granulosa theca cell tumor

(Watson, 1999; McCue *et al.*, 2006; Gündüz *et al.*, 2010; McKinnon and Barker, 2010) which stated that a horse with GTCT on one of its ovaries usually followed by hypofunction of contralateral ovary. Proliferative granulosa cells secrete inhibin which affects the low level of the FSH concentration, leading to atrophy of the contralateral ovary (Zelli *et al.*, 2006; Ellenberger *et al.*, 2007). This inhibits follicles to grow optimally which leads to infertility in mares and is shown by prolonged anestrus.

Generally, mares with GTCT changes in behavior. Tumors which invade the theca cells in the ovary lead to an increase in the secretion of testosterone (Ball *et al.*, 2013). Excessive testosterone results in a changing of behavior into stallion-like behavior that is one of the typical symptoms in mares with GTCT (Stabenfeldt *et al.*, 1979; Bosu *et al.*, 1982; Crabtree, 2011). In this study 12 out of 13 mares showed stallion-like behavior symptoms due to GTCT. Stallion like behavior also showed on mares with long-term usage of anabolic steroid as estrus

suppressors (Turner and Irvine, 1982). However, there is no research to support that administration of anabolic steroids causes tumors in horses.

Estrogen was produced excessively when the tumor attacked granulosa cells. The increasing estrogen causes mares with GTCT to show symptom such as nymphomania. An increase of estradiol level in mares will lead to nymphomania (Yoshida *et al.*, 2000). While other researcher stated that in cases of malignant GTCT, where estradiol level increased abnormally, sign of nymphomania was more obvious (Ellenberger *et al.*, 2007).

GTCT occurrence has no predilection on breeds, local horses could also be affected by GTCT. In this study, mares with GTCT detected from breeds such as crossbred, thoroughbred, and warmblood horses. Mares were found affected from age 4-18 years old. Some researchers found that GTCT can occur in horses with an average age of 11.7 years old (Crabtree, 2011) and between age 2-20 years old (Meagher *et al.*, 1977).

In this study, one mare went through ovariectomy to remove tumors. The sizes of tumors removed range from 8.08 x 19.5 cm. The weight of ovary which is affected by GTCT increased with the size of the tumor formed (McCue *et al.*, 2006). The removed GTCT was seen as a gross rounded mass. Multicystics were found after a transverse incision on the tumor (Figure 2) which are consistent with the result seen from ultrasound imaging. Tumors showed multiple hemorrhage while incising (Ellenberger *et al.*, 2007). The mare showed estrous sign 6 months after removal of tumors. Pregnancy examinations were performed after 30 days of breeding indicating positive pregnancy. It was proven that removal of GTCT is helpful in restoring function of the contralateral ovary (Hoque *et al.*, 2003).

A mare with GTCT who was bred while showing estrus sign showed positive pregnancy. This mare often shows stallion-like behavior and has been used as a teaser on other mares. GTCT marked as hypoechoic honeycomb structure at the ovary and fetus were found underlying one of the uteri horn seen from ultrasound imaging (Figure 1). Pregnancy can occur in mares with GTCT if the contralateral ovary function optimally where the follicles in the ovaries were normal and develop well unlike those hypofunction collateral ovaries. Another researcher reported cases where positive pregnancy came along with affected GTCT ovaries and mare showed sign of stallion-like behavior (Gee *et al.*, 2012).

### CONCLUSION

In conclusion, the prevalence rate of GTCT during year 2006 and 2007 were 4.71% and 5.56%, respectively followed by a decrease in prevalence rate of GTCT during 2008-2014. Ovariectomy carried out on affected mares was able to restore normal estrus cycles. Pregnancy occurred in conjunction with GTCT where mare showed symptoms of stallion-like behavior.

### ACKNOWLEDGMENT

We would like to thank the horse owners from all over Indonesia that have supported this case study.

### REFERENCES

- Ball, B.A., A.J. Conley, J. Almeida, A.E. Vico, J. Crabtree, C. Munro, and I.K.M. Liu. 2013. A retrospective analysis of 2253 cases submitted for endocrine diagnosis of possible granulosa cell tumors in mares. *J. Equine Vet. Sci.* 34(2):307-313.
- Bosu, W.T.K., S.C.V. Camp, R.B. Miller, and R.R. Owen. 1982. Ovarian disorder: Clinical and morphological observations in 30 mares. *Can. Vet. J.* 23(1):6-14.
- Crabtree, J. 2011. Review of seven cases of granulosa cell tumour of the equine ovary. *Vet. Rec.* 169(10):251-258.
- Ellenberger, C., C.P. Bartman, H.O. Hoppen, J. Kratzsch, H. Aupperle, E. Klug, D. Schoon, and H.A. Schoon. 2007. Histomorphological and immunohistochemical characterization of equine granulosa cell tumor. *J. Comp. Path.* 136(2-3):167-176.
- Gee, E.K., M. Dicken, R.M. Archer, C.L. Herdan, F.E.T. Pauwels, and B.M. Drayton. 2012. Granulosa theca cell tumour in a pregnant mare: Concentrations of inhibin and testosterone in serum before and after surgery. *N. Z. Vet. J.* 60(2):160-163.
- Gündüz, M.C., G. Kaşıkçı, R. Kiliçarslan, M. Uçmak, O. Düzgün, and C. Tek. 2010. Reproductive performance following unilateral ovariectomy for treatment of ovarian tumors in 7 mares. *Turk. J. Vet. Anim. Sci.* 34(3):283-287.
- Hoque, S.M.D., H. Senba, N. Tsunoda, R.I. Derar, G. Watanabe, K. Taya, T. Osawa, and Y.I. Miyake. 2003. Endocrinological change before and after removal of the granulosa-theca cell tumor (GTCT) affected ovary in 6 mares. *J. Vet. Med. Sci.* 65(8):887-891.
- Maurice, K.T. 2005. Diagnosis and surgical removal of a granulosa-theca cell tumor in a mare. *Can. Vet. J.* 46:644-646.
- McCue, P.M., J.F. Roser, C.J. Munro, I.K.M. Liu, and B.L. Lasley. 2006. Granulosa cell tumors of the equine ovary. *Vet. Clin. Equine.* 22(3):799-817.
- McKinnon, A.O. and K.J. Barker. 2010. Granulosa theca cell tumours. *Equine Vet. Educ.* 22(3):121-124.
- Meagher, D.M., J.D. Wheat, J.P. Hughes, G.H. Stabenfeldt, and B.A. Harris. 1977. Granulosa cell tumors in mares: A review of 78 cases. *Proc. Am. Ass. Equine Practnrs.* 23:133-143.
- Stabenfeldt, G.H., J.P. Hughes, P.C. Kennedy, D.M. Meagher, and D.P. Neely. 1979. Clinical findings, pathological changes and endocrinological secretory patterns in mare with ovarian tumours. *J. Reprod. Fertil. Suppl.* (27):277-285.
- Sundberg, J.P., T. Burnstein, E.H. Page, W.W. Kirkham, and F.R. Robinson. 1977. Neoplasms of equidae. *J. Am. Vet. Med.* 170(2):150-152.
- Turner, J.E. and C.H. Irvine. 1982. Effect of prolonged administration of anabolic and androgenic steroid on reproductive function in the mare. *J. Reprod. Fertil.* 32:213-218.
- Watson, E.D. 1999. Granulosa cell tumours in the mare: A review of 9 cases. *Equine Vet. Educ.* 11(3):136-142.
- Yoshida, G., N. Tsunoda, Y.I. Miyake, H.M.D. Shafiqul, T. Osawa, N. Nagamine, H. Taniyama, Y. Nambo, G. Watanabe, and K. Taya. 2000. Endocrinological studies of mares with granulosa-theca cell tumor. *J. Equine Sci.* 11(2):35-43.
- Zelli, R., L. Sylla, M. Monaci, G. Stradaidoli, L.E. Sibley, J.F. Roser, C. Munro, and I.K.M. Liu. 2006. Gonadotropin secretion and pituitary responsiveness to GnRH in mares with granulosa theca cell tumor. *Theriogenology.* 66:1210-1218.