

Selecting Treatment Modality for Small Hepatocellular Carcinoma: Radiofrequency Ablation, Percutaneous Alcohol and Acetic Acid Injection

Birry Karim*, Andri Sanityoso Sulaiman**

*Department of Internal Medicine, Faculty of Medicine, University of Indonesia
Dr. Cipto Mangunkusumo General National Hospital, Jakarta

**Division of Hepatology, Department of Internal Medicine, Faculty of Medicine
University of Indonesia/Dr. Cipto Mangunkusumo General National Hospital, Jakarta

ABSTRACT

Hepatocellular carcinoma (HCC) is the most common primary hepatic malignancy worldwide and is the leading cause of death in patients with cirrhosis. In early-stage tumors, potential curative therapies have been used including ablative therapies using percutaneous ethanol injection (PEI), percutaneous acetic acid injection (PAI) or radiofrequency ablation (RFA); surgical resection and liver transplantation. RFA is more effective and safer than other local ablative therapy modalities. RFA should be considered as the first-line treatment for patients with small HCC, i.e. sized less than 5 cm; preferably less than or equal to 3 cm since they are not suitable for liver resection or liver transplantation. RFA should also be compared with transarterial embolization, which currently has been considered as the standard HCC therapy in some countries. It has been reported that the combination of RFA and embolization treatment may reduce the early and late recurrence rate.

Keywords: *hepatocellular carcinoma, percutaneous ethanol injection, acetic acid injection, radiofrequency ablation*

ABSTRAK

Karsinoma hepatoselular merupakan tumor ganas hati yang sering ditemukan di seluruh dunia dan merupakan penyebab tersering kematian pasien dengan sirosis hati. Pada fase awal kanker ini, beberapa modalitas tatalaksana telah digunakan, meliputi injeksi etanol perkutan, injeksi asam asetat perkutan atau ablasi radiofrekuensi; reseksi dan transplantasi hati. Ablasi radiofrekuensi merupakan modalitas ablasi yang paling efektif dan aman. Ablasi radiofrekuensi merupakan pilihan pada kasus hepatoma dengan ukuran kurang dari 5 cm, lebih dianjurkan ukuran yang lebih kecil atau sama dengan 3 cm, sepanjang reseksi maupun transplantasi hati tidak mungkin dilakukan. Ablasi radiofrekuensi sebaiknya dibandingkan dengan embolisasi transarterial dimana modalitas ini telah digunakan sebagai terapi standar untuk hepatoma di beberapa negara maju. Dilaporkan bahwa kombinasi ablasi radiofrekuensi dengan embolisasi transarterial dapat menurunkan angka kekambuhan.

Kata kunci: *karsinoma hepatoselular, injeksi etanol perkutan, injeksi asam asetat, ablasi radiofrekuensi*

INTRODUCTION

Hepatocellular carcinoma (HCC) is the most common primary hepatic malignancy worldwide and is the leading cause of death in patients with cirrhosis in Europe. Early detection strategies have increased the number of small HCC amenable to curative treatment.¹

More than 600,000 people die of HCC each year. HCC is the sixth most common malignancy worldwide. It is the 5th most common malignant disease in male and the 8th most common in female. It is the 3rd most common cause of death from cancer, after lung and stomach cancer. HCC is the most common malignant disease in several regions of Africa and Asia. At least 300,000

of the 600,000 deaths worldwide occur in China alone, and the majority of the other 300,000 deaths occur in resource-challenged countries in sub-Saharan Africa. Worldwide research on the disease should be intensified in both medical and pharmaceutical fields, especially with a focus on providing help to areas where resources are limited. Treatment approaches depend on the stage of the disease at diagnosis and on access to complex treatment regimens. However, advanced disease is not curable, and management of advanced disease is expensive and only marginally effective in increasing quality-adjusted life years.²

The incidence of HCC is increasing in Europe and the United States. It is currently the leading cause of death among cirrhotic patients. Chronic hepatitis B viral (HBV) infection is the predominant risk factor of HCC in Asia and Africa; while chronic hepatitis C viral (HCV) infection is the major cause of HCC in Western countries and Japan. Hepatocellular carcinoma develops in 80% cases of liver cirrhosis and such pre-neoplastic condition is assumed to be the strongest predisposing factor. Chronic HBV carriers have a 100-fold relative risk of developing HCC compared with non-carriers. The annual HCC incidence rate is 2–6% in cirrhotic patients. Aflatoxin B1 intake further increases the risk of HCC. In Western countries and in Japan, HCV infection is the main risk factor for HCC, together with other causes of cirrhosis. Approximately 20–30% of the estimated 170 million HCV-infected individuals worldwide will develop cirrhosis. Once cirrhosis is established, the annual incidence of HCC is of 3–5%, and one third of them will develop an HCC over their lifetime.³

CLINICAL PROBLEM

HCC accounts for 80–90% of primary liver cancer. HCC is a major health problem worldwide, with an estimated incidence ranging between 500,000 and 1,000,000 new cases annually. It is the 5th most common cancer in the world, and the 3rd most common cause of cancer-related death. For years, partial hepatectomy and liver transplantation have been considered as the main curative treatments. However, only 10 to 20% of HCC is resectable. Anatomic location, size or number of lesions, inadequate liver remnant, or comorbid condition precludes surgery in the majority of patients. Orthotopic liver transplantation can cure some patients with poor liver function due to the underlying cirrhosis; however, only few are eligible due to the scarcity of donors.⁴ These devastating HCC problems are most likely due to failure in recognizing patients at risk (with hepatitis B and/or C), high

prevalence of risk factors in the population, lack of medical expertise and facilities for early diagnosis, and lack of effective treatment following the diagnosis.²

BARCELONA CLINIC LIVER CANCER CLASSIFICATION

The Barcelona clinic liver cancer classification (BCLC) is the most frequently utilized classification for management of HCC. In early-stage tumors, potential curative therapies have been used including ablative therapies using percutaneous ethanol injection (PEI), percutaneous acetic acid injection (PAI) or radiofrequency ablation (RFA); surgical resection and liver transplantation. Those treatments provide better survival rates at 5-years of 40–70% vs. < 20% for untreated patients; however, they are applicable in only 30–40% of patients with HCC.¹

BCLC staging classification and treatment schedule consists of five staging: (1) Stage 0: patients with very early HCC are optimal candidates for resection; (2) Stage A: patients with early HCC are candidates for radical therapies (resection and ablation, liver transplantation or percutaneous treatments); (3) Stage B: patients with intermediate HCC may benefit from chemoembolization; (4) Stage C: patients with advanced HCC may receive new agents in the setting of a RCT; (5) Stage D: patients with end-stage disease will receive symptomatic treatment.⁵

SELECTING TREATMENT MODALITY

Percutaneous treatments provide good results (5-year survival of 40–50%), but are unable to achieve response rates and outcomes comparable to those for surgical treatments, even when they are applied as the first option. Therefore, we consider percutaneous ablation as the best option for nonsurgical HCC. Percutaneous ethanol injection is easy to perform and obtains complete response rates in about 70% of solitary tumors less than 3 cm and in almost 100% in tumors less than 2 cm. Five-year survival in Child Turcotte Pugh (CTP) class A patients with small tumors may exceed 60%. Radiofrequency ablation has been claimed to require significantly less sessions than percutaneous ethanol injection to obtain the same response rates and is proposed to better control the local disease. Further RCTs are needed to confirm this statement. For sub-capsular tumors, percutaneous ethanol injection is preferred to radiofrequency ablation to prevent needle track seeding.⁵

Huo et al, compared PEI with PAI in a prospective study among cirrhotic patient. Sixty-three patients were treated by PAI using 50% acetic acid and 62 by

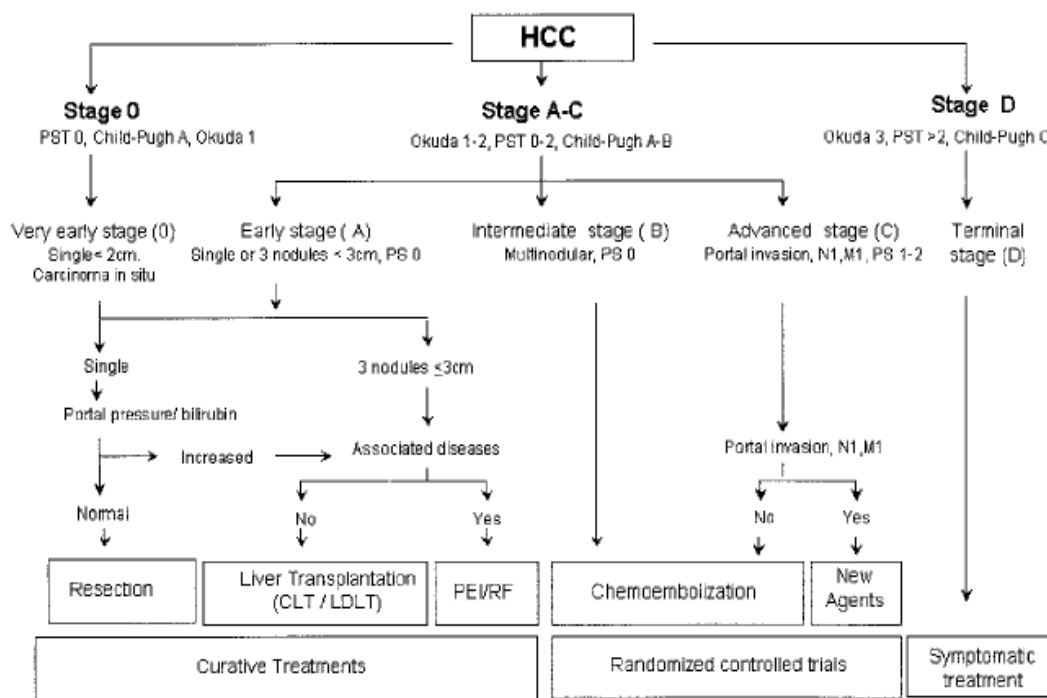


Figure.1 The Barcelona approach: diagnosis, staging, and treatment of hepatocellular carcinoma⁵

PEI using pure ethanol. During a follow-up period of 6–38 months, 19 (30%) subjects of the PAI group and 21 (34%) subjects of the PEI group died ($p = 0.704$). The 1- and 3-year survival rates were 84% and 51% for the PAI group as well as 81% and 46% for the PEI group ($p = 0.651$). The corresponding tumor recurrence rates were 51% and 74% for the PAI group, and 54% and 64% for the PEI group ($p = 0.787$). PAI has the advantage of fewer treatment sessions in each treatment course. From the study, we conclude that PAI and PEI are equally effective in the treatment of HCC.⁶

Sala et al, evaluated the early response of 282 cirrhotic patients with unresectable early HCC who were treated with RFA, PAI, or PEI. Initial complete responses were achieved in 192 patients and were independently related to the size of the main tumor ($p = 0.015$) and tumor stage ($p = 0.0001$); (< 2 cm, 96%; 2.1–3 cm, 78%; > 3 cm, 56%; 2–3 nodules, 46%). At the end of follow-up, 80 patients had sustained their complete response. The 1-, 3-, and 5-year survival rates were 87%, 51%, and 27%, respectively. The independent predictors of survival were Child-Turcotte-Pugh (CTP) class ($p = 0.0001$) and initial complete response ($p = 0.006$). CTP class A patients with initial complete response achieved 42% survival at 5 years; this figure increased to 63% in patients with 2 cm or smaller tumors. In conclusion, the study demonstrated that initial complete response to percutaneous ablation is associated with an improved

survival in both CTP class A and B patients with nonsurgical HCC.⁷

Livraghi et al, compared the effectiveness of RFA with percutaneous ethanol injection in the treatment of small HCC. Eighty-six patients with 112 small (3-cm diameter) HCCs underwent RFA (42 patients with 52 tumors) or percutaneous ethanol injection (44 patients with 60 tumors). Therapeutic efficacy was evaluated with dual-phase spiral computed tomography performed at least 4 months after treatment. Complete necrosis was achieved in 47 of 52 tumors with RFA (90%) and in 48 of 60 tumors with PEI (80%). One major complication (hemothorax that required drainage) and four minor complications (intraoperative bleeding, hemobilia, pleural effusion, cholecystitis) occurred in patients treated with RFA.⁸

Waki et al, evaluated the prognosis and associated factors in patients with small hepatocellular carcinoma (HCC; up to 3 nodules, each up to 3 cm in diameter) treated with percutaneous RFA as first-line treatment. Eighty-eight consecutive patients who had percutaneous RFA as first-line treatment were enrolled, among them 70 patients who had hypervascular HCC nodules were treated by a combination of transcatheter arterial chemoembolization and RFA therapy. RFA was repeated until an ablative margin was obtained. The rate of local tumor progression at 1 and 3 years was 4.8%, respectively. The rate of overall survival at 3 and 5 years was 83.0% and 70.0%; while the rate of

disease-free survival at 3 and 5 years was 34.0% and 24.0%, respectively. Overall survival of patients with early recurrence after RFA was significantly worse than that of patients with late recurrences. In conclusion, we consider that percutaneous RFA under the protocol reported here has the potential to provide local tumor control for small HCC. In addition to host factors, time interval from RFA to recurrence was an important determinant of prognosis.⁹

Koda et al evaluated 73 nodules treated with percutaneous ethanol injection in 49 patients with small hepatocellular carcinoma. The clinicopathologic variables examined included age, gender, Child–Pugh classification, number of tumors (single vs. multiple), tumor size, degree of tumor differentiation, ultrasonographic findings such as peripheral hypoechoic band (so-called ‘halo’), intra-tumoral echo pattern, tumor staining on enhanced computed tomography, combination therapy with transcatheter arterial embolization, and serum α -fetoprotein level. The local recurrence rates were 19%, 27%, 33%, 33%, and 33%, respectively, and the new nodular recurrence rates were 19%, 51%, 74%, 83%, and 83%, respectively at 1, 2, 3, 4, and 5 years after percutaneous ethanol injection therapy. The frequency of local recurrence was associated with the histological differentiation of more than moderately differentiated ($p = 0.001$), presence of a sonographic halo ($p = 0.005$), an intratumoral heterogeneous echo pattern ($p = 0.001$), and positive tumor staining on enhanced computed tomography ($p = 0.01$). This study showed that the presence of a halo and an intra-tumoral echo pattern on ultrasonography were useful predictors for local recurrence after PEI therapy for small hepatocellular carcinoma, and that a high serum α -fetoprotein level was associated with a higher frequency of new nodular recurrences.¹⁰

A prospective randomized control trial (RCT) was conducted by Ohnishi et al, to assess whether ultrasound-guided percutaneous acetic acid injection is superior to percutaneous ethanol injection in the treatment of small HCC. A total number of 60 patients with one to four HCCs smaller than 3 cm were enrolled in the trial. Thirty one and 29 patients, respectively, were treated by PAI using 50% acetic acid or by PEI using absolute ethanol. However, 8% of 38 tumors treated with PAI and 37% of 35 tumors treated with percutaneous ethanol injection developed a local recurrence ($p < 0.001$), respectively. The first and second year survival rates were 100% and 92% in PAI and 83% and 63% in PEI ($p = 0.0017$). A multivariate analysis of prognostic factors revealed that treatment was an independent

predictor of survival. The risk ratio of PAI versus PEI was 0.120 ($p = 0.0050$). In conclusion, the study indicates that PAI is superior to PEI in the treatment of small HCC.¹¹

Lin et al, compared the clinical outcome of percutaneous RFA, conventional PEI, and higher-dose PEI in treating HCC sized 4 cm or less. A total of 157 patients with 186 HCCs sized 4 cm or less were randomly assigned to 3 groups (52 patients in the conventional PEI group, 53 patients in the higher-dose PEI group, and 52 patients in the RF group). Clinical outcomes in terms of complete tumor necrosis, overall survival, local tumor progression, additional new tumors, and cancer-free survival were compared across 3 groups. The rate of complete tumor necrosis was 88% in the conventional PEI group, 92% in the higher-dose PEI group, and 96% in the RF group. Significantly fewer sessions were required to achieve complete tumor necrosis in the RF group than in the other 2 groups ($p < 0.01$). The local tumor progression rate was lowest in the RF group (vs. the conventional PEI group, $p = 0.012$; vs. the higher-dose PEI group, $p = 0.037$). The overall survival rate was highest in the RF group (vs. the conventional PEI group, $p = 0.014$; vs. the higher-dose PEI group, $p = 0.023$). The cancer-free survival rate was highest in the RF group (vs. the conventional PEI group, $p = 0.019$; vs. the higher-dose PEI group, $p = 0.024$). From the above mentioned study, we concluded that RFA yields better clinical outcomes than conventional and higher-dose PEI in treating HCC sized 4 cm or less.¹²

Lin et al, compared the outcomes of RFTA, PEI, and PAI in the treatment of HCC. A total of 187 patients with HCCs of 3 cm or less were randomly assigned to RFTA ($n = 62$), PEI ($n = 62$), or PAI ($n = 63$). Tumor recurrence and survival rates were assessed. RFTA was superior to PEI and PAI with respect to local recurrence, overall survival, and cancer-free survival rates, but RFTA also caused more serious complications.¹³

Shiina et al, compared RFA and PEI in RCT. The study included 232 patients with hepatocellular carcinoma who had 3 or fewer lesions, each 3 cm or less in diameter, and liver function of Child–Pugh class A or B. The primary end point was survival rate and the secondary end points were overall recurrence and local tumor progression. The number of treatment sessions was lesser (2.1 times vs. 6.4 times, respectively, $p < 0.0001$) and the length of hospitalization was shorter (10.8 days vs. 26.1 days, respectively, $p < 0.0001$) in RFA than in PEI. Four year survival rate was 74% in RFA and 57% in PEI. RFA had 46% smaller risk of

death ($p = 0.02$), 43% smaller risk of overall recurrence ($p = 0.0009$), and 88% smaller risk of local tumor progression ($p = 0.006$) than PEI. The incidence of adverse events was not different between both therapies.¹⁴

A RCT, which was conducted by Brunello et al, compared PEI, the standard approach which has been used for many years to treat early non-surgical HCC in cirrhotic patients, and RFA, which has become an interesting alternative treatment. The trial evaluated 139 cirrhosis patients in Child-Pugh classes A/B with 1-3 nodes of HCC (diameter 15-30 mm), for a total of 177 lesions. Patients were randomized to receive RFA ($n = 70$) or PEI ($n = 69$). The primary end-point was complete response (CR) 1 year after the percutaneous ablation of all HCC nodes identified at baseline. Secondary end-points were: early (30-50 days) CR, complications, survival and costs. The study result demonstrated that in the intention-to-treat analysis, 1-year CR was achieved in 46/70 (65.7%) and in 25/69 (36.2%) patients treated by RFA and PEI, respectively ($p = 0.0005$). For lesions > 20 mm in diameter, there was a larger CR rate in the RFA group (68.1% versus 26.3%). An early CR was obtained in 67/70 (95.7%) patients treated by RFA compared with 42/64 (65.6%) patients treated by PEI ($p = 0.0001$). Complications occurred in 10 and 12 patients treated by RFA and PEI, respectively. The overall survival rate was not significantly different in the RFA versus PEI arm. There was an incremental health-care cost for each additional patient successfully treated by RFA. Thus, we could conclude from this study that the 1-year CR rate after percutaneous treatment of early HCC is significantly better with RFA than with PEI; however, a clear survival advantage has not been revealed in cirrhotic patients.¹⁵

A meta-analysis evaluating five RCTs which included 701 patients demonstrated that RFA was superior to PEI in the treatment of small HCC with respect to overall survival, 1-, 2-, and 3-year survival rates, 1-, 2-, and 3-year cancer-free survival rates, as well as tumor response. Radio frequency showed a significantly smaller risk of local recurrence.¹⁶

In a meta-analysis study, Germani et al, compared treatment modalities of radiofrequency ablation, percutaneous alcohol and acetic acid injection by identifying comparison on survival rate, recurrence rate, tumor necrosis, and complications. RFA was superior to PEI for survival ($p = 0.001$), complete necrosis of tumor and local recurrence. For tumors > 2 cm, RFA was not significantly better than PEI. PAI did not differ significantly from PEI for survival

($p = 0.18$), and local recurrence; but it required less sessions. PAI had similar outcomes, except local recurrence, to RFA in the direct and indirect comparison. In conclusion, RFA seems to be a superior ablative therapy than PEI for HCC, particularly for tumors sized > 2 cm. PAI does not differ significantly from PEI for all the outcomes evaluated. RFA and PAI have similar survival rates. For tumors sized > 2 cm, the outcome benefits comparing RFA and PEI are similar. PAI needs re-evaluation versus both PEI and RFA for > 2 cm tumors.¹

Yang et al, reported their retrospective study that evaluated effectiveness and safety of combined RFA and transcatheter arterial chemoembolization (TACE) treatment for recurrence of HCC post hepatectomy and compared them to single modality. A total of 103 patients were included and divided into RFA group, TACE group and combination RFA and TACE group. Survival rate among combination RFA and TACE group had better result compared to single TACE modality (93.5 vs. 68.6%, $p = 0.011$). Recurrence rate and survival rate of 1-, 3-, and 5-years showed better result in combined RFA and TACE modality.¹⁷

Yuen et al, reported the effectiveness of TACE for early stage and unresectable HCC. A total of 96 Child-Pugh A dan B HCC patients were included in the study. The study suggested that TACE group have better survival rate than conservative therapy.¹⁸ Kirikoshi et al, reported the effects of TACE and combined therapies (TACE + PEI or TACE + RFA) on long-term survival rates, which were evaluated in 268 untreated HCC patients by using various statistical analyses. The cumulative survival rates in the TACE alone group were significantly superior to those in the palliative treatment group. Furthermore, the cumulative survival rates in the combined TACE + PEI/RFA group were significantly superior to those in the TACE alone group. When the comparison among the groups was restricted to patients with two or three tumors fulfilling the Milan criteria, significantly greater prolongation of survival was observed in the combined TACE + PEI/RFA group than in the PEI/RFA alone group. From this study, we conclude that the aforementioned treatment modalities yield greater improvements on the survival rate and survival duration as compared to palliative treatment in HCC patients. Moreover, in terms of the effect on survival period, combined TACE + PEI/RFA therapy was more effective than TACE monotherapy, and also more effective than PEI or RFA monotherapy in cases with multiple tumors fulfilling the Milan criteria.¹⁹

Percutaneous ablation under ultrasound guidance is currently the best therapy for early-stage HCC when

resection or liver transplantation is not possible. PEI with 95% alcohol and RFA result in complete necrosis of 95% of tumors sized < 2 cm, but only 50% when applied to tumors with 3–5 cm diameter, with survival rate of > 50% at 5 years. The best candidates are patients in Child-Pugh A stage with small HCC.¹

PEI is cheap, well-tolerated, simple to perform, and does not require a general anesthetic agents. Severe complications are infrequent at 0–2%, including seeding. There are some reasons for this. First, tumor necrosis is heterogeneous because ethanol does not diffuse uniformly within the nodule due to internal septa in 33% of nodules and encapsulation of the tumor.¹ Second, ethanol is diluted by vascular washout; and third, the needle is not centrally positioned.

Acetic acid used as a 50% solution is as cheap as alcohol. Moreover, it penetrates and destroys intra-nodule septa due to its low pH and breaks down lipid and collagen fibers within intra-tumoral septa and capsules, which often contain cancer cells. PAI is performed as easily and safely as PEI, and it requires fewer treatment sessions.^{1,9}

In order to decrease the risk of local recurrence, combined RFA and TACE treatment is recommendable; while to reduce late recurrence, the most effective therapy is decreasing relapse rate by using polyphenolic acid and interferon.⁹

HCC resection could be performed safely in non-cirrhotic patients. The best candidates to undergo resection is patients with solitary tumor, asymptomatic patients with good liver function (BCLC stage A1), and the 5-year survival rate is 70%.⁴

Neoplastic cells destruction could be achieved by using chemical substance (alcohol, acetic acid) or by modifying the temperature (radiofrequency, microwave, laser and cryoablation). PEI is the procedure of choice for small tumor due to its high efficacy, minimal complications, and low cost. The mechanisms of PEI include dehydration, vascular occlusion, and fibrosis. Indication for PEI is small sized tumor (diameter < 5 cm), cirrhotic patients with Child-Pugh A stage and unresectable tumor. The survival rate of patients who had PEI may increase up to 50%. RFA shows higher success rate than PEI; however, it has more complications and higher cost.

CONCLUSION

Early stage of HCC could be treated with curative treatment such as ablative therapies using PEI, PAI or RFA, and surgical resection or liver transplantation.

RFA is more effective and safer than other modalities of local ablative therapies. RFA should be considered as the first-line treatment for patients with small HCC, who are not suitable for liver resection or liver transplantation. RFA should also be compared to transarterial embolization, which currently has been considered as the standard HCC therapy in some countries. It has been reported that the combination of RFA and embolization treatment may reduce the early and late recurrence rate. Since there are some risks of systematic error, including the risk of bias in trials and random errors due to small sample size of the trials and there are only a few number of trials; therefore, further trials are necessary. The data on small HCC are not conclusive and further RCTs should be performed comparing RFA, PEI and PAI.

REFERENCES

1. Germani G, Pleguezuelo M, Gurusamy K, Meyer T, Isgrò G, Burroughs AK. Clinical outcomes of radiofrequency ablation, percutaneous alcohol and acetic acid injection for hepatocellular carcinoma: a meta-analysis. *Hepatology* 2010;52:380–8.
2. Ferenci P, Fried M, Labrecque D, Bruix J, Sherman M, Omata JM, et al. Hepatocellular carcinoma (HCC): a global perspective. *J Clin Gastroenterol* 2010;44:239–45.
3. Llovet JM, Bruix J. Novel advancements in the management of hepatocellular carcinoma in 2008. *J Hepatol* 2008;48:S20–37.
4. Lau WY, Lai EC. The current role of radiofrequency ablation in the management of hepatocellular carcinoma: a systematic review. *Ann Surg* 2009;249:20–5.
5. Llovet JM, Fuster J, Bruix J. The Barcelona approach: diagnosis, staging, and treatment of hepatocellular carcinoma. *Liver Transpl* 2004;10:S115–20.
6. Luo TI, Huang YH, Wu JC, Lee PC, Chang FY, Lee SD. Comparison of percutaneous acetic acid injection and percutaneous ethanol injection for hepatocellular carcinoma in cirrhotic patients: a prospective study. *Scand J Gastroenterol* 2003;38:770–8.
7. Sala M, Llovet JM, Vilana R, Bianchi L, Sole M, Ayuso C, et al. Initial response to percutaneous ablation predicts survival in patients with hepatocellular carcinoma. *Hepatology* 2004;40:1352–60.
8. Livraghi T, Goldberg SN, Lazzaroni S, Meloni F, Solbiati L, Gazelle GS. Small hepatocellular carcinoma: treatment with radio-frequency ablation versus ethanol injection. *Radiology* 1999;210:655–61.
9. Waki K, Aikata H, Katamura Y, Kawaoka T, Takaki S, Hiramatsu A, et al. Percutaneous radiofrequency ablation as first-line treatment for small hepatocellular carcinoma: results and prognostic factors on long-term follow up. *Gastroenterol Hepatol* 2010;25:597–604.
10. Koda M, Murawaki Y, Mitsuda A, Ohyama K, Horie Y, Suou T, et al. Predictive factors for intrahepatic recurrence after percutaneous ethanol injection therapy for small hepatocellular carcinoma. *Cancer* 2000;88:529–37.
11. Ohnishi K, Yoshioka H, Ito S, Fujiwara K. Prospective randomized controlled trial comparing percutaneous acetic acid injection and percutaneous ethanol injection for small

- hepatocellular carcinoma. *Hepatology* 1998;27:67–72.
12. Lin SM, Lin CJ, Lin CC, Hsu CW, Chen YC. Radiofrequency ablation improves prognosis compared with ethanol injection for hepatocellular carcinoma \leq 4 cm. *Gastroenterology* 2004;127:1714–23.
 13. Lin SM, Lin CJ, Lin CC, Hsu CW, Chen YC. Randomized controlled trial comparing percutaneous radiofrequency thermal ablation, percutaneous ethanol injection, and percutaneous acetic acid injection to treat hepatocellular carcinoma of 3 cm or less. *Gut* 2005;54:1151–6.
 14. Shiina S, Teratani T, Obi S, Sato S, Tateishi R, Fujishima T, et al. A randomized controlled trial of radiofrequency ablation with ethanol injection for small hepatocellular carcinoma. *Gastroenterology* 2005;129:122–30.
 15. Brunello F, Veltri A, Carucci P, Pagano E, Ciccone G, Moretto P, et al. Radiofrequency ablation versus ethanol injection for early hepatocellular carcinoma: a randomized controlled trial. *Scand J Gastroenterol* 2008;43:727–35.
 16. Orlando A, Leandro G, Olivo M, Andriulli A, Cottone M. Radiofrequency thermal ablation vs. percutaneous ethanol injection for small hepatocellular carcinoma in cirrhosis: meta-analysis of randomized controlled trials. *Am J Gastroenterol* 2009;104:514–24.
 17. Yang W, Chen MH, Wang MQ, Cui M, Gao W, Wu W, et al. Combination therapy of radiofrequency ablation and transarterial chemoembolization in recurrent hepatocellular carcinoma after hepatectomy compared with single treatment. *The Japan Society of Hepatology. Hepatol Res* 2009;39:231–40.
 18. Yuen MF, Chan AO, Wong BC, Hui CK, Ooi GC, Tso WK, et al. Transarterial chemoembolization for inoperable, early stage hepatocellular carcinoma in patients with Child-Pugh grade A and B: results of a comparative study in 96 Chinese patients. *Am J Gastroenterol* 2003;98:1181–5.
 19. Kirikoshi H, Saito S, Yoneda M, Fujita K, Mawatari H, Uchiyama T, et al. Outcome of transarterial chemoembolization monotherapy, and in combination with percutaneous ethanol injection, or radiofrequency ablation therapy for hepatocellular carcinoma. *Hepatol Res* 2009;39:553–62.

Correspondence:
Andri Sanityoso Sulaiman
Division of Hepatology, Department of Internal Medicine
Dr. Cipto Mangunkusumo General National Hospital
Jl. Diponegoro No. 71 Jakarta 10430 Indonesia
Phone: +62-21-39100924 Facsimile: +62-21-3918842
E-mail: andri_sani@yahoo.com
