

# Primary Hepatic Lymphoma in a 32-Year-Old Male

Nurria B Indriyaningrum\*, Syifa Mustika\*\*

\*Faculty of Medicine, University of Brawijaya/Saiful Anwar Hospital, Malang

\*\*Division of Gastroentero-hepatology, Department of Internal Medicine, Faculty of Medicine, University of Brawijaya/Saiful Anwar Hospital, Malang

## Corresponding author:

Syifa Mustika. Division of Gastroentero-hepatology, Department of Internal Medicine, Dr. Saiful Anwar General Hospital. Jl. Jaks Agung Suprpto No. 2 Malang Indonesia. Phone: +62-341-362101; facsimile: +62-341-369384. E-mail: drtika\_78@yahoo.com.

## ABSTRACT

A 32-year-old male came with right upper abdominal pain with a mass increasing in size since the last 6 months, with no other typical symptoms. The physical findings revealed right upper abdominal mass, rubbery consistence, irregular surface, rounded edge, unclear border, immobile, without any tenderness. Other physical examination revealed normal findings, without any lymphadenopathy at another site. The laboratory findings revealed non-reactive hepatitis B and C markers, normal alpha-fetoprotein (AFP), slightly increased lactate dehydrogenase (LDH). Plain chest X-ray showed elevated right hemidiaphragm, and a large mass sized  $\pm 14.18 \times 8.56 \times 12.56$  cm compressing the liver. We've done biopsy with ultrasound guiding on the mass, and the histological examination revealed that it was lymphoma with negative CD20. The diagnosis was established as primary hepatic lymphoma and the patient was then given chemotherapy.

**Keywords:** primary hepatic lymphoma, CD20 negativity, young adult

## ABSTRAK

Seorang pria berusia 32 tahun datang dengan nyeri dan adanya massa pada perut bagian kanan atas yang dirasakannya makin membesar sejak 6 bulan terakhir, tanpa disertai gejala lain. Hasil pemeriksaan fisik didapatkan adanya massa abdomen bagian kanan atas, konsistensi padat kenyal, permukaan tidak rata, tepi tumpul, batas tidak jelas, tidak dapat digerakkan dan tidak nyeri. Pemeriksaan fisik lain didapatkan normal dan tidak ada pembesaran kelenjar getah bening di tempat lain. Pemeriksaan penunjang menunjukkan penanda hepatitis B dan C tidak reaktif, alpha-fetoprotein (AFP) normal, lactose dehydrogenase (LDH) sedikit meningkat. Secara radiologis, dari foto toraks polos ditemukan hemidiafragma kanan meninggi, dan didapatkan tumor besar berukuran  $\pm 14.18 \times 8.56 \times 12.56$  cm yang menekan hati. Telah dilakukan biopsi pada massa tersebut dan hasilnya adalah suatu limfoma dengan CD20 yang negatif. Diagnosis ditegakkan sebagai limfoma hepar primer dan pasien menjalani kemoterapi.

**Kata kunci:** limfoma hepar primer, CD20 negatif, dewasa muda

## INTRODUCTION

Liver is the largest reticuloendothelial organ in the human body. Thus, not surprising that liver often involved in non-Hodgkin lymphoma. But, liver

involvement without any sign of spleen, lymphnodes, marrow or other lymphoid structure involvement is very rare, known as primary hepatic lymphoma (PHL).<sup>1</sup>

Primary hepatic lymphoma (PHL) is a very rare malignancy, only about 0.016% occurrence from

overall of non-Hodgkin lymphoma case. Mostly originated from B-cell, and rarely from T-cell. Often misdiagnosed and mistreated, and several reports of unnecessary resection. Most patients with PHL treated with chemotherapy using many combinations of regimen. But, the optimal treatment is still unclear with undefined outcome.<sup>2</sup>

Majority of the PHL patients are middle-aged males with usually non-specific symptoms. The diagnosis of PHL needs liver biopsy with histological description suitable with lymphoma, without any other lymphoproliferative disease outside the liver.<sup>3</sup> Differential diagnosis for hepatic lesion, with no involvement of blood vessels are: fatty infiltration, amyloid infiltration, primary hepatoma and metastatic neoplasm.<sup>2</sup>

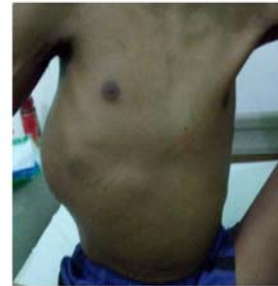### CASE ILLUSTRATION

A 32-year-old male came with right upper abdominal pain with mass increasing in size since the last 6 months. It was felt hardened of the right upper abdominal, which was getting bigger with increasing intensity of pain. The pain was felt continuously all the day until he could not do his daily activity and disturbance in resting. He also had decreased of appetite due to the fullness sensation every time he tried to eat. He only able to eat 2-3 spoonful of food each time. He had reduced amount of urine and decreased frequency of bowel movement. He felt nausea and sometimes vomit small amount of liquid. He had decreased of body weight, around 5 kg within the last 2 weeks.

This patient had been hospitalized previously due to the same complaint. The first was at October 2015, when he was referred from a private hospital with suspicion towards hepatoma with differential diagnosis of liver abscess. We tried to aspirate the mass with hypoechoic lesion, but there was no fluid inside. The patient was discharged with analgetic and planned for further workup at outpatient department. But, he was lost to follow up, and re-hospitalized at December 2015 due to increasing pain. We then done the biopsy at the mass with the result of lymphoma. He was suggested to start the chemotherapy immediately, but he refused and chose complementary medication instead.

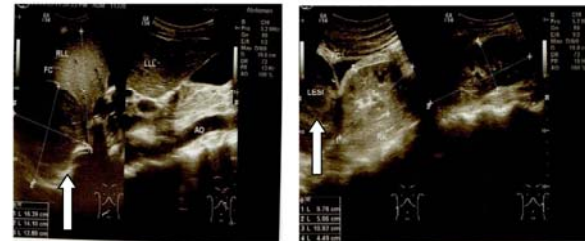He returned at April 2016 with massive increase of the abdominal mass and more severe pain. He had no previous history of significant illness. He was a farmer, married, with 2 children. Physically he looked moderately ill, cachectic, and bulging at his right upper abdominal area. The mass was rubbery,

irregular surface, rounded edge, indefinite margin, immobile, without tenderness in palpation. Other physical findings were within normal limit, without any lymphnode enlargement at other sites.

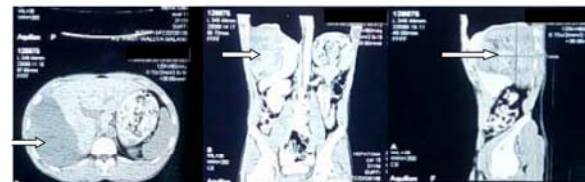

**Figure 1.** Patient looked cachectic, with mass bulging at his right upper abdominal area

Laboratory examination revealed no significant findings, with hemoglobin level 13.8 g/dL, white blood cell 13,640/ $\mu$ L without blast cell, thrombocytes 523,000/ $\mu$ L, AST 46 U/L, ALT 18 U/L, albumin level was 3.0 g/dL, AFP 2.2, LDH 732 IU/L, with non-reactive result of hepatitis B and C marker. The abdominal ultrasound and CT-scan revealed a mass sized 14.18x8.56x12.56 cm as shown in Figure 2 and 3.



**Figure 2.** Abdominal ultrasound showing a solid, heterogeneous and hypoechoic mass, clear border, almost at all of the right lobe, including segment 5,7,8, with impression of adhering to right diaphragm. Size  $\pm$  14.18x8.56x12.56 cm, with vascularization inside the mass. Portal/vascular/biliary system was not dilated.

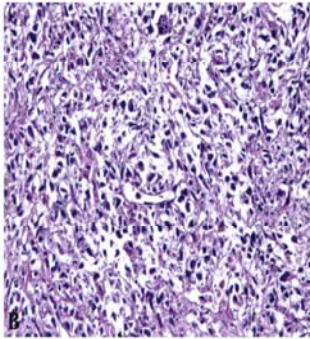


**Figure 3.** Abdominal CT with and without contrast revealed a heterogeneous nodule without any enhancement of the contrast. The nodule was located laterally to the liver, size  $\pm$  14,18x8,56x12,56 cm, clear border, pressing the liver.

Based on those data, initially we suggest that this patient had liver abscess. We tried to drain the abscess with ultrasound guiding, but there was no liquid within the mass. The patient then underwent



biopsy of the nodule and sent to pathological laboratory for further examination.



**Figure 4. Histological finding with 400x magnification showing large sized lymphoid cells infiltration with further immunohistochemistry staining showed negative CD20.**

According to those results, this patient fulfilling the diagnostic criteria of PHL: (1) Initial symptoms of the patient mostly caused by liver involvement; (2) No palpable lymphadenopathy and no distant lymphadenopathy from radiological evaluation; (3) No leukemic representation from the peripheral blood analysis. In addition to histological findings, this patient then diagnosed as primary hepatic lymphoma with cancer pain.

From several literatures reporting some studies about PHL patients, there were some factors influencing the prognosis: (1) Serum LDH level > 10% above normal limit; (2) Serum  $\beta$ -2-microglobulin level > 3 mg/L (normal: 0.6-2 mg/L); (3) Largest tumor mass > 7 cm; (4) Constitutional symptoms exist; (5) Ann Arbor stage III or IV. This patient included as high risk for relapse.

## DISCUSSION

The real incidence and prevalence of PHL itself is unknown. But it is clearly very rare and only 0.4% of overall extranodal NHL, and 0.016% of overall NHL cases. With increasing NHL incidence the occurrence of PHL predicted to be increased as well. Diagnostic criteria of PHL that has been generally accepted is from Lei et al, consist of: (1) Initial symptoms of the patient mostly caused by liver involvement; (2) No palpable lymphadenopathy and no distant lymphadenopathy from radiological evaluation; (3) No leukemic representation from the peripheral blood analysis.

In addition to the above criteria, liver biopsy with histological description suggesting lymphoma, without other lymphoproliferative disease outside the liver. PHL primarily occur in middle-aged, around 50 years

old (range: 21-75 years old) with male to female ratio 1.7:1. The chief complaint is variable, most often is abdominal pain (70% of the patients).<sup>1</sup>

This patient is a young male, aged 32 years old, came with chief complaint abdominal pain at the right upper quadrant. From physical examination revealed a considerable mass at the right upper abdomen, initially suspected as hepatoma with differential diagnosis of liver abscess. Other symptoms were insignificant, only anorexic, weakness and decreased of body weight. These signs were suitable with epidemiological distribution of PHL that usually affecting middle-aged males. No other lymphadenopathy at the other sites, nor leukemic description from the peripheral blood smear. With negative serological markers of hepatitis and normal value of AFP, the suspicion to PHL should be emerged sooner. But, due to the rare incidence of PHL and radiological findings supporting to liver abscess, this patient was initially managed as liver abscess. And after the possibility of hepatoma and liver abscess was excluded, this patient had biopsy of the mass and further histopathological examination.

Etiopathogenesis of the PHL is still unknown, possibly involving several factors. Some recent reports showing relationship between the increasing incidence of PHL with hepatitis C virus (HCV) infection. Other virus possibly involved in the pathogenesis of PHL are Epstein-Barr virus (EBV) and HIV. EBV is important particularly in post-transplant patients, where reactivation of EBV will induce the onset of PHL. Also there are reports of PHL in HIV patients, transplantation recipient with cyclosporine therapy and lupus erythematosus (SLE) patients.<sup>1</sup>

The possibility of hepatitis B and C infection in this patient has already excluded since the initial examination. But, the detection of any EBV or HIV infection should be further evaluated. Although clinically patient did not look immunocompromised nor any sign of autoimmune disease, a comprehensive laboratory assessment should ideally be done, particularly if there are any sign of infection or any other underlying condition, in order to obtain successful treatment and favourable outcome.

Laboratory findings usually reveal normal in comparison with secondary hepatic lymphoma, because no bone marrow involvement in PHL. If there are abnormal results, suggesting that it was a secondary hepatic lymphoma or due to splenomegaly secondary to liver dysfunction in PHL. Level of serum AST, ALT, ALP and bilirubin do not show a significant increase. Increased LDH showing tissue necrosis, found in

30-80% patients. Level of  $\beta$ -2-microglobulin found increased in 90% patients. CRP and LED elevated in one-third of the patients. Tumor marker such as AFP and CEA are not elevated, and this will distinguish primary liver cancer from metastatic process to the liver.<sup>1,5</sup>

Laboratory findings of this patient also shows no abnormality since the beginning. Ideally, should be done marrow biopsy to exclude marrow involvement. But, since this patient has already in pain and uncomfortable with his condition, and from the peripheral examination did not show any abnormality, we considered that bone marrow biopsy for this patient was not necessarily done at that time.

Radiologically, PHL presents in three forms: (1) Solitary lesion; (2) Multiple lesion in the liver; (3) Diffuse hepatic infiltration. The description is not specific, could present as hypovascular metastatic nodule. Malignant neoplasm of the colon, gaster, lung, prostate and transitional cell are primary tumors that most often having metastatic process to the liver with hypovascular lesions. Infections (such as mycosis and TB) and inflammation (such as sarcoidosis) sometimes present radiologically as multifocal hepatic lesions. From ultrasound examination, PHL mostly giving hypoechoic lesion compared to the surrounding normal liver parenchym due to high cellularity and less stromal. From CT examination with contrast, 50% does not have enhancement, 33% have patchy enhancement and 16% have ring pattern enhancement. PET scan examination shows increased uptake of FDG at the lesion. PET scan can exclude secondary liver lymphoma.<sup>1,4</sup>

Radiological result of this patient also did not show any significant findings. It was hypoechoic lesion without enhancement of the contrast. The lesion was solitary nodule, but it was bulky and pressing the liver, bulging outward and pushing the diaphragm upward. At first admission, the mass that this patient had was not as big as at the last admission. With radiologically hypoechoic lesion, the suspicion was tend to be liver abscess. But, after no liquid revealed after aspiration, we excluded the liver abscess and work-up this patient as solid mass of the liver. PET scan was not done due to limitation of infrastructure in our hospital.

PHL could be Hodgkin or non-Hodgkin, but NHL is more commonly found. Immunophenotypically, B cell is more frequently found compared to T cell (63% and 25% consecutively). Microscopically it can present as diffuse pattern or nodular pattern. Nodular pattern considered to have more severe damage to the

liver. Differential diagnosis for PHL includes primary hepatic tumor, metastatic process to the liver, and systemic lymphoma with secondary liver involvement. PHL can also presenting as acute liver failure. Immunohistochemistry assessment, flowcytometry and karyotyping are important to establish the accurate diagnosis.<sup>1,5,7</sup>

Histopathological finding from nodule biopsy of this patient showed spreading of large sized cell, rounded, uniform, hyperchromatic, with conclusion suggesting to non-Hodgkin lymphoma. But, from CD20 examination revealed negative result, while other immunohistochemistry examination (LCA and Vimentin) could not be done because of the insufficient amount of tissue sample. Ideally, we should do a second biopsy to confirm the diagnosis with proper examination, but considering the large mass causing discomfort to the patient, we chose prompt management by giving chemotherapy with expectation to reduce the size of the bulky mass.

Considering that PHL is extremely rare, the chemotherapy protocol used to treat PHL is according to case reports or case series. The choices of treatment are: (1) Surgery; (2) Chemotherapy; (3) Radiation; (4) Combination. The factors influencing the outcome of PHL patient are: (1) Old age; (2) Low performance scale; (3) Bulky disease; (4) Histologically unfavourable; (5) High LDH level; (6) Comorbid condition; (7) Immunosuppression condition. From a serial case of 14 patients that have surgical therapy followed by adjuvant chemotherapy showed median survival rate of 20.7 months. While from another retrospective cohort study towards 24 patients showed that risk factors prior to therapy as followed: (1) Serum LDH level > 10% above normal limit; (2) Serum  $\beta$ -2-microglobulin level > 3 mg/L (normal: 0.6-2 mg/L); (3) Largest tumor mass > 7 cm; (4) Constitutional symptoms exist; (5) Ann Arbor stage III or IV.

If the patient has none of the above risk factors, the patient considered to have low risk of recurrence, and treated with CHOP chemotherapy. If the patient has at least one risk factor, he considered as high risk of relapse and should be treated with alternating combination chemotherapy (doxorubicin, methylprednisolone, cytosine arabinoside and cisplatin; alternating with metothrexate, bleomycin, cyclophosphamide, doxorubicin, vincristine and methylprednisolone; alternating with messna, iphosphamide, mitoxantrone and etoposide). With this regimen the overall complete remission reaches 83.1% (100% for patients treated with alternating triple therapy).<sup>1,8-10</sup> According to many



factors found in this patient, we consider this patient as poor prognosis.

## CONCLUSION

We reported a case of young male with a CD20-negative PHL. PHL is a rare condition with non-specific clinical symptoms, laboratory, radiological and initial histopathological findings, that make establishing the diagnosis of PHL is a real challenge. Clinical criteria of PHL in addition to immunohistochemistry examination of biopsy is absolutely necessary to define the type of the cell and decide therapy choice with best outcome. Prompt diagnosis and early treatment suitable with the clinical findings are important to have complete remission and optimal survival rate. Due to the late diagnosis of this patient and uneducated family, we lost contact of this patient and therefore the prognosis is predicted as unfavourable.

## REFERENCES

1. Padhan RK, Das P, Shalimar. Primary Hepatic Lymphoma. *Trop Gastroenterol* 2015;36:14-20.
2. Resende V, Oliveira TS, Gomes RT, Laboissiere RS, Tavares-Junior WC, de Melo Couto OF. Primary hepatic lymphoma: a case report. *Int J Surg* 2013;4:1165-8.
3. Zentar A, Tarchouli M, Elkaoui H, Belhamidi MS, Ratbi MB. Primary Hepatic Lymphoma. *J Gastrointest Canc* 2014;45:380-2.
4. Steller EJA, van Leeuwen MS, van Hillegersberg R, Schipper MEI, Rinkes IHMB, Molenaar IQ. Primary lymphoma of the liver- a complex diagnosis. *World J Radiol* 2012;4:53-7.
5. Myoteri D, Dellaportas D, Arkoumani E, Marinis A, Zizi-Sermpetzoglou. A primary hepatic lymphoma: a challenging diagnosis. *Case Rep Oncol Med* 2014;2014:212598.
6. Patel TS, Malvania R, Gami AG. Primary hepatic lymphoma: a case report. *J Cytol* 2015;32:36-8.
7. Warner B, Bird G, Schofield J, Rassam S. Primary hepatic lymphoma: a diagnosis to remember. *J Med Cases* 2013;4:52-5.
8. Valladolid G, Adams LL, Weisenberg E, Maker VK, Maker AV. Primary hepatic lymphoma presenting as an isolated solitary hepatic cyst. *Am Soc Clin Oncol* 2012;31:e21-e23.
9. Agmon-Levin N, Berger I, Shtalrid M, Schlanger H, Sthoeger ZM. Primary Hepatic Lymphoma: A Case Report and Review of the Literature. *Age and Ageing* 2004;33:637-40.
10. Avlonitis VS, Linos D. Primary Hepatic Lymphoma: A Review. *Eur J Surg* 1999;165:725-9.