

17 Year Old Female Patient with Systemic Lupus Erythematosus and Ulcerative Colitis

*Rizky Amelia**, *Supriono***

* Department of Internal Medicine, Faculty of Medicine

University of Brawijaya/Dr. Saiful Anwar General Hospital, Malang

** Division of Gastroentero-hepatology, Department of Internal Medicine

Faculty of Medicine, University of Brawijaya/Dr. Saiful Anwar General Hospital, Malang

ABSTRACT

Gastrointestinal manifestations are common in systemic lupus erythematosus (SLE). Although the relationship between SLE with ulcerative colitis (UC) rarely obtained, SLE patients with gastrointestinal manifestations should preferably be evaluated for the possibility of an inflammatory bowel disease (IBD). UC prognosis associated with SLE is usually good, whereas by proper diagnosis and management, the clinical output and a good life expectancy of patients will be obtained

A young female, 17 years old, who had previously been diagnosed with SLE for 5 years, came with complaints of abdominal pain and chronic diarrhea. From the results of colonoscopy and biopsy of the intestinal mucosa was noted that in accordance with UC. After receiving treatment for 6 days, she no longer obtained complaints of abdominal pain and diarrhea.

Keywords: *systemic lupus erythematosus, gastrointestinal, ulcerative colitis, inflammatory bowel disease*

ABSTRAK

Manifestasi gastrointestinal merupakan hal yang sering terjadi pada lupus eritematosus sistemik (LES). Meskipun hubungan antara LES dengan kolitis ulseratif (KU) jarang didapatkan, sebaiknya pada pasien LES dengan manifestasi gastrointestinal dilakukan evaluasi untuk kemungkinan adanya suatu penyakit inflamasi usus besar. Prognosis UC terkait LES biasanya baik, dimana dengan diagnosis dan penatalaksanaan yang tepat akan didapatkan keluaran klinis dan harapan hidup yang baik pada pasien.

Seorang perempuan muda berusia 17 tahun yang sebelumnya telah terdiagnosa LES selama 5 tahun, datang dengan keluhan nyeri perut dan diare kronik. Dari hasil pemeriksaan kolonoskopi dan biopsi mukosa usus didapatkan gambaran yang sesuai dengan KU. Setelah mendapat terapi selama 6 hari, tidak didapatkan lagi keluhan nyeri perut dan diare.

Kata kunci: *lupus eritematosus sistemik, gastrointestinal, colitis ulseratif, penyakit inflamasi usus besar*

INTRODUCTION

Systemic lupus erythematosus (SLE) and inflammatory bowel disease (IBD) are systemic diseases caused by abnormal immune response, depending on the interaction between genetic vulnerability and environmental factor.¹ Gastrointestinal manifestation is commonly found in SLE. Although not as common as nephritis lupus, clinically SLE-associated

gastrointestinal involvement is significant because most of these cases may become life-threatening if not being treated promptly. Anorexia, nausea, vomiting, dysphagia, abdominal pain, diarrhea, digestive tract bleeding are symptoms which happen to approximately 50% patients with SLE.² Persistent diarrhea occurring due to ulcerative colitis (UC), which is also one of the IBDs, is reported in several studies to be associated

with SLE.³ UC also has strong relation with the occurrence of autoimmune diseases.⁴ Dubois et al reported SLE cases with diarrhea as much as 5.9%,⁵ Fries et al stated 25%,⁶ Jessar et al 13%,⁷ while Harvey et al 8%.⁸ This case report will discuss about the diagnosis and management of SLE and UC.

CASE ILLUSTRATION

A 17 year old female came with the complaint of watery stool since 2 days before hospital admission with the frequency of 5-8 times per day, with mucous in the faeces. Patient also complained of lethargic and looked pale. Pain was felt in the lower abdominal area every time before diarrhea and subsided after diarrhea. Appetite was decreased due to stomach fullness. Seventeen days earlier, patient was also admitted to the hospital with similar symptoms. Patient had been diagnosed with SLE since 2007, routinely visited the Internal Medicine Outpatient Clinic, Saiful Anwar Hospital for check-up and had received therapies azathioprine 50 mg twice daily, metilprednisolone with the dose of 8 mg twice daily. Besides, patient had also received captopril 6.25 mg thrice daily and calcium supplement once daily.

From physical examination, it was found that Glasgow coma scale (GCS) 4/5, blood pressure 90/60 mmHg, axilla temperature 36.5°C, heart rate 88 bpm, respiratory rate 24 times per minute, patient looked moderately ill, underweight and moonface. Body weight 33 kg, height 156 cm, BMI 13.56 kg/m². From head examination, there was anemic conjunctiva, cloudy in bilateral ocular lenses and malar rash. From chest examination, it was found that right heart border was in right SL and left heart border in 5th ICS left MCL, ictus cordis was seen, palpable at 5th ICS left MCL. Lungs examination was within normal limits. From inspection of the abdomen, we found that there was 8 cm scar in the right lower region, increased bowel sound. Extremities examination was within normal limits. Urine production was 62 mL/hour.

Laboratory examination revealed hemoglobin (Hb) 8.7 g/dL, leukocyte 6,900/uL, lymphocyte 500/uL, thrombocyte 300,000/uL, erythrocyte sedimentation rate (ESR) 68 mm/hour, aspartate transaminase (AST) 29 U/L, alanine transaminase (ALT) 12 U/L, random blood glucose 113 mg/dL, albumin 2.20 g/dL, ureum 41.2 mg/dL, creatinine 0.9 mg/dL, serum electrolyte natrium 136 mmol/L, kalium 4.5 mmol/L, chloride 109 mmol/L. Plasma mass density \leq 1.024. Urinalysis mass density 1.020, pH 6.5, protein albumin +1, erythrocyte

3+, 10x = epithel 1-2/SPF, 40x = erythrocyte 40-50/HPF, leukocyte 2-4/HPF. Complete faecal analysis, white in colour, soft consistency, epithel 1+/HPF; leucocyte 0-2, cyte 2-4, *Entamoeba hystolitica* cyst was identified. Faecal culture results showed *Enterobacter gergoviae* strongly sensitive to colistin, cotrimoxazole, amoxycillin and clavulanic acid, ceftriaxone, and gentamycin antibiotics.

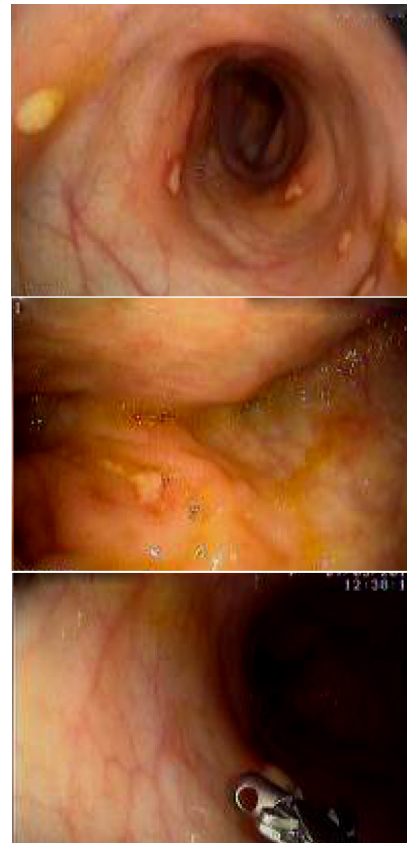

Figure 1. Colonoscopy results showed multiple ulcer and hyperemic mucosa

Colonoscopy results revealed many ulcers from the rectum until the caecum with various shapes and sizes, then biopsy from several locations was performed. Conclusion drawn was suspect of ulcerative colitis. From biopsy of 4 colon mucosa specimens, we found microscopic appearance with broad erosion, destruction of crypt, cryptitis, lamina propria, infiltration of plasma cells, lymphocytes and neutrophils, a few eosinophil cells, glands experienced mild degree of dysplasia. Some glands showed proliferative, normal blood vessels, muscular mucosa was observed, lymphoid follicles were not found, very few macrophage cells, malignant cells were not found. There were also group of plasma cells, lymphocytes and neutrophils with a conclusion of ulcerative colitis.

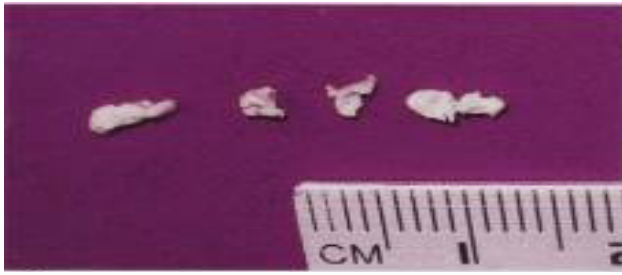

Figure 2. Macroscopic appearance of intestinal mucosa biopsy which was performed in several places

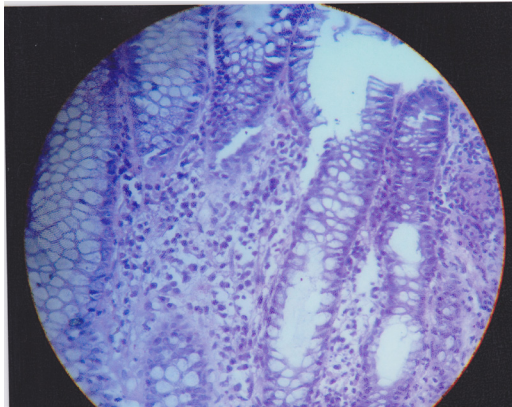


Figure 3. Macroscopic and microscopic pictures of intestinal mucosa biopsy showed erosion and crypt destruction with inflammatory cells infiltration

Problem list in this patient include chronic inflammatory diarrhea caused by IBD, SLE on treatment, immature cataract one day care surgery (ODS), and malnutrition. Patient received therapy; 1900 kcal per day low fiber diet, intravenous injection of ceftriaxone 1 gram twice daily, orally administered medicine metilprednisolon 8 mg twice daily, azathioprine 50 mg twice daily, captopril 6.25 mg thrice daily, and attapulgit 2 tablets per diarrhea, maximal 12 tablets per day. Therapy response after 6 days with those medicines mentioned above was evaluated, patient's general condition ameliorated, no more complaint of stomachache or diarrhea.

DISCUSSION

SLE may manifest in the entire gastrointestinal tract.⁹ SLE and UC are chronic autoimmune diseases with the characteristic of relapse and remission episodes.^{1,10} The presence of SLE with inflammatory gastrointestinal disease is a frequently questioned phenomenon, but is rarely associated.⁹ The relationship between SLE and UC is very rare and has only been documented in several case reports. Dubois et al found 2 cases from 520 patients.⁵ Other studies reported the association in 2 cases from 464 patients and other literature studies stated most colitis precede the

occurrence of SLE.¹¹ Estimated prevalence of UC in SLE patients is $\pm 0.4\%$ and Crohn's disease is even less than that.^{2,12,13} It is also reported by Snook et al in a study of 1,200 IBD patients, 6.6% patients with UC had at least another one autoimmune abnormality.¹²

Coexistence of SLE and IBD is difficult to diagnose because both diseases have several similar gastrointestinal symptoms and some drugs used to treat IBD may cause drug-induced lupus.² Diagnosing IBD in SLE is quite challenging due to several factors. First, almost 50% SLE patients have gastrointestinal symptoms, the most common is stomachache.⁸ Second, UC may happen before or after the diagnosis of SLE.² In most cases, diagnosis of SLE is confirmed before IBD. The first disease is usually inactive in the manifestation of the second disease. Patient with both processes tends to experience less photosensitive, serositis, and neurological disturbance, and in general has relative good prognosis from both SLE and IBD.^{2,13} In this patient, diagnosis of SLE was confirmed before colitis was diagnosed. This showed that UC occurred in idiopathic SLE. In a case of chronic diarrhea, it may be found two or more etiologies and or pathophysiology of diseases. Colonoscopy is not routinely performed in every chronic diarrhea cases, however it helps to confirm the main diagnosis in pathology anatomy through intestinal mucosa biopsy.¹⁴ In this patient, colonoscopy results revealed suspect of UC and was supported with the intestinal mucosa biopsy results; there was broad erosion, destruction of crypt, cryptitis, lamina propria, infiltration of plasma cells, lymphocytes and neutrophils, few eosinophil cells, glands experienced mild degree of dysplasia. Some glands showed proliferative, normal blood vessels, muscular mucous was observed, no lymphoid follicles were found, very few macrophage cells, no malignant cells were found. There was also groups of plasma cells, lymphocytes, and neutrophils.

Hoffman et al in their review regarding gastrointestinal manifestations in SLE found that there was no clear border in idiopathic cases of SLE which was associated with UC.¹⁵ Some differences between sulphasalazine-induced SLE (in UC patients) and incidence of UC in idiopathic SLE are the presence of low amount of complements (in drug-induced lupus, complement value is generally normal) and negative dsDNA.⁴ Besides, idiopathic SLE is accompanied with the presence of various types of autoantibodies, such as: collagen-like receptor (CLR) to C1q which present in approximately 47% patients with SLE, anticardiolipin antibody (in 10-30% SLE patients),

anti Ro, anti-La antibody, human leukocyte antigen (HLA) DR3 are associated with idiopathic SLE, while HLA DR4 may be found in drug induced lupus.¹⁶ In this patient, those autoantibodies were not examined due to financial reason and limitations in the examination procedure.

Severity degree of UC is based on patient's symptoms and to the area of colitis, not to the severity degree of inflammation histologically. Based on Montreal classification, this patient was included in severe degree of UC, based on defecation frequency > 6 times, Hb < 10.5 g/dL, and ESR > 30 mm/hour.¹⁷ Current therapies to treat patients with UC include aminosalicylates (5-ASA), steroid, immunosuppressants, and biological agent (infliximab, tocolizumab).¹³ Antibiotic is also advised in severe degree of UC if an infection is found.¹⁷ In this patient, therapies given were appropriate to the routine SLE therapy, which were: steroid and azathioprine. Besides, antibiotic ceftriaxone, which was appropriate with the culture results, was added to eradicate infection.

If a patient is diagnosed with SLE and initiated by gastrointestinal symptoms, including stomachache and diarrhea, particularly if not associated with clinical symptoms of recurrent SLE, it is wise to think about IBD.¹⁷ Prognosis of SLE associated IBD is usually good.² With prompt diagnosis and management, patient's good clinical outcome and life expectation will be obtained.

REFERENCES

1. Nitzan O, Elias M, Saliba WR. Systemic lupus erythematosus and inflammatory bowel disease. *Eur J Intern Med* 2006;17:313-8.
2. Xin-Ping Tian, Xuan Zhang. Gastrointestinal involvement in systemic lupus erythematosus: Insight into pathogenesis, diagnosis and treatment. *World J Gastroenterol* 2010;16:2971-7.
3. Katsanos KH, Voulgari PV, Goussia A, Oikonomou P, Christodoulou DK, Drosos AA, Tsianos EV. Co-existence of Crohn's disease in a patient with systemic lupus erythematosus. *Rheumatol Int* 2013;33:2145-8.
4. Koutroubakis IE, Kritikos H, Mouzas IA, Spanoudakis SM, Kapsoritakis AN, Petinaki E, et al. Association between ulcerative colitis and systemic lupus erythematosus: report of two cases. *Eur J Gastroenterol Hepatol* 1998;10:437-9.
5. Dubois E, Tuffanelli D. Clinical manifestation of systemic lupus erythematosus. Computer analysis of 520 cases. *J Am Med Assoc* 1964;190:104-11.
6. Fries J, Holman HR. Systemic lupus erythematosus: a clinical analysis. Philadelphia: WB Saunders 1975.p.79.
7. Jessar R, Lamont-Havers R, Ragar C. Natural history of lupus erythematosus disseminatus. *Ann Intern Med* 1953;38:717-29.
8. Harvey A, Shulman LE, Tumulty PA, Conley CL, Schoenrich EH. Systemic lupus erythematosus: review of literature and clinical analysis of 138 cases. *Medicine* 1954;33:291-437.

9. Steffan W, Derk S, Derk CT. The gastrointestinal manifestations of systemic lupus erythematosus: a survey of the literature. *Open Autoimmun J* 2009;1:10-26.
10. Hallegua DS, Wallace CJ. Gastrointestinal and hepatic manifestations. In: Wallace DJ, Hahn BH, eds. *Dubois' Lupus Erythematosus*. 6th ed. Philadelphia: Lippincott Williams and Wilkins 2002.p.843-57.
11. Nagata M, Ogawa Y, Hisano S, Ueda K. Crohn's disease in systemic lupus erythematosus: a case report. *Eur J Pediatr* 1989;148:525-6.
12. Snook JA, de Silva HJ, Jewell DP. The association of autoimmune disorders with inflammatory bowel disease. *Quart J Med* 1989;72:835-840.
13. Meier J, Sturm A. Current treatment of ulcerative colitis. *World J Gastroenterol* 2011;17:3204-12.
14. Simadibrata M. Pendekatan diagnostik diare kronik. In: Sudoyo A, Setyohadi B, Alwi I, Simadibrata M, Setiati S. *Buku Ajar Ilmu Penyakit Dalam*. Jilid I. Edisi IV. Jakarta: Pusat Penerbitan Departemen Ilmu Penyakit Dalam Fakultas Kedokteran Universitas Indonesia 2006.p.355-62.
15. Hoffman BI, Katz WA. The gastrointestinal manifestations of systemic lupus erythematosus: a review of the literature. *Semin Arthritis Rheum* 1980;9:237-47.
16. Stevens HP, Ostlere LS, Rustin MH. Systemic lupus erythematosus in association with ulcerative colitis: related autoimmune diseases. *Br J Dermatol* 1994;130:385-9.
17. University of Maryland Medical Center. Ulcerative colitis [cited 2012 Aug 28]. Available from: URL: <http://umm.edu/programs/ibd/services/conditions/colitis>.

Correspondence:

Supriono

Division of Gastroentero-hepatology

Department of Internal Medicine

Dr. Saiful Anwar General Hospital

Jl. Jaksa Agung Suprpto No. 2 Malang 65111 Indonesia

Phone: +62-341-362101 Facsimile: +62-341-369384

E-mail: sprint.mlg@gmail.com