

Case Report

Pregnancy in a patient with dilated cardiomyopathy (DCM)

Aulia Mustika^{1*} and Aruman Yudantho^{1,2}

¹Department of Cardiology, Faculty of Medicine, University of Diponegoro Semarang, Indonesia; ²Department of Cardiology, Dr. Kariadi Hospital, Semarang, Indonesia.

*Correspondence:

Aulia Mustika
Department of
Cardiology, Faculty of
Medicine, University of
Diponegoro, Semarang,
Indonesia.

E-mail address:
lhea_zainal@yahoo.com

Abstract

Pregnancy in dilated cardiomyopathy (DCM) has an extremely high risk. However, DCM is usually asymptomatic at a young age. In pregnancy with DCM, it appears progressive and becomes symptomatic, and mimicking with peripartum cardiomyopathy (PPCM). We reported a case of a 23-year-old woman who was 20 weeks pregnant with her first child complained of chest palpitations and severe faintness. These progressive symptoms have happened and started during pregnancy. This case report suggests that physiological and emotional burdens are greater during pregnancy, especially for dilated cardiomyopathy (DCM) patients. This condition often leads to the progression of the DCM. The DCM often headways from the asymptomatic phase upturn to the symptomatic stage.

Keywords: Dilated cardiomyopathy, pregnancy, heart failure Introduction

Introduction

Dilated cardiomyopathy (DCM) often occurs before pregnancy. It is acknowledged that new symptoms of DCM may appear during pregnancy - making it similar to peripartum cardiomyopathy (PPCM). Patients with DCM will be advised to avoid pregnancy. DCM cases during pregnancy are rare have been described and therefore here we reported a case of pregnancy women with DCM.

Case

A 23-year-old woman who was 20 weeks pregnant with her first child complained of chest/heart palpitations and faintness as if she was about to pass out. These symptoms have happened during pregnancy. The patient claimed not experienced palpitations before pregnancy. In addition, the patient often felt tired quickly and the heartbeat faster than usual when doing heavy work. She had not experienced swollen feet and waking up at night due to shortness of breath or sleeping with a high pillow. A while after, the patient was admitted to the hospital with similar complaints. She underwent outpatient treatment after showing improvement. About three months prior to pregnancy, the patient often complained of intermittent spinning dizziness. A neurology examination result indicated a blockage of blood vessels in the patient's neck. However, further tests such as DSA were not carried out because the patient was confirmed pregnant.

The patient claimed no history of other diseases during her first child pregnancy - married once. Among the family, she is the 3rd child of three siblings. Her mother (45 years old) was diagnosed with DCM.

The patient's clinical condition was decent, with blood pressure 100/70 mmHg, a heart rate of 98 beats per minute, a breath rate of 20 breaths per minute, a temperature of 36.5°C, and a saturation of 100%. Physical heart examination showed that heart sounds 1 and 2 are irregularly-regular. Heart murmurs and other abnormal heart sounds like galloping were not found. No crackles sound created on her vesicular breath. Abdominal examination performed five months of gestation, no signs of peripheral congestion. The general tests were performed to check blood routine, electrolytes, kidney and liver function in normal value.

Article Information
Received : 03 Nov 2021
Accepted : 10 Dec 2021
Published : 11 Dec 2021

electrocardiogram (ECG) examination result (as shown in Figure 1) showed sinus tachycardia with occasional premature ventricular contractions (PVC). Meanwhile, the Echocardiography results (as shown in Figure 2) showed left-atrial and left-ventricular dilatation and global hypokinetic, with decrease left ventricular ejection fraction (LVEF 28%). It also revealed good right-ventricular function and no regurgitation and stenosis of the heart valves.

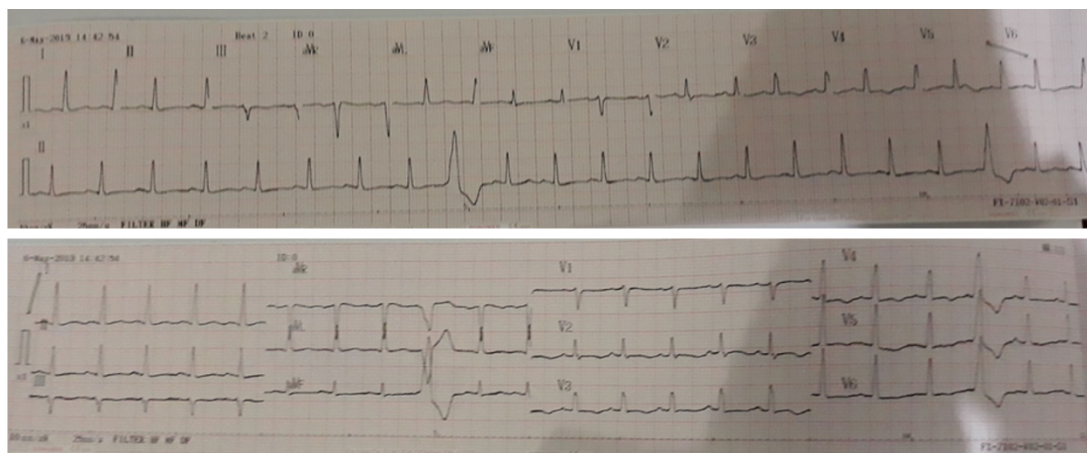


Figure 1. The results of the ECG examination indicate sinus rhythm tachycardia 111 beats per minute, normoaxis and PVC occasional.

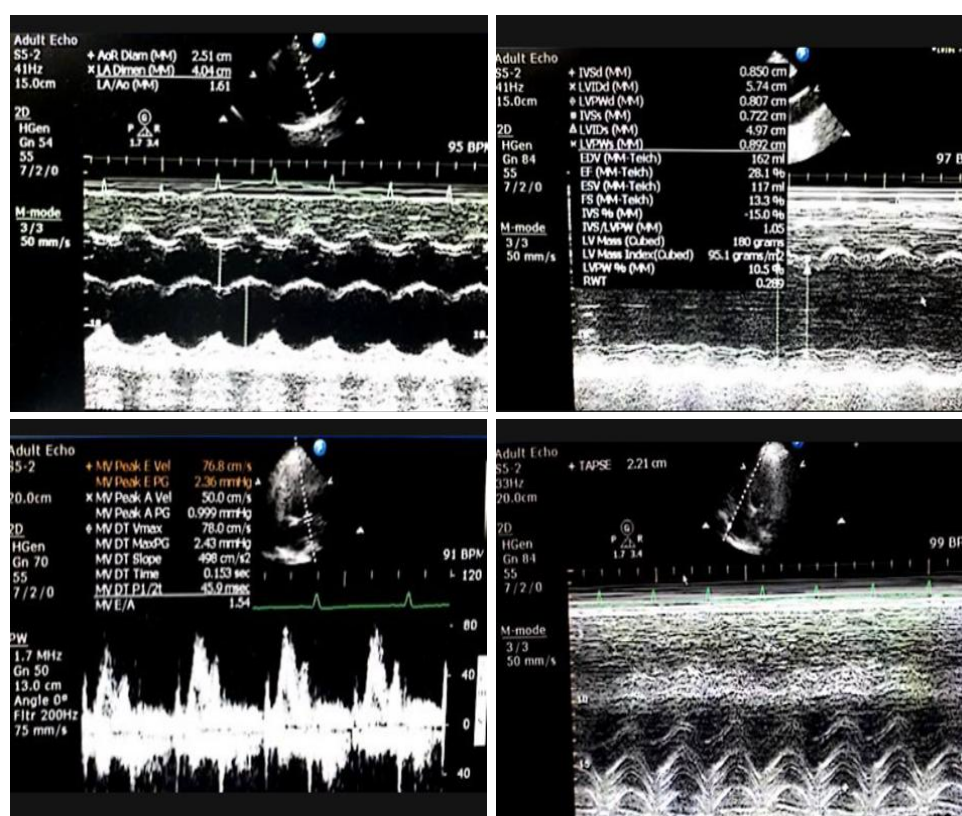


Figure 2. Echocardiography examination results showed left atrial and ventricular dilatation, global hypokinetic, decreased left ventricular systolic function with LVEF 28%, left ventricular diastolic dysfunction grade I with normal left atrium pressure, good RV systolic function with tricuspid annular plane systolic excursion (TAPSE) 22 mm, mild mitral valve regurgitation, no other valves either pulmonary hypertension.

The patient was diagnosed with dilated cardiomyopathy at 20 weeks of pregnancy. With several episodes of syncope and low LV function, careful discussion is necessary due to its extremely high-risk care. Therefore, the decision is whether she can complete pregnancy or if it must be interrupted. The doctor has provided clear explanations on risks and consequences, yet the family refused and decided to continue the pregnancy. As the pregnancy was continued, treatment must be applied and adjusted while considering the fetus. The patient was given therapy of furosemide 40mg/12 hours, digoxin 0.25mg/24 hours, and evaluated every month up to delivery.

Furthermore, the patient had no significant medical treatment during pregnancy. At 38 weeks of pregnancy, the baby was scheduled to be delivered with section caesarian. The baby weight of 2800 grams, and the mother was medically stable. However, one year after delivery, the patient often underwent hospitalization due to acute decompensated heart failure, and was clinically deteriorating. It was characterized by a functional decline to New York Heart Association (NYHA) class III. The echocardiography results (one year after) showed dilatation deteriorating of the four heart chambers, a decrease in right ventricular function with a TAPSE value of 14 mm, and a decline in left ventricular function with an LVEF of 19%.

Discussion

The DCM diagnosis is obtained through anamnesis observation to figure out the symptoms of heart failure, arrhythmia, or neurological disorders. In addition, there was a family history of the same disease. The diagnosis indicated left ventricular dilatation accompanied by a decrease in LVEF function of 28%. The onset of the patient when symptoms were found that distinguishes it from the diagnosis of PPCM. PPCM is usually found in late pregnancy or the months after birth (Arany and Elkayam, 2016; Bollen et al., 2015; Japp et al., 2016).

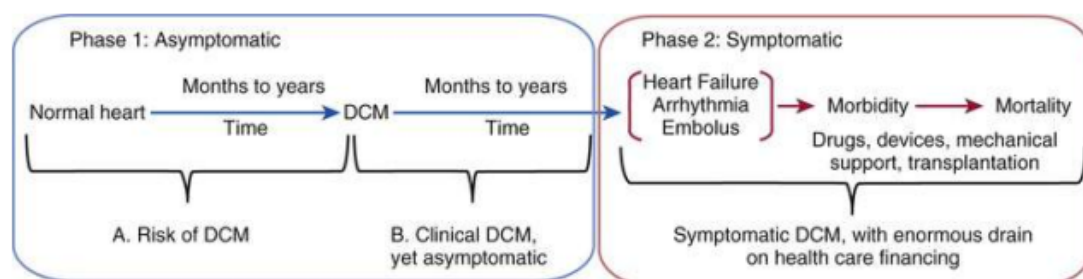


Figure 3. Dilated cardiomyopathy.

The patient underwent an extremely high-risk pregnancy. Based on the Modified World Health Organization classification, maternal cardiovascular risk is in group IV, where the risk of maternal event rate is 40-100%. Therefore, women with dilated cardiomyopathy are advised to avoid pregnancy, and if they are pregnant, termination is also recommended (Regitz-Zagrosek et al., 2018).

DCM is the cause of the disease. Most patients go through two phases (Figure 3). Phase 1 includes two periods in which both do not cause symptomatic manifestations. In the initial period (1A), patients who have risk factors can develop DCM at any time. In this phase, identifying individual genetic information is helpful as an initial screening for detecting DCM occurrence. In phase 1B, DCM has occurred but is asymptomatic. This is not detected because, clinically, it does not show symptoms of cardiovascular abnormalities.

The findings of DCM cases are usually obtained incidentally in people who perform regular health checks. In phase two, when DCM is clinically manifest (symptomatic), the occurrence of symptoms of heart failure, arrhythmia, and embolism are common in DCM that cause morbidity and mortality (Morales and Hershberger, 2015).

Commonly, physiological burdens are greater during pregnancy. Metabolic changes are often associated with pregnancy. In other words, maternal metabolism changes substantially during pregnancy by increasing cardiac output and blood volume. Plasma volume reaches its maximum point with a maximum increase of 40%. This condition often leads to the progression of the DCM. The DCM often headways from the asymptomatic phase upturn to the symptomatic stage. Based on Jasmine et al.'s study, the outcomes of 36 DCM patients who experienced pregnancy showed that 39% of patients experienced at least one cardiovascular complication. Complications can include heart failure, arrhythmia, and stroke. The timing of cardiovascular complications was found antepartum, intrapartum, and postpartum. Antepartum complications are the most common ones. Predicted characteristics of cardiovascular complications mainly occurred in patients with moderate or severe LV systolic dysfunction (EF <45) and NYHA class III or IV classification, as well as a history of cardiovascular occurrences before pregnancy. These are crucial predictive factors (Grewal et al., 2009; Regitz-Zagrosek et al., 2018; Sanghavi and Rutherford, 2014).

Conclusion

The conclusion of this case report is that although this patient was able to continue the pregnancy and delivery process, the disease progression to a symptomatic phase in the form of heart failure with worsening of NYHA class was getting faster in the postnatal period.

Authors' contributions

Conceptualization: AM and AY; Data curation: AM and AY; Formal analysis: AM and AY; Funding acquisition: AY; Investigation: AM; Project administration: AM and AY; Resources: AM and AY; Software: AM; Supervision: AY; Validation: AY; Writing-original draft preparation: AM and AY; Writing-review and editing: AM and AY.

Acknowledgments

The authors would like to thank to the: Faculty of Medicine, University of Diponegoro, RSUP dr. Kariadi Semarang.

Conflict of interest

There is no conflict of interest was reported by the authors.

Funding

This study received no external funding.

References

- Arany Z and Elkayam U. Peripartum cardiomyopathy. *Circulation* 2016; 133(14):1397-1409.
- Bollen IA, et al. Peripartum cardiomyopathy and dilated cardiomyopathy: different

- at heart. *Frontiers in physiology* 2015; 5:531.
- Grewal J, et al. Pregnancy outcomes in women with dilated cardiomyopathy. *Journal of the American College of Cardiology* 2009; 55(1):45-52.
- Japp AG, et al. The diagnosis and evaluation of dilated cardiomyopathy. *Journal of the American College of Cardiology* 2016; 67(25):2996-3010.
- Morales A and Hershberger RE. The rationale and timing of molecular genetic testing for dilated cardiomyopathy. *Canadian Journal of Cardiology* 2015; 31(11):1309-1312.
- Regitz-Zagrosek V, et al. 2018 ESC guidelines for the management of cardiovascular diseases during pregnancy: the task force for the management of cardiovascular diseases during pregnancy of the European Society of Cardiology (ESC). *European heart journal* 2018; 39(34):3165-3241.
- Sanghavi M and Rutherford JD. Cardiovascular physiology of pregnancy. *Circulation* 2014; 130(12):1003-1008.