

Case Report

Coinciding SARS-CoV-2 infection in HIV patients with cerebral toxoplasma

Dika Chandra Bintari^{1,2} and Paulus Sugianto^{1,2*}

¹Department of Neurology, Faculty of Medicine, Universitas Airlangga, Surabaya, Indonesia; ²Department of Neurology, Dr. Soetomo General Hospital, Surabaya, Indonesia.

*Correspondence:

Paulus Sugianto
Department of
Neurology, Faculty of
Medicine, Universitas
Airlangga Surabaya,
Indonesia.

E-mail address:
paulus.sugianto.unair@
gmail.com

Abstract

A massive and notorious impact of coronavirus disease 2019 (COVID-19) pandemic has affected communities worldwide, urging extra preventive measure, especially for individuals with comorbidities including those who are suffering from human immunodeficiency virus/acquired immune deficiency syndrome (HIV/AIDS). We reported a case of a 45-year-old man with severe acute respiratory syndrome coronavirus 2 (SARS-CoV-2) and HIV infection as well as toxoplasmosis. The patient presented to the hospital with decreased consciousness and stiffness on both hands and feet accompanied with loss of appetite, fever, and coughing. Since 2014, he had been diagnosed with HIV and undergone combined antiretroviral therapies. Toxoplasmosis was revealed by multislice computed tomography (MSCT) showing multiple rim-like lesion in cortex-subcortex of left temporal lobe along with surrounding perifocal oedema. Furthermore, the finding was corroborated by the contrasted image exhibiting rim enhancement patterns. The patient was also RT-PCR confirmed Covid-19. Following examinations, the patient received pyrimethamine with a loading dose of 200 mg. The management was continued with oral intake of pyrimethamine, clindamycin, folic acid, and vitamin B6 for maintenance dose. This case report suggests that HIV patient suffering from COVID-19 can be treated with antiretroviral therapies since the specific antiviral for SARS-CoV-2 has not yet available. We believe that this case report could contribute to more understanding on the development of clinical management for COVID-19 in HIV-positive patients.

Keywords: HIV, COVID-19, SAR-CoV-2, antiretroviral, toxoplasma

Introduction

Coronavirus disease 2019 (COVID-19) pandemic has impacted not only on the healthcare system, but also environmental management and economy (Fahriani et al., 2021; Wagner et al., 2021; Dhama et al., 2021). In certain communities the disease has more devastating effect (Bastola et al., 2021). People who are living with human immunodeficiency virus/acquired immune deficiency syndrome (HIV/AIDS) have been reported to suffer worse during the COVID-19 pandemic because of the disruption in healthcare system (Jiang et al., 2020).

Upon infection, HIV could reduce the number of CD4+ T cells that eventually lead to AIDS (CD4+ T cells <200 cells/ μ L). In 2018, 37.9 million people was estimated to be infected with HIV, where 23.3 million of which were under antiretroviral therapies. Among those patients, 86% had succeeded to suppress the virus resulting an undetectable and untransmittable viral load, known as 'undetectable equals untransmittable' (U = U) (Cooper et al., 2020). Several reports suggest HIV does not contribute to poorer outcomes of patients with SARS-CoV-2 (Karmen-Tuohy et al., 2020; Del Amo et al., 2020). However, the participants of the aforementioned studies were under highly active antiretroviral therapy. Meanwhile, in Indonesia, the access to antiretroviral therapies remains key challenge (Riono and Challacombe, 2020). Insufficient antiretroviral therapies, result in increasing susceptibility against SARS-CoV-2 infection.

Article Information
Received : 12 Oct 2021
Accepted : 11 Dec 2021
Published: 11 Dec 2021

Similar to other chronic comorbidities (such as obesity, chronic liver diseases, cardiovascular diseases, and so forth), people with HIV/AIDS are hypothesized to be more susceptible to severe COVID-19 symptoms. Since HIV-positive people are more likely to experience immunosuppression. In this regard, the susceptibility against opportunistic infection could increase and is associated with abnormal humoral immune and T-cells responses (Mirzaei et al., 2021). Herein, we reported a rare case of coinciding COVID-19 in an HIV patient with toxoplasmosis. Toxoplasma infection has been widely recognized as the major cause of focal brain lesions that is commonly attributed to the reduction of antiparasitic T-cell activities in HIV people (Vidal, 2019). Despite the COVID-19 infection, the patient did not receive antiviral treatment, except for antiretroviral to treat the HIV.

Case report

A 45-year-old male patient presented to the hospital with a chief complaint of gradual decreased consciousness for 3 days ago. He was not able to follow communication during conversation, in which this condition has occurred since 2014. On examination, he was unable to follow instructions. The patient also experienced stiffness on his hands and feet for the last 3 days. Patient had fever since the last 5 days and cough for 2 weeks. A week ago, patient had loss of appetite. Seizure, slurred speech, partial weakness, headache, nausea and vomiting were denied. Since 2014, the patient had been diagnosed with HIV and received duviral and efavirenz therapies (though the drugs intake had been stopped since last year). The patient had been prescribed with clindamycin and pyrimethamine from 2014 to 2015. Patient denied to have histories of hypertension, diabetes or stroke.

Physical examination revealed neither meningeal signs nor stiff neck and eyeball movement to all directions. Facial palsy impression was not observed, though lingua palsy was difficult to evaluate. Sensory and cerebral sign examination was difficult to evaluate. From neurologic assessment, it was obtained BPR +2/+2 TPR +2/+2 KPR +2/+2 APR +2/+2, where pathologic reflexes were not found. From laboratory testing, abnormality was obtained at Hb 9.6; 106.000 platelets; albumin level of 2.7; and positive COVID-19 (based on real-time reverse transcriptase-polymerase chain reaction). Radiological examination showed no abnormality.

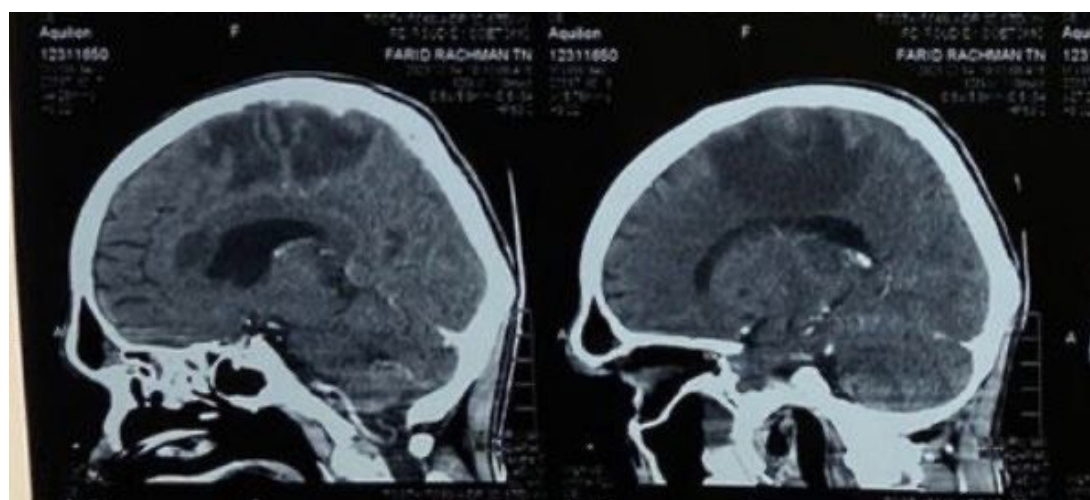


Figure 1. Multislice computed tomography (MSCT) showing a rim-like lesion was found in cortex-subcortex of left temporal lobe along with surrounding perifocal oedema suggesting cerebral toxoplasmosis.

Multislice computed tomography (MSCT) was also carried on the patient with reformatted axial, coronal, and sagittal images of head, with and without contrast.

According to the examination, a rim-like lesion was found in cortex-subcortex of left temporal lobe along with surrounding perifocal oedema (Figure 1). With contrast, the image showed rim enhancement patterns. In Sulci and Gyri, the images looked normal – without abnormal classification and midline deviation. Mucosa thickening (28 HU) appeared in right-left maxillary sinus and left frontalis. Abnormality was not found in right-left orbital, mastoid, and paranasal sinuses. The calvaria appeared normal. Osteolytic/osteoblastic process was not observable. Based on the MSCT, it was concluded that multiple rims enhancing lesion in cortex-subcortex of left temporal lobe along with surrounding perifocal oedema suggested the image of cerebral toxoplasmosis. Images of infarction, bleeding, or mass effect on brain parenchyma were not observable.

Discussion

In this case report, patient's chief complaint (loss of consciousness) along with the symptoms observed during examination (unable to follow communication and instruction as well as stiffness on both hands and feet) could be caused by cerebral toxoplasmosis. It is the main cause of wide brain lesion in people with HIV/AIDS leading to high morbidity and mortality. The most common characteristic of cerebral toxoplasmosis is neurological deficits on focal subacute and brain lesions that enhance the ring in basal ganglia, yet the spectra of its clinical manifestation and neuroradiological features are wide (Cohen et al., 2011). It is supported by further examination using MSCT of the reformatted coronal, axial and sagittal images of the patient's head. The examination revealed the appearance of multiple rim-like lesion in cortex-subcortex of left temporal lobe along with surrounding perifocal oedema, in which rim enhancement was shown in contrasted image. Overall, the MSCT results suggest the image of cerebral toxoplasmosis. Hence, the patient was managed for cerebral toxoplasmosis with pyrimethamine loading (200 mg), continued with maintenance dosage of pyrimethamine 3 x 25 mg per oral.

Rapid advancement of antiretroviral drugs has allowed patients to sustain his life since initial HIV infection in 2014. Combined antiretroviral therapy targeting multiple life cycle steps of HIV could optimally suppress the viremia plasma for a long period of time (Karmen-Tuohy et al., 2020). The patient had histories of receiving duviral and efavirenz therapies (from 2014 to 2020) and clindamycin and pyrimethamine (from 2014 to 2015). Duviral is an antiretroviral drug containing zidovudine (AZT) and lamivudine (3TC). The drug was administered to the patient as a part of his medication regimen due to hepatitis B coinfection. According to a published literature (Pau et al., 2014), lamivudine is a very active drug against hepatitis B that does not cause addictive effect. Moreover, it has high oral absorbance and long intracellular half-life. The drug is excreted through kidneys, where dosing adjustment is required for patients with renal dysfunction. Commonly, the drug could be very well tolerated, though the side effect of skin colour changing is often reported.

On the other hand, zidovudine, is an analogue of thymidine converted into its active form -intracellular triphosphate that could inhibit the activities of DNA polymerase of HIV reverse transcriptase. This drug could be well absorbed through oral; undergoing a glucuronidation in liver and eventually eliminated by kidneys. Zidovudine could be administered twice a day per dose without considering food intake. Usually, zidovudine is prescribed along with lamivudine to form 2-NRTI backbone from the combination. It is commercially available as formulated product along with lamivudine (Combivir ®) as well as lamivudine and abacavir (Trizivir ®). Currently, due to the side effect of zidovudine, its uses have been limited in armamentarium. Several common side effects include suppression of bone marrow (especially in macrocytic anemia and neutropenia), nausea and vomiting, nail

pigmentation, and headache. Even though uncommon, serious side effects such as myopathy, lactic acidosis, and cardiomyopathy are also reported (Pau et al., 2014).

Comorbidities of chronic diseases, especially in terms of multimorbidity, appear to be the factor of COVID-19-related deaths. Extra preventive measurement is required for individuals with comorbidities, including people with immunocompromised such as HIV/AIDS. Wariness over the increasing risk of COVID-19 for people with HIV/AIDS is based on the assumption that the people is prone to immunosuppression. HIV infection is related to abnormal humoral immune and T-cell responses, leading to the increase on the vulnerability against opportunistic infections (Mirzaei et al., 2021). It is a concern in population with poorly controlled HIV infection, where worse outcome of COVID-19 is expected (Karmen-Tuohy et al., 2020).

Indeed, there are published report suggesting a reduced risk of serious COVID-19 symptoms among HIV-positive people (Del Amo et al. 2020; Karmen-Tuohy et al., 2020). This phenomenon could be ascribed to the use of antiretroviral therapies. During SARS outbreak in 2003, antiretroviral therapy was suggested as protective factors; though because the number of studies was limited, it was impossible to draw a conclusion (Chen and Cao, 2004). Studies using molecular docking showed that lamivudine could be effective against SARS-CoV-2 by downregulating RNA-dependent RNA polymerase (Elfiky, 2020). Basically, treatment of COVID-19 is primarily based on the experience against similar viruses such as severe acute respiratory syndrome coronavirus (SARS-CoV), Middle East respiratory syndrome coronavirus (MERS-CoV), HIV dan influenza (Wang et al., 2020). From a study participated by 60 hospitals in Spain (Del Amo et al. 2020), it was found that HIV-positive patients under antiretroviral therapy had lower risk of COVID-19 and hospitalization length, in comparison to those who were not. Therefore, in our case, the patient was administered with antiretroviral to treat HIV and COVID-19, under a circumstance of the absence of specific antivirus for SARS-CoV-2.

Conclusion

With the absence of specific antivirus for SARS-CoV-2, retroviral therapy was considered the best option to reduce the risk of COVID-19 in HIV-positive patients. Further studies are urged to develop a proper treatment for people living with HIV/AIDS who are also suffering from COVID-19.

Authors' contributions

Conceptualization: DCB and PS; Data curation: DCB and PS; Investigation: DCB; Supervision: PS; Validation: DCB and PS; Writing-original draft preparation: DCB and PS; Writing-review and editing: DCB and PS.

Consent for publication

Written informed consent for publication was sought from the patient.

Acknowledgments

We are grateful to the parent of patient for consent to publish this case and for the cooperation in providing the data for research.

Conflict of interests

No conflict of interest is declared.

Funding

This study received no funding.

References

- Bastola A, et al. SARS-CoV-2 and Orientia tsutsugamushi co-infection in a young teen, Nepal: Significant burden in limited-resource countries in Asia? *Narra J.* 2021;1(2):e34.
- Chen XP and Cao Y. Consideration of Highly Active Antiretroviral Therapy in the Prevention and Treatment of Severe Acute Respiratory Syndrome. *Clin Infect Dis* 2004;38(7):1030–1022.
- Cohen MS, et al. Acute HIV-1 Infection. *N Engl J Med.* 2011;364(20):1943–1954.
- Cooper TJ, Woodward BL, Alom S, Harky A. Coronavirus disease 2019 (COVID-19) outcomes in HIV/AIDS patients: a systematic review. *HIV Med.* 2020;21(9):567–577.
- Del Amo J, et al. Incidence and Severity of COVID-19 in HIV-Positive Persons Receiving Antiretroviral Therapy: A Cohort Study. *Ann Intern Med.* 2020;173(7):536–541.
- Dhama K, et al. The role of disinfectants and sanitizers during COVID-19 pandemic: advantages and deleterious effects on humans and the environment. *Environ Sci Pollut Res.* 2021;28(26):34211–34228.
- Elfiky AA. Ribavirin, Remdesivir, Sofosbuvir, Galidesivir, and Tenofovir against SARS-CoV-2 RNA dependent RNA polymerase (RdRp): A molecular docking study. *Life Sci.* 2020;253:117592.
- Fahriani M, et al. Disruption of childhood vaccination during the COVID-19 pandemic in Indonesia. *Narra J.* 2021;1(1):e7.
- Jiang H, Zhou Y, Tang W. Maintaining HIV care during the COVID-19 pandemic. *Lancet HIV.* 2020;7(5):e308–299.
- Karmen-Tuohy S, et al. Outcomes Among HIV-Positive Patients Hospitalized With COVID-19. *JAIDS J Acquir Immune Defic Syndr.* 2020;85(1):6–10.
- Mirzaei H, et al. COVID-19 Among People Living with HIV: A Systematic Review. *AIDS Behav.* 2021;25(1):85–92.
- Pau AK and George JM. Antiretroviral therapy: current drugs. *Infect Dis Clin North Am.* 2014;28(3):371–402.
- Riono P, Challacombe SJ. HIV in Indonesia and in neighbouring countries and its social impact. *Oral Dis.* 2020;26(S1):28–33.
- Vidal JE. HIV-Related Cerebral Toxoplasmosis Revisited: Current Concepts and Controversies of an Old Disease. *J Int Assoc Provid AIDS Care.* 2019;18:2325958219867315.
- Wagner AL, Rajamoorthy Y, Taib NM. Impact of economic disruptions and disease experiences on COVID-19 vaccination uptake in Asia: A study in Malaysia. *Narra J.* 2021;1(2):e42.
- Wang D, Li Z, and Liu Y. An overview of the safety, clinical application and antiviral research of the COVID-19 therapeutics. *J Infect Public Health.* 2020;13(10):1405–1414.