



INTISARI SAINS MEDIS

Published by Intisari Sains Medis

Geriatric Patient Outcomes of Major Burn due to High-Voltage Electrical Injury: A Case Report



CrossMark

Vincent Anggriant^{1,3*}, Ratna Rayeni Natasha Roosseno¹,
Daniel Puguh Pramudyo², Yoseph Chandra³

¹Department of Plastic Surgery, Regional Public Hospital Mangusada, Badung, Bali, Indonesia;

²Department of Surgery, Panti Wilasa Dr. Cipto Hospital, Semarang, Jawa Tengah, Indonesia;

³General Practitioner, Panti Wilasa Dr. Cipto Hospital, Semarang, Indonesia;

*Corresponding author:

Vincent Anggriant;
General Practitioner, Panti Wilasa Dr. Cipto Hospital, Semarang, Indonesia; Plastic Reconstructive and Aesthetic Surgery Intern at Regional Public Hospital (RSD) Mangusada, Badung, Bali;
vincent.anggriant@gmail.com

Received: 2022-07-02

Accepted: 2022-08-10

Published: 2022-09-22

ABSTRACT

Introduction: Electrical burns are uncommon but result in high morbidity and mortality due to severe tissue damage. Geriatrics are vulnerable to aggressive burns because of skin atrophy, comorbidities, diminished host defence mechanisms and reduced mobility. A high-voltage electrical injury has complex complications, especially long-term complications. This study aimed to present the case of geriatric patient outcomes of major burn due to high-voltage electrical injury.

Case Presentation: This is a case report of electrical burn injuries; a 70 years old man came to the emergency room approximately 1 hour after the incident, and a chief complaint was burning due to electrical shock. The patient had a history of electrical shock when fishing on the side of the river bank, where

there is a high-voltage electrical central behind him. When he threw his fishing line, the fishing line caught on the exposed high-voltage transformer cable causing an electric shock. The examination showed that the patient was conscious of burns on the right chest to the abdomen and palm to the right hand, as well as on both soles of the feet. Another complaint was a pain in the wound due to electrical shock without a history of fainting, shortness of breath, chest pain, headache, and vomiting. The patient's previous medical history showed uncontrolled hypertension.

Conclusion: Our study demonstrates a rare geriatric patient discharged without complications due to a high-voltage injury. Strict multi-specialty management and rehabilitation are required to treat electrical injuries properly.

Keywords: Burns, electrical injury, geriatric, high-voltage, treatments.

Cite This Article: Anggriant, V., Roosseno, R.R.N., Pramudyo, D.P., Chandra, Y. 2022. Geriatric Patient Outcomes of Major Burn due to High-Voltage Electrical Injury: A Case Report. *Intisari Sains Medis* 13(3): 551-554. DOI: [10.15562/ism.v13i3.1442](https://doi.org/10.15562/ism.v13i3.1442)

INTRODUCTION

Traditionally, the “geriatric” or “elderly” are considered to be those persons aged 65 and older. High-risk burn injuries due to age-related complications such as decreased physical strength, an impaired protective mechanism, poor vision, longer reaction time, abuse, and neglect. As life expectancy increases, the incidence of burn injuries raises in the elderly as well. Burn injuries can have worse outcomes in the elderly since wound healing in this population is delayed, leading to morbidities, prolonged hospital stays, and mortalities.^{1,2} Age directly contributes to increased burn mortality, and dealing with burn injury in multiple medical conditions is challenging.³

During electric shock, the human body acts as a conductor. Electric energy changes to thermal energy, and muscle and bone can be damaged in addition to the skin

and soft tissue. High-tension electrical injuries are generally well-demarcated, full thickness, and leathery on palpation. Severe damage to an extremity often results in amputation or other handicaps, and digital amputations are seen in lower-tension electrical injuries as well. Electrical burn injuries account for 3%–5% of all thermal burn patients.^{4,5} Almost all electric injuries occur accidentally and cannot be prevented. If the patient is not treated immediately, fatal damage to an electric injury can result in multiple organs or tissue dysfunction.⁶

Electrical injuries represent approximately 3% of admissions to burn units. However, the extent of injuries is often deeper and more severe than non-electrical burns. Electric injury is a relatively common form of mechanical trauma, can occur due to lightning strikes, low voltage or high voltage electric

shock, and is often associated with high morbidity and mortality. Almost all electric injuries occur accidentally and cannot be prevented. If the patient is not treated immediately, fatal damage to an electric injury can result in multiple organs or tissue dysfunction.⁶

The case of electric injury is relatively rare. Although this case is rare, the morbidity and mortality from this incident are very high.⁷ In the United States, reported by the American Burn Association estimates that 4.400 people have been injured in electric accidents, and 400 have died from electrical injuries each year; most are related to work (miners, electricians, dan construction workers).⁸ According to Liu's study, it was found that 0,5% of deaths were related to electrical injuries. Among these deaths, 60% - 70% were caused by low voltage electricity and sometimes caused by short

circuits from car batteries in America and China.⁹ In Indonesia, there are not much collective data on electric injury. One epidemiological research on electric injury patients in the Burn Unit, Cipto Mangunkusumo General Hospital in 2009 – 2010 shows that as many as 11,8% of patients treated at the Burn Unit were electric injury in origin.¹⁰

In the case of electrical burn injuries, surviving the patients often experience body function disorders, and some require reconstructive surgeries.¹¹⁻¹³ Fatal complications caused by electric injury, especially cardiac such as arrhythmias and respiratory arrest, may cause death. Selective laboratory results influence immediate and precise diagnosis. Proper handling and treatment reduce and even eliminate the losses especially caused by complications of the electrical injury.^{11,14}

In this report, we aim to present a case of high-voltage electrical injury that was complicated by full-thickness burns.

CASE PRESENTATION

A 70 years old man came to the emergency room at Panti Wilasa Dr. Cipto Hospital, Semarang, approximately 30 minutes after the incident. His friend accompanied him with a chief complaint of burns due to high-voltage electrical shock. The patient had a history of electrical shock when fishing on the side of the river bank, where there is a high-voltage electric central behind him. When he threw his fishing line, the fishing line caught on of the exposed high-voltage transformer cable and hit one of the patient's body parts, causing an electrical shock. The examination obtained blood pressure of 180/90 mmHg, heart rate 73 times per minute, respiratory rate 20 times per minute, oxygen saturation of 99%, axillary temperature of 36,7 Celcius and weight of 80 kg. In the primary survey, obtained airway was cleared with spontaneous breathing, in circulation CRT < 2 seconds, normal skin color, good skin turgor, and no bleeding, conscious with a good response from the patient, pupil isochore (+/+), reflex (+/+), exposure not found any burn-in back side. The secondary survey had burn injuries on the right chest to the abdomen, palm to the right hand, and both soles of the feet. Another complaint is a pain in the

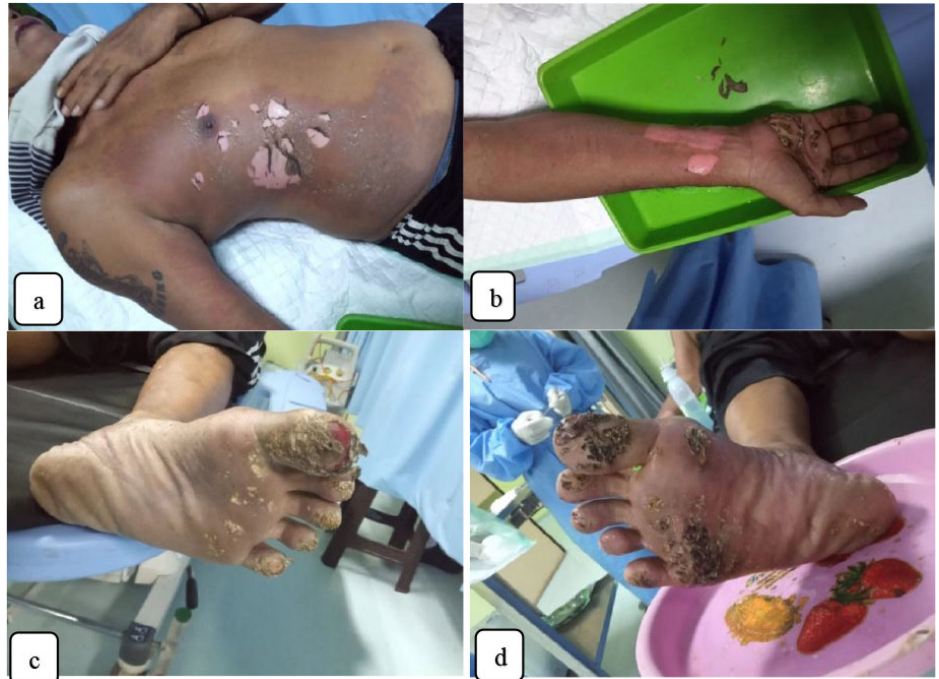

Figure 1. Burn Injuries on the patient (a) regio thorax anterior dextra Grade II A-B (9%); (b) regio manus digiti III-V, palmaris, antebrachia dextra Grade II B (4,5%); (c) plantar pedis sinistra and digiti I-V Grade III (4,5%); (d) plantar pedis dextra and digiti I-V Grade III (4,5%).

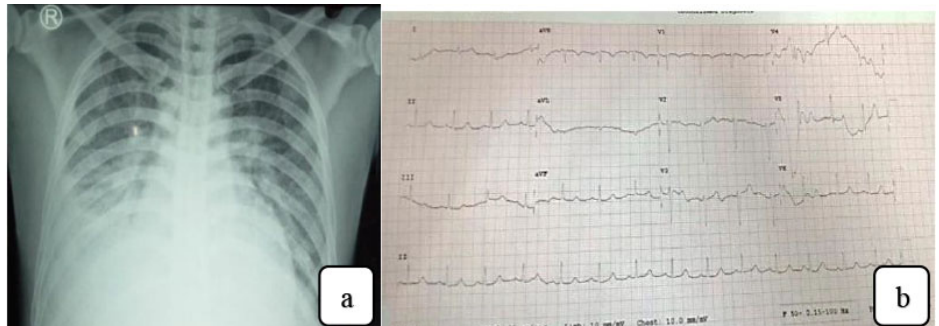


Figure 2. (a) Thorax x-ray and (b) Normal ECG result (ER).

wound due to electric shock without a history of fainting, shortness of breath, chest pain, headache, and vomiting. The patient's previous medical history showed uncontrolled hypertension, and there had been no allergic response.

Based on physical examination and workup results, patients diagnosed with major burns due to high-voltage electrical injuries with clinical conditions found burns in the right thorax anterior (9% grade II A-B); right manus digits III-V, palmaris, and ante-brachial (4,5% grade II B); right plantar pedis and digits I-V (4,5% grade III); left plantar pedis and digits I-V (4,5% grade III). Patient total burn surface area (TBSA) is 22,5% in grades

II-III. Initial treatment is carried out in the emergency room, immediate surgical debridement by a surgeon and handled by a multi-disciplinary team.

Patient Management

Based on physical examination and the patient's medical history, management was given to the patient to maintain hemodynamic stability, initial treatment in the emergency room such as pain killer (paracetamol 1 gram per IV), non-steroid anti-inflammation drug (ketorolac 30 milligrams per IV), oral anti-hypertension (captopril 50 milligrams per oral), antibiotics (cefuroxime 1 gram per IV), ranitidine 50 milligrams per IV, and

Table 1. Urine and blood test results.

Urinary Examination		Blood Examination		Electrolyte	
Color	Yellow	RBC	5,3	Na	142 mmol/L
Clarity	Clear	WBC	12,5	K	4,9 mmol/L
Sp. Gravity	1.020	HGB	15,2	Cl	101 mmol/L
pH	6.0	HCT	44,3	Ad-random Glucose: 138 mg/dL	
Albumin	Negative	PLT	235		
Blood/Hb	Negative	Renal Function			
Urobilinogen	0,2 mg/dL	BUN	38		
Nitrit	Negative	Ur	55		
Keton	Negative	Cr	1,6		
Glucose	Negative	U. Acid	7,9		
Protein	Negative	Liver Function			
Leucocyte	Negative	AST	43 U/L		
Bacteria	Negative	ALT	50 U/L		
Blood/Hb	Negative	Alb	3,1 gr/dL		

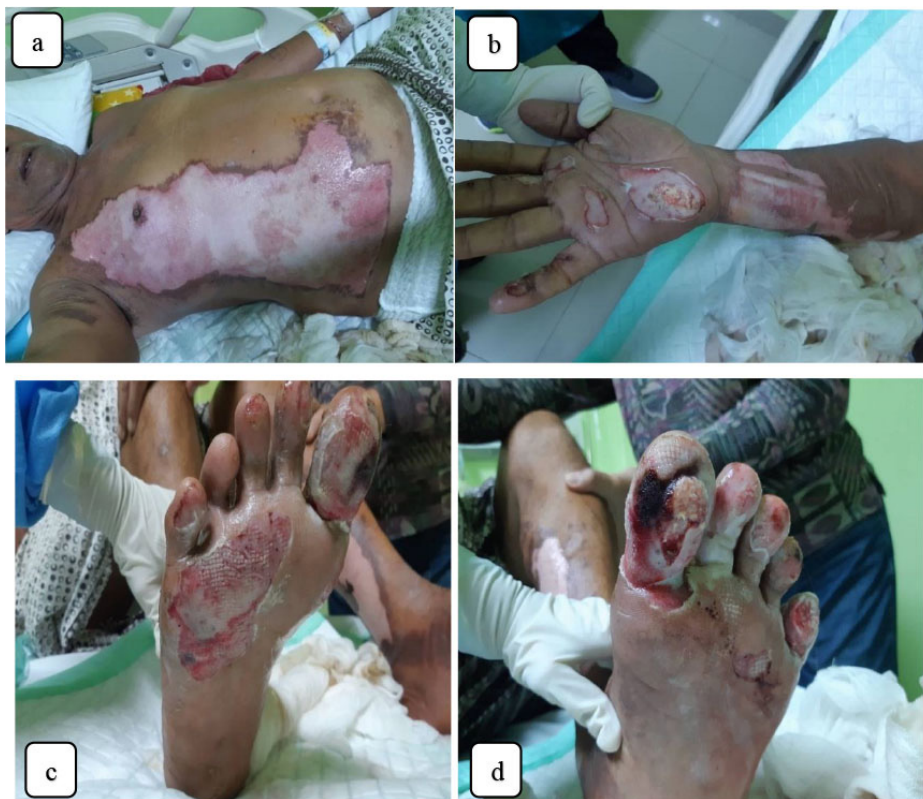

Figure 3. Post debridement (a) regio thorax anterior dextra Grade II A-B (9%); (b) regio digiti III & V, palmaris, antebrachia dextra Grade II B (4,5%); (c) plantar pedis dextra and digiti I-V Grade III (4,5%); (d) plantar pedis sinistra and digit I-V Grade III (4,5%).

fluid administration. By using the Baxter formula, for fluid administration in the management of burns, given 7200 cc of ringer lactate fluid in the first 24 hours, which in the first 8 hours was given 3600 cc and for the next 16 hours had to spend 3600 cc of ringer lactate fluid. And urine

output in the first 8 hours was 2950 cc. And on the next day, continued administration of 2700 cc of futrolite fluid therapy in 24 hours and 500 cc of 3% sodium chloride in 24 hours. Urine output in the first 8 hours was 2150 cc. Reducing acid secretion by blocking histamine H2 receptors,

ranitidine was administered at 150 mg twice a day. Due to hypoalbuminemia in the patient, 20% albumin was given 100 cc per IV. Antibiotic cefuroxime 1 gram IV was given 3 times a day, and paracetamol 1 gram was given 3 times a day. Wound management with surgical debridement of the burns area was performed on the first day in the operating room.

In this case, the patient was hospitalized for 4 days because the patient asked to be discharged. The patient's condition when discharged showed signs of stable hemodynamics and no more complaints. The patient was given the antibiotic cefixime 200 milligrams taken 2 times a day for 5 days and paracetamol 500 milligrams taken 3 times daily.

DISCUSSION

The electrical injury will occur when a person comes into contact with the current produced by a source. These sources can be man-made (for example, power lines in utility companies) or natural, such as lightning strikes.⁷ Electric current can flow through two types of currents, direct current (DC) or alternating current (AC), where the flow of electrons changes direction in rhythmic mode. Alternating current is the most common type of electricity in homes and offices, standardized to a frequency of 60 cycles/second (Hz).¹³ In this case, the patient is exposed to an electric shock from a high-voltage (> 1000 V).

Electrical injury severity and complications depend on the amount of stress, resistance, type of current, current path and duration of contact. There are three main mechanisms for the occurrence of electric injury, and they are: (1) electrical energy causes direct tissue damage, alters the potential of resting membrane cells, and generates muscle tetany; (2) conversion of electrical energy into heat energy, causing large tissue damage and coagulative necrosis; (3) mechanical injury with direct trauma resulting from falls or severe muscle contractions.¹⁵

In patients >65 years of age with the worst outcomes after burn injury, pre-existing frailty is a major determinant of outcome.¹⁵ Elderly patients have a unique acute phase response after burn injury characterized by decreased organ

perfusion and oxygenation.¹⁶ Furthermore, elderly patients are particularly prone to infection, mental health alteration and malnutrition, all of which are associated with increased morbidity and mortality.¹⁷

Gastrointestinal complications can also occur in electrical injury. This is associated with a sequel's "stress response," which increases the secretion of stomach acid and peptic acid. The pathogenesis of "curling's ulcers" and stress ulcers is a change in the quality and quantity of mucous substance in the stomach, loss of integrity of mucous barrier, bile-acid reflux and digestive enzymes, hypersecretion of acid, hypoproteinemia and/or with negative nitrogen balance, mucosal ischemia during the opening of submucosal arteriovenous shunts, local vasoconstriction or the development of microvascular thrombus after intravascular coagulopathy process. Gastrointestinal lesions can occur within 5 hours after the incident. Within 72 hours, many cases develop gastroduodenal ulcerations, which result in large bleeding or perforation.¹⁸

Initial administration of oral or enteral food that starts 6 hours after the incident is an effective supplement in preventing stress-induced ulceration. Early feeding reduces the incidence and severity of bacterial translocation by maintaining the integrity of the mucosal barrier.¹⁹ The use of antacids and H₂ receptor blockers has become an established practice to prevent bleeding. H₂ receptor blockers, for example, ranitidine, administered at a dose of 150 mg twice a day for about 3-6 weeks, is a normal practice today, with the idea of reducing acid secretion by blocking histamine H₂ receptors on parietal cells of the gastric mucosa.²⁰

Progressive ischemia in electric injury is also a serious complication. Thrombus formation in arterioles, narrowing of vessels decreases blood flow, and tissue necrosis can occur.²¹ This is a factor that contributes to amputation decisions. Therefore, in this case, amputation can be avoided because there is no necrotic tissue, so only performed debridement and proper wound management are performed. Plastic surgery procedures, such as skin grafts or artificial dermis, are useful for first-time surgery, and regional or free flaps are useful if the injury is

severe. In case of electric injury with high tension, groin and abdominal flaps are the most commonly used flaps.²²

CONCLUSION

Although uncommon, electrical burns cause wide-ranging and potentially devastating injuries. Electric injury has complex complications, so appropriate treatment to prevent complications from occurring has a very important role. Strict multi-disciplinary management and rehabilitation are required to treat electrical injuries properly. High-voltage electrical accidents must be avoided by placing the transmission cables underground.

CONFLICT OF INTEREST

The authors declare that they have no competing financial or personal interests.

AUTHOR CONTRIBUTION

All authors contributed equally in conducting the study and writing and revising the manuscript.

FINANCIAL SUPPORT

This research received no specific grant from public, commercial, or not-for-profit funding agencies.

ETHICAL APPROVAL

The institutional review board/ethics committee does not require approval for case reports.

REFERENCES

1. Eggert E, Huss F. Medical and biological factors affecting mortality in elderly residential re victims: a narrative review of the literature. *Scars, Burn Heal*. 2017;4(3):205–12.
2. Bayuo J, Agbenorku P, Amankwa R, Agbenorku M. Epidemiology and outcomes of burn injury among older adults in a Ghanaian tertiary hospital. *Burn Open*. 2018;2(2):98–103
3. Toppi J, Cleland H, Gabbe B. Severe burns in Australian and New Zealand adults: Epidemiology and burn centre care. *Burns*. 2019;45(6):1456–61
4. Mirmohammadi SJ, Mehrparvar AH, Kazemeini K et al: Epidemiologic characteristics of occupational burns in Yazd, Iran. *Int J Prev Med* 2013;4(6):723-727
5. Kumar S, Ali w, verma AK et al: Epidemiology and mortality of burns in the lucknow Region, India—a 5 year study. *Burns* 2013;39(8):1599–1605.
6. Lisa A. Foris; Martin R. Huecker. *Electrical Injuries*. StatPearls Publishing LLC: January

2018. [https:// www.ncbi.nlm.nih.gov/books/NBK448087/](https://www.ncbi.nlm.nih.gov/books/NBK448087/).
7. Waldmann V, Narayanan K, Combes N, Marijon E. Electrical injury. *BMJ*. 2017;357.
8. National Burn Repository [Internet]. 8th ed. Chicago: American Burn Association; 2015 Accessed: 14 July 2022. Available: <http://www.america.burn.org/2012NBRAnnualReport.pdf>.
9. Liu, H., Q. Wang, Z. Zhao, Y. Xie, S. Ding, dan Z. Wang. 2016. The Clinical and Medicolegal Analysis of Electrical Shocked Rats: Based on the Serological and Histological Methods. *Biomed Research International*. 2016;1-12
10. Suzan, R., dan D. E. Andayani. Management of Nutrition in Patient with Burns Electricity. *JMJ*. 2017;5(1):1-13.
11. Karimi, H., M. Momeni, dan M. Vasigh. Long Term Outcome and Follow Up of Electrical Injury. *Journal of Acute Disease*. 2015;107- 111.
12. Dewi NK, Adnyana IM, Sanjaya IG, Hamid AR. Epidemiologi pasien luka bakar di RSUP Sanglah Denpasar tahun 2018-2019. *Intisari Sains Medis*. 2021;12(1):219-23.
13. Ungureanu M. Electrocutions-treatment strategy (case presentation). *Journal of Medicine and Life*. 2014;7(4):623-6.
14. Elfiah U, Suryani DY. Case Report: Risk of Electric Injury on Delayed Initial Treatment. *Jurnal Rekonstruksi dan Estetik*. 2019;4(1):11-9.
15. Romanowski K, Curtis E, Barsun A, Palmieri T, Greenhalgh D, Sen S. The frailty tipping point: determining which patients are targets for intervention in a burn population. *Burns*. 2019;45(5):1051-6.
16. Rehou S, Shahrokhi S, Thai J, Stanojcic M, Jeschke MG. Acute phase response in critically ill elderly burn patients. *Critical care medicine*. 2019;47(2):201-9.
17. Grigorian A, Joe V, Chin T, Bernal N, Lekawa M, Satahoo S, et al. 23 Burns in Octogenarians: 80 is the New 60. *Journal of Burn Care & Research*. 2019 Mar 9;40(Supplement_1):S19-.
18. Kumar, Arige Subodh, Gogulapati Venkata Sudhakar. Upper gastrointestinal lesions and bleed in burn injuries: An endoscopic evaluation. *Indian Journal of Burns*. 2014;22(1):72.
19. Yasti, Ahmet Çınar, Emrah Şenel, Mutlu Saydam, Geylani Özok, Atilla Çoruh, Kaya Yorgancı. Guideline and treatment algorithm for burn injuries. *Ulus Travma Acil Cerrahi Derg*. 2015; 21(2):79-89.
20. Suryantari SA, Satyarsa AB, Ariani NK. Pemanfaatan antidepresan pada depresi lanjut usia. *Gema Kesehatan*. 2019;11(2):78-85.
21. Seng, Khoo Kah, Leong Qi Wen, Bustaman Syamimi, Ho Choon Aik, Lim Chen Hong. Management of an Electrocuted Burn Injury in a District Hospital-A Case Report and Literature Review. *Journal of Clinical and Diagnostic Research*. 2018;12(5):1-12.
22. Al-Qattan MM, Al-Qattan AM. Defining the indications of pedicled groin and abdominal flaps in hand reconstruction in the current microsurgery era. *The Journal of Hand Surgery*. 2016;41(9):917-27.



This work is licensed under a Creative Commons Attribution