



INTISARI SAINS MEDIS

Published by Intisari Sains Medis

Dramatic improvement in severe-critical COVID-19 patient after tocilizumab administration: a clinical experience



CrossMark

Yesicha Kurniawati¹, Kadek Surya Atmaja^{1*}, Ketut Suryana², Wayan Wahyu Semara Putra³

¹Intern of Pulmonology and Respiratory Medicine Department, Wangaya Regional General Hospital, Denpasar, Bali, Indonesia;

²Internist of Internal Medicine Department, Wangaya Regional General Hospital, Denpasar, Bali, Indonesia;

³Pulmonologist of Pulmonology and Respiratory Medicine Department, Wangaya Regional General Hospital, Denpasar, Bali, Indonesia

*Corresponding author:

Kadek Surya Atmaja;

Intern of Pulmonology and Respiratory Medicine Department, Wangaya Regional General Hospital, Denpasar, Bali, Indonesia;
suratmaja89@gmail.com

Received: 2021-02-02

Accepted: 2021-04-20

Published: 2021-04-30

ABSTRACT

Background: Severe acute respiratory syndrome coronavirus 2 (SARS-CoV-2) infections in coronavirus disease 2019 (COVID-19) involve so many inflammatory cytokines, especially Interleukin-6 (IL-6). The usage of tocilizumab as an anti-IL-6 receptor antibody had been approved as COVID-19 medication.

Case Presentation: This article reports a 51-year-old woman diagnosed with severe-critical COVID-19. The

patient made significant progress after tocilizumab administration. The patient was hospitalized for 14 days before being discharged.

Conclusion: Tocilizumab administration showed a significant improvement in COVID-19 patients. However, further investigations are needed to explain this further.

Keywords: COVID-19, SARS-CoV-2, IL-6, Tocilizumab.

Cite This Article: Kurniawati, Y., Atmaja, K.S., Suryana, K., Putra, W.W.S. 2021. Dramatic improvement in severe-critical COVID-19 patient after tocilizumab administration: a clinical experience. *Intisari Sains Medis* 12(1): 338-340. DOI: [10.15562/ism.v12i1.951](https://doi.org/10.15562/ism.v12i1.951)

INTRODUCTION

A series of atypical respiratory diseases occurred in China in December 2019. This virus rapidly spread all over the world and became a global pandemic. It was then known novel coronavirus as the culprit. Due to its high homology to the Severe Acute Respiratory Syndrome Corona Virus (SARS-CoV), it was then named Severe Acute Respiratory Syndrome Corona Virus 2 (SARS-CoV-2). SARS-CoV-2 causes disease primarily in the respiratory system, but other organs could also be affected. The disease than called coronavirus disease 19 (COVID-19).^{1,2}

The symptoms vary in severity, ranging from mild to severe. The infected person could be a carrier with no symptom to a severe symptom such as Acute Respiratory Distress Syndrome (ARDS). On January 17th, 2021, the World Health Organization had reported 93,217,287 cumulative cases of COVID-19 with 4,725,029 new cases weekly. COVID-19 was first reported in Indonesia on March 2nd, 2020. On January 20th, 2021, the Indonesian government announced 12,568 new confirmed cases,

which made Indonesia has a total of 939,948 cumulative confirmed COVID-19 cases since it was first reported.¹⁻⁵ The main aim of this study is to evaluate the dramatic improvement in COVID-19 patients who are critically ill after administration of tocilizumab.

CASE PRESENTATION

A 51-year-old woman came to the Emergency Room with a chief complaint of shortness of breath for 5 days. The patient also complained of fever, nausea, and dry cough since 1 week prior. The patient had no history of type II diabetes mellitus, hypertension, cardiovascular, and respiratory disease.

On admission, the patient was conscious with a blood pressure of 126/75 mmHg, pulse rate of 82 bpm, respiratory rate of 24 times per minute, axillar temperature of 37.7°C, oxygen saturation level of about 91% in room air.

On physical examination, rhonchi in both lungs were observed. Chest radiograph showed haziness in both lungs suggested pneumonia (Figure 1). Routine

hematology showed elevated neutrophil percentage (81.5%) and elevated neutrophil-lymphocyte ratio (5.89). SARS CoV-2 RT PCR examination was reported to be positive.

The patient was admitted to the COVID-19 isolation ward and treated by a pulmonologist with normal saline 20 drips per minute, remdesivir 200 mg IV drips on the first day, then 100 mg IV drips every 24 hours at second until the tenth day, azithromycin 500 mg tablet every 24 hours, enoxaparin sodium 6000 IU

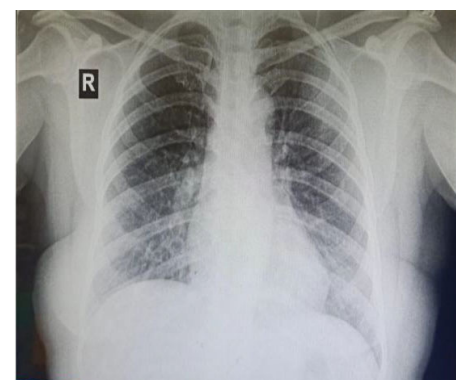


Figure 1. Chest radiograph suggested a pneumonia

Table 1. The progress note

Date	12. 29	12. 30	1. 1	1. 4	1. 7	1.11
	Before Tocilizumab administration			After Tocilizumab administration		
Day of admission	I	II	IV	VII	X	XIV
Fever (°C)	37.7°C	39°C	38.0°C	37.5°C	37.1°C	36.6°C
Shortness of breath	+	+	±	-	-	-
Respiratory rate (times/minute)	24	32	22	20	18	17
Blood pressure (mmHg)	126/75	136/86	125/73	115/72	112/70	115/70
Pulse rate(times/minute)	96	102	88	86	84	82
SPO ₂ (%)	91% on room air	89% on 15 lpm NRM	99% on 15 lpm NRM	99% on 8 lpm NRM	98% on 4 lpm NC	98% on room air
WBC (10 ³ /μL)	7.66		7.57		7.31	-
Neutrophil (10 ³ /μL)	6,24		5.87		6.78	
Lymphocyte (10 ³ /μL)	1.06		1.07		1,49	
NLR	5.89		5.45		4.53	
IL-6 (pg/mL)		153.4	102,7			
D-Dimer (ng/mL)		1223.5	833.1			
Procalcitonin (ng/mL)		0.09	0.06			
LDH (U/L)		1235	754			
CXR	Haziness in both lungs suggested a Pneumonia					
SARS-CoV-2 IgM	Reactive					
SARS-CoV-2 IgG	Reactive					
RT-PCR	Positive					
						Negative

SPO₂, Oxygen saturation; lpm, liters per minute; WBC, White Blood Cell; NLR, Neutrophil Lymphocyte Ratio, LDH, Lactate Dehydrogenase.

injection every 24 hours, dexamethasone 5 mg injection every 24 hours, vitamin C 500 mg injection every 12 hours, cholecalciferol 5000 IU tablet every 12 hours, and paracetamol 500 mg tablet every 8 hours if axillary temperature more than 37.5°C.

On the second day of hospitalization, the dyspnea has gotten worse, the patient's oxygen saturation level of about 89% on 15 lpm non-rebreathing oxygen mask, The patient's axillary temperature was 39°C. Blood gas analysis showed pH 7.48. Further examination revealed elevated IL-6 (153.4 pg/mL), elevated D-Dimer (1223.5 ng/mL), elevated procalcitonin (0.09 ng/mL), and elevated LDH (1,235 U/L) levels. The patient was admitted to the Intensive Care Unit and got additional therapy, such as high flow nasal cannula oxygenation (FiO₂: 100%, Flow: 40 lpm), Lidocaine 2% 2 mL + NaCl 0,9% 3 mL nebulizer every 8 hours and tocilizumab 200 mg IV drips. 48 hours after tocilizumab administration, the patient's condition was significantly

got better. The patient progress note can be seen in Table 1.

After 14 days of hospitalization, the patient's condition improved. There were no complaints of shortness of breath, fever and nausea. The cough got much better. RT-PCR SARS CoV-2 evaluation showed negative results, and the patient was discharged from the hospital.

DISCUSSION

In this patient, before tocilizumab was administered, IL-6 level was 153.4 pg/mL, D-Dimer level was 1223.5 ng/mL, procalcitonin was 0.9 ng/mL, and LDH level was 1,235 U/L. After tocilizumab administration, the laboratory results got significantly better. IL-6 level creased to 102.7 pg/mL, D-Dimer level decreased to 833.1 ng/mL, procalcitonin level decreased to 0.06 ng/mL, and LDH level decreased to 754 U/L.

In this patient, on the second day of hospitalization, the condition got worse, and the patient was admitted to ICU.

But after tocilizumab administration, the patient's condition got better. The complaint of shortness of breath was better, the cough was decreased, and axillary temperature remained at about 37.2 - 38°C.

IL-6 has three main pathways of signal transduction.⁶⁻¹⁰ They are classical signal, trans-signal, and trans-presentation. IL-6 binds to the IL-6 receptor. This complex then binds to the transmembrane glycoprotein (gp130) to initiate intracellular signal transduction in the classical signal transduction pathway. IL-6 receptors also exist in soluble form. Both transmembrane and soluble forms of IL-6 receptors are bound by IL-6. In trans-signal transduction, the binding affinity of IL-6 to IL-6 receptor both transmembrane and soluble form are the same, those complex than bind to gp130 that leads initiation of intracellular signal transduction. This trans-signal transduction explains the cell that doesn't express the IL-6 receptor could still respond to IL-6 by stimulation

of soluble form IL-6 receptor.^{10,11}

Extracellular soluble glycoprotein 130 (sgp130) in the trans-presentation signal pathway could form a complex with soluble IL-6 receptors to prevent it from binding with gp130. After IL-6 binds to gp130, it then activates Janus Kinase/Signal transducer and activator of transcription (JAK-STAT) pathway. Other pathways are also activated, such as RAS-RAF-AKT-P13K and SRC-YAP-NOTCH. IL-6 induces proliferation, differentiation, and antibody production of B-cells. IL-6 causes immature thymocytes to differentiate into CTLs.^{10,11}

COVID-19 patients who had severe disease severity produce an abundance of cytokines that leads to cytokine storms. There is still a lack of study that provides data of a mortality rate in severe COVID-19; hence understanding the outcome of severe COVID-19 remains poor. A meta-analysis study consists of a total of 24 studies with 10,150 patients that assess ICU mortality of COVID-19 patients showed a 41.6% mortality rate. In another study that enrolled 344 COVID-19 with the severe and critically ill patient, among 100 patients who received mechanical ventilation, 97% of death occurred before 28 days.¹³

A study that included 43 COVID-19 patients in China that compared IL-6 levels in severe and mild cases reported that IL-6 was significantly higher in severe cases. IL-6 was the most frequently reported increased cytokine in COVID-19 patients. Targeting IL-6 or IL-6 receptors are a promising strategy for relieving inflammation symptoms in COVID-19. Tocilizumab, an anti-IL-6 receptor antibody, had been approved for the treatment of rheumatoid arthritis. China has approved tocilizumab for the treatment of COVID-19.^{11,12,14} A retrospective cross-sectional study that compared the outcome of the tocilizumab treated patient and without tocilizumab group found a

higher death case in without tocilizumab group (72% vs. 25%, $P=0.002$). This data suggest administration tocilizumab could be an option to reduce the mortality rate among severe COVID-19 patient.¹⁵

CONCLUSION

IL-6 was the most frequently reported increased cytokine in COVID-19 patients. Targeting IL-6 or IL-6 receptors are a promising strategy for relieving inflammation symptoms in COVID-19. Tocilizumab is an anti-IL-6 receptor antibody that has been approved as COVID-19 medication and administration of this medication in this study has proved patient improvement for the next day.

CONFLICT OF INTEREST

None declared.

FUNDING

This study was fully funded by the researcher.

AUTHOR CONTRIBUTIONS

All the authors are responsible for the study from the conceptual framework.

REFERENCES

1. Yuki K, Fujiogi M, Koutsogiannaki S. COVID-19 pathophysiology: A review. *Clin Immunol.* 2020;215:108427. doi:10.1016/j.clim.2020.108427.
2. World Health Organization. Weekly epidemiological update. 2021. Available from: <https://www.who.int/publications/m/item/weekly-epidemiological-update---19-january-2021>.
3. Adityo S, Martin R, Ceva W, et al. Coronavirus Disease 2019: Review of Current Literatures. *JPDI.* 2020;7(1):45-67. doi: 10.7454/jpdi.v7i1.415.
4. Samudrala PK, Kumar P, Choudhary K, et al. Virology, pathogenesis, diagnosis and in-line treatment of COVID-19. *EJP.* 2020;883:173375. doi:10.1016/j.ejphar.2020.173375.
5. Jin Y, Yang H, Ji W, et al. Virology, Epidemiology, Pathogenesis, and Control of COVID-19.

Viruses. 2020;12(4):372. doi:10.3390/v12040372.

6. Ezzikouri S, Nourilil J, Benjelloun S, Kohara M, Tsukiyama-Kohara K. Coronavirus disease 2019-Historical context, virology, pathogenesis, immunotherapy, and vaccine development. *Hum Vaccin Immunother.* 2020;16(12):2992-3000. doi:10.1080/21645515.2020.1787068.
7. Mason RJ. Pathogenesis of COVID-19 from a cell biology perspective. *Eur Respir J.* 2020;55(4):2000607. doi:10.1183/13993003.00607-2020.
8. Harrison AG, Lin T, Wang P. Mechanisms of SARS-CoV-2 Transmission and Pathogenesis. *Trends Immunol.* 2020;41(12):1100-1115. doi:10.1016/j.it.2020.10.004.
9. Cevik M, Kuppalli K, Kindrachuk J, Peiris M. Virology, transmission, and pathogenesis of SARS-CoV-2. *BMJ.* 2020;371:m3862. doi:10.1136/bmj.m3862.
10. Ebrahimi N, Aslani S, Babaie F, et al. Recent findings on the Coronavirus disease 2019 (COVID-19); immunopathogenesis and immunotherapeutics. *Int Immunopharmacol.* 2020;89(Pt B):107082. doi:10.1016/j.intimp.2020.107082.
11. Zhang C, Wu Z, Li JW, Zhao H, Wang GQ. Cytokine release syndrome in severe COVID-19: interleukin-6 receptor antagonist tocilizumab may be the key to reduce mortality. *Int J Antimicrob Agents.* 2020;55(5):105954. doi:10.1016/j.ijantimicag.2020.105954.
12. Sun X, Wang T, Cai D, et al. Cytokine storm intervention in the early stages of COVID-19 pneumonia. *Cytokine Growth Factor Rev.* 2020;53:38-42. doi:10.1016/j.cytogfr.2020.04.002.
13. Wang Y, Lu X, Li Y, et al. Clinical Course and Outcomes of 344 Intensive Care Patients with COVID-19. *Am J Respir Crit Care Med.* 2020;201(11):1430-1434. doi:10.1164/rccm.202003-0736LE.
14. Esmaeilzadeh A, Elahi R. Immunobiology and immunotherapy of COVID-19: A clinically updated overview. *J Cell Physiol.* 2021;236(4):2519-2543. doi:10.1002/jcp.30076.
15. Klopfenstein T, Zayet S, Lohse A, et al. Tocilizumab therapy reduced intensive care unit admissions and/or mortality in COVID-19 patients. *Med Mal Infect.* 2020;50(5):397-400. doi:10.1016/j.medmal.2020.05.001.



This work is licensed under a Creative Commons Attribution