

The Need of Chest Computer Tomography in The Assessment of Mediastinal Seminoma and Non Seminomatous Germ Cell Tumors

Aziza Icksan¹, Reny Luhur², Elisna S³, Heriawati³.

¹Department of Radiology, ²Department of Pulmonology and Respiratory Medicine,

³Department of Pathology, Persahabatan Hospital Jakarta, Indonesia

ABSTRAK

Germ cell tumor mediastinum merupakan salah satu dari masa mediastinum anterior yang terdiri dari teratoma, seminoma dan non seminomatous. Diferensial diagnosa dari germ cell tumor pada mediastinum anterior meliputi massa thymus, massa tiroid dan lymphoma. Dalam membuat diagnosa, disamping gejala klinis dan usia pasien, pemeriksaan seromarker serta temuan foto toraks dan CT toraks sangat membantu. Diagnosa pasti ditegakkan berdasarkan pemeriksaan sitologi dan histopatologi dari spesimen yang berperan penting sebagai baku emas.

Penentuan lokasi tumor yang tepat sangatlah penting dalam penanganan pasien. Foto toraks merupakan pemeriksaan imaging awal yang dilakukan pada pasien yang sudah diketahui atau dicurigai menderita germ cell tumor mediastinum. Pemeriksaan Chest CT dengan kontras merupakan prosedur rutin dalam penanganan germ cell tumor mediastinum.

Kasus non seminomatous dan seminoma germ cell tumor pada mediastinum anterior dilaporkan pada laki laki berusia 17 dan 15 tahun. Pada kedua pasien ini telah dilakukan pemeriksaan foto toraks dan CT toraks dengan menggunakan kontras media.

Kata kunci : germ cell tumor mediastinum, seminoma, non seminomatous, foto toraks, CT toraks.

ABSTRACT

Mediastinal germ cell tumor is one of the anterior mediastinal mass which consists of teratoma, seminoma and non seminomatous. The differential diagnosis of the anterior mediastinal germ cell tumor such as thymic mass, thyroid mass and lymphoma. The diagnosis depends on some criteria such as, clinical finding, the age of the patient, sero markers, location of the mass and findings on the chest radiograph and chest CT. Cytology and histopathology finding from the specimens are paramount important as a gold standard.

Accurate assessment of the location is very important to manage the patient. Chest radiograph is usually the first imaging study obtained in a patient with known or suspected of mediastinal germ cell tumor, and for further evaluation enhanced Chest CT nowadays has become the routine procedure in assessing mediastinal germ cell tumor.

Cases of the mediastinal non seminomatous and seminoma germ cell tumors were reported in a 17 and 15 year old males. Chest radiograph and enhanced chest CT were used to diagnosing and assessing of the patients.

Key word : mediastinal germ cell tumor, seminoma, non seminomatous, chest radiograph , Enhanced chest CT.

INTRODUCTION

Mediastinal masses are classically defined according to their location in the anterior, middle or posterior compartment.¹⁻⁴ Mediastinal Germ Cell Tumors (GCT) account for 10 to 15 % of anterior mediastinal masses and usually occur in young adults.^{3,4}

Chest X Ray (CXR) is usually the first imaging study obtained in a patient with known or suspected mass and remains important for localization of the mass.

In some cases Chest X Ray is needed for characterization of the lesion.^{2,4}

In most centers, Computer Tomography (CT) is the mainstay and it is routinely done for evaluation of known or suspected mediastinal masses. In Indonesia, enhanced CT has been the routine procedure in assessing mediastinal masses. MRI is not routinely used. In some condition MRI done to further evaluate the location of tumor, extend of the diseases and it is also used in patient

ALAMAT KORESPONDENSI

dr. Aziza Icksan, Sp.Rad, Instalasi Radiologi RS. Persahabatan

Email: azizagicksan@yahoo.com

for whom contrast is contra indication.^{2,4-10}

This paper report of two cases affecting a 17 and 15 year old males who were diagnosed as a different type of malignant anterior mediastinal masses, one was non seminomatous and the other one was seminoma GCT, who were came to Persahabatan Hospital with complain of dyspnoe due to compression of the mass to the superior vena cava.

CASE REPORT

CASE 1

A 17 year old male came to Persahabatan Hospital with complain of dyspnoe, cough, and dysphagia. Three weeks before admitted to the hospital, he had came with increasing clinical problems. Seromarkers of LDH, β -HCG, δ -fetoprotein increased. No evidence of a testicular or retroperitoneal abnormality.

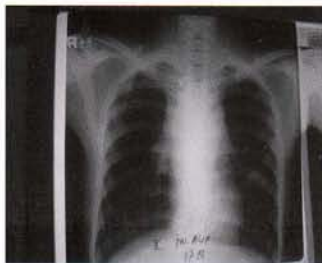

Figure 1. From CXR, there are dilatation of the mediastinal and multiple nodule in both of the lung.

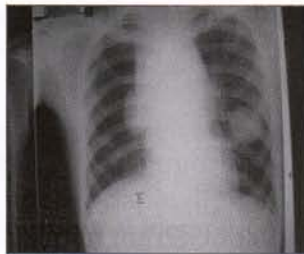


Figure 2. there are multiple nodule in the left lung.

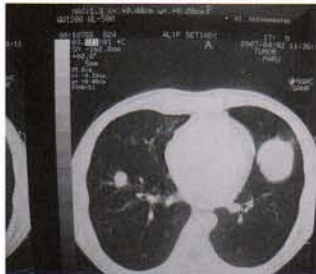


Figure 3. Finding from chest CT: there is an anterior mediastinal mass with heterogenous density, capsulated margin, peripheral enhancement and non visualized vena cava superior with collateral anterior superficial vein. There are multiple nodules in both of the lung, no calcification - malignant GCT suspected, DD/ lymphoma.

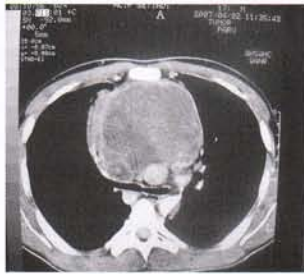


Figure 4. Trans Thoracic Needle Aspiration (TTNA) guided CT was performed in lung mass.



Figure 5. Cytology confirmed as non-seminomatous germ cell tumor.

CASE 2

A 15 year old male came to Persahabatan Hospital with complain of dyspnoe since 1 month ago. No history of TB. Physical finding were venecation on the right neck region, and elevation of jugular venous pressure. Laboratory finding was elevated β HCG but δ feto protein and LDH in normal limit.

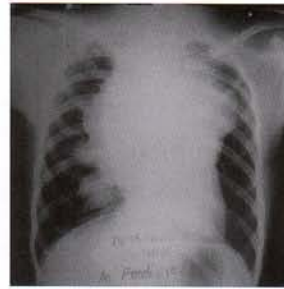


Figure 1. The chest x ray shows a mediastinal widening suspicious of mass.

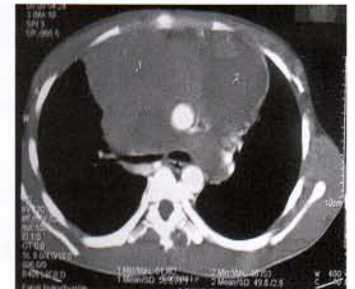


Figure 2. Enhanced chest CT shows large lobulated and encapsulated homogenous anterior mediastinal mass without calcification with compression of the superior vena cava without collateral superficial veins. Germ cell tumor was suspected, dd/ lymphoma and thymoma.



Figure 3. TTNA guided CT was performed from the mass. Cytology from the specimen contains a few cells with dispersed tumor cells and concluded as seminoma germ cell tumor.

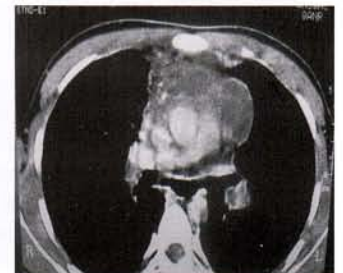

Figure 4. Evaluation after chemotherapy with chest CT. The mass decreased in size for > 50% and the superior vena cava was visualized.

LITERATURE REVIEW

MEDIASTINAL MASSES

Mediastinal masses are classically defined according to their location in the anterior, middle or posterior compartment. This simple classification tends to constrict thinking and minimizes more detailed anatomic analysis. Much more important is the accurate assessment of the location.¹⁻⁴

Germ cell tumor account for approximately 20 % of all mediastinal tumours, and 10 to 15 % of anterior mediastinal mass. Most of them occur near or within the thymus. Germ cell tumor usually found in children and young adults.^{14,13} The mean age at presentation is 27 years old. Overall more than 80% of germ cell tumor

are benign with the large majority of these being benign teratoma. Ninety percent of malignant mediastinal germ cell tumor occur in men as seminoma and non seminomatous type.^{3,4}

Malignant germ cell tumor secrete Lactic Dehydrogenase (LDH), α Fetoprotein (α FP) & β - human chorionic gonadotropin (β HCG). These tumor markers are useful for the diagnosis and follow up of therapy.

Mediastinal seminoma is most common among patient with malignant tumor representing 30% of cases and usually symptomatic. Mediastinal seminoma typically occurs in white males in their 3rd and 4th decades of life. Ten percent of patients may have an elevated β HCG but never have elevated α FP.^{4,13} Mediastinal seminoma has a good response to chemo radiation.^{4,13}

Mediastinal non seminomatous tumor is a heterogenous group of tumors including embryonal cell carcinoma, endodermal sinus tumors, choriocarcinoma or mixed germ cell tumors composed of multiple histological features. These tumors are malignant, aggressive behavior, poor prognosis and typically cause symptoms in young adult men. LDH, α FP and β - HCG are frequently elevated.^{4,13}

CLASSIFICATION

Anterior mediastinal masses.^{11,12}

1. Thymic masses:
 - Thymoma
 - Thymic hyperplasia
 - Thymic ca
 - Thymic carcinoid
 - Thymolipoma
2. Thyroid masses.
3. Germ cell tumor (GCT) :
 - Mature teratoma . (70 % of GCT).
 - Seminoma.
 - Non seminoma.
4. Lymphoma.

DIFFERENTIAL DIAGNOSIS

The differential diagnosis of the mediastinal masses depends on the some criteria:

- The age of the patient.
- The location of the mass.
- The imaging technique used to evaluate the mass and
- Findings on imaging examination.

The key point in making the differential diagnosis of a mediastinal masses are to be confident that the mass origins from the mediastinum and not from other organs like lung, pleura, spine or sternum.^{2,4}

IMAGING FEATURE^{2,4-6,8}

MEDIASTINAL SEMINOMA :

CHEST X RAY

Chest X Ray finding show a large, lobulated, anterior mediastinal mass projecting to one or both side of the mediastinum and often obscuring a portion of the heart.

ENHANCED CHEST CT

Chest CT features are large, smooth or lobulated mass, homogenous soft tissue density with small areas of low attenuation can be seen. Obliteration of fat plane is common, invasion to adjacent structure is rare but possible to metastase to regional lymph node and bone. Pleural and pericardial effusion could be present.

MEDIASTINAL NON SEMINOMA :

CHEST X RAY

Chest X Ray show large lobulated anterior mediastinal masses and may be ill defined margin or associated with pleural effusion and possible metastasis to the lung.

ENHANCED CHEST CT

Chest CT features are often large irregular anterior masses with extensive central heterogenous area of low attenuation due to necrosis, hemorrhage, cyst formation and peripheral contrast enhancement, they shows local invasion. Nodal and distant metastasis are frequently. They often appear infiltrative, with obliteration of fat plane and may be speculated. Calcification can be seen. Some times there are pleural and pericardial effusion due to metastasis and may be bilateral.

DISCUSSION

This paper has reported two cases of a 17 and 15 year old male with diagnosis of non seminomatous and seminoma anterior mediastinal germ cell tumor which was similar to some literatures that non seminomatous and seminoma germ cell tumor almost found in a young men.^{3,4}

The patients came to Persahabatan Hospital with chief clinical complain of dispnoe, no history of testicular and peritoneal mass. It was similar to some literatures that anterior mediastinal germ cell tumor almost found in a large mass and compression of the vena cava superior and come to the Hospital with complain of dyspnoe or venectasi.^{2,4}

The first patient a 17 year old male, finding from chest x ray and chest CT, there is a large anterior mediastinal mass, with heterogenous density, no calcification, capsulated, peripheral enhancement, compression of superior vena cava and multiple nodule in both of the lung. This findings were suspicious of an anterior mediastinal germ cell tumor with the differential diagnosis as non seminomatous germ cell tumor and Lymphoma due to heterogenous density, peripheral enhancement with multiple nodule in both of the lung. Increased sero markers of LDH, β HCG, and α fetoprotein give more confidences to the diagnosis of non seminomatous germ cell tumor. Cytological finding from Trans Thoracal Neddle Aspiration (TTNA) guided CT from the left lung mass, established the diagnosis. This findings were similar to some literatures has been reported.^{2,4-10} In the second case, reported a 15 years old male.

Finding from the chest x ray shows mediastinal widening suspicious of mass. Enhanced chest CT was done and demonstrated a large lobulated, encapsulated homogenous anterior mediastinal mass, no calcification and there is compression of vena cava superior due to mass. The differential diagnosis were germ cell tumor, lymphoma and thymoma due to homogenous mass with peripheral enhancement. Only sero marker of β HCG was increased. It was a sign of seminoma germ cell tumor. Cytological finding from TTNA guided CT established the diagnosis of seminoma germ cell tumor. This findings were similar to some literatures has been reported.^{2,4,13} There is any discrepancy in this second case with some literatures, that seminoma germ cell tumor usually found in 3 and 4 th decade of life but in this case the patient age of 15 year. Evaluation chest CT after chemotherapy, decreasing of the mass size more than 50%. This finding similar to literatures that seminoma has good response to chemo radiation.^{4,13}

CONCLUSION

This paper has reported two different type of anterior mediastinal malignant germ cell tumor which were consist of non seminomatous and seminoma germ cell tumor. The chief complain is dyspnoe due to compression of the superior vena cava. The chest x ray is the first imaging done in this cases. Abnormal mediastinal contour in chest x ray, is one of the most common aspect requiring chest CT. Sero markers has been done to help the diagnosis. Cytology from TTNA guided CT was done as a gold standard to established the diagnosis.

Chest CT has been the routine imaging modality of choice and paramount important not only for diagnosis and guided TTNA but for evaluate the treatment. Correct diagnosis for proper management needs good cooperation between Clinician, Pathologist and Radiologist.

REFERENCES

1. Stollo JS, Rosado de Christenson ML. Primary mediastinal malignant germ cell neoplasms : imaging features. *Chest Surg Clin N Am* 2002;12: 645-58.
2. Hansell: MDavid, Armstrong P, Lynch A David, Adams Mc H Page. Mediastinal and aortic disease in : Imaging of diseases of the chest; 4 th edition. Philadelphia: Elsevier Mosby ; 2005,page 921-26.
3. Rosado- de- Christenson ML, Templeton PA, Moran CA. From the archives of the AFIP. Mediastinal Germ cell tumors: radiologic and pathologic correlation. *RadioGraphics* 1992; 12: 1013-30.
4. Lau S, Yeung WH, Kwan WH, Cheng CS, Lam HS. Computed Tomography of anterior Mediastinal Masses. *JHK Coll Radiol* 2003;6:100-6.
5. Polansky SM, Barwick KW, Ravin CE. Primary mediastinal seminoma. *AJR Am J Roentgenol* 1979;132:17-21.
6. Lee KS, Im JG, Han CH,et al. Malignant primary germ cell tumors of the mediastinum: CT features. *AJR*

- 1989;153:947-51.
7. El- Khatib M, Chew FS. Embryonal carcinoma of the anterior mediastinum. *AJR* 1998;170:722.
8. Levitt RG, Husband JE, Glazer HS. CT of primary germ cell tumors of the mediastinum. *AJR* 1984; 142:73- 8.
9. Mori K, Eguchi K, Moriyama H, et al. Computed tomography of anterior mediastinal tumors. Differentiation between thymoma and germ cell tumor. *Acta radiol* 1987;28:395-8.
10. Panicek DM, Toner GC, Heelan RT, et al. Non seminomatous germ cell tumors: enlarging masses despite chemotherapy. *Radiology* 1990;175:499-502.
11. Fausto, Abbas, Kumar, Robbins and Cotran. Pathologic Basis of diseases. 7th edition Elsevier Saunders 2005.
12. Shimosato Y, Mukai K. Tumors of the mediastinum in Atlas of tumor pathology. Published by Armed forces institute of pathology 1997. Page 183-205.
13. Stollo DC, Rosado-de-Christenson LCML, Jett JR. Primary Mediastinal tumors. Part I. Tumors of the anterior mediastinum. *Chest* 1997; 112:511-22.