

Stereotactic Ablative Body Radiotherapy (SABR) in The Management Spinal Metastases: A Brief Overview*

HENRY KODRAT, SOEHARTATI GONDHOWIARDJO

Department of Radiotherapy, Dr. Cipto Mangunkusumo National Hospital, Jakarta, Indonesia

Diterima: 10 Oktober 2016; Diriview: 17 Oktober 2016; Disetujui: 15 Desember 2016

ABSTRACT

It is well known that radiotherapy provides successful pain relief in bone metastases. Advancements in imaging and radiotherapy delivery technology have enabled safe delivery of higher dose radiotherapy, which will produce more durable tumor control. Over the last decades stereotactic radiosurgery (SRS), which delivers high dose radiation, has been successfully used for the treatment of intracranial lesions. The good results obtained in SRS have led to development of extra cranial stereotactic radiosurgery known as stereotactic ablative body radiotherapy (SABR). This review paper enlightens indication, target definition, efficacy and toxicity in spinal SABR.

Keywords: spinal, metastasis, stereotactic, radiotherapy

ABSTRAK

Radioterapi telah terbukti sebagai modalitas yang dapat menghilangkan nyeri pada metastases tulang. Kemajuan dalam teknologi pencitraan dan pemberian radioterapi telah memungkinkan pemberian radioterapi dosis tinggi dengan aman, di mana hal ini dapat meningkatkan kontrol lokal. Selama dekade terakhir ini, *stereotactic radiosurgery* (SRS) yang memberikan radiasi dosis tinggi dinyatakan bermanfaat untuk tatalaksana berbagai kelainan intrakranial. Hasil cukup memuaskan yang diperoleh SRS mendorong untuk dikembangkan *stereotactic radiosurgery* ekstrakranial yang kemudian dikenal sebagai *stereotactic ablative body radiotherapy* (SABR). Tinjauan pustaka ini menjelaskan indikasi, target radiasi, efektivitas, dan efek samping pada prosedur SABR spinal.

Kata Kunci: spinal, metastases, stereotaktik, radioterapi

INTRODUCTION

Bone metastasis is one of manifestations, which is often found in malignancy patients. Bone metastasis can cause debilitating effects, especially if metastasis locates in the spine. This is because spinal metastasis can cause not only pain and pathologic fractures as a usual problem in bone metastasis but also spinal cord compression. Spinal cord compression can produce mild to severe neurological symptoms. Spinal metastases can be found in 30-50% of patients with malignancies.¹⁻³

Radiotherapy has been recognized as an important modality in the treatment of bone metastasis. This is due to radiotherapy has been proved in pain relief in 50-80% patients with bone metastasis. Moreover, one-third of patients can achieve complete pain relief.¹⁻³

KORESPONDENSI:

**dr. Henry Kodrat,
SpOnk Rad**

Department
of Radiotherapy,
Dr. Cipto Mangunkusumo
National Hospital,
Jakarta, Indonesia
Email:
henrykodrat@gmail.com

This review paper enlightens the stereotactic ablative body radiotherapy (SABR) as an emerging modality in radiotherapy, and indication, target definition outcome and toxicity in spinal SABR.

MANAGEMENT DECISION IN BONE METASTASES

Spinal metastasis can cause spinal cord compression. In the past, treatment of spinal cord compression was with corticosteroids and radiotherapy. The role of surgical decompression was not yet known. Patchell et al conducted study to compare surgical decompression followed by radiotherapy with radiotherapy alone. The study shown that the decompression surgery can improve the ability to walk after treatment, and reduce the use of steroids and analgesics.²⁻⁴

The management of spinal metastasis requires multi-disciplinary approach involving surgery, radiotherapy, chemotherapy and physical medicine and rehabilitation. The management decision in spinal metastasis needs to consider various aspects such

as neurology, oncology, mechanical stability and systemic disease. These should be assessed before the commencement of treatment. Neurological functions can be assessed with degree of spinal cord compression, myelopathy and functional radiculopathy. The degree of spinal cord compression can be assessed by Magnetic Resonance Imaging (MRI) and it is classified based on Bilsky grading system. Oncology assessment address histopathology type of the tumor, which will determine the radiosensitivity of tumor in relation with conventional radiotherapy. Mechanical stability assesses for the possibility of pathologic fracture. Spinal instability can be defined as loss of spinal integrity as a result of a neoplastic process, which is associated with movement-related pain, symptomatic or progressive deformity and/or neural compromise under physiologic loads. Mechanical stability can be assessed with spine instability neoplastic score (SINS). Systemic disease assesses metastasis disease, comorbidities and performance status, which is related with patient survival.^{2,5}

Table 1: Decision framework in spinal metastasis⁵

Neurologic	Oncologic	Mechanical	Systemic	Management decision
Low grade ESCC (epidural spinal cord compression) + no myelopathy	Radiosensitive	Stable		cEBRT
	Radiosensitive	Unstable		Stabilization followed by cEBRT
	Radioresistant	Stable		SRS
	Radioresistant	Unstable		Stabilization followed by SRS
	Radiosensitive	Stable		cEBRT
	Radiosensitive	Unstable		Stabilization followed by cEBRT
High grade ESCC +/- myelopathy	Radioresistant	Stable	Able to tolerate surgery	Decompression/stabilization followed by SRS
	Radioresistant	Stable	Unable to tolerate surgery	cEBRT
	Radioresistant	Unstable	Able to tolerate surgery	Decompression/stabilization followed by SRS
	Radioresistant	Unstable	Unable to tolerate surgery	Stabilization followed by cEBRT

ESCC: Epidural spinal cord compression; cEBRT: conventional external beam radiotherapy; SRS: stereotactic radiosurgery.

STEREOTACTIC ABLATIVE BODY RADIOTHERAPY (SABR)

The application of stereotactic radiosurgery was widely known when in 1967, when dr. Lars Leksell introduced GammaKnife in treating various intracranial disorders. In concordance with the development of radiotherapy technology, a linear accelerator (LINAC) had been modified so it could also delivered cranial radiosurgery. The application of LINAC in cranial

radiosurgery has been used since 1982. Because of satisfactory result in cranial radiosurgery, radiosurgery began to be used for extra-cranial abnormalities. It started since 1991 for cases of lung and liver tumors and it was known as stereotactic body radiotherapy (SBRT). Because we try to deliver high ablative dose, so it can also be referred as stereotactic ablative body radiotherapy (SABR).^{6,7}

SABR uses the stereotactic principle in radiotherapy delivery because the delivery of high ablative dose needs a high accuracy. Stereotactic is a concept that uses three-dimensional coordinate system to define the target location. Stereotactic 3-dimensional coordinates can be divided into external stereotactic coordinates that are usually attach to the fixation frame such as Allan Hamilton fixation method and internal stereotactic coordinate, which usually uses image-guidance localization method for the verification of the target. The image-guidance localization method can use either cone-beam CT-Scan or orthogonal with kilo voltage images (x-ray stereoscopic). Stereoscopic is a 3 dimensional measurement method using two

or more 2-dimensional images intersect, which will produce a 3 dimensional coordinates for each image, which is intersecting.⁶⁻⁹

There are several characteristics in SABR such as high degree of accuracy because of stereotactic principle, high conformity to the shape of the target, fix immobilization, steep dose fall off outside the target and high ablative radiation dose. Because of high dose, it requires distance between the tumor and healthy organs so it allows for steep dose fall off and it can only be delivered in small-size tumor. SABR refers not only to single fraction but also hypofractionated up to 5 fractions.⁶⁻⁹

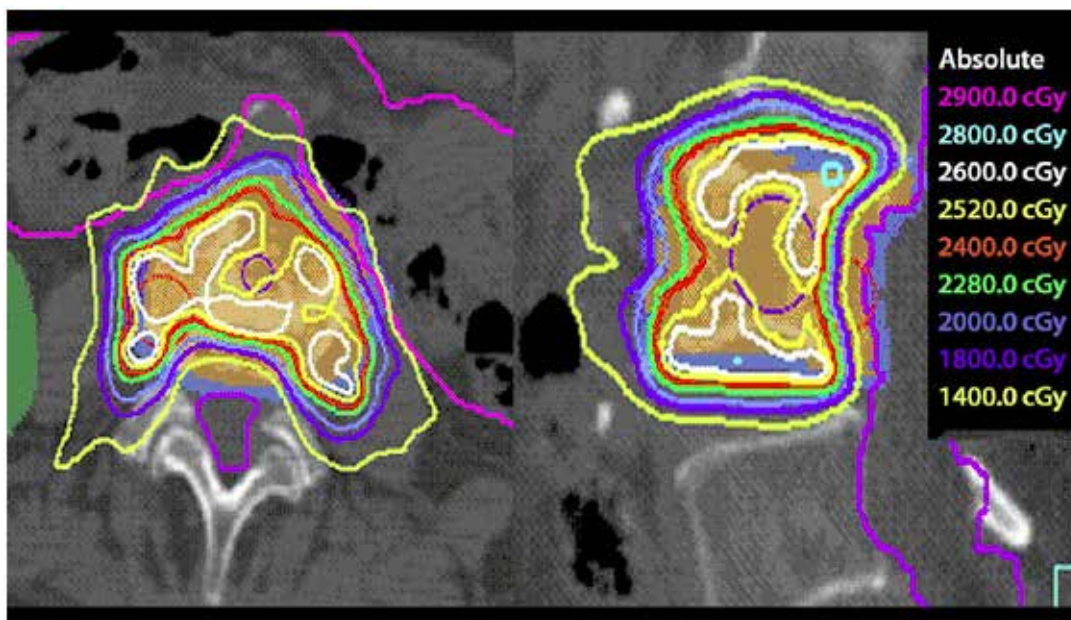


Figure 1: Spinal metastasis SABR delivered in a single fraction with 24 Gray(Gy) dose (red line). We can see steep dose fall off distribution between the vertebrae and the spinal cord (the purple line)⁹

There are several platforms that can perform SBRT such as LINAC system, Cyberknife, Novalis and TomoTherapy. All of these existing systems use the principle of image-guidance. The image guidance method applies the imaging technology to verify the position of the target before the radiotherapy delivery. LINAC and TomoTherapy is equipped with cone-beam CT-Scan for verification, while Novalis and Cyberknife uses orthogonal kV images for verification.⁷⁻⁹

INDICATION

SABR may be indicated in certain circumstances. SABR can be delivered if patient meet the following indication and there is no contraindications for SABR procedure. The following table illustrates some of the indications and contraindications for spinal metastases SABR based on evidence-based clinical guidelines from the American Society for Radiation Oncology (ASTRO).^{2,8}

Table 2: Summary of indications and contraindications for spinal metastasis SABR according to ASTRO guideline²

Characteristics	Indication	Contraindications
Radiology	Spinal or paraspinal metastasis by MRI No more than 2 consecutive or 3 noncontiguous spine segments involved	Spinal MRI cannot be done Epidural spinal cord or cauda equina compression Spinal canal compromise > 25% Unstable spinal requiring surgical stabilization Tumor location within 5 mm of spinal cord or cauda equina (relative)
Patients	Age 18 yo KPS 40 - 50 Medically inoperable or patient refused surgery	Active connective tissue disease (ex: scleroderma) Worsening or progressive neurologic deficit Inability to lie flat on table for SABR < 3 months life expectancy
Tumor	Histo-pathologic confirmation of malignancy Biopsy of spine lesion if first suspected metastasis	Radiosensitive tumor such as multiple myeloma Extra spinal disease not eligible for further treatment
Previous treatment	Previous EBRT <45 Gy total dose Failure of previous surgery at that level Presence of gross residual disease after surgery	Previous SBRT to same level Systemic radionuclide delivery within 30 days before SBRT EBRT within 90 days before SBRT Chemotherapy within 30 days of SBRT

Abbreviation: KPS: Karnofsky performance scale, EBRT: external beam radiotherapy

In addition to the ASTRO criteria, we can also incorporate additional criteria based Radiation Therapy Oncology Group - 0631 (RTOG 0631), which stated that there should be a distance between the spinal cord and tumor ≥ 3 mm and paraspinal mass diameter should less than 5 cm.¹⁰

TARGET DEFINITION

MRI is recommended for target definition in spinal metastases SABR. In spinal SABR target definition, we must incorporate visible tumor mass with CT-Scan and MRI, including epidural and paraspinal mass and also adjacent area to account for subclinical tumor spread. International spine radiosurgery consortium has issued guidelines for target volume definition in spinal SABR. This guideline classifies vertebrae bones into six compartments, consists of body, the right pedicle, right transversus process and lamina, spinosus process, left transversus process and lamina and the left pedicle. In spinal SABR target definition, if the tumor mass close to adjacent compartment, we must include adjacent compartment in target volume to eliminate the possibility of microscopic spread. PTV margin should less than 3 mm because of fix immobilization and the application of image-guided. PTV margins can be adjusted in the area adjacent

to the spinal cord so that there is a distance between tumor and spinal cord. It is useful for step dose fall off become possible.^{2,11}

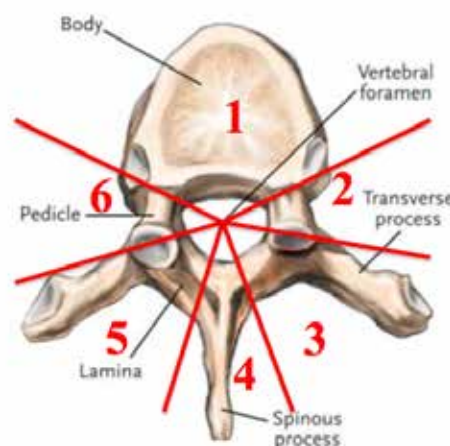


Figure 2: The anatomy classification system based on the compartment for target definition in spinal radiosurgery¹¹

Target definition recommendation for postoperative spinal metastases SABR should involve all regions of preoperative lesions including bone, epidural extension and the adjacent compartment, which is possible to harbor microscopic disease. Internal fixation is not included in the target volume.¹²

TREATMENT OUTCOME

SABR treatment effects for spinal metastases are not only in pain relief as conventional radiotherapy for bone metastases in general, but also for local control, spinal cord decompression and improvement of neurological function. Currently, there is no phase 3 data compares SABR to conventional radiotherapy in spinal metastasis management. The available data are based on phase 2 data. Saghal et al. is still collecting data to compare SABR to conventional radiotherapy. This protocol compares SABR, which delivered 12 Gy/fraction for 2 fractions with conventional radiotherapy 4 Gy/fraction for 5 fractions. The primary end-point is pain control.¹³

SABR showed a good response in pain relief. Wang et al. reported that patients with no pain were increased from 26% in pre-SABR group to 54% in post-SABR group, and also accompanied by a reduction in opioid use 8.9% at 6 months post-SABR. Ryu et al. reported that the overall pain control for

1 year was 84% and median duration of pain relief at the treated level was 13.3 months.^{14,15}

Yamada et al. reported SABR with 24 Gy dose in single fraction with a median follow-up of 15 months; Local control rate was 90%; Median time to local failure was 9 months; and the median survival time was 15 months. In all cases of death were caused by systemic disease progression and not by the local failure. Wang et al. reported 1-year and 2-years progression free survival post-SABR was 80.5% and 72.4% respectively.^{15,16}

Ryu et al. evaluated not only pain response, but also tumor shrinkage response and improvement of neurological function. In this study, Ryu obtained tumor shrinkage response 2 months post-SABR was 65 ± 14%. The tumor shrinkage caused thecal sac patency improved 20%. Also neurological function improved as much as 81%. When compared with the study by Patchell et al. overall ambulatory rate was 84% and it was almost comparable with study by Ryu et al., which overall intact rate was 81%.^{4,17}

Table 3: Literature review of the spinal metastasis SABR outcome

Author & year	N	Dose/fraction	Follow-up	Pain response	Local control	Neurologic function	Tumor reduction
Yamada (MSKCC), 2008. ¹⁵	103	18 – 24 Gy/1 fraction	Median 15 months	NS	90%	NS	NS
Wang (MDACC), 2012. ¹⁴	149	27-30 Gy/3 fractions	Median 15.9 months	26% no pain pre SBRT increased to 54% 6 months after SBRT (BPI) Strong opioid use declined from 29.9% to 20%	1 year PFS 80.5% 2 year PFS 72.4%	NS	NS
Ryu, 2008. ¹⁶	49	10 – 16 Gy	NS	Overall pain control 1 year: 84%	NS	NS	NS
Ryu, 2010. ¹⁷	62	12 – 20 Gy/1 fraction Median 16 Gy	Median 11.5 months	NS	NS	Improved in 81%	65±14% at 2 months
Ryu (RTOG 0631), 2014. ¹⁰	44	16 – 18 Gy/1 fraction	NS	NS	NS	NS	NS

NS: Not specify; BPI: brief pain inventory, MSKCC: Memorial Sloan Kattering Cancer Center; MDACC: MD Anderson Cancer Center; PFS: Progression free survival.

TOXICITY

There are 2 toxicities which become an issue in spinal SABR, which are radiation myelopathy and vertebrae compression fracture. The other toxicity, which can occur in spinal SABR are related to the location of the lesion. Some example of other toxicities is cough, dyspepsia, esophagitis and pruritus, but they usually occur in low grade.^{10,18-20}

Saghal et al. has issued guidance to predict radiation myelopathy after SABR according to thecal sac point maximum (Pmax). This model described radiation myelopathy probability of 1 – 5% for SABR single fraction up to five fractions. For single fraction SABR with Pmax of 9.2 Gy, the probability of myelopathy is nearly 9.2% and Pmax of 12.4 Gy, the probability of myelopathy is nearly 5%. For hypofractionated SABR in 3 fractions with the total Pmax of 14.8 Gy, the myelopathy probability is 1%, while the total Pmax of 20.3 Gy, the myelopathy probability is approximately 5%. American Association of Physicist in Medicine (AAPM) recommends D0.035 cc as a maximum dose reference.¹⁸

Vertebral compression fractures occurs due to a decrease in vertebrae bone quality. This is associated with not only osteolytic and osteoblastic disease, but also radiotherapy. Radiotherapy can cause damage to the collagen, which leads in reduction in bone strength. SABR can also cause osteoradionecrosis of bone and tumor tissues. There are several factors predictors of this complications, which are vertebral body collapse $\geq 50\%$, SABR dose > 19 Gy, abnormal bone alignment and lytic bone lesion type.^{19,20}

CONFLICT OF INTEREST

None of the authors have any conflict of interest to declare.

CONCLUSION

SABR is an advanced technology in radiotherapy modalities in spinal metastasis management. It is delivered mainly in case, which meets the following criteria such as radio-resistant tumors, small size and low degree of spinal cord compression. The outcome of SABR is not only pain relief, but also local tumor control and improvement of neurological function as well as decompression of the spinal cord. The issue that we should keep in mind that SABR need latency period until the effect appears, which is represented by the improvement of clinical

symptoms. If we need rapid response in high-grade spinal cord compression, surgery should be performed first. The advantage of SABR compared with conventional radiotherapy needs to be determined further.

REFERENCES

1. Chow E, Zeng L, Salvo N, Dennis K, Tsao M, Lutz S. Update on the systematic review of palliative radiotherapy trials for bone metastases. *Clin Oncol* 2012;24:112–124. DOI: 10.1016/j.clon.2011.11.004
2. Lutz S, Berk L, Chang E, Chow E, Hahn C, Hoskin P et al. Palliative radiotherapy for bone metastases: an ASTRO evidence-based guideline. *Int J Radiat Oncol Biol Phys.* 2011;79(4):965-974. DOI: 10.1016/j.ijrobp.2010.11.026
3. Ejima Y, Matsuo Y, Sasaki R. The current status and future of radiotherapy for spinal bone metastases. *J Orthop Sci.* 2015;20:585–592. DOI: 10.1007/s00776-015-0720-x
4. Patchell RA, Tibbs PA, Regine WF, Payne R, Saris S, Kryscio RJ et al. Direct decompressive surgical resection in the treatment of spinal cord compression caused by metastatic cancer: a randomized trial. *Lancet* 2005;366:643–648. DOI: 10.1016/S0140-6736(05)66954-1
5. Laufer I, Rubin DG, Lis E, Cox BW, Stubblefield MD, Yamada Y et al. The NOMS framework: approach to the treatment of spinal metastatic tumors. *The Oncologist* 2013;18:744-751. DOI: 10.1634/theoncologist.2012-0293
6. Solberg TD, Siddon RL, Kavanagh B. Historical development of stereotactic ablative radiotherapy. In: Lo SS, The BS, Lu JJ, Schefter TE (ed) *Stereotactic body radiation therapy*. Berlin: Springer 2012; P. 9- 35
7. Fuss M, Boda-Heggemann J, Papanikolaou N, Saiter BJ. Image-guidance for stereotactic body radiation therapy. *Med Dosim* 2007;32(2):102–110. DOI: 10.1016/j.meddos.2007.01.007
8. Saghal A, Larson DA, Chang EL. Stereotactic body radiosurgery for spinal metastases: A critical review. *Int J Radiat Oncol Biol Phys.* 2008;71(3):652–665. DOI: 10.1016/j.ijrobp.2008.02.060
9. Sangha A, Korol R, Saghal A. Stereotactic body radiotherapy for the treatment of spinal metastases: an overview of the university of Toronto Sunnybrook Health Sciences Odette Cancer Center, technique. *J Medic Imag Radiat Scienc.* 2013;44:126–133. DOI: 10.1016/j.jmir.2013.04.002
10. Ryu S, Pugh SL, Gertzen PC, Yin FF, Timmerman RD, Hitchcock YJ et al. RTOG 0631 phase 2/3 study of image guided stereotactic radiosurgery for localized (1-3) spine metastases: phase 2 results. *Prac Radiat Oncol.* 2014(4);76–81. DOI: 10.1016/j.ppro.2013.05.001

11. Cox BW, Spratt DE, Lovelock M, Bilsky MH, Lis E, Ryu S. International spine radiosurgery consortium consensus guideline for target volume definition in spinal stereotactic radiosurgery. *Int J Radiat Oncol Biol Phys.* 2012; 83(5): 597-605. DOI: 10.1016/j.ijrobp.2012.03.009
 12. Reymond KJ, Robertson S, Lo SL, Soltys SG, Ryu S, McNutt T et al. Consensus contouring guidelines for post-operative stereotactic body radiation therapy (SBRT) for metastatic solid tumor malignancies to the spine. *Int J Radiat Oncol Biol Phys.* 2016; article in press. DOI: 10.1016/j.ijrobp.2016.09.014
 13. NCIC clinical trials group: Feasibility study comparing stereotactic body radiotherapy vs conventional palliative radiotherapy in spinal metastases. 2016.
 14. Ryu S, Jin R, Jin JY, Chen Q, Rock J, Anderson J et al. Pain control by image-guided radiosurgery for solitary spinal metastases. *J Pain Symptom Manage* 2008; 35(3): 292-298. DOI: 10.1016/j.jpainsymman.2007.04.020
 15. Wang XS, Rhines LD, Shiu AS, Yang JN, Selek U, Gning I et al. Stereotactic body radiation therapy for management of spinal metastases in patients without spinal cord compression: a phase 1-2 trial. *Lancet Oncol.* 2012;13:395–402. DOI: 10.1016/S1470-2045(11)70384-9
 16. Yamada Y, Bilsky MH, Lovelock DM, Venkatraman ES, Toner S, Jhonson J et al. High-dose, single-fraction image-guided intensity-modulated radiotherapy for metastatic spinal lesion. *Int J Radiat Oncol Biol Phys.* 2008;71(2):484 – 490. DOI: 10.1016/j.ijrobp.2007.11.046
 17. Ryu S, Rock J, Jain R, Lu M, Anderson J, Jin JY et al. Radiosurgical decompression of metastatic epidural compression. *Cancer* 2010;116(9):2250–2257. DOI: 10.1002/cncr.24993
 18. Saghal A, Weinberg V, Ma L, Chang E, Chao S, Muacevic A et al. Probabilities of radiation myelopathy specific to stereotactic body radiation therapy to guide safe practice. *Int J Radiat Oncol Biol Phys.* 2013;85(2):341–347. DOI: 10.1016/j.ijrobp.2012.05.007
 19. Saghal A, Whyne CM, Ma L, Larson DA, Fehlings MG. Vertebral compression fracture after stereotactic body radiotherapy for spinal metastases. *Lancet Oncol.* 2013;14:310–320. DOI: 10.1016/S1470-2045(13)70101-3
 20. Saghal A, Atenafu EG, Chao S, Omair AA, Boehling N, Balagamwala EH et al. Vertebral compression fracture after spine stereotactic body radiotherapy: A multi-institutional analysis with a focus on radiation dose and the spinal instability neoplastic score. *J Clin Oncol.* 2013;31:3426–3431. DOI: 10.1200/JCO.2013.50.1411
- * This review article was presented at The Inaugural Meeting of North American Spine Society (NASS), International Society for Minimal Intervention in Spinal Surgery (ISMIS), and Indonesian Spine Society (ISS) - NASSISMIS 2016. Bali, September 23 – 24, 2016.