



## CASE REPORT

**Bilateral Optic Neuritis as an Atypical Presentation of Primary Sjögren's Syndrome (pSS)****Authors:**

Denisa Rosati<sup>ORCID</sup>  
Lukisiari Agustini\*<sup>ORCID</sup>

**Affiliations:**

Department of Ophthalmology,  
Faculty of Medicine, Universitas  
Airlangga—RSUD Dr. Soetomo  
Surabaya, Indonesia.

**Corresponding author:**

Lukisiari Agustini  
lukisiari.agustini@fk.unair.ac.id

**Dates:**

Received: 28 October 2021  
Revised: 10 June 2022  
Accepted: 15 June 2022  
Published: 27 July 2022

**DOI:**

<https://doi.org/10.20473/vsehj.v1i3.2022.72-76>

**Copyright:**

© 2022 Author(s). Open access under Creative Commons Attribution-Share Alike 4.0 International Licence (CC-BY-SA).

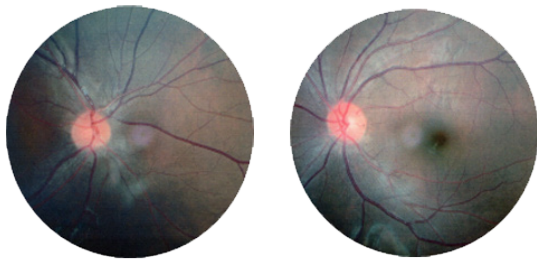
**Abstract**

**Introduction:** Primary Sjögren's syndrome (pSS) is a chronic progressive autoimmune disease that primarily affects exocrine glands with varying symptoms. Here we discuss atypical optic neuritis as an initial presentation of pSS without any sicca symptoms. **Case presentation:** A 22-year-old woman came to the outpatient clinic with the chief complaint of rapid deteriorating visual acuity that had started one week before—no complaint of the eye or other mucosal dryness. At the initial visit, best corrected visual acuity (BCVA) was hand movement on the right eye and 6/7.5 on the left eye with decreasing color perception. Fundus examination showed bilateral optic nerve head edema. Schirmer test and tear-film break up time were within normal limits. After the initial one gram intravenous methylprednisolone treatment, no significant changes were observed for three consecutive days. Serological investigations revealed raised levels of SS-A native. Improvement happened after being given azathioprine. **Conclusion:** Optic neuritis may be the initial presentation of Sjögren's syndrome without sicca symptoms. The presence of a specific antibody, including anti-SSA, is supportive for the diagnosis of such a case.

**Keywords:** primary Sjögren's syndrome (pSS); optic neuritis; anti-Sjögren's syndrome A

**Introduction**

Optic neuritis is an optic nerve inflammation, where the most common cause is idiopathic. However, this disease can also be associated with several conditions such as demyelinating disease, autoimmune disease, infection, and inflammation. Dominant optic neuritis affects a healthy young woman with subacute decreased visual acuity symptoms with unilateral pain. Optic neuritis is the most common optic neuropathy in patients under 50 years of age, and as much as 20% is an early sign of multiple sclerosis (MS).<sup>[1]</sup> Common complaints of optic neuritis include impaired subacute monocular visual acuity, flashes or flickering lights, discomfort or pain around the eye (90%) on eye movement due to contraction of the eyeball muscle that pulls the optic nerve sheath, headache, visual field disturbances, widening of the blind spots (focal central/altitudinal/arcuata), impaired color vision (dyschromatopsia), presence of relative afferent pupillary defect (RAPD) and optic disc appears edema in papillitis.<sup>[2]</sup> Sjogren's syndrome is a chronic progressive autoimmune disease with periductal lymphocytic infiltration in the exocrine secretory glands, especially the salivary and tear glands. This causes dryness of the mucous membranes throughout the body and the appearance of systemic symptoms due to an inflammatory reaction or vasculitis and can be accompanied by neurological disorders.<sup>[3]</sup> Based on data, the incidence of optic neuritis worldwide is 0.94-2.18 per 100.000 person/year, with 1.62 per 100.000 person/year in Japan. Female predominance was 1:3 in a European cohort study<sup>[4]</sup>. Clinical manifestations of Sjogren's syndrome include dry eye symptoms, xerostomia, edema of the salivary gland, dry skin, and persistent dry cough. Optic neuritis caused by Sjogren's syndrome is very rare. According to a retrospective study by Tang and Wei<sup>[3]</sup>, out of 128 patients treated



**Figure 1.** Fundus picture of right and left eye showed bilateral edematous optic disc on initial presentation.

with optic neuritis, only eight people had Sjogren's syndrome. Of the eight people, only three people with dry eye manifestations, while the others were diagnosed based on the results of the ANA profile test (SS-A and SS-B).<sup>[3]</sup> According to Shiboski et al.<sup>[5]</sup> diagnostic criteria for Sjogren's syndrome based on complaints of dry eyes for three months (objectively with Schirmer's test < 5 mm for five minutes), serological results of ANA titer > 1:160 with Anti-Ro-SSA and/or positive anti-La/SSB antibodies and abnormal histological examination (salivary gland biopsy) in the form of mononuclear lymphoid cell infiltration in the salivary glands.

There is no standard treatment for optic neuritis associated with Sjogren's syndrome. However, based on previous literature<sup>[6]</sup>, administration of high-dose methylprednisolone for three days followed by oral prednisone can give good results. In addition, immunosuppressive drugs can also be used.<sup>[6]</sup> Here we discuss atypical optic neuritis as an initial presentation of primary Sjögren's syndrome (pSS) without any sicca symptoms.

**Case presentation**

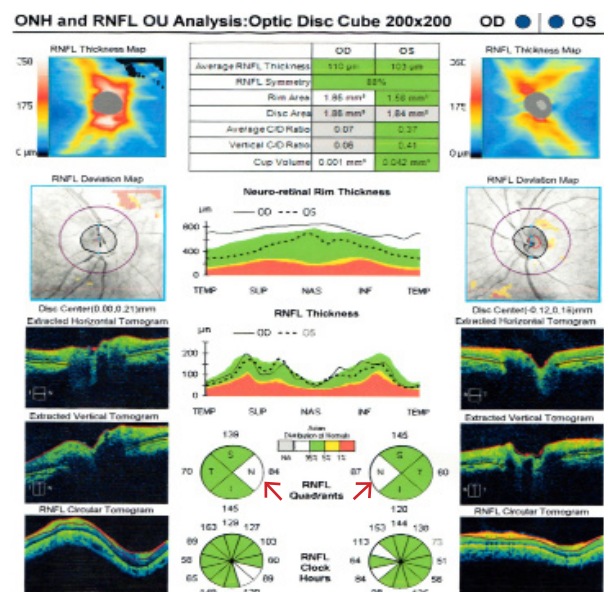
A 22-year-old woman came to the outpatient unit with rapidly deteriorating visual acuity in the right eye one week before being admitted to the hospital. She had blurred vision which was accompanied by eye pain in movement. There was no diplopia, recurrent red eyes, nystagmus, headache, nausea, or vomiting. Seeing black dot, the flash of light and curtain-like vision were denied. The patient also felt a little blurry in the left eye with no pain on movement. No complaints of burning, gritty, itchy, or dry eyes in both eyes. Dry lips and difficulty chewing were denied. The patient was referred from a regional hospital with suspicion of right eye optic neuritis. There was no trauma, history of wearing glasses, eye surgery, or previous systemic disease. History of treatment with oral methylprednisolone 8 mg every eight hours and artificial tears for three days but no improvement of vision.

The general status of the patient was within normal limit. Ophthalmology examination revealed right eye hand movement visual acuity and the left eye visual acuity was 6/20 pinhole improved to 6/7.5. Intraocular

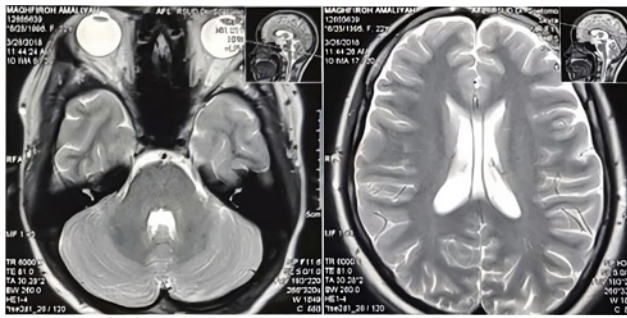
pressure in both eyes was within the normal limit. Examination of color perception in the right eye could not be evaluated, and the left eye was within normal limit. Ocular motility in both eyes was good in every direction but accompanied by pain in the right eye movement. Anterior segment examination revealed no abnormalities except a positive RAPD. It decreased light reflex in the right eye, while in the left eye, the pupil diameter was 3 mm without RAPD. We found positive fundus reflex in the right eye in the posterior segment, blurred margin, hyperemic optic nerve head, and no exudate or bleeding on the retina with a positive macular reflex. We found positive fundus reflex, sharp margin, and hyperemic optic nerve head in the left eye with normal retina and positive macular reflex (Figure 1). We also ran an optical coherence tomography (OCT) examination that revealed an edematous optic nerve head in the nasal quadrants of both eyes (Figure 2).

Using Humphrey field analyzer (HFA), visual field examination found no visual field defect in the left eye, while the right eye could not be evaluated (Figure 3). Brain and orbital (magnetic resonance imaging) MRI with and without contrast showed no mass, infarction, bleeding, or infection process in the brain parenchyma. The right and left optic nerves were normal, and there was no vascular attachment (Figure 4).

We diagnosed the patient with bilateral optic neuritis. Due to acute visual impairment, the patient was hospitalized to receive a one gram injection of methylprednisolone for three consecutive days. During the treatment period, the patient also underwent laboratory tests to look for possible autoimmune disease causes. We have undergone a complete blood investigation with a peripheral smear. Kidney and liver function tests were within normal limits, while the



**Figure 2.** Optic nerve head OCT showed increased RNFL thickness on nasal quadrant both eyes (red arrows)



**Figure 3.** MRI T2 weighted of the orbit showed normal right and left optic nerve without vascular attachment. No infarction, mass, bleeding or infection process on brain parenchyma.

serological antinuclear antibody (ANA) test result was positive at 211.61. The results of C3 C4 and rheumatoid factor were within normal limits. Due to a positive ANA test, our patient was consulted to the internal medicine department. The internist could not establish a definite diagnosis, and it was advised to perform an ANA profile examination. However, the patient could not afford the examination. The patient underwent a visual evoked potential (VEP) examination, which revealed a partial demyelinating prechiasmal lesion on the right side of the visual pathway (Table 1).


Three consecutive days of intravenous methylprednisolone injection showed no significant improvement. The visual acuity of the right eye improved slightly to one meter counting fingers while the left eye was 6/10 pinhole improved to 6/6. The color perception of the right eye was 1/14, while the left eye was within the normal limit. Examination of the posterior segment showed hyperemia in both optic nerve heads with clear boundaries. Furthermore, our patient was steroid tapered off with prednisone 1 mg/kg body weight/day for 14 days orally. The patient was evaluated in the outpatient unit three days later. There was no improvement in visual acuity and color perception. Our patients was re-educated to do an ANA profile examination to find out the cause of the patient's current condition. The ANA profile test revealed a strong positive of SS-A native and Ro-52

recombinant, which were markers of Sjogren's syndrome. We performed a Schirmer's test that showed a reading of more than 10 mm at the end of five minutes, and the tear film break-up time was ten seconds.

Our patient was consulted to the rheumatology division and diagnosed with Sjogren's syndrome. The patient received Azathioprine 50 mg once daily. One week later, the visual acuity changed to 5/60 on the right eye, with color vision improving to 9/14. On the next visit, visual acuity improved significantly to 5/60 pinhole 5/12, and color perception was 12/14. The posterior segment showed significant changes and became firmly demarcated with normal color. After three months of treatment, the BCVA of the right eye was 5/6.6, the left eye was 5/5, the right and left eyes color perceptions were normal. Fundus examination remained the same with the last visit (Figure 5). The patient was decreasing the dose of methylprednisolone and continuing azathioprine.

**Discussion and conclusions**

Sjogren's syndrome is an autoimmune disease that causes exocrine glands throughout the body to die gradually. The lacrimal and salivary glands are the most impacted, causing the most symptoms in the form of the ocular surface and mucosal dryness. This condition can affect the exocrine glands exclusively or as a side effect of other autoimmune diseases.<sup>[7],[8],[9]</sup> Although very rare, optic neuritis can be an early sign of Sjogren's syndrome in which there is no complaint of dry mouth and dry eye. In this case, we found a vague case of Sjogren's syndrome associated with bilateral optic neuritis in a young woman. After detailed history taking, no keratoconjunctivitis sicca nor xerostomia symptoms were found in this patient. A similar case was also reported by Tang et al.<sup>[3]</sup>, which observed eight patients with primary Sjogren's syndrome, all were women, and half of the patients had bilateral optic neuritis. All of the patients initially presented with acute blurred vision, just like our patient with negative serum



**Figure 4.** Humphrey perimetry revealed general depression on the right eye and defect on the left eye at pattern deviation.

**Table 1.** Visual Evoked Potential examination shows partial demyelinating prechiasma lesion on right visual pathway.

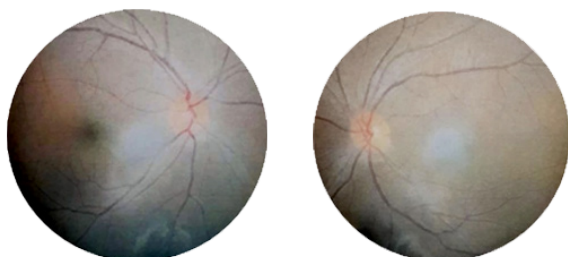
Trace	VEP (3 Ch)			
	N75 (mm)	P100 (mm)	N145 (mm)	N75-P100 ( $\mu$ V)
Norm		< 117		
Ch1 O1 - Cz R	82.0	102.3	124.2	3.64
Ch2 Oz - Cz R	80.9	102.0	123.8	6.28
Ch3 O2 - Cz R	77.0	93.4	122.7	4.03
Ch1 O1 - Cz L	67.6	84.8	105.5	8.32
Ch2 Oz - Cz L	68.4	86.7	103.5	9.54
Ch3 O2 - Cz L	66.8	85.5	109.4	15.06

anti AQP4 antibody titers, so neuromyelitis optic was not taken into consideration.<sup>[3]</sup> Another study from Sun et al.<sup>[6]</sup> also reported some cases of Sjogren's syndrome-related optic neuritis. The seven female patients were all between the ages of 8 and 56. Five of the individuals had never been diagnosed with Sjögren's syndrome before.<sup>[6]</sup> In a case series published by Bak et al.<sup>[11]</sup>, three out of five patients exhibited optic neuropathy as the first sign of primary Sjögren's syndrome without any obvious sicca symptoms.

Until now, the pathogenesis of Sjogren's syndrome with the clinical presentation of optic neuropathy is unknown. Several studies suggest this could be due to the presence of salivary gland targets with the Central Nervous System (CNS). Anti-Ro/SSA antibodies have also been examined in Sjogren's syndrome patients to see if they generate cross-reactions with antigens in neurons. A wide range of clinical symptoms of Sjögren's syndrome-related optic neuropathy is caused by many of these processes.<sup>[11]</sup> In this case, we made the diagnosis of pSS based on diagnostic criteria of the American Rheumatology Association<sup>[5]</sup>, including five criteria. Labial salivary gland with localized lymphocytic sialadenitis of >1 foci per mm<sup>2</sup> and a positive anti-SSA antibody titer are the two critical criteria with three points each. Other requirements worth one point each are a > 5 ocular staining score, an unstimulated whole saliva flow rate of less than 1 ml/minute, and a Schirmer's test reading of less than 5 mm at the end of five minutes in at least one eye. Anti-SSA antibody titers were considerably increased after the additional serological examination. Despite the

absence of sicca symptoms in this patient, the presence of anti-SS-A, a Sjögren's syndrome-specific antibody, supports the diagnosis in this uncommon instance of optic neuritis. Anti-SSA and anti-SSB antibodies were shown to be positive in the majority of primary Sjögren's syndrome patients in a prior investigation.<sup>[12],[13]</sup> Patients with visual neuritis caused by primary Sjögren's syndrome may not have any other symptoms. As a result, it is easy to overlook or misinterpret it. There was a diagnostic and therapeutic challenge in this. Misdiagnosis of pSS-associated ON has negative effects. To begin with, it may cause a delay in adequate treatment, as well as unanticipated complications and visual loss.<sup>[14]</sup> Second, misdiagnosis can lead to incorrect therapy and negative outcomes. Five of seven cases in earlier reports were misdiagnosed as primary ON or other eye disorders.<sup>[15],[16]</sup>

Because the patient had no sicca symptoms, treating pSS is also challenging. There is no standard treatment for Sjögren's syndrome-associated optic neuritis. In this case, based on the optic neuritis treatment trial (ONTT), the initial treatment for acute attacks of optic neuritis is high dose corticosteroids of 1000 mg intravenous methylprednisolone daily over three consecutive days followed by oral prednisone 1 mg/kg per day for eleven days and tapering off the dosage gradually. Other choices include oral prednisolone, cyclophosphamide, or plasmapheresis. Treatment for optic neuropathy, such as conventional use of steroid and immunosuppressive agents, do not specifically cure the disease, whereas more specific therapy like biological therapy targeted autoantibodies for better results in autoimmune disease. Serological and histological studies have disclosed the essential function of T cells and B cells in generating inflammation with tissue death in the salivary glands as pathogenesis of Sjögren's syndrome. As a result, autoimmune illnesses have been treated with abatacept, alefacept, and rituximab.<sup>[17]</sup> A case of optic neuritis with impaired vision in a middle-aged woman without a prior diagnosis of pSS was described by Sun et al.<sup>[6]</sup> To improve visual acuity, and the patient was given one

**Figure 5.** Fundus examination after three months medication shows decreased optic disc hyperemia.

gram of methylprednisolone intravenously for three days. Our patient had a methylprednisolone injection followed by a maintenance dosage of prednisone as part of the conventional treatment procedure for optic neuritis, however, no improvement in vision was seen. It emphasizes Sjögren's syndrome's atypical signs, such as optic neuritis, before major disease-related ocular or oral symptoms.<sup>[18],[19],[20]</sup> The patient was diagnosed with Sjögren's syndrome and received oral administration of azathioprine which is effective after steroid tapering

According to thorough research, most patients with optic neuritis do not follow the expected clinical course.<sup>[19]</sup> Although further research is not normally required in typical optic neuritis, neuroimaging is necessary to rule out the potential of multiple sclerosis.<sup>[20]</sup> On the other hand, atypical instances necessitate a more thorough and ongoing assessment. In cases of optic neuritis with an atypical underlying condition, a detailed clinical history, thorough testing, and attentive monitoring are essential.

## References

- [1] Hoorbakht H, Bagherkashi F. Optic neuritis: Its differential diagnosis and management. *Open Ophthalmol J* 2012;6:65–72. <https://doi.org/10.2174/1874364101206010065>.
- [2] Bowling B. *Kanski's Clinical Ophthalmology*. 8th ed. London: W B Saunders; 2015.
- [3] Tang W-Q, Wei S-H. Primary Sjögren's syndrome related optic neuritis. *Int J Ophthalmol* 2013;6:888–891. <https://doi.org/10.3980/j.issn.2222-3959.2013.06.26>.
- [4] Toosy AT, Mason DF, Miller DH. Optic neuritis. *Lancet Neurol* 2014;13:83–99. [https://doi.org/10.1016/S1474-4422\(13\)70259-X](https://doi.org/10.1016/S1474-4422(13)70259-X).
- [5] Shiboski CH, Shiboski SC, Seror R, Criswell LA, Labetoulle M, Lietman TM, et al. 2016 American college of rheumatology/ European league against rheumatism classification criteria for primary Sjögren's syndrome: A consensus and data-driven methodology involving three international patient cohorts. *Arthritis Rheumatol (Hoboken, NJ)* 2017;69:35–45. <https://doi.org/10.1002/art.39859>.
- [6] Sun J-Y, Liu Z, Zhao P, Liu T. Optic neuritis as an initial presentation of primary Sjögren syndrome: A case report and literature review. *Medicine (Baltimore)* 2016;95:e5194. <https://doi.org/10.1097/MD.0000000000005194>.
- [7] Colaci M, Cassone G, Manfredi A, Sebastiani M, Giuggioli D, Ferri C. Neurologic complications associated with Sjögren's disease: Case reports and modern pathogenic dilemma. *Case Rep Neurol Med* 2014;2014:590292. <https://doi.org/10.1155/2014/590292>.
- [8] Tobón GJ, Persj-O, Devauchelle-Pensec V, Youinou P. Neurological disorders in primary Sjögren's syndrome. *Autoimmune Dis* 2012;2012:645967. <https://doi.org/10.1155/2012/645967>.
- [9] Massara A, Bonazza S, Castellino G, Caniatti L, Trotta F, Borrelli M, et al. Central nervous system involvement in Sjögren's syndrome: Unusual, but not unremarkable—clinical, serological characteristics and outcomes in a large cohort of Italian patients. *Rheumatology (Oxford)* 2010;49:1540–1549. <https://doi.org/10.1093/rheumatology/keq111>.
- [10] Bak E, Yang HK, Hwang J-M. Optic neuropathy associated with primary Sjögren's syndrome: A case series. *Optom Vis Sci Off Publ Am Acad Optom* 2017;94:519–526. <https://doi.org/10.1097/OPX.0000000000001054>.
- [11] Min JH, Kim HJ, Kim BJ, Lee KW, Sunwoo IN, Kim SM, et al. Brain abnormalities in Sjogren syndrome with recurrent CNS manifestations: Association with neuromyelitis optica. *Mult Scler* 2009;15:1069–1076. <https://doi.org/10.1177/1352458509106228>.
- [12] Toker E, Yavuz S, Direskeneli H. Anti-Ro/SSA and anti-La/SSB autoantibodies in the tear fluid of patients with Sjögren's syndrome. *Br J Ophthalmol* 2004;88:384–387. <https://doi.org/10.1136/bjo.2003.028340>.
- [13] Hernández-Molina G, Leal-Alegre G, Michel-Peregrina M. The meaning of anti-Ro and anti-La antibodies in primary Sjögren's syndrome. *Autoimmun Rev* 2011;10:123–125. <https://doi.org/10.1016/j.autrev.2010.09.001>.
- [14] Tan P, Yu WY, Umapathi T, Lim S-A. Severe optic neuritis in a patient with combined neuromyelitis optica spectrum disease and primary Sjögren's syndrome: A case report. *J Med Case Rep* 2012;6:401. <https://doi.org/10.1186/1752-1947-6-401>.
- [15] Nitescu D, Nicolau A, Caraiola S, Predeteanu D, Ionescu R, Tanasescu C. Neuromyelitis optica—complication or comorbidity in primary Sjögren's syndrome? *Rom J Intern Med* 2011;49:295–300.
- [16] Wingerchuk DM, Weinshenker BG. The emerging relationship between neuromyelitis optica and systemic rheumatologic autoimmune disease. *Mult Scler* 2012;18:5–10. <https://doi.org/10.1177/1352458511431077>.
- [17] Kahlenberg JM. Neuromyelitis optica spectrum disorder as an initial presentation of primary Sjögren's syndrome. *Semin Arthritis Rheum* 2011;40:343–348. <https://doi.org/10.1016/j.semarthrit.2010.05.005>.
- [18] Adler S, Villiger PM. Inhibitors of T cell Activation in the Treatment of Sjögren's Syndrome. *Curr Treat Options Rheumatol* 2015;1:269–276. <https://doi.org/10.1007/s40674-015-0024-5>.
- [19] Saxena R, Phuljhele S, Menon V, Gadaginamath S, Sinha A, Sharma P. Clinical profile and short-term outcomes of optic neuritis patients in India. *Indian J Ophthalmol* 2014;62:265–267. <https://doi.org/10.4103/0301-4738.121131>.
- [20] Beck RW, Cleary PA, Anderson MMJ, Keltner JL, Shults WT, Kaufman DI, et al. A randomized, controlled trial of corticosteroids in the treatment of acute optic neuritis. The Optic Neuritis Study Group. *N Engl J Med* 1992;326:581–588. <https://doi.org/10.1056/NEJM199202273260901>.