



CASE REPORT

Management of Posterior Capsule Rupture Complication in Cataract Patient with High Myopia and Partial Thickness Macular Hole

Authors:

Bimanda Rizki Nurhidayat^{ORCID}
Dicky Hermawan*^{ORCID}

Affiliations:

Department of Ophthalmology,
Faculty of Medicine, Universitas
Airlangga—RSUD Dr. Soetomo
Surabaya, Indonesia.

Corresponding author:

Dicky Hermawan
dicky.hermawan@fk.unair.
ac.id

Dates:

Received: 04 September 2021

Revised: 10 March 2022

Accepted: 22 March 2022

Published: 6 April 2022

DOI:

<https://doi.org/10.20473/vsehj.v1i2.2022.49-53>

Copyright:

© 2022 Author(s). Open access under Creative Commons Attribution-Share Alike 4.0 International Licence (CC-BY-SA).

**Abstract**

Introduction: To report clinical outcome after posterior capsule rupture complication in a cataract patient with partial-thickness macular hole. **Case presentation:** A 49-year-old woman was presented with blurred vision of the left eye two years before admission. The blurred vision increased, accompanied by eye dazzled on light exposure. There was a history of myopia on both eyes and partial-thickness macular hole in the left eye. The left eye visual acuity was 3/60 with S-7.00 correction became 5/12 no improvement with pinhole. There was a partial-thickness macular hole on the left eye in the optical coherence tomography macula. Cataract surgery was performed with intraoperative posterior capsule rupture (PCR) complication. Follow-up had been monitored from day-1 until day-60 postoperatively. **Conclusions:** The decision of performing cataract surgery prior to macular hole surgery is a good decision. Any intraoperative complication such as posterior capsule rupture should be followed up closely to avoid macular hole worsening. Long-term follow-up should be done to prevent the late complication after surgery.

Keywords: cataract surgery; posterior capsule rupture; macular hole

Introduction

High myopia is generally defined as myopia exceeding -5.00 D or axial length greater than 26 mm. Cataract surgery is considerably more challenging in a highly myopic eye. High myopia is related to a higher risk of retinal detachment and fovea-macular schisis.^[1] The examination before surgery for a patient with high myopia and macular hole includes non-contact optical biometry, performing B-scan ultrasonography, intraocular lens (IOL) formula using the SRK/T formula, and the Haigis formula.^[2] Furthermore, optical coherence tomography (OCT) macula for evaluating macula and vitreomacular interface must be performed. Pre-current maculopathy became an independent risk factor of each postoperative visual improvement. Subsequently, dilated retinal peripheral and fovea examinations are important in high myopia postoperatively.^[1]

Partial-thickness macular hole is a disease formed from adhesion in the vitreomacular interface and can treat according to the stage.^[2] The prevalence of partial-thickness macular hole based on a 2017 study in America was 144 people with old age and female sex as the risk factors. In this clinical study report, ocular comorbidities risk factors are that patients diagnosed with cataracts had an 86% increased risk of developing macular holes compared with patients without cataracts and twice as high in patients diagnosed with pseudophakia or aphakia.^[3] Phacoemulsification seems efficacious in high myopia with great improvement of visual acuity. However, phacoemulsification-associated complications including posterior capsular rupture, retinal detachment, advanced myopic traction maculopathy, took place more frequently in the high myopia population.^[4] Considering that in high myopia cases, it is difficult to maintain the stability of the anterior chamber due to high anterior chamber depth fluctuations during the operation (difficult to regulate the amount of water entering and leaving the

anterior chamber, bottle height, and aspiration flow rate). Posterior capsule rupture (PCR) may necessitate more surgical procedures, more postoperative monitoring, and a higher likelihood of postoperative complications, which could impact ultimate visual outcomes.^[3]

This case report will discuss the management of clinical outcomes after posterior capsule rupture complications in cataract patient with a partial thickness macular hole. Hopefully, this case will contribute to a better understanding of managing posterior capsule rupture complication intraoperative and postoperatively in patients with partial-thickness macular hole.

Case presentation

A 49-year-old woman came to the Eye Clinic in Dr. Soetomo General Hospital Surabaya. Her chief complaint was left eye blurred vision gradually. The patient complained of left eye blurred vision since two years before admission which increased in one year, blurred in far sight accompanied by dazzled eye on light exposure. She also complained about reading difficulty and performing other routine tasks. Pain and watery eye were denied. Black shadow and narrowing visual field were also denied. The patient had no complaints on the right eye and had a history of cataracts extraction at Dr. Soetomo General Hospital Surabaya three months previously. There was no history of hypertension, diabetes mellitus, and trauma. She had history of using spectacles with sphere minus 4.00 D on both eyes. Right eye correction before surgery was 1/60 cc S -7.00 C -1.50 A 105 became 5/15 no improvement with pinhole. Left eye visual acuity was 3/60 with correction of S -7.00 became 5/12 no improvement with pinhole. The intraocular pressure of the right eye was 17.3 mmHg and the left eye was 14.6 mmHg. The patient's vital sign was within normal limit.

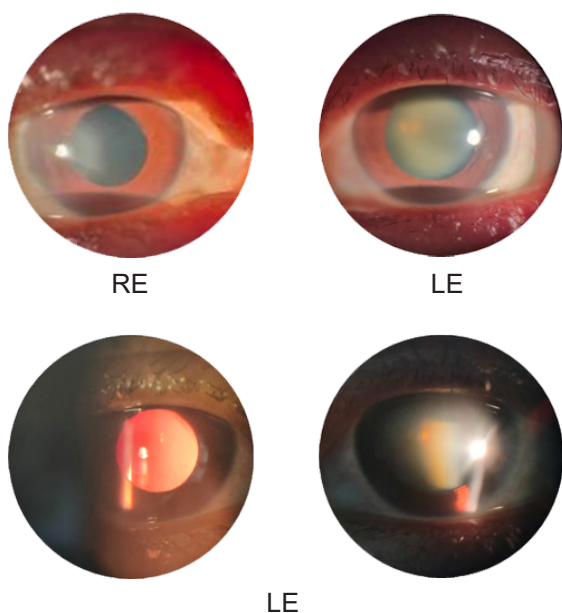


Figure 1. Clinical appearance anterior segment in both eyes.

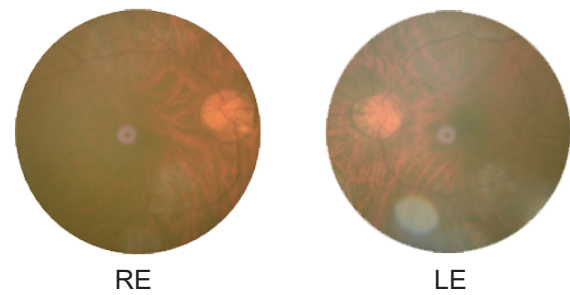


Figure 2. Clinical appearance posterior segment in both eyes.

Anterior segment examination of the right eye showed IOL. Anterior segment examination of the left eye revealed a lens opaque with cataract type of nuclear subcapsular cataract (Figure 1). Indirect funduscopy examination found that right eye was within normal limit and there was myopic crescent, tigroid fundus, and macular hole on the left eye (Figure 2) Biometry examination with non-contact optical biometry using SRK/T formula to determine the IOL power and plan for IOL implantation showed RF +17.00 D. B-scan ultrasonography result was within normal limit with the right eye axial length was 24.32 mm and left eye axial length was 23.85 mm (Table 1). OCT macula examination showed partial-thickness macular hole on the left eye (Figure 3). Ancillary test result was within normal limit. The patient's diagnosis was right eye pseudophakia and left eye immature cataract with partial-thickness macular hole. The patient was planned for left eye phacoemulsification and consulted to retinal division. Retinal division answered that there was no contraindication for cataract extraction surgery in the left eye. The patient will be re-evaluated after cataract surgery had been performed.

The patient was planned for left eye phacoemulsification. On pre-operative management, she was treated with levofloxacin eye drop and diclofenac sodium eye drop for the left eye. Surgery was performed in Dr. Soetomo General Hospital Surabaya operating room. Durante operation posterior capsule rupture was occurred on nucleofraction step (last segment removal) The next step was converted to ECCE technique. Anterior vitrectomy was performed which was continued with IOL implantation RE +15.00 D in the sulcus, main port suturing using nylon 10.0 (five sutures) Iridectomy was performed at 1 o'clock. Postoperative therapies were 0,5% levofloxacin eye drop, 1% prednisolone acetate eye drop, 0,1% diclofenac sodium eye drop, 500 mg paracetamol orally, and 500 mg ciprofloxacin orally. Six hours after surgery, the patient complained of pain in the left eye, headache, nausea, vomiting. Left eye intraocular pressure examination was 31.8 mmHg. The patient was treated with acetazolamide 250 mg, potassium chloride 600 mg, and timolol 0.5% every 12 hours on the left eye. The complaint, intraocular pressure, and anterior segment were monitored.

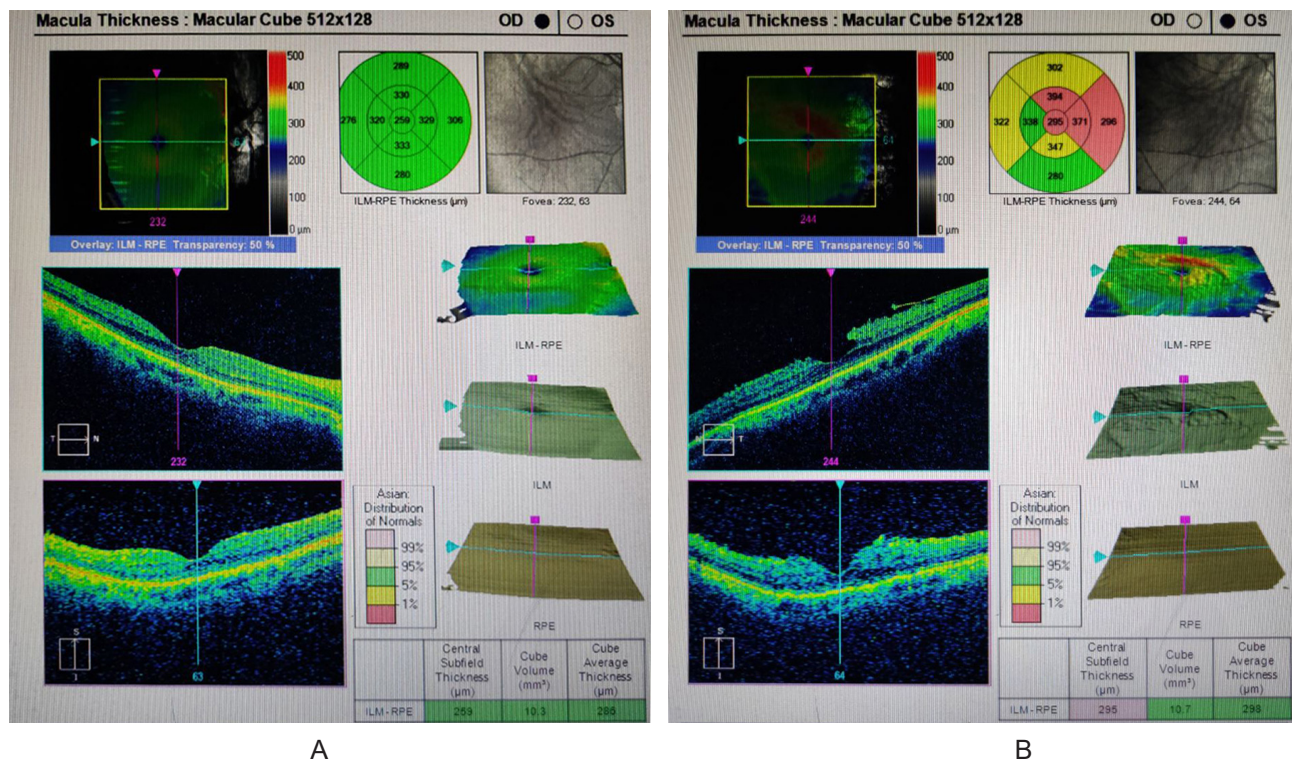


Figure 3. Optical coherence tomography (OCT) Macula; (A) Right eye normal OCT, and (B) Left eye partial thickness macular hole.

One day after surgery follow-up, the patient's complaint was minimal pain. General examination was within normal limits. Ophthalmic findings was left eye visual acuity of hand movement with good projecting illumination and red-green test. Intraocular pressure of the left eye was 14.6 mmHg (on therapy). Anterior segment examination of the left eye showed conjunctival hyperemi, subconjunctival bleeding at 1-2 o'clock, five corneoscleral sutures, positive flare and cell, iridectomy at 1 o'clock, and air bubble in the anterior chamber. Posterior segment examination of the left eye showed positive fundus reflex, details are were difficult to be evaluated. The patient continued the medication at

Table 1. Biometry.

OD			OS		
	K1: 7.97 mm			K1: 7.81 mm	
	K2: 7.64 mm			K2: 7.75 mm	
	AXL: 24.32 mm			AXL: 23.85 mm	
	ACD: 2.80 mm			ACD: 3.61 mm	
				LT: 3.62 mm	
118.0	15.5	0.35	118.0	16.5	-0.46
	16.0	0.01		17.0	-0.81
	16.5	-0.33		17.5	-1.17
118.1	15.0	0.40	118.1	16.5	-0.40
	15.5	0.07		17.0	-0.75
	16.0	-0.29		17.5	-1.10
118.4	15.5	0.24	118.4	16.5	-0.21
	16.0	-0.10		17.0	-0.55
	16.5	-0.44		17.5	-0.90

home and was followed up one week after surgery at an outpatient clinic. The complaint was minimal pain. General examinations were within normal limits

Ophthalmic findings was right eye visual acuity was 3/60, left eye visual acuity was 3/60 became 5/20 on pinhole examination. Auto refractometer examination result was RE S -3.25 C -1.50 A 120, LE S +2.50 C -10.25 A 112. Intraocular pressure of the right eye was 14.6 mmHg and left eye was 17.3 mmHg (on therapy). Anterior segment examination of the left eye showed conjunctival hyperemia, five corneoscleral sutures, positive flare and cell, iridectomy at 1 o'clock and IOL on placed. Indirect funduscopy examination found right eye within normal limit and myopic crescent, tigroid fundus, macular hole on the left eye. The patient was continued with medication, remaining lens mass observation, education of her condition, and followed up at the outpatient clinic.

Two months after surgery, the patient came after suture removal one week previously. Ophthalmic findings was right eye visual acuity was 3/60 with correction of S - 2.50 C - 2.00 A 120 became 5/5, left eye visual acuity was 5/20 with correction of S -1.25 C -0.50 A 90 became 5/6 pinhole not improved. Right eye intraocular pressure was 17.3 mmHg and left eye intraocular pressure was 14.6 mmHg. The anterior segment was within normal limit. OCT macular examination showed partial-thickness macular hole on the left eye which was relative as the same as before. Retinal division evaluation had no plan for surgery and being monitored every three months to evaluate macular hole condition.

Discussion and conclusions

The literature reports the incidence of PCR ranging from 0.2 % to 14%. The amount of vitreous loss was determined between 1% and 5%. Advanced procedures, instruments, and methodologies have reduced PCR rates from 0.45% to 5.2%. PCR occurs in 0.45% to 3.6% of surgeries performed by skilled surgeons, and it occurs in 4.8% to 11% of physicians transitioning from phacoemulsification to extracapsular cataract extraction.^[3] The patient has posterior capsular rupture complications during surgery and converting to extracapsular cataract extraction (ECCE).

Each year, eight out of one hundred thousand people develop partial-thickness macular holes, with a female to male ratio of 2 to 1.^[5] From other study results, females have a 64% increased risk of being diagnosed with a macular hole than males, and Asian-Americans had a 177% increased risk of developing macular holes.^[6] Partial-thickness macular holes are most common in people between the ages of 60 and 80; however, they can also occur in younger myopic eyes. A macular hole is a common side effect of pathological myopia with an axial length greater than 26.5 mm and/or a diopter larger than -6.00 diopters.^[6] The patient was 49-year-old woman with a history of myopic eyes (left eye of -7.00 diopters, normal axial length of 23.85 mm) and unilateral macular hole.

Because of the high prevalence of intraoperative and postoperative problems, phacoemulsification is suggested and successful for cataract patients with high myopia. Careful and adequate pre-operative follow-up is important.^[4] The most common type is an intraoperative posterior capsular tear, which can occur at any stage of cataract surgery. The kind of cataract and the eye state affect the likelihood of posterior capsular problems. Complications rose in proportion to the difficulty of the case and were impacted by the surgeon's level of experience.^[7] High myopic cataract surgery complications, such as posterior capsular rupture (3.91%), retinal detachment (1.74%), progressive myopic traction maculopathy (5.91%), capsular contraction syndrome (2.1%), intraocular lens dislocation (0.58 %), and transient intraocular pressure elevation (28.15%), were more common in highly myopic individuals, according to a

study published in 2021.^[4] In a study published in 2019, long-term follow-up and outcomes on highly myopic patients with myopic traction maculopathy, result is myopic traction maculopathy stays stable in a majority of patients after cataract surgery, long axial length, incomplete posterior vitreous detachment, and entire macular retinoschisis at preliminary assessment may additionally confer excessive risk for the development of myopic traction maculopathy after cataract surgery.^[8] Lens material may enter the posterior segment if the posterior capsule ruptures during surgery. Fluid intake should be reduced, and the anterior segment should be stabilized. The proper response will be determined by assessing the location and size of the rip. Changes in surgical technique can be used to treat small ruptures of the posterior capsule during nuclear emulsification. Using a low-flow, low-vacuum setting, the surgeon can utilize an ophthalmic viscosurgical devices (OVD) to separate the vitreous and remove the residual nuclear and cortical material. The risk of vitreous aspiration or further injury to the capsule is reduced by completely closing the aspiration port and using low ultrasonic power.^[9] To reduce the risk of nuclear separation, conversion to large-incision ECCE is indicated if there are a lot of remaining nuclei. In the case of vitreous prolapse, a bimanual anterior vitrectomy is performed. Through the side port incision, insert a 23-gauge lavage cannula. The irrigation bottle is put at the proper height during the vitrectomy to keep the anterior chamber open. After vitrectomy, the risk of vitreoretinal traction or vitreous adhesion to the IOL, iris, or incision is reduced. After cataract surgery, a higher risk of retinal detachment, CME, and endophthalmitis is linked to the vitreous loss. Vitrectomy should be performed at 500 to 800 cuts per minute, with a 20 cc/min aspiration flow rate and a 150 to 200 mmHg vacuum. Vitrectomy of the anterior chamber and pupillary planes was continued. Check for vitreous strands with a rod through the anterior chamber; the strands should be removed if any are present. If a circular moveable pupil is detected and an intact air bubble in the anterior chamber, the vitreous is successfully removed from the anterior chamber. Preservative-free purified triamcinolone acetate suspension is effective when used to identify vitreous strands. Kenalog particles (triamcinolone acetonide) are visible because they are stuck on and inside the vitreous gel. Suturing the corneal incision is advised in situations of vitreous loss with posterior capsular rupture to prevent infection. Remove any remaining vitreous with glassware or Vannas scissors at the main and lateral incision sites.^[7]

Patient with high myopia is the finest risk factor for postoperative retinal detachment, intraoperative preservation of an intact posterior capsule, IOL implantation, and anterior vitrectomy in cases of

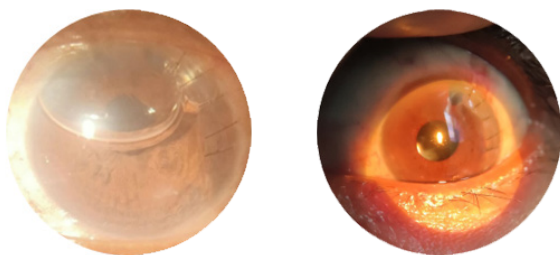


Figure 4. Clinical appearance; (A) Post operation surgery on left eye; (B) One week post operation surgery on left eye.

posterior capsular rupture are acknowledged to protect against rhegmatogenous retinal detachment.^[2] IOL insertion makes vitreous mobility more stable and limited, unlike left aphakia. With a more stable vitreous, the pull on the retina as well as the macula of the retina is less, so that it can reduce the risk of retinal detachment and fovea-macular schisis. Intraocular lens implantation in posterior capsular tear are several options, such as (a) IOL insertion and rotation should always be kept away from the capsular tear area; (b) the IOL long axis should pass through the posterior capsular tear meridian; (c) IOLs with posterior capsular tear (6 mm) without vitreous loss can be placed in the capsular bag; (d) if there is sufficient posterior capsular tear (> 6 mm) at the anterior capsular edge, the IOL can be placed in the sulcus. Three IOLs with a total diameter greater than 12.5 mm, with or without optical capture, can be placed into the ciliary sulcus. Because of the risk of developing uveitis-glaucoma-hyphema (UGH) syndrome, monolithic acrylic IOLs are not recommended for the ciliary sulcus; (e) cemented IOLs are a promising alternative to sutured scleral fixation or anterior chamber IOLs in cases of capsular insufficiency. By suturing the haptic to the iris or anchoring the haptic to the sclera through the ciliary sulcus, a posterior chamber intraocular lens (PCIOL) can be utilized without capsular support.^{[7],[9]} During surgery, the patient was converted to the ECCE technique, anterior vitrectomy was performed, and IOL implantation in the sulcus was continued.

The vitreous in the anterior chamber can cause chronic intraocular inflammation, corneal oedema, glaucoma, and cystoid macular oedema if the posterior capsule ruptures.^[9] Alternatively, it can be separated into striatal keratopathy, corneal oedema, glaucoma, uveitis, and fibrin response are all early postoperative anterior segment problems. Pseudophakic bullous keratopathy, glaucoma, and down-epithelial growth to AC are late postoperative anterior segment problems.^[3] Peak intraocular pressure should be actively managed and constantly monitored after surgery, especially in the first 48 hours. Scleral indentation retinal tests were performed on all patients 1-2 weeks following surgery to visualize the retinal periphery. Patients with cystoid macular oedema (CME) should be closely examined at home using the Amsler grid for reduced contrast and distortion. During follow-up, optical coherence tomography is essential. To prevent CME, extended durations of topical steroids and continuous topical NSAIDs are indicated in comparison to routine instances (off-label). IOP control is recommended in eyes with residual OVD or lens fragments. If the lens material is still intact, immediate referral to a retinal specialist is necessary for definitive treatment. In addition to the increased risk of glaucoma and CME, these patients should be informed about the increased risk of retinal tear or detachment in the future.^[3] The patient had

early complication of PCR after surgery such as corneal oedema, glaucoma, uveitis, and was followed up with OCT. The result was a partial-thickness macular hole on the left eye, relatively the same between before and after surgery. Two months after surgery subjective refraction result was better than before surgery.

Based on this case, we must be considering the cautious in cataract surgery cases on high myopia with abnormalities of the macula. Further attention can be paid to a complete pre-operative examination, a safe and effective surgery to avoid complications during surgery, especially measures to reduce the traction of the vitreous to the retina and macula in case of vitreous prolapse on posterior capsule rupture. Intraoperative complication posterior capsule rupture can be closely followed up to avoid worsening the condition of macular hole and long-term follow-up postoperative should be done to prevent the late complication after surgery and obtain a successful clinical outcome.

References

- [1] Chong EW, Mehta JS. High myopia and cataract surgery. *Curr Opin Ophthalmol* 2016;27:45–50. <https://doi.org/10.1097/ICU.0000000000000217>.
- [2] Cetinkaya S, Acir NO, Cetinkaya YF, Dadaci Z, Yener HI, Saglam F. Phacoemulsification in eyes with cataract and high myopia. *Arq Bras Oftalmol* 2015;78:286–289. <https://doi.org/10.5935/0004-2749.20150076>.
- [3] Chakrabarti A, Nazm N. Posterior capsular rent: Prevention and management. *Indian J Ophthalmol* 2017;65:1359–1369. https://doi.org/10.4103/ijo.IJO_1057_17.
- [4] Yao Y, Lu Q, Wei L, Cheng K, Lu Y, Zhu X. Efficacy and complications of cataract surgery in high myopia. *J Cataract Refract Surg* 2021;47:1473–1480. <https://doi.org/10.1097/j.jcrs.0000000000000664>.
- [5] McCannel CA. 2019–2020 Basic and Clinical Science Course, Section 12: Retina and Vitreous. San Fransisco: American Academy of Ophthalmology; 2020.
- [6] Ali FS, Stein JD, Blachley TS, Ackley S, Stewart JM. Incidence of and risk factors for developing idiopathic macular hole among a diverse group of patients throughout the United States. *JAMA Ophthalmol* 2017;135:299–305. <https://doi.org/10.1001/jamaophthalmol.2016.5870>.
- [7] Agarwal A. Posterior Capsular Rupture: A Practical Guide to Prevention and Management. 1st ed. New Jersey: SLACK Incorporated; 2013.
- [8] Cai L, Sun Z, Guo D, Fan Q, Zhu X, Yang J, et al. Long-term outcomes of patients with myopic traction maculopathy after phacoemulsification for incident cataract. *Eye (Lond)* 2019;33:1423–1432. <https://doi.org/10.1038/s41433-019-0416-0>.
- [9] American Academy of Ophthalmology. 2020–2021 BCSC (Basic and Clinical Science Course), Section 11: Lens and Cataract. San Fransisco: American Academy of Ophthalmology; 2020.