



## CASE REPORT

**Blast Eye Injury After Mobile Phone Battery Explosion: How to Manage it?****Authors:**

Ratih Justitia Kartika\*<sup>ORCID</sup>  
Ismi Zuhria<sup>ORCID</sup>

**Affiliations:**

Department of Ophthalmology,  
Faculty of Medicine, Universitas  
Airlangga—RSUD Dr. Soetomo  
Surabaya, Indonesia.

**Corresponding author:**

Ratih Justitia Kartika  
ratih.justitia.kartika-2017@  
fk.unair.ac.id

**Dates:**

Received: 19 July 2021  
Revised: 26 January 2022  
Accepted: 28 January 2022  
Published: 18 March 2022

**DOI:**

[https://doi.org/10.20473/  
vsehj.v1i2.2022.28-34](https://doi.org/10.20473/vsehj.v1i2.2022.28-34)

**Copyright:**

© 2022 Author(s). Open  
access under Creative  
Commons Attribution-Share  
Alike 4.0 International  
Licence (CC-BY-SA).

**Abstract**

**Introduction:** Injuries from mobile phone blasts have been on the rise in recent years. Lithium-ion batteries are the most common type found in cellphones and devices. In 2016 around 100 of the 2.5 million phone cell units have been recorded to have exploded. Mobile battery burst is a significantly underappreciated cause of serious ocular morbidity and could be a combination of mechanical, thermal, and chemical effects. Knowing proper management is very important to achieve the best result. **Case presentation:** We describe an ocular blast injury due to mobile phone battery explosion when plugged in to charge that experienced spasm and burned cilia, limbal ischemia, broad corneal haziness on both eyes, and visual acuity decreased. The fluorescein test was positive. We did proper irrigation and debris extraction around the ocular surface and periorbital tissue. It was treated with quinolone antibiotics eyedrop, atropine sulfate eyedrop, prednisolone eyedrop, and NSAID orally. In four days, the patient's eye showed good clinical improvement with decreased corneal haziness with minimal epithelial defect. The visual acuity was improved on both eyes. **Conclusions:** Lithium-ion batteries are used in almost all smartphones and electronics. Lithium explosions can result in chemical and thermal burns on the ocular surface. Ocular alkali chemical injury combined with thermal and mechanical is an emergency case. The vision can be saved if the ocular surface burns are treated promptly and properly. These cases are required to raise public awareness about the potential risks of smartphone use, adopt safe practices as recommendations from the manufacturers, and avoid counterfeit products and such accidents.

**Keywords:** ocular blast injury; mobile phone battery; lithium; limbal ischemia

**Introduction**

Humankind is encountering gadgets that convert chemical energy to electrical energy, such as mobile phones, in tandem with technological progress. The indiscriminate use of mobile phones exposes us to the risks linked with them, such as accidental burns and explosion injuries. Mobile phone blasts have become more common in recent years, resulting in disastrous effects, which can be ascribed mostly to the use of low-quality items, user irresponsibility, and the use of phones while charging.<sup>[1]</sup> There are two types of batteries: nonchargeable and charged. Lithium-ion batteries are the most common type found in cellphones and devices. Lithium is chosen because it is light and has a high energy density. Lithium-ion batteries are extremely efficient, however they suffer from heat concerns. Mobile battery burst is a significantly underappreciated cause of serious ocular morbidity. These batteries may overheat while charging, resulting in “thermal runaway,” or an uncontrolled rise in internal battery temperature. The batteries are also loaded with a flammable electrolyte, which can catch fire when heated.<sup>[2]</sup> The mechanism of injury caused by a battery blow could be a combination of mechanical (battery fragments), thermal, and chemical injuries.<sup>[2]</sup> Ocular explosion injuries are true ophthalmic emergencies, and both pose the risk of blindness. Alkalis and acids in solid, liquid, powder, mist, or vapor form are examples of chemical agents that cause eye damage. The severity of the harm is determined by the type of offending agent, its concentration, the length of exposure, and the area of contact.<sup>[3]</sup> During these twenty years, the number of mobile phone-related injuries in the United

States has gradually climbed, with 29.19 new instances per million person-years in 2016, and around 100 of the 2.5 million phone cell units have been recorded to have exploded.<sup>[4],[5]</sup> Alkaline agents are especially dangerous because they have both hydrophilic and lipophilic characteristics, allowing them to quickly penetrate cell membranes and enter the anterior chamber. Because many corneal proteins bind acid, acids produce less harm than alkalis.<sup>[6]</sup>

Computer technology is advancing at a rapid pace in this age of connectivity. In our daily life, communication tools are abundantly available. According to the United Nations specialized agency for information and communication technology, there are about seven billion mobile phones in the world.<sup>[7]</sup> However, communication technology may also present some risks. Mobile phones are an outstanding example of a device that might endanger a person's health.<sup>[6]</sup> The harm caused by radiation emitted by mobile phones is well documented. The lithium battery explosion in the phone might result in severe burns. An exothermic reaction explosion can cause thermal and chemical injuries.<sup>[8]</sup> Lithium is a delicate silvery-white alkali metal that is extremely reactive and volatile. Lithium is corrosive; its alkaline components irritate the nose, mouth, and eye at first, and prolonged exposure can cause a chemical burn to the ocular surface.<sup>[9]</sup> The indiscriminate use of cell phones exposes us to the risks linked with them, such as accidental burns and explosion injuries. When using a cellphone, the face and eyes are more vulnerable to injury.<sup>[10]</sup>

A chemical injury is characterized by a sudden onset of acute pain, epiphora, and blepharospasm. Periorbital edema and erythema, de-epithelialized skin, and loss of eyelashes and eyebrows are examples of acute periocular indications of damage. Corneal and conjunctival epithelial defects, chemosis, conjunctival inflammation, limbal ischemia, corneal cloudiness, sterile ulceration, edema, and occasionally perforation are early symptoms. The stage of a chemical eye burn is especially useful in predicting the outcome.<sup>[11]</sup> Several classification systems have been proposed to aid in the prediction of the fate of acute ocular burns. The classification methods Roper-Hall and Dua are widely used.<sup>[12]</sup>

The primary goal of treating acute thermal or chemical ocular burns is to accelerate epithelial healing, reduce inflammation, and avoid further tissue melting in order to minimize scarring sequelae and severe visual loss.<sup>[13]</sup> The best first-aid measure for corrosive chemical eye burns is to rinse the eyes with a neutral pH aqueous flushing solution as soon as possible after a corrosive chemical ocular splash.<sup>[14]</sup> To obtain the good results, conventional medical therapy such as steroids, ascorbate, citrates, tetracyclines, lubricants, and surgical techniques such as placing a glued-on hard contact lens,

tenoplasty, and amniotic membrane transplantation were used.<sup>[3]</sup> The level of damage to corneal, limbal, and conjunctival tissues at the time of injury determines the recovery of ocular surface burns.<sup>[6]</sup> Glaucoma, dry eye disease, limbal stem cell shortage, and scarring of the eyelids, conjunctiva, and cornea are all complications of chemical damage. Although most severe injuries are treated conservatively with eye drops at first, very severe injuries, notably corneal ulceration or perforation, may necessitate surgical intervention using limbal stem cell autograft or corneal transplantation to restore vision and relieve symptoms.<sup>[15]</sup> This study was documenting a case of ocular alkali chemical injury caused by a cellphone battery explosion with the hopes of better understanding the findings, visual morbidity, and therapy

### Case presentation

A 22-years-old male was referred to the emergency department. He complained about pain on the right and left eyes two hours before admission due to a mobile phone battery explosion when plugged in to charge. By the time of his first visit, the general examination is blood pressure 110/70 mmHg, heart rate 80 x/minute, respiratory rate 18 x/minute, temperature 36,1oC. We found that the patient presented with the blurry vision on right-left eyes, redness, difficulty opening his eyes, and tearing.

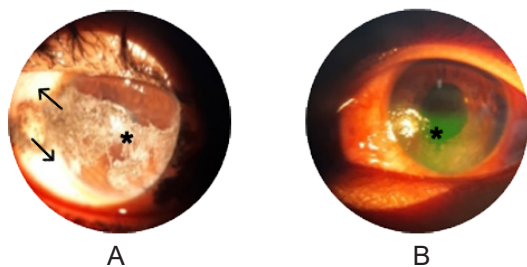
On ophthalmology examination, visual acuity was one-meter finger counting on the right eye and 6/8.5 on the left eye with normal palpation IOP on both eyes. Anterior segment examination showed spasm and burned cilia on the right-left eyes without any burned lesion around periorbital tissue. Slit-lamp biomicroscopic examination showed conjunctival hyperemia on both eyes. Arrow's sign showed limbal ischemia about less than 1/3 area in the right eye. Asterix sign showed corneal haziness with visible iris details on both eyes, positive fluorescein test about 12 mm and positive epithelial defect on the right eye, positive fluorescein test about 6 mm on the left eye inferiorly (Figure 1-2). The posterior segment of the right eye was difficult to be evaluated due to corneal haziness. The posterior segment of the left eye was a positive fundus reflex, sharp margin, normal color optic nerve, no retinal hemorrhage, exudate or crystals, and positive macular reflex.

Regarding the examination and depend on the severity of ocular surface burn caused by chemical agent of battery composition, the patient was diagnosed with ocular blast injury due to mobile phone explosion with right eye grade II chemical ocular injury and left eye grade I chemical ocular injury in accordance to Hughes classification. The patient was treated with Tetracaine hydrochloride 0.5% eye drop on both eyes to decrease his pain, debris extraction around the ocular surface and periorbital tissue, irrigation of 2 liters sterile water

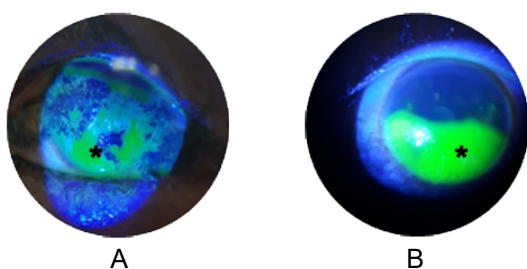
**Table 1.** The biometry of the twin.

	Before Treatment		Day 3 <sup>rd</sup>		Day 4 <sup>th</sup>	
	Right Eye	Left Eye	Right Eye	Left Eye	Right Eye	Left Eye
Visual Acuity	1/60	6/8.5	6/15	6/8.5	6/15	6/6
IOP	Normal Palpation	Normal Palpation	Normal Palpation	Normal Palpation	Normal Palpation	Normal Palpation
Palpebra	Spasm (+), Burned silia (+)	Spasm (+), Burned silia (+)	Spasm (+), Burned silia (+)	Spasm (+), Burned silia (+)	Spasm (-), Burned silia (+)	Spasm (-), Burned silia (+)
Conjunctiva	Hyperemia (+), Limbal ischemia (+) 1/3 area	Hyperemia (+), Limbal ischemia (-)	Hyperemia (+) slightly, Limbal ischemia < 1/3 area	Hyperemia (+) slightly, Limbal ischemia (-)	Hyperemia (+)slightly, Limbal ischemia < 1/3 area	Hyperemia (+)slightly, Limbal ischemia (-)
Cornea	Hazy (+), fluorescein test (+) 12 mm	Hazy (+), fluorescein test (+) 6 mm	Hazy (+), fluorescein test (+) 11x5 mm	Hazy (+), fluorescein test (+) 2 mm	Hazy (+), fluores- cein test (+) 2x3 mm	Clear, fluorescein test (-)

on both eyes, fornices swab with a cotton tip to remove chemical agent residual Irrigation was enough because the pH of the ocular surface all was neutral. For further management, the patient was treated with one drop Quinolone antibiotic eyedrop every four hours in both eyes, one drop Natrium carboxymethylcellulose eyedrop mini dose every one hour in both eyes, one drop of Atropine sulfate eyedrop every 24 hours in both eyes, one drop Prednisolone acetate eyedrop every 6 hours in both eyes, NSAID every eight hours orally, and Doxycyclin 100 mg every 12 hours orally.



**Figure 1.** Slit-lamp examination with direct illumination.

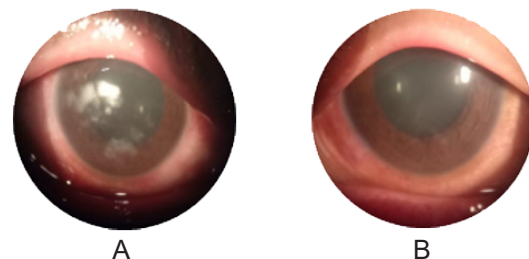


**Figure 2.** Fluorescein test; (A) Right eye; (B) Left eye.

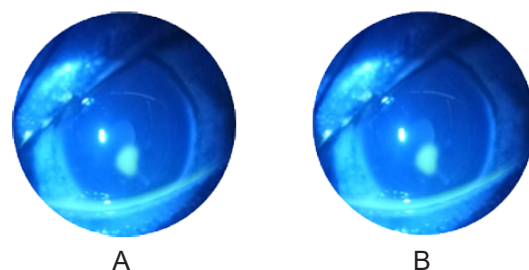
Three days post-treatment, the patient showed significant clinical improvement (Table 1). Ophthalmology examination showed that visual acuity was 6/15 on the right eye and 6/8.5 on the left eye. Intraocular pressure was normal palpation on both eyes. Anterior segment examination still showed spasm and burned cilia on both eyes, conjunctival hyperemia on both eyes, limbal ischemia about less than 1/3 area in the right eye, and no limbal ischemia on the left eye, corneal haziness with visible iris details on both eyes, positive fluorescein test

about 11 x 5 mm and positive epithelial defect on the right eye, positive fluorescein test about 2 mm inferiorly and positive defect epithelial on the left eye (Figure 3-4).

The patient's condition at four days post-treatment showed good clinical improvement. We found that his pain decreased significantly in both eyes, with visual acuity improved to 6/15 on the right eye and 6/6 on the left eye. Anterior segment examination showed decreased spasm on both eyes, minimal conjunctival hyperemia on both eyes, limbal ischemia about less than 1/3 area in the right eye, no limbal ischemia on the left eye, decreased corneal haziness with visible iris details on both eyes, positive fluorescein test about 2 x 3 mm with a positive epithelial defect on the right eye, and negative fluorescein test on the left eye (Figure 5-6).



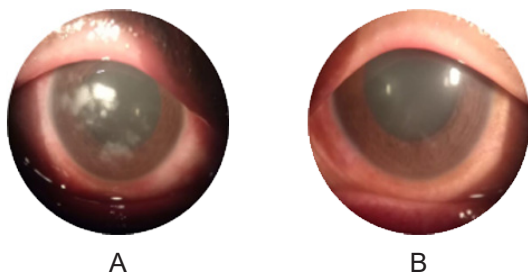
**Figure 3.** Slit lamp examination three days post treatment; (A) Right eye; (B) Left eye.




**Figure 4.** Three days after the admission. Anterior segment of the right eye on day one postoperative. Good condition of the conjunctival suture.

### Discussion and conclusions

Chemical burns to the eye or ocular adnexa represent a severe injury with potentially long-term consequences relevant to the vision and overall quality of life. Ocular



**Figure 5.** Slit lamp examination four days post treatment; (A) Right eye; (B) Left eye.



**Figure 6.** Fluorescein test four days post treatment; (A) Right eye; (B) Left eye.

chemical injury is an ophthalmic emergency and accounts for 11.5%–22.1% of ophthalmic trauma.<sup>[15]</sup> These injuries are associated with early and extended concerns of ocular pain, decreased visual acuity, ectropion, and extended risk for infection. Vision loss increases the risk of serious injuries, depression, delirium, chronic disease, and social health. These conditions can also generally affect the quality of life and reduce economic productivity.<sup>[14]</sup> The goal of treatment is to minimize further damage to the ocular surface and ultimately restore normal ocular surface anatomy and visual function.<sup>[16]</sup> More than 25,000 chemical products that can cause chemical eye injuries have been identified, many of which may be classified as acids or bases, oxidizing or reducing agents, or corrosives. Injuries caused by alkaline agents occur more frequently and are usually more severe than those caused by acidic agents. The injury severity is related to the nature, concentration, quantity, and pH of the active chemical and surface area exposure duration. In particular, a history of a high-velocity (explosive) chemical or thermal injury should always raise suspicion of an associated intraocular foreign body.<sup>[12]</sup> Alkalis characteristically penetrate the eye more rapidly than acids. Alkaline agents can perforate the cornea in less than 15 seconds. Serious ocular chemical injuries are characterized by corneal opacification, ischemia to the margin of the cornea, and extensive conjunctival involvement.<sup>[17]</sup> Alkali damage results from the interaction of the hydroxyl ions, causing cell membranes saponification and cell death, and disruption of the extracellular matrix.<sup>[6]</sup>

Communication between individuals is now easier than ever because of tremendous improvements

in telecommunication during the last decade.<sup>[7]</sup> Communication technologies are extensively available in our daily lives, yet they may also pose significant risks. Mobile phones are an outstanding example of a gadget that might endanger a person's health.<sup>[6]</sup> The lithium battery explosion in the phone might result in severe burns.<sup>[6]</sup> Lithium-ion batteries have proven to be a technological and economic success, enabling a wide range of uses ranging from cellular phones to electric cars and large-scale electrical energy storage plants.<sup>[6]</sup> The dangers connected with gas and smoke emissions from failing lithium-ion batteries may pose a more serious concern in rare cases. Lithium is a delicate silvery-white alkali metal that is highly reactive and volatile. Lithium's corrosive chemicals, frequently alkaline, irritate the nose, throat, and eye at first; however, prolonged exposure can cause a chemical burn to the ocular surface.<sup>[9]</sup> An irreversible thermal event in a lithium-ion battery can be caused by a variety of factors, including spontaneous internal or external short circuits, overcharging, external heating or fire, and mechanical damage. A lithium-ion battery's electrolyte is flammable and often comprises lithium hexafluorophosphate (LiPF<sub>6</sub>) or other Li-salts containing fluorine.<sup>[11]</sup> Some data on ocular injury by mobile phone blast showed grade I ocular surface burn with multiple soot particles over cornea and conjunctiva with charred eye.<sup>[2]</sup>

Conjunctivalization of the cornea protects against progressive melting and perforation.<sup>[12]</sup> Limbal stem cells, the source of corneal epithelial regeneration, are the most critical potential targets in acute chemical burns.<sup>[3]</sup> Associated lid burns can cause lid shortening, rigidity, and contractures resulting in exposure keratitis and mechanical injury to the cornea, and are usually associated with poor prognosis. Intraocular pressure is another critical factor. High intraocular pressure should be aggressively managed; however, persistent hypotony is generally an indicator of poor prognosis—classification schemes for grading the severity of the initial injury help guide treatment and estimate prognosis.<sup>[5]</sup> The Roper–Hall categorization system, launched in the mid-1960s, is the most well-established and widely used. It gives prognostic guidance depending on the quantity of perilimbal ischemia and the degree of corneal haze. It has been essential to know better the role of the limbus in wound healing.<sup>[12]</sup>

Lagophthalmos can occur due to mechanical changes in the lids, edema, or scarring. Long-term repercussions of extensive conjunctival burns include symblepharon, cicatricial entropion, ectropion, and trichiasis. The percentage of surviving limbal tissue is an important prognostic indicator. Chemical properties, especially the pH of the hazardous chemical, have been identified

as crucial in influencing the quantity and kind of tissue damage. Blinking does not remove solid particles, and caustic powders like lime or concrete may linger in increased concentrations in the conjunctival sac, increasing the likelihood of tissue destruction. When the epithelium is damaged, alkaline solutions penetrate deeper into the tissues, destroying proteoglycan ground substance and the collagen matrix. If the substance reaches the collagen fibrils of the trabecular meshwork, it might produce scarring, which inhibits aqueous outflow and causes secondary glaucoma. Strong alkaline chemicals reach the anterior chamber and produce extensive iris, lens, and ciliary body inflammation.<sup>[18]</sup> Minor redness and watering to severe photophobia are among the symptoms. After such an injury, the most important structural changes are limbal ischemia, limbal stem cell deficit, corneal conjunctivalization, symblepharon development, and lid border abnormalities with advanced consequences of corneal and scleral melt. After chemical or thermal injuries, chronic inflammation of the limbal stroma results in limbal stem cell deficiency.<sup>[11]</sup>

Ascorbic acid, citrate, tetracycline, corticosteroids, and medroxyprogesterone are some of the medicinal treatments that have been used to treat ocular burns. The surgical therapy of acute ocular burns comprises necrotic tissue debridement, tissue adhesive application, tenoplasty, and tectonic keratoplasty.<sup>[19]</sup> It is critical to address an emergency first aid situation quickly and with enough water. It should be utilized if normal saline is available; otherwise, clean water should be used. Irrigation using isotonic solutions such as normal saline, lactated ringer solution, or clean water should begin as soon as the patient is exposed to the chemical and continue until the patient arrives at the hospital. Irrigation is maintained in the hospital until the pH of the ocular surface approaches.<sup>[7]</sup> The pH level is determined by exposing the affected ocular tissue to pH indicators that cause chemical injuries to the cornea, such as universal paper, and should be rechecked at regular intervals after irrigation to ensure stability. As a result, there is a need to raise public understanding of irrigation. Early medical care aims to minimize inflammation, encourage corneal re-epithelialization, and prevent acute consequences, including infection or corneal melt.

Preserved drugs should not be used in treatment.<sup>[20]</sup> Tap water with a low salt content causes immediate dilution yet causes significant tissue edema. Water and the electrolytes it contains are taken from the tissue at high salt concentrations.<sup>[15]</sup> Corticosteroids have the beneficial effects of suppressing inflammatory cells and inhibiting collagenase. When taken with topical ascorbate, the prolonged use of topical steroids is not related to corneoscleral melting. Ascorbate levels in the aqueous humor may decrease after a chemical injury

due to the ciliary body epithelium damage. It has been demonstrated that topical or systemic replenishment of decreasing aqueous ascorbate levels lowers the development of corneal thinning and ulceration. Supplementation can be obtained by the hourly use of 10% sodium citrate eye drops and/or the four-times-daily administration of 1.000 mg of oral ascorbic acid. In the case of serious injuries, topical treatment is preferable to systemic administration. Citrate chelates extracellular calcium and inhibits polymorphonuclear leukocyte activity by lowering membrane and intracellular calcium levels. Citrate also inhibits collagenase activity. Citrate and ascorbate have been shown to alleviate corneal ulcers through different methods. A cycloplegic drug, such as cyclopentolate 1% or atropine 1%, will relieve discomfort and lower the chance of posterior synechiae. Other adrenergic medications, such as phenylephrine hydrochloride, should be avoided since vasoconstrictor activity may worsen limbal ischemia.

Chemical burns can cause tear film anomalies due to damaged conjunctival goblet cells, and severe injuries can directly harm the lacrimal system. Frequent use of preservative-free tear replacements may aid in promoting healing and re-epithelialization by washing away debris and inflammatory cells and moisturizing the ocular surface. The trabecular meshwork and the production of inflammatory mediators might limit aqueous outflow, resulting in increased intraocular pressure. The therapy of choice is the suppression of aqueous humor production. If there is no contraindication, short-term oral acetazolamide treatment may be preferred to decrease epithelium toxicity from preservatives in topical medicines. Tetracyclines have been shown to reduce collagenase activity and corneal ulcers in experimental alkali injuries. This action is independent of their antibacterial effects and is assumed to occur via zinc chelation, an element required for matrix metalloproteinase activity.<sup>[12]</sup>

Intermediate surgical intervention promotes re-epithelialization, inflammation management, and the protection and maintenance of the ocular surface. Amniotic Membrane Transplantation (AMT) is an early or intermediate surgical treatment that promotes epithelialization and suppresses inflammation to avoid or reduce scarring-induced sequelae in the late phase. AMT in the early stages may aid in suppressing inflammatory infiltration and may lessen the length and amount of inflammation.<sup>[11]</sup> Tenoplasty is an option for promoting corneal epithelialization and preventing ulceration after severe damage. A vascularized pedicle of Tenon's capsule is rotated over the cornea in this procedure. Limbal autografts are the preferred therapy since there is little chance of rejection. The state of the neighboring limbus must always be evaluated when choosing corneal

transplantation treatments in chemical burns. When the lesion has preserved the descemet's membrane and the corneal endothelium, deep anterior lamellar keratoplasty may be explored. Artificial corneas are the last option for individuals with severely damaged eyes who are not candidates for penetrating keratoplasty. Keratoprosthesis has the potential for vision rehabilitation, and preliminary research indicates that retention rates are excellent. Infection, corneal melt, glaucoma, and a retroprosthetic membrane are risks associated with keratoprosthesis installation. When all other therapeutic options have been explored for a painful blind eye, evisceration or enucleation may be necessary.<sup>[16]</sup>

Facial burns are a common component of thermal trauma, with ocular involvement affecting between 7.5 % and 27% of patients admitted to burning units. Initial treatment includes carefully removing debris with irrigation and sterile cotton swabs. Because patients may have decreased tear production, blink reflex, and eyelid movement or excursion, early prophylactic ocular lubrication is advised. Drops are thought to be less effective than ointments.<sup>[12]</sup> Antimicrobial prophylaxis with a topical antibiotic is warranted in the case of epithelial problems. Several topical antibiotics, such as chloramphenicol, tetracycline, and ofloxacin, have been used or advocated in the literature in the form of drops or ointments. At the moment of injury, the risk of microbial contamination must be addressed when selecting an antibiotic. In an unclean injury or microbial keratitis, boosted antibiotics such as tobramycin and cefazolin may be required. These antibiotics, however, must be administered with caution since they have a poor therapeutic to harmful ratio.<sup>[13]</sup>

Lithium-ion batteries are used in almost all smartphones and electronics. An irreversible thermal event in a lithium-ion battery can be initiated in several ways, resulting in a fire and/or explosion. Mobile battery blast is a highly underestimated etiology for severe ocular morbidity and could be a combination of mechanical, thermal, and chemical injuries. The types of chemical agents include alkalis and acids. Ocular alkali chemical injury combined with thermal and mechanical is an emergency case. The initial treatment extracts the debris around the ocular surface and periorbital tissue. A combination of quinolone topical, artificial tears eye drop, antimuscarinic agent topical as a cycloplegic, corticosteroid topical, oral NSAID, and oral doxycycline can improve clinical significance in this patient. Timely presentation and proper management can salvage the vision. These cases are needed to increase public awareness about the potential risks of cellphone use, adopt safe practices as recommendations from the manufacturers, and avoid counterfeit products and such accidents.

## References

- [1] Sharda P, Panwar P. 'BOMBILE' – Newest enemy to our sight? A case series. *Trop Doct* 2022;52:120–124. <https://doi.org/10.1177/00494755211036839>.
- [2] Behera S, Mahapatra A, Sharma PK, Dora J, Biswal SS. Mobile blast injury in eye. *Glob J Res Anal* 2022;9:1–2.
- [3] Sharifipour F, Idani E, Zamani M, Bonyadi MHJ. Oxygen therapy for acute ocular chemical or thermal burns: A pilot study. *Am J Ophthalmol* 2011;151:823–828. <https://doi.org/10.1016/j.ajo.2010.11.005>.
- [4] Povolotskiy R, Gupta N, Leverant AB, Kandinov A, Paskhover B. Head and neck injuries associated with cell phone use. *JAMA Otolaryngol Neck Surg* 2020;146:122–127. <https://doi.org/10.1001/jamaoto.2019.3678>.
- [5] Lin MP, Eksioglu Ü, Mudumbai RC, Slabaugh MA, Chen PP. Glaucoma in patients with ocular chemical burns. *Am J Ophthalmol* 2012;154:481–486. <https://doi.org/10.1016/j.ajo.2012.03.026>.
- [6] Mcghee CNJ, Crawford AZ, Patel D V. Chemical and Thermal Injuries to the Ocular Surface. In: Holland EJ, Mannis MJ, Lee WB, editors. *Ocul. Surf. Dis. Cornea, Conjunctiva Tear Film*, Amsterdam: Elsevier Inc.; 2013, p. 219–230. <https://doi.org/10.1016/B978-1-4557-2876-3.00029-8>.
- [7] Karabagli Y, Köse AA, Cetin C. Partial thickness burns caused by a spontaneously exploding mobile phone. *Burns* 2006;32:922–924. <https://doi.org/10.1016/j.burns.2006.03.009>.
- [8] Cherubino M, Pellegatta I, Sallam D, Pulerà E, Valdatta L. Enzymatic debridement after mobile phone explosion: A case report. *Ann Burns Fire Disasters* 2016;29:273–275.
- [9] Larsson F, Andersson P, Blomqvist P, Mellander B. Toxic fluoride gas emissions from lithium-ion battery fires. *Sci Rep* 2017;7:1–13. <https://doi.org/10.1038/s41598-017-09784-z>.
- [10] Narang P, Mittal V, Mittal R, Mathur A. Ocular surface burn secondary to smart phone battery blast. *Indian J Ophthalmol* 2017;65:326. [https://doi.org/10.4103/ijo.IJO\\_495\\_16](https://doi.org/10.4103/ijo.IJO_495_16).
- [11] Tejwani S, Kolari RS, Sangwan VS, Rao GN. Role of amniotic membrane graft for ocular chemical and thermal injuries. *Cornea* 2007;26:21–26.
- [12] Dua HS, King AJ, Joseph A. A new classification of ocular surface burns. *Br J Ophthalmol* 2001;85:1379–1383. <https://doi.org/10.1136/bjo.85.11.1379>.
- [13] Soleimani M, Naderan M. Management strategies of ocular chemical burns: Current perspectives. *Dovepress* 2020;14:2687–2699. <https://doi.org/10.2147/OPHTH.S235873>.
- [14] Haring RS, Isaac SD, Roomasa C, Canner JK, Schneider EB. Epidemiologic trends of chemical ocular burns in the United States. *JAMA Ophthalmol* 2016;134:1119–1124. <https://doi.org/10.1001/jamaophthalmol.2016.2645>.
- [15] Wiesner N, Dutescu RM, Uthoff D, Kottek A, Reim M, Schrage N. First aid therapy for corrosive chemical eye burns: Results of a 30-year longitudinal study with two different decontamination concepts. *Graefes Arch Clin Exp Ophthalmol* 2019;257:1795–1803. <https://doi.org/10.1007/s00417-019-04350-x>.

- [16] Tandon R, Gupta N, Kalaivani M, Sharma N, Titiyal JS, Vajpayee RB. Amniotic membrane transplantation as an adjunct to medical therapy in acute ocular burns. *Br J Ophthalmol* 2011;95:199–204. <https://doi.org/10.1136/bjo.2009.173716>.
- [17] Kwok JM, Chew HF. Chemical injuries of the eye. *Can Med Assoc J* 2019;191:E1028. <https://doi.org/10.1503/cmaj.190428>.
- [18] Eslani M, Baradaran-rafi A, Movahedan A, Djalilian AR. The Ocular Surface Chemical Burns. *Hindawi J Ophthalmol* 2014;2014:1–6. <https://doi.org/10.1155/2014/196827>.
- [19] Sharma N, Kaur M, Agarwal T, Sangwan VS, Vajpayee RB. Treatment of acute ocular chemical burns. *Surv Ophthalmol* 2018;63:214–235. <https://doi.org/10.1016/j.survophthal.2017.09.005>.
- [20] Hoffman JJ, Casswell EJ, Shortt AJ. Assault-related severe ocular chemical injury at a London ophthalmic referral hospital: A 3-year retrospective observational study. *BMJ Open* 2020;10:e038109. <https://doi.org/10.1136/bmjopen-2020-038109>.