



Potential Ethyl Acetate Fraction of Mangkokan Leaf Extract (Nothopanax Scutellarium) in Hyperglycemic Rats: A Systematic Review

Sri Lestari Ramadhani Nasution^{1*}); Chrismis Novalinda Ginting¹; I Nyoman Ehrich Lister¹

¹ Department of Medicine, Faculty of Medicine, University of Prima Indonesia, Medan, Indonesia

ARTICLE INFO

Article history:

Received 11 November 2021
Accepted 21 February 2022
Published 10 March 2022

Keyword:

Diabetes mellitus
Ethyl acetate extract
Alloxan

ABSTRACT

Mangkokan leaves (*Nothopanax scutellarium*) contain various phytochemicals such as flavonoids and saponins, where these compounds have antioxidant activity that can improve oxidative stress in the body. Treatment of Diabetes Mellitus disease can be done with drugs and herbs, optimal blood glucose control alone cannot prevent complications. The available therapies for DM include insulin therapy and other hypoglycemic agents that can not be separated from various side effects and failure to significantly prevent complications, including the Mangkokan leaf herbal treatment (*Nothopanax scutellarin*) which has an antidiabetic effect. To systematically review the effect of the ethyl acetate fraction of the extract of the Mangkokan (*Nothopanax scutellarium*) leaf extract on blood sugar levels, malondialdehyde, insulin expression in pancreatic cells and pancreatic histopathology in hyperglycemic rats. A systematic search was carried out in the PubMed database, Medline, Web of Science, Scopus, EMBASE from 2017 to 2021. The reported results stated that Alloxan is a compound that has diabetogenic properties and is toxic especially to pancreatic beta cells and when administered to animals will cause the rat to be diabetic. Alloxan causes damage to pancreatic beta cells by activating reactive oxygen (ROS) which is initiated by the reduction reaction of alloxan.

This open access article is under the [CC-BY-SA](https://creativecommons.org/licenses/by-sa/4.0/) license.



Kata kunci:

Diabetes mellitus
Ekstrak etil asetat
Aloksan

*) corresponding author

Sri Lestari Ramadhani Nasution

Doctoral Student of Postgraduate Medicine,
Faculty of Medicine
University of Prima Indonesia
Jl. Sekip Simp Sikambang, Sei Putih Tim,
Medan Petisah, Medan, Sumatera Utara,
20111

Email: srilestariinst@gmail.com

DOI: 10.30604/jika.v7i1.855

ABSTRAK

Daun mangkokan (*Nothopanax scutellarium*) mengandung berbagai fitokimia seperti flavonoid dan saponin, dimana senyawa tersebut memiliki aktivitas antioksidan yang dapat meningkatkan stres oksidatif dalam tubuh. Pengobatan penyakit Diabetes Mellitus dapat dilakukan dengan obat-obatan dan herbal, pengendalian glukosa darah yang optimal saja tidak dapat mencegah terjadinya komplikasi. Terapi yang tersedia untuk DM antara lain terapi insulin dan agen hipoglikemik lainnya yang tidak lepas dari berbagai efek samping dan kegagalan untuk mencegah komplikasi secara nyata, termasuk pengobatan herbal daun mangkokan (*Nothopanax scutellarin*) yang memiliki efek antidiabetik. Mengkaji secara sistematis pengaruh fraksi etil asetat ekstrak ekstrak daun mangkokan (*Nothopanax scutellarium*) terhadap kadar gula darah, malondialdehid, ekspresi insulin pada sel pankreas dan histopatologi pankreas pada tikus hiperglikemik. Penelusuran sistematis dilakukan di database PubMed, Medline, Web of Science, Scopus, EMBASE dari tahun 2017 hingga 2021. Hasil yang dilaporkan menyatakan bahwa Alloxan merupakan senyawa yang memiliki sifat diabetogenik dan bersifat toksik terutama terhadap sel beta pankreas dan bila diberikan pada hewan akan menyebabkan tikus menjadi diabetes. Aloksan menyebabkan kerusakan sel beta pankreas dengan mengaktifkan oksigen reaktif (ROS) yang diawali dengan reaksi reduksi aloksan.

This open access article is under the [CC-BY-SA](https://creativecommons.org/licenses/by-sa/4.0/) license.



INTRODUCTION

The incidence of DM continues to increase constantly. About 10% of the world's population suffers from diabetes. 366 million people in the world in 2030 are predicted to suffer from DM and are dominated by type 2 diabetes mellitus. DM is not only a problem in developed countries but also developing countries such as Indonesia. However, optimal blood glucose control alone cannot prevent complications. This shows that alternative treatment strategies are still needed. The available therapies for DM include insulin therapy and other hypoglycemic agents which are associated with side effects and failure to significantly prevent complications. Therefore, alternative treatments are needed that are cheap and have minimal side effects. One of the herbal plants that acts as an antioxidant, among others, is the leaves of the Mangkokan (*Nothopanax scutellarin*).

In Diabetes Mellitus there are signs of hyperglycemia or glucosuria, accompanied by classic symptoms of polyuria, polyphagia, polydipsia, pruritus, and weight loss. Diabetes mellitus is a disease that is closely related to the metabolism of glucose in the blood. High glucose levels in the body cannot be absorbed completely and do not undergo metabolism in the cells. As a result, a person's energy will be reduced, so easily tired and experience weight loss. The normal level of glucose in the fasting blood is 70-90 mg/100 mL of blood. When the glucose level is below 70 mg/100 mL of blood, it is called hypoglycemia. while glucose levels above 90 mg/100 ml is called hyperglycemia. Diabetes mellitus occurs when there is not enough insulin to be produced or the available insulin does not work properly. So diabetes is characterized by hyperglycemia. Insulin is a polypeptide secreted by cells of the islets of Langerhans, synthesized as proinsulin. Insulin is the main regulating hormone. carbohydrate metabolism and their interactions with protein and lipid metabolism. Insulin acts on cell membranes to increase the rate at which glucose and other sugars are absorbed into cells (especially muscle tissue), and glucose is metabolized in cells. Insulin is produced by pancreatic cells at low levels and much higher levels when stimulated in response to various stimuli, especially glucose.

The human pancreas contains 8 mg of insulin. Diabetes mellitus can be prevented before being infected by maintaining a good, healthy, and balanced diet. Diabetes therapy can be done by taking medication, both traditional and modern, and it is also important to have a healthy and balanced diet. Currently, several plants in Indonesia have been used as drugs for diabetes mellitus and have been scientifically investigated, including sambiloto (*Andrographis paniculata* Ness), johar (*Cassia siamea* Lamk), dandang gendis (*Clinacanthus nutans* Lindau), garlic (*Allium sativum* L.) and cecendet (*Physalis minima* L.).

The occurrence of chronic complications in DM is caused by the emergence of oxidative stress where free radicals exceed the immune system, causing macrovascular and microvascular disorders. Oxidative stress also results in an imbalance between antioxidants and pro-oxidants that has the potential to cause damage. Chronic hyperglycemia will cause apoptosis of vascular endothelial cells through excessive mitochondrial superoxide production. Excessive glucose metabolism will produce free radicals. Under normal conditions in the body, there is a balance between the production of free radicals that act as oxidants and antioxidants. Free radicals are magnetic and very reactive because they are considered to destroy body cells with all the consequences. Free radicals are more dangerous than non-radical oxidants. This is due to the nature of free radicals which have high reactivity and the tendency to form new

radicals when they meet other compounds. The negative impact on the cell membrane will result in a chain reaction called lipid peroxidation. The end result of this chain reaction is the breaking of fatty acid chains into various compounds that are toxic to cells, including Malondialdehyde (MDA). (Ebaid et al., 2019)

The effects of oxidative stress and an increase in free radicals in diabetes mellitus will have an impact on the destruction of several compounds and will further damage metabolism, causing a complication reaction in the form of tissue damage, both microvascular and macrovascular which will cause endothelial dysfunction. . Based on this, how important is the balance of compounds in the human body. Balanced oxidants, balanced antioxidants, balanced blood sugar levels to avoid hyperglycemia. (Ighodaro, Adeosun and Akinloye, 2017).

Ethyl acetate which is a semi-polar solvent can attract compounds with a wide polarity range from polar to non-polar which are made through the Fischer esterification reaction of acetic acid and ethanol. The mechanism of action of alloxan that causes damage to pancreatic beta cells is to enter the pancreatic beta cells first and then be absorbed by pancreatic beta cells. Alloxan causes pancreatic beta cell damage by activating reactive oxygen (ROS) which is initiated by the alloxan reduction reaction. The result of alloxan reduction is dialuric acid which is then reoxidized to alloxan as before and will form a redox reaction cycle that will produce superoxide radicals. pancreas, resulting in depolarization of pancreatic beta cells.

Necrosis that occurs in pancreatic beta cells is thought to occur due to the depolarization process of pancreatic beta cell membranes due to alloxan induction. Changes that occur in the pancreas due to the induction of alloxan are the shrinking of the islets of Langerhans and the nuclei of pyknotic cells which indicate the occurrence of necrosis. Necrosis causes lytic changes involving the cytoplasm of cells which are characterized by the formation of vacuoles, but the most obvious changes occur in the cell nucleus, namely cell death which usually looks smaller, the boundaries are not clear and dark in color or commonly called pyknosis. (Eva Decroli, 2019). Changes that occur in the pancreas due to the induction of alloxan are the shrinking of the islets of Langerhans and the nuclei of pyknotic cells which indicate the occurrence of necrosis. Necrosis causes lytic changes involving the cytoplasm of cells which are characterized by the formation of vacuoles, but the most obvious changes occur in the cell nucleus, namely cell death which usually looks smaller, the boundaries are not clear and dark in color or commonly called pyknosis. (Eva Decroli, 2019).

Changes that occur in the pancreas due to the induction of alloxan are the shrinking of the islets of Langerhans and the nuclei of pyknotic cells which indicate the occurrence of necrosis. Necrosis causes lytic changes involving the cytoplasm of cells which are characterized by the formation of vacuoles, but the most obvious changes occur in the cell nucleus, namely cell death which usually looks smaller, the boundaries are not clear and dark in color or commonly called pyknosis. (Eva Decroli, 2019). But the most obvious changes occur in the cell nucleus, namely cell death which usually looks smaller, the boundaries are not clear and dark in color or commonly called pyknosis. (Eva Decroli, 2019). But the most obvious changes occur in the cell nucleus, namely cell death which usually looks smaller, the boundaries are not clear and dark in color or commonly called pyknosis. (Eva Decroli, 2019).

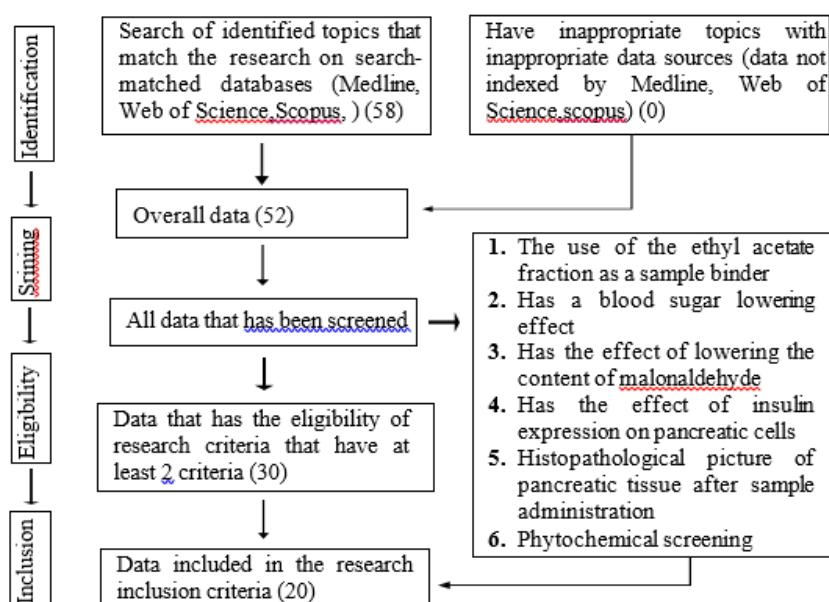
Bangkok leaves (*Nothopanax scutellarin*) contain various phytochemicals such as flavonoids and saponins, where these

compounds have antioxidant activity that can increase oxidative stress in the body. Several previous studies have been conducted to explore other pharmacological effects of this plant such as hair growth, wound healing, and antibacterial effects. Treatment and prevention of DM focuses on inhibiting oxidative stress, such as the use of antioxidants to anticipate the effects of free radicals.

Hydrogen Peroxide (H₂O₂) is one of the toxic free radicals. Catalase as an endogenous antioxidant plays a major role in controlling the concentration of H₂O₂ by catalyzing H₂O₂ into oxygen and water so that it is nontoxic. However, there have been no previous studies that have explored its pharmacological effects, one of which is the antihyperglycemic effect. Therefore, this study aimed to explore and analyze the effect of the ethyl acetate fraction of Mangkokan (*Nothopanax scutellarium*), on diabetes mellitus using white rats (*Rattus norvegicus*) as experimental animals. The results of this study are expected to increase the use value of Mangkokan Leaves (*Nothopanax scutellarium*), and develop ready-to-use products made from Indonesian natural ingredients (Via Rifkia, Mahdi Jufri, 2017).

METHOD

Database and Search Strategy In June 2019, a systematic review was conducted according to the Preferred Reporting Items Guidelines for Systematic Reviews and Meta-Analysis (PRISMA) 2009 [18]. The aim was to systematically identify clinical trials and experimental studies in animals that have evaluated the effect of the leaves of the bowl (*Nothopanax Scutellarium*) on diabetes to date. To this end, we performed a time-filtered bibliographic search from January 2017 to June 2021 in the following four electronic databases: Medline, Web of Science, Scopus. The PubMed search engine was also consulted. The search terms were based on the following descriptors in the Medical Subject Headings (MeSH): ethyl acetate, extracts of Mangkokan leaves (*Nothopanax Scutellarium*), Blood Sugar Levels, dosage, phytochemicals, Malondialdehyde, insulin expression in pancreatic cells, histopathology of pancreatic tissue. The search strategy used in all databases was Mangkokan Leaf (*Nothopanax Scutellarium*), dosage, phytochemical content and Ethyl Acetate Fraction and Hyperglycemia or Malondialdehyde or insulin expression in pancreatic cells or pancreatic tissue histopathology.



Picture 1. Prism flow chart in research. In this study, researchers obtained 58 journals as a comparison that had a relationship with benefits in diabetes, where several journals were found that had benefits in lowering blood sugar levels, lowering malondialdehyde levels, insulin levels, and histopathology in pancreas as many as 20 as comparison journals that have at least 2 inclusion criteria from the researcher. The results obtained are not based on the same extract but based on the effect of the same extract with the extracts in this study.

RESULTS AND DISCUSSION

Ethyl Acetate Solvent

This compound is an ester of ethanol and acetic acid. This compound is a colorless liquid with a characteristic odor. Ethyl acetate is a semi-polar solvent that attracts polar and non-polar compounds, has low toxicity, and is easy to use. Ethyl acetate which is a semi-polar solvent is able to attract compounds with a wide range of polarity from polar to non-polar. Ethyl acetate is prepared by the Fischer esterification reaction of acetic acid and ethanol. Esters are derived from carboxylic acids containing the -COOH group. (Putri, Warditiani and Larasanty, 2013).

Phytochemical screening needs to be done to determine the class of compounds contained in the extract used. In this study, phytochemical screening was carried out to see the class of compounds in the ethyl acetate extract of the Mangkokan leaf so that the ability of the ethyl acetate solvent to attract the compounds contained in the Mangkokan leaf was also known. Warditiani and Larasanty, 2013). Ethyl acetate has a boiling point of 77 °C making it easier to separate the oil from the solvent in the distillation process. Based on previous research, ethyl acetate solvent gave a higher yield than alcohol and acetone solvents. This is most likely related to the non-polar nature of essential oils, so essential oils tend to dissolve in non-polar solvents as well (Rhodia, 2012).

Table 1

A table that describes the comparison of each journal related to the presence of diabetes that is managed by looking at the results ranging from blood sugar levels, myaldehyde, pancreatic histopathology, insulin expression and phytochemical content of the samples used in each study

No	Name of Researcher and Year of Research	Researched Subject	Research design	Sample Used	Research Intervention	Research result
1	(Nasution et al., 2020)	Blood sugar levels, malondialdehyde (MDA), insulin expression in pancreatic cells and pancreatic histopathology	Experimental study with post-test only group design	Mushroom leaves	Mangkokan leaves were made in ethyl acetate fraction and made extracts which were given to rats that had been induced by alloxan with 3 different doses, namely 125, 250 and 500 mg/kgBW by oral route.	Samples that intervened in rats showed that there was an effective decrease in blood sugar levels and a decrease in MDA levels but still did not reach the effectiveness of the standard group, namely metformin and ethyl acetate fraction extracts, which have various kinds of phytochemicals, namely alkaloids, triterpenoids and steroids, saponins, flavonoids, and tannins
2	(Sari et al., 2018)	Blood sugar levels, Malondialdehyde (MDA), pancreatic histopathology	Experimental study with post-test group design	Henna (henna nails)	Nail girlfriend was made with ethanol extract given to rats that had been induced with alloxan at a dose of 200, 400 and 600 mg/kgBW given orally for 28 days.	The extract given its effect worked on days 14 and 21 in lowering blood sugar levels, and it would rise again on day 28, with the most significant effectiveness. The three extracts did not show any significant changes in MDA levels and on phytochemical screening found coumarins, flavonoids, naphthalene and gallic acid derivatives.
3	(Pashapoor, Mashhadryrafi and Mortazavi, 2020)	Blood sugar levels, malondialdehyde, pancreatic histology	Experimental	Nutmeg	This study was divided into 5 treatment groups in rats consisting of a normal group, a group that was induced by alloxan, 3 groups given nutmeg seed extract (at doses of 50, 100, and 200 mg/kgBW) and a positive control given oral route of metformin.	The results obtained were nutmeg seed extract had significant results in reducing blood sugar levels at doses of 100 and 200 mg/kgBB (P value <0.01), with a decrease in mDA levels in the pancreas and an improvement in cells, namely with an improvement from the enlarged size, as well as the increased number of cells so that they have increased insulin sensitivity
4	(Susanti, Setiadi and Peniati, 2019)	Blood sugar levels, pancreatic histopathology, insulin	Experimental randomized design with a randomized post-test design.	Aloe vera skin	The intervention was carried out on five groups of rats, namely the untreated group, the alloxan induced group at a dose of 120 mg/kgBW consisting of no extract and 3 groups with aloe vera peel extract consisting of 87.5 mg/kgBW, 170 mg /kgBW, 350 mg/kgBW observed for 28 days	Aloe vera has an effect in reducing the risk of necrosis in cells which is almost similar to that in a group of normal rats which is the most effective at a dose of 350 mg/kgBW compared to the other 2 doses. Aloe vera contains various kinds of phytochemicals, namely flavonoids, alkaloids, tannins, saponins, triterpenoids, steroids and phenol components that function as antioxidants.
5	(Pane et al., 2018)	Malondialdehyde (MDA), superoxide dismutase (SOD), blood sugar levels	Randomized clinical study consisting of two groups (Randomized control trial)	Gambir	The use of the method by distributing 2 groups consisting of a placebo group and a group given gambier extract to type 2 diabetes patients who were given together with metformin (each placebo group was given 500 mg metformin and the intervention group was given 500 mg metformin with 375 mg gambier extract). which is given	There was no significant difference between the 2 groups except that the mDA levels in patients receiving gambier extract (p 0.001) were lower than those in the placebo group (p 0.44). On day 14, SOD in patients given gambier extract (p 0.57) was higher than in the placebo group (p 0.07)

					2 hours after eating and then monitors the patient for 14 days and takes a blood sample from the patient's vein which is taken to see blood sugar levels, mda and sod	
6	(Ali et al., 2020)	Potential antidiabetic, malondialdehyde (MDA), antioxidant	Experimental	Mandarin orange peel	The intervention consisted of 5 groups of streptozotocin-induced rats consisting of a normal group, a negative control group, a group with hydroethanol extract of mandarin orange peel, a group with hesperidin and a group with quercetin which was given for 4 weeks.	The results obtained are mandarin orange peel extract with substances contained in it, namely hesperidin and quercetin have a significant effect in lowering blood sugar levels by increasing insulin sensitivity and there appears to be an improvement in pancreatic cells with the return of the size of cells, as well as an increase in the size of the cells. of insulin secretion and reduces the percentage of necrosis in pancreatic cells
7	(Aligita et al., 2018)	Blood sugar levels, pancreatic histopathology, insulin secretion and sensitivity	Experimental	cherry leaf	Consists of 6 intervention groups, consisting of a negative control group, a positive control group, a group given glibenclamide 0.65 mg/kgBW and 3 groups given cherry leaf extract at a dose of 100, 200 and 400 mg/kgBW given for 14 days. on day 3,7,10 and 14	Cherry extract has the effect of lowering blood sugar levels, with the most effective dose at a dose of 400 mg/kgBW, regenerating pancreatic cells and increasing insulin sensitivity. The phytochemicals contained are flavonoids, tannins, triterpenoids, steroids and polyphenols components
8	(Hayaza et al., 2019)	Anti-diabetic activity, pancreatic histopathology	Experimental	Ketapang leaves	This study intervened in 6 groups of mice consisting of a normal group, a DM group without treatment, a DM group with metformin 6.5 mg/kgBW, and 3 treatment groups given Ketapang leaf extract at doses of 50, 100, and 200 mg/kg. kgBB observed for 14 days	Ketapang leaves have a fairly high antioxidant content in the form of -carotene, phenol, flavonoids, and tannins. The extract in this study concluded that the higher the dose given, the less blood sugar levels in the intervention group were given due to improvement in pancreatic cells, namely from the enlarged diameter of the islets of Langerhans so that insulin secretion or sensitivity would increase.
9	(Damayanthi, Forester and Handharyani, 2018)	Blood sugar levels, malondialdehyde levels in rat liver	Experimental with Pre and post test-controlled group design	Okra	Consisting of 6 intervention groups in rats consisting of a normal group, a DM group without streptozotocin-induced intervention, and 4 groups receiving an okra extract intervention consisting of 2 green okra extracts and 2 purple okra extracts at a dose of 5 mg and 10 mg/day. kgBB of quercetin observed for 14 days	The results obtained were that each okra contained flavonoids (quercetin) and phenolics, which were found in purple okra which had a higher content than green okra, indicating that purple okra was more effective in lowering blood sugar levels and mDA levels in streptozotocin- induced rats in mice. dose of 5 mg/kgBW although the difference between the two types of okra did not show significant distance results
10	(Naibaho, Safithri and Wijaya, 2019)	Anti hyperglycemia, malondialdehyde, weight change in rats	Experimental	Cat's whiske, turmeric, ginger, lime, lemon and kaffir lime	Interventions on mice were divided into 4 groups consisting of negative control, positive control and 2 groups given a combination extract in 2 forms, namely micro-encapsulated drink powder and nano-encapsulated drink powder that had been induced by streptozotocin by checking the results every 2 weeks (kgd). and	The results obtained were that the intervention group had controlled blood sugar levels and controlled body weight due to the pdouxu inhibitor activity of MDA, although for researchers it was not certain that it was found that nano-encapsulated drink powder was better than micro-encapsulated drink powder which was not too significant.

					rat body weight) for 6 weeks	
11	(Kusmiati et al., 2019)	Glucose level, malondialdehyde level	Experimental	marigold flower	The intervention in mice consisted of 7 groups, namely a group without treatment, a negative control group, a group given glibenclamide 5 mg/kgBW, a group given vitamin E 10mg/kgBW and 3 groups given marigold flower lutein extract at doses of 40, 80, and 160 mg/kgBW induced alloxan	Marigold flower lutein extract has the potential to reduce blood sugar levels which is seen to be most effective at a dose of 160 mg/kgBW and has antioxidants that can reduce MDA levels, because the phytochemical screening obtained contains phytochemicals in the form of alkaloids, flavonoids, saponins, tannins, triterpenoids and steroids
12	(Serang and Hammi, 2020)	Blood sugar level, malondialdehyde (MDA) level in blood plasma, antioxidant effect	Experimental	Genjer leaves	This study intervened in 5 groups of rats, consisting of a negative control group, a positive control group (glibenclamide 0.45 mg) with 3 groups of genjer leaf ethanol extract consisting of 3 doses, namely 32.5 mg/kgBW, 65 mg/kg. kgBW and 130 mg/kgBW in alloxan-induced rats were monitored every week for 21 days	Ethanol extract from genjer leaves contains flavonoids, alkaloids and tannins as an antioxidant effect and effectiveness in reducing mda levels in blood plasma in alloxan-induced rats at a dose of 130 mg/kgBW which is the most effective.
13	(Putri, Lestari and Gofur, 2020)	Malondialdehyde levels, Reactive oxygen species (ROS)	Experimental	Black soybean tempeh and Purple sweet potato	The intervention was carried out on 6 groups of rats, 5 of which were induced by streptozotocin consisting of a group given glibenclamide and 3 groups given a combination extract with a ratio of 3:1, 1:1 and 1:3 between black soybean tempeh and purple sweet potato.	Has an antioxidant effect because it contains flavonoids and has effectiveness in lowering MDA levels, especially in combination extracts with a ratio of 1:1.
14	(Dos Santos et al., 2017)	Anti hyperglycemia, malondialdehyde levels, antioxidants	Experimental	Yacon leaves	This study was conducted on rats aged 60 days that had been induced by streptozotocin consisting of 4 groups, 3 of which were given the intervention of hydroethanolic extract of yacon leaves consisting of 25, 50 and 100 mg/kgBW which were observed for blood sugar levels, mda for 8 weeks.	The results of the study obtained were that there was a decrease in mda levels and an increase in sod but not too significant in the DM intervention given Yacon. There is an effect of reducing glucose levels which is quite effective at a dose of 100 mg/kgBW which indicates an increased sensitivity in pancreatic cells. For the phytochemical content in the hydroethanolic extract of yacon in the form of flavonoids and phenolic acids which have potential as antioxidants
15	(Laily Kurniawati et al., 2018)	Malondialdehyde levels, glucose levels liver histopathology	Experimental	Purple golden flower root/pletakan	The intervention group consisted of 3 groups of rats induced by streptozotocin multiple times with a low dose of 20 mg/kgBW consisting of a normal group, a diabetic group without treatment and a group with an intervention of pletekan root extract at a dose of 250mg/kgBW for 21 days under observation.	The results obtained showed that extracts from pletekan root had an effect in lowering glucose levels which was quite significant which was a sign of the improvement of pancreatic cells which increased insulin secretion and sensitivity to the bloodstream and decreased MDA levels after the intervention. The highest phytochemicals contained in pletekan roots are triterpenoids, flavonoids, phenol components, glycosides and saponins which play an important role as antioxidants.

16	(Khalaf et al., 2021)	Anti-diabetic, pancreatic histopathology, malondialdehyde	Experimental	Alfalfa	The intervention on albino rats were divided into 5 groups, namely the group without diabetes, 4 groups that were induced by alloxan at a dose of 60 mg/kgBW consisting of a negative control group, 2 groups given alfalfa extract at a dose of 60 and 120 mg/kgBW and positive control with administration of glibenclamide at a dose of 10 mg/kgBW via the oral route was observed for 21 days, and on the last day rats were sacrificed under anesthesia to take pancreatic specimens for histopathology.	The results obtained were increased activity of SOD, G6PD, GPx, insulin catalase in the pancreas increased when MDA levels decreased which was found in a group of rats given alfalfa water extract so that it has the potential to control blood sugar levels and has a high flavonoid content as an antioxidant.
17	(Nova et al., 2020)	Anti-hyperglycemic, anti-inflammatory, antioxidant	Experimental	Moringa leaves	The subjects used were rats aged 10 weeks which consisted of 4 groups, namely the normal group, the normal group with the administration of Moringa leaf extract, the diabetes group and the diabetes group with the administration of streptozotocin-induced Moringa leaf extract for 6 weeks.	The results obtained are Moringa leaf extract has an effect in lowering blood sugar significantly compared to the group of rats without the extract and reduces free radical activity, namely decreasing MDA levels, increasing levels of catalase activity (CAT), increasing levels of superoxidase (SOD) and increasing levels of glutathione (GSH) found in rats given Moringa leaf extract, both non-diabetic and diabetic
18	(Al Syaad et al., 2019)	Blood sugar levels, malondialdehyde (MDA), antioxidants	Experimental	Soursop and ginger	This study consisted of 6 groups of albino rats consisting of a control group, a diabetes group and 4 groups that were given extract, namely 2 groups of soursop extract and 2 groups of ginger extract which had been induced by streptozotocin and observed for 30 days.	Extracts from soursop and ginger have effectiveness in lowering glucose levels, have antioxidant activity, namely by reducing MDA levels, increasing GPx, SOD, CAT and GSH activities found in liver specimens and having antiapoptotic activity that prevents tissue damage, namely in the liver of rats that have been cured. induced by streptozotocin
19	(Guevara-Vásquez, Campos-Florián and Dávila-Castillo, 2021)	Blood glucose level from glucose tolerance test, insulin secretion, phytochemical	Experimental Pre and post test-controlled group design	Soursop leaf	The intervention consisted of 6 groups of rats, namely the normal/DM group, the alloxan-induced group via intragastric oral to perform OGTT/IP which consisted of 2 groups, namely the normal/positive control DM group (metformin mg/kgBW), and the normal/DM group with soursop leaf extract at a dose of 200 mg/kgBW, this study lasted for 14 days, of which 7 days for adaptation and day 10 starting in the group that will experience DM to be induced by alloxan	In the phytochemical screening of the extract, it was found that it contained flavonoids, alkaloids, steroids, tannins and <i>Leucoanthocyanidins</i> . During the OGTT, in normal rats, soursop leaf extract had an effect in improving glucose levels after a glucose tolerance test with a ratio between soursop leaf extract and metformin, which was 24.42%: 31.08%. Meanwhile, rats with DM had an effect in lowering glucose levels with a ratio between soursop leaf extract and metformin with a percentage of 37.61%: 44.02%, where group assessment was obtained during the intervention 120 minutes, which was measured at the beginning of each intervention, 30 minutes, 60 minutes, 90 minutes and 120 minutes. This study also showed that soursop leaf extract had an

						inhibition of glucose absorption in the intestine.
20	(Shafiee et al., 2018)	Levels of glucose, antioxidants, flavonoids and phenols	Experimental	medlar leaves	The intervention was divided into 6 groups of mice given IP streptozotocin induction consisting of a normal group given 1 unit of insulin syringe every day, a DM group as a negative control, a positive group given metformin 200 mg/kgBW, and 3 groups given medlar leaf extract. with doses of 50, 100 and 200 mg/kgBW for 21 days which were observed every day	The results of this study are medlar leaves have the potential to reduce blood glucose which is effective at a dose of 50 mg/kgBW, and have an antioxidant effect in reducing MDA levels but increasing GSH levels because from the phytochemical results, medlar leaf extract contains phytochemical components of flavonoids and phenols and improves metabolism of mice with a return to normal body weight in mice
21	(Li et al., 2018)	Glucose levels antioxidants	Experimental randomized design with randomized post-test design	Klabat	The intervention was carried out in six groups of mice induced by streptozotocin, namely the positive control group who were given metformin 500mg/kgBW, the DM group without intervention, 2 DM groups with high and low doses of flavonoid and 2 intervention groups given clabat extract at a dose of 20 and 80 mg. /kgBW which lasts for 5 weeks, i.e. 1 week of adaptation and 4 weeks of intervention, then several mice will be sacrificed to take specimens of their kidneys, liver and pancreas for histopathology	The results obtained are clabat contains flavonoid phytochemicals and stilbene glycosides which have antioxidant effects, namely reducing MDA levels, increasing SOD and CAT. The results obtained that fenugreek extract has a significant effect in lowering blood sugar with a percentage ratio of 17.1%, 20.8%, 14.4%, 15.9%, 11.2%, and 11.3%. the specimens taken showed cell improvement from specimens that received clabat extract with flavonoids.

Immunohistochemical Engineering

The different cell types in the pancreatic islets of Langerhans can be identified by immunostaining techniques, in situ hybridization for hormone production (using additional nucleotide probes to direct mRNA), and appearance of secretory granules by electron microscopy. Immunohistochemistry is a technique for identifying cellular or tissue constituents (Antigens) through antigen-antibody interactions, wherein antibody binding sites are identified by direct labeling of antibodies, or by using secondary labeling methods (Kabiraj et al., 2015). The detection of insulin by immunocytochemistry is one of the most powerful and sensitive techniques available for monitoring expression levels in islets of Langerhans, cells, tissue samples, and cells that express the insulin gene transgenically (Wasterfall, 2017). The following is a picture of insulin expression in beta cells of the pancreatic islets of Langerhans using the IHC (anti-insulin antibody) staining technique.

This research was colored by immunohistochemical method using rabbit monoclonal anti-mouse insulin antibody and as a secondary antibody used universal type antibody (Trekki Universal Link). The expression of insulin protein in pancreatic tissue was observed using a light microscope equipped with optilab software to document images, record videos, count and measure objects.

Pancreatic Histopathology

Results of Experimental Rat Pancreas Histopathology Test After 4 weeks of treatment, the mice were dissected and then their pancreas was taken for preparation and staining using the hematoxylin-eosin (HE) method. Histological description of the pancreas from the results of examination and microscopic reading with original magnification of 400x mouse pancreas preparation is presented in Pancreatic tissue in the normal treatment group (P0) showed acinar glands arranged around the islets of Langerhans, the epithelium was cuboidal. The existence of an orderly arrangement of endocrine cells scattered in the islets of Langerhans with uniform cell shape, the nucleus of the endocrine cells looks bluish purple with a round shape and visible nucleoli and pink cytoplasm.

Morphological changes were seen in the pancreas in the DM group or in the STZ- induced group (P1), namely lesions in the pancreatic tissue in the form of endocrine system cell degeneration that caused cell necrosis.

Endocrine cell degeneration is seen in nuclei that are transformed into polymorphs (non-uniform). The changes that occur are described in the form of changes in the nucleus of the endocrine gland cells to become smaller (pyknosis) and even begin to disappear, only an empty cytoplasm containing glycogen stores is visible and enlarged without a nucleus and a hyperchromatic cytoplasmic form.

In the positive control group given glibenclamide, there was a significant decrease in the blood glucose levels of rats. Glibenclamide is a sulfonylurea oral hypoglycemic drug that has a therapeutic effect on lowering blood glucose levels, so it was chosen as a comparison compound in research (Tanu, 2007).

Its interaction with ATP-sensitive K channels on the cell membrane causes the membrane to depolarize and this condition opens the Ca channels. This dose was then converted into a dose for the test animals were white rats. The decrease in blood glucose levels in glibenclamide-treated rats was also supported by histopathological observations where the improvement of the islets of Langerhans was close to normal.

In the treatment with ethanolic extract of mangosteen rind showed a decrease in blood glucose levels on days 7 and 14 in rats treated with glibenclamide and ethanol extract of mangosteen rind on days 7 to 14 although not quite close to normal.

Blood Sugar Levels and Dosage Group

Blood glucose levels in the 150 and 300 mg/kg BW groups showed almost the same effect as the positive control. The decrease in glucose levels in the treatment with extract at a dose of 150 mg/kg BW was more significant than at a dose of 300 mg/kg BW, possibly due to the presence of antagonist compounds contained in the mangosteen rind extract. The research proposed by Ambarsari et al. (2013) on the anti-diabetic effectiveness of the plant *Syzygium cummin* which stated that a dose of 100 mg/kg BW was more effective than a dose of 200 mg/kg BW and 400 mg/kg BW. The same thing was also stated by Sukadar et al.

Things like this can happen, considering that diabetes mellitus is a metabolic disorder disease related to energy production in human (or animal) cells and includes metabolic disorders from birth (Hasdianah, 2012). The physiological condition of each individual is different is one of the factors why the dose of the drug determines the therapeutic effect of the drug.

This condition is also influenced by fasting blood glucose levels before administration of the test preparations that can be seen. The ability to lower blood glucose levels is found in the mangosteen rind due to the presence of antioxidants in the mangosteen rind. There was a decrease in blood glucose levels during the treatment of mangosteen peel extract, possibly due to the antioxidant content where the mangosteen peel extract had a damping power of 72.93 percent. Mangosteen rind turns out to contain xanthenes which are high levels of antioxidants because their antioxidant content is 66.7%, (Qosim, 2007).

CONCLUSION AND RECOMMENDATIONS

The parameters used to assess the level of pancreatic damage in this study were the islets of Langerhans morphometry which included diameter and circumference. In addition to quantitative data, visualization of the islets of Langerhans is also described descriptively, namely the state of the structure and endocrine cells of the islets of Langerhans which have symptoms of cell necrosis. The diameter and circumference of the island of Langerhans were calculated using the Image Raster application. Each island of Langerhans has a different shape from one another. To get the diameter of the island of Langerhans done evenly by drawing a line from

one side of the island of Langerhans to the other side that is parallel to the horizontal, then the Image Raster application outputs the value of the length of the diameter in units of m. The perimeter of the island of Langerhans was also measured using the Image Raster application. This is done by drawing polygonal lines along the fine fibers surrounding the islets of Langerhans. Then the Image Raster application outputs the data in m units. The following is an example of the results of calculating the diameter and circumference of Langerhans Island using the Image Raster application.

Insulin Expression in Rat Pancreatic Beta Cells with Immunohistochemistry Immunohistochemical technique or IHC is an examination method using monoclonal and polyclonal antibodies to identify antigens in tissue. The IHC test can be used to check for normal and abnormal antigens present in the tissue. The main advantage of the IHC method compared to other detection methods is that it can detect proteins in cell morphology (Webster et al., 2009) (Kaliyappan et al., 2012). There are three methods of calculating IHC scores that are common and internationally accepted, namely Allred-Score, Immunoreactive Score (IRS), and H-Score. The Allred-Score combines the value of the percentage of positive cells with the intensity of the color of the reaction that occurs in the observed field of view.

Acknowledgment

Thank you to the supervisor who has guided to complete this research. And don't forget we thank the family for the great support to the author.

ETHICAL CONSIDERATION

This research has been declared ethically compliant according to the WHO 7 Standards 2011 by the Health Research Ethics Commission (KEPK) University of Prima Indonesia.

Funding Statement

The authors did not receive support from any organization for the submitted work.

Conflict of Interest Statement

The author's interest in the last 3 years has been in the field of biomedical medicine and public health. Because in the current era, herbal treatment is needed using natural ingredients to minimize the side effects of medicines circulating in the community for the realization of better public health.

REFERENCES

- Abdulwahab, DA et al. (2021) 'Melatonin protects the heart and pancreas by enhancing glucose homeostasis, oxidative stress, inflammation and apoptosis in T2DM-induced mice', *Heliyon*, 7(3), p. e06474. doi: 10.1016/j.heliyon.2021.e06474.
- Ajie, RB (2015) 'WHITE DRAGON FRUIT (*Hylocereus undatus*) POTENTIAL AS A TREATMENT OF DIABETES MELLITUS', 4, pp. 69–72.
- Akhigbe, R. and Ajayi, A. (2021) 'Impact of reactive oxygen species in the development of cardiometabolic disorders: a review',

- Lipids in Health and Disease, 20(1), p. 1–18. doi:10.1186/s12944-021-01435-7.
- Ariyadi, T. and Suryono, H. (2017) 'Quality of Skin Tissue Preparation and Microwave Method', *Journal of Labora Medika Vol*, 1(1), p. 7–11.
- Asdie, RH, Witjaksono, DP and Loehoeri, S. (2008) *Textbook of Internal Medicine*, Interna Publishing.
- Asmat, U., Abad, K. and Ismail, K. (2016) 'Diabetes mellitus and oxidative stress—A brief review', *Saudi Pharmaceutical Journal*, 24(5), pp. doi:10.1016/j.jsps.2015.03.013.
- Azitha, M., Aprilia, D. and Ilhami, YR (2018) 'The Relationship of Physical Activity with Fasting Blood Glucose Levels in Diabetes Mellitus Patients who Come to the Internal Medicine Clinic of M. Djamil Hospital Padang', *Andalas Health Journal*, 7(3), p. 400. doi:10.25077/jka.v7.i3.p400-404.2018.
- Bacanli, M. and Dilsiz, SA (undated) 'Effects of phytochemicals against diabetes', 89, pp.209-238. doi: 10.1016/bs.afnr.2019.02.006.
- Balfas, RF, Ustrina, N. and Widyarini, S. (2018) 'Effect of Spirulina platensis on Level Analysis, Histopathology, Insulin and Glut-4 Expression in Streptozotocin-Induced Wistar Rats (Effect of Spirulina platensis on Level Analysis, Histopathology), Expression of Insulin and Glut-4 in ', 16(2), p. 238–247.
- Bancroft, JD and Layton, C. (2019) *Connective tissue and other mesenchyme with their stains, Bancroft's Histological Engineering Theory and Practice*. doi:10.1016/b978-0-7020-6864-5.00012-8.
- Barrett, KE et al. (2012) *Ganong's Review of Medical Physiology 24th Edition's Review of Medical Physiology*, McGraw-Hill.
- Boudreau, MD et al. (2006) 'Food exposure to 2-aminoanthracene induces morphological and immunocytochemical changes in pancreatic tissue of fisher-344 mice', *Toxicological Sciences*, 93(1), p. doi:10.1093/toxsci/kf033.
- Charlton, A. et al. (2021) 'Oxidative stress and inflammation in renal and cardiovascular complications of diabetes', *Biology*, 10(1), p. 1–18. doi:10.3390/biology10010018.
- Chin, SC et al. (2004) 'Amyloidosis Concomitantly Involving Sinonasal Cavity and Larynx', *American Journal of Neuroradiology*, 25(4), p.
- DeLong, L. (2013) *Robbins Basic Pathology, General and Oral Pathology for Dental Hygienists*. doi:10.1136/jcp.47.1.95-d.
- Ebaid, H. et al. (2019) 'Effectiveness of Adansonia digitata Leaf Methanol Extract in Reducing Hyperglycemia, Hyperlipidemia, and Oxidative Stress of Diabetic Rats', *BioMed Research International*, 2019. doi: 10.1155/2019/2835152.
- Erwin et al. (2013) 'INSULIN EXPRESSION IN THE PANCREAS OF MICE (Mus musculus) INDUCED BY REPEAT STREPTOZOTOCIN', *Journal of Veterinary Medicine - Indonesian Journal of Veterinary Sciences*, 7(2), p. 97–100. doi: 10.21157/j.ked.animal.v7i2.900.
- Esmail Al-Snafi, A. et al. (2019) 'Medicinal Plants with Antidiabetic Effects-A Review (Part 1)', 9(3), p. 9–46.
- Eva Decroli (2019) *Type 2 Diabetes Mellitus*. Publishing Center for Internal Medicine, Faculty of Medicine, Andalas University, Padang.
- Fedchenko, N. and Reifenrath, J. (2014) 'Different approaches to interpretation and reporting of results of immunohistochemical analyzes in bone tissue - a review', *Diagnostic Pathology*, 9, p. 221. doi:10.1186/s13000-014-0221-9.
- Fitriani, N. and Layal, K. (2017) 'Antidiabetic Activity of Combination of Ethanol Extract of Andrographis Paniculata Leaves and Vernonia Amygdalina Introduction Diabetes mellitus is a disease', 7(2).
- Fitriani, N., Layal, K. and Kamila, K. (2017) 'Antidiabetic Activity of Combination of Ethanol Extract of Andrographis Paniculata Leaves and Vernonia Amygdalina', *Syifa' MEDIKA: Journal of Medicine and Health*, 7(2), hlm. 104. doi:10.32502/sm.v7i2.1371.
- Hayden, MR et al. (2007) 'Longitudinal ultrastructural study of amyloid islands in a mouse model of HIP type 2 diabetes mellitus', *Experimental Biology and Medicine*, 232(6), p. 772–779. doi: 10.3181/00379727-232-2320772.
- Ighodaro, OM, Adeosun, AM and Akinloye, OA (2017) 'Alloxan-induced diabetes, a general model for evaluating the glycemic control potential of therapeutic compounds and plant extracts in experimental studies', *Medicina (Lithuania)*, 53(6), p. 365–374. doi: 10.1016/j.medic.2018.02.001.
- Iloanya, EL et al. (2021) 'Effect of Abrus Precatorius Seed Methanol Extract Fraction on Malondialdehyde and Antioxidant Levels of Alloxan-Induced Diabetic Rats', 24 (March), p. 35–51. doi: 10.9734/JABB/2021/v24i130195.
- International Diabetes Foundation (2019) 'International Diabetes Federation - Facts & Figures', 2019.
- Jameson, L. (2017) *Harrison's endocrinology 4th Edition*.
- Jubaidah, S. et al. (2018) 'Formulation and Test of Rabbit Hair Growth from Hair Tonic Preparations Combination of Celery Leaf Extract (Apium graveolens Linn) and Mangkokan Leaf (Polyscias scutellaria (Burm.f.) Fosberg)', *Jurnal: Ilmiah manuntung*, 4(1), pp.8–14.
- K, AL, N, FA and Adi, P. (2015) 'The Effect of Powdered Cow's Milk on Liver MDA Levels in Male White Rats (Rattus Novergicus Strain Wistar) Type 2 Diabetes Mellitus Model The Effect of Cow's Milk Powder on Hepatic MDA Levels in Rats Male White (RattusNovergicusWista', 28(3), pp. 222–227.
- Kabiraj, A. et al. (2015) 'Properties of Antigen-Antibody (Ag-Ab) interactions:7 Monoclonal and polyclonal antibodies: sensitivity and specificity', *BioMedSciDirect*, 6(2), p. 5204–5210. Available at: https://www.biomedscidirect.com/journalfiles/IJBMRF20151859/principle_and_tech_niques_of_immunohistochemistry_a_review.pdf.
- Kaliyappan, K. et al. (2012) 'Applications of immunohistochemistry', *Journal of Pharmacy and Bioallied Sciences*, 4(6), p. 307. doi: 10.4103/0975-7406.100281.
- Lin, S. and Srijit, T. (2018) 'Phytochemicals and their effective role in the treatment of diabetes mellitus: a brief review', *Phytochemical Reviews*, 17(5), p. 1111-1128. doi:10.1007/s11101-018-9575-z.
- Macdonald, O. et al. (2019) 'Oral Supplementation of Fish Oil Extract to Reduce Fasting Blood Glucose and Endothelial Damage But Not Malondialdehyde Levels in Diabetic Male Wistar Rats (Rattus norvegicus)', *Saudi Pharmaceutical Journal*, 7(3), p. 1–18. doi: 10.1155/2017/357870.