



JETROMI

Journal of Endocrinology, Tropical Medicine, and Infectious Disease



A Case Report of a Giant Pheochromocytoma

Dian Anindita Lubis^{1,2}, Agnes Stephanie Harahap³, Em Yunir¹

¹ Division of Endocrinology, Diabetes and Metabolic, Department of Internal Medicine, Faculty of Medicine, University of Indonesia, Jakarta, Indonesia

² Division of Endocrinology, Diabetes and Metabolic, Department of Internal Medicine, Faculty of Medicine, University of Sumatera Utara, Medan, North Sumatera, Indonesia

³ Department of Anatomical Pathology, Faculty of Medicine, University of Indonesia, Jakarta, Indonesia

Abstract Pheochromocytoma is a rare catecholamine secreting tumor that are usually arise from adrenal medulla and produces signs and symptoms of excessive catecholamine secretion from tumor. A 32 years old female presented to the hospital, with dyspeptic symptoms. She had fluctuative hypertension, palpitation and sweating. Abdominal ultrasonography showed a right adrenal mass, and computed tomography of the adrenal glands confirmed a right adrenal mass. However, clinical biochemistry tests specific for pheochromocytoma was not performed. Laparoscopic right adrenalectomy was done and the adrenal tumor was excised. Histopathology and immunohistochemistry confirmed the diagnosis of adrenal pheochromocytoma; the tumor cells being positive for chromogranin, synaptophysin, S-100 protein, and inhibin. Following the surgery, the patient did well and showed full recovery at follow-up after 1 month.

Keyword: Adrenal Pheochromocytoma, Hypertension, Metanephrine

Abstrak. Feokromositoma merupakan tumor jarang yang mensekresi hormon katekolamin yang umumnya berasal dari medulla adrenal dan menghasilkan tanda dan gejala dari sekresi katekolamin yang berlebih dari tumor. Seorang wanita 32 tahun datang ke rumah sakit, dengan gejala dispepsia. Pasien memiliki hipertensi yang fluktuatif, palpitasi dan berkeringat banyak, Ultrasonografi abdominal menunjukkan adanya massa adrenal kanan. Namun, pemeriksaan biokimia spesifik untuk feokromositoma tidak diperiksa. Pada pasien dilakukan laparotomi adrenalectomi kanan dan dilakukan eksisi tumor adrenal. Hasil histopatologi dan imunohistokimia menunjukkan suatu feokromositoma adrenal terdapat sel tumor yang positif untuk chromogranin, syntaptophysin, S-100 protein, dan inhibin. Setelah dilakukan pembedahan, pasien tidak memiliki keluhan dan tampak kembali sehat setelah 1 bulan pembedahan.

Kata Kunci: Feokromositoma Adrenal, Hipertensi, Metanefrin

Received 30 September 2019 | Revised 12 December 2019 | Accepted 30 December 2019

*Corresponding author at: Division of Endocrinology, Diabetes and Metabolic, Department of Internal Medicine, Faculty of Medicine, University of Indonesia, Jakarta, Indonesia

E-mail address: dianindita@hotmail.com

Copyright © 2020 Published by Talenta Publisher

ISSN: 2686-0872 | e-ISSN: 2686-0856 | DOI: 10.32734/jetromi.v2i1.2037

Journal Homepage: <https://jetromi.usu.ac.id>

1. Introduction

Catecholamine-secreting tumor, pheochromocytoma, is a rare neoplasm that derived from chromaffin tissue on the adrenal medulla. Prevalence of pheochromocytomas is estimated between 0,05% and 0,1% of patients with hypertension or 3 to 8 people per million per year in general population. Peak incidence occurs during the fourth and fifth decades of life [1],[2]. However, as illustrated by autopsy studies, the average delay in diagnosis is almost 3 years and in 0,05% to 0,1% of the patients, or even missed during life [3]. Here, we present a rare case of secondary hypertension due to giant adrenal pheochromocytoma.

2. Case Illustration

A 32-year-old woman, visited hospital with complaints of dyspepsia for the past 3 months. She was investigated elsewhere for dyspeptic symptoms and was found to have a right adrenal mass of 7,5 cm in diameter on screening ultrasound. On systemic examination, she was found hypertension and tachycardia. Patient has known hypertension for 1 year. However, the blood pressure has a tendency to fluctuate. She was prescribed calcium channel blockers (amlodipine 10 mg once daily). In addition, she also had palpitations, headache and sweating for the past 4 months. Each attack persists for few minutes to half an hour and occurs irregularly. Physical examination revealed no edema nor obesity. Abdomen was soft, no tenderness, no palpable masses, no organomegaly, and no ascites. Her bowel sounds normal.

ECG showed normal tachycardia. An ultrasonography of abdomen showed a right adrenal mass. She then had Computed Tomography (CT) scan of abdomen and revealed right sided adrenal mass of a size of 9,05 cm x 7,68 cm x 9 cm (Figure 1). We made a provisional diagnosis of secondary hypertension due to adrenal pheochromocytoma. However, for confirming diagnosis, we need to do biochemical investigations i.e. 24-hour urinary metanephrine level or fractionated metanephrines in plasma, which patient refused to. Cortisol level was normal (17,36 ug/dL). With written consent, patient was prepared for right open adrenalectomy with all precautions were taken and prepared for managing the preoperative hypertensive crisis. Right adrenalectomy was then performed. The patient was extubated and was kept in the intensive care unit for 48 hours. There were no untoward events in the postoperative period, patient remained normotensive in the postoperative period and the patient was discharge home on the 10th day.

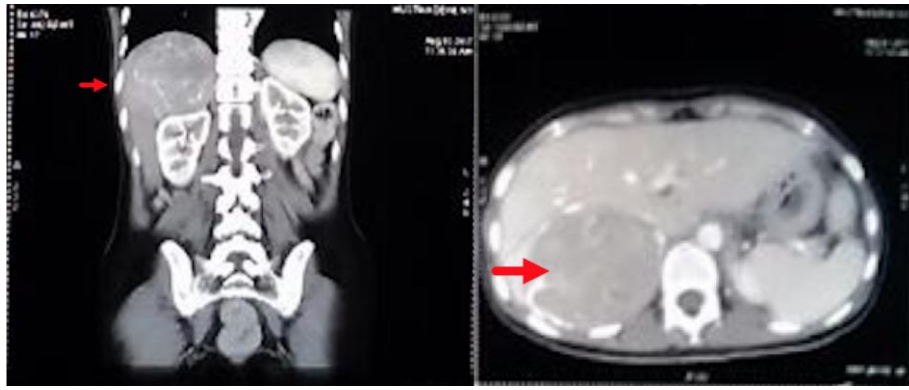


Figure 1 MSCT/CT scan abdomen with contrast

Gross examination of the right adrenal gland showed a nodular mass with the measurements of 9.5 x 8 x 6 cm, brown, encapsulated, and surrounding with fat. The microscopy sections showed a Zellballen nests of chromaffin cells with vascular invasion, round/oval nuclei, pleomorphic, and areas of brown fat, suggested pheochromocytoma in the adrenal gland. Immunohistochemistry of the tumor cells were positive for chromogranin, synaptophysin, inhibin and S-100 protein. They were negative for calretinin, melanA, bcl2 (Figure 2.).

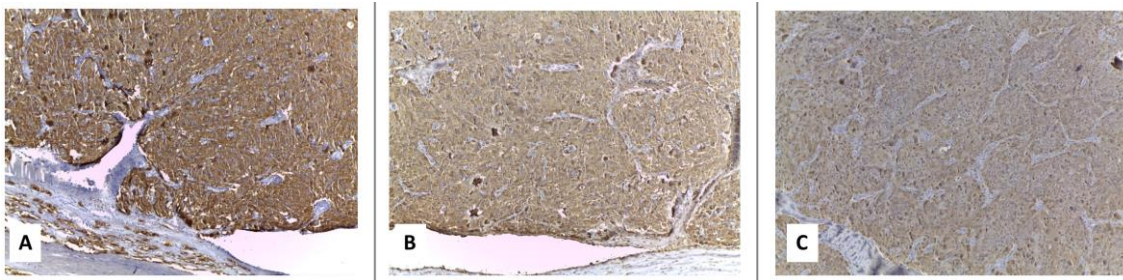


Figure 2 Immunohistochemistry of tumor cells: A) Chromogranin; B) synaptophysin; C) S-100

The patient was followed up in the hospital after 1 month, the blood pressure was normal. Six weeks after surgery, 24-hour urinary metanephrine revealed normal level of metanephrine (58 mcg/24 h), normal level of normetanephrine (353 mcg/24 h), and normal total metanephrine (411 mcg/24 h). She has then been advised to follow up periodically in order to rule out recurrence.

3. Discussion

Over the last 2 decades, incidence of adrenal incidentalomas has dramatically increased as a result of a widespread use of abdominal imaging modalities, including ultrasound, CT, and magnetic resonance imaging (MRI). An understanding of the differential diagnosis of adrenal masses, a biochemical profile of hyperfunctioning adrenal tumors, and assessment of the risk factors for malignancy of adrenal is required in the evaluation of adrenal incidentalomas.

Patients with hyperfunctioning tumors and those with potentially malignant lesions need to be performed adrenalectomy, afterwards. Factors that influencing the decision include the size and the nature of lesion [4].

Functioning adrenal tumors, even pheochromocytoma, are not always found, even when signs of adrenal hormone excess are evident. Approximately 30% of pheochromocytomas are found as incidentalomas, and later diagnosed accurately as pheochromocytomas. During screening for adrenal tumors, elevated plasma and urine catecholamines is essential for diagnosing pheochromocytoma. Urinary catecholamines and their metabolites can be measured accurately in 24-hour urine, while plasma catecholamines levels are often affected by various conditions, such as hypertonic status and stress [4].

Signs and symptoms of pheochromocytoma, as a result from hemodynamic and metabolic action of circulating catecholamine, typically present with hypertension, unusual sweating, headache, frequent arrhythmias, and pallor during hypertension episode [1],[2]. However, giant pheochromocytoma, >7 cm in size, may not present with these symptoms. This is probably due to the presence of tumor necrosis, high loads of interstitial tissue compared to chromaffin cells or lack of catecholamine secretion due to encapsulation by connective tissue [5].

Diagnosis of pheochromocytoma is confirmed by elevation of metanephrine and catecholamine production, supported with radiologic studies [1]. However, prior to ordering biochemical testing, detailed medical history including a family history and factors that may provoke paroxysms is an essential requirement. On localizing tumor, CT scanning is the preferred imaging modality to MRI because its outstanding spatial resolution is superior. It has 90% of sensitivity and 75% to 80% of specificity for adrenal tumor [3].

To prevent cardiovascular complications, it is always indicated to perform surgical removal of the tumor [6].

The most important goal for preoperative management of a pheochromocytoma patient is to normalize heart rate, blood pressure, function of other organs, and prevent a patient from a surgery-induced catecholamine-storm by giving the combination of alpha and beta blockade [2], [7]. Surgical resection of the tumor is the treatment of choice for pheochromocytoma, with result of cured hypertension [7]. However, 25% of patients remain hypertension, possibly due to coexisting hypertension. Laparoscopic removal of pheochromocytoma should be limited to a diameter of 4 cm, while open surgical exploration is indicated when tumors are large, multiple, or difficult to remove by laparoscopy [8]. In postoperative period, monitoring blood pressure, heart rate, and blood glucose is recommended in conjunction with the adjustment of associated therapy [9]. To determine whether the tumor has completely removed or not, measurement of urine or plasma metanephrines is recommended at 2 to 6 weeks after surgery [3].

Since there were no histological criteria nor scoring systems has been described to differentiate between malignant and benign pheochromocytoma, in 2017, World Health Organization (WHO) made the classification of endocrine tumor (benign pheochromocytoma and malignant pheochromocytoma) into a single section; pheochromocytoma [10].

Generally, 90% of patients is cured after surgical removal, yet a persistent risk of local or metastatic recurrences or a new tumor appears in 5% during 5 years follow-up [3]. To assess recurrent or metastatic disease, lifelong annually biochemical testing is suggested [9]. If biochemical test is elevating persistently, additional imaging studies are indicated [3].

4. Conclusion

We have reported a rare case of giant adrenal pheochromocytoma. Adrenal pheochromocytoma was confirmed by clinical, imaging, and histopathology findings. Even though pheochromocytoma causes hypertension in 0,1%, early detection is crucial, not only for the potential treatment of hypertension but also to prevent the potential fatal condition of the unrecognized tumor.

REFERENCE

- [1] H. Huang, J. Abraham, E. Hung, S. Averbuch, M. Merino, S. M. Steinberg, et al., "Treatment of Malignant Pheochromocytoma/Paraganglioma with Cyclophosphamide, Vincristine, and Dacarbazine: Recommendation from a 22-year Follow-Up of 18 Patients," *Cancer*, vol. 113, pp. 2020-8, 2008.
- [2] K. Pacak, H. J. L. M. Timmers, G. Eisenhofer, "Pheochromocytoma," in *Endocrinology: Adult and Pediatric*, seventh edition, J. L. Jameson, L. De Groot, Eds. Elsevier, 2016, pp. 1902-30.
- [3] J. W. M. Lenders, G. Eisenhofer, "Update on Modern Management of Pheochromocytoma and Paraganglioma," *Endocrinology Metabolism*, vol. 32, pp. 152, 2017.
- [4] T. Ito, T. Imai, T. Kikumori, A. Shibata, T. Horiba, H. Kobayashi, et al, "Adrenal Incidentaloma: Review of 197 Patients and Report of a Drug-Related False-Positive Urinary Normetanephrine Result," *Surgery Today*, vol. 36, pp. 961-5, 2006.
- [5] S. Munakomi, S. Rajbanshi, P. S. Adhikary, "Case Report: A Giant but Silent Adrenal Pheochromocytoma – A Rare Entity," *F1000Research*, vol. 5, pp. 290, 2016.
- [6] R. Ramachandran, V. Rewari, "Current Perioperative Management of Pheochromocytomas," *Indian Journal of Urology*, vol. 33, pp. 19-25, 2017.
- [7] S. K. Biswas, M. J. Alam, M. M. Rahman, M. M. Rahman, L. Sanjowal, M. Islam, "Case Report A Case Report of Adrenal Pheochromocytoma," *Faridpur Medical College Journal*, vol. 6, pp. 55-8, 2011.
- [8] W. M. Manger, R. W. Gifford, "Pheochromocytoma," *The Journal of Clinical Hypertension*, vol. 4, pp. 62-72, 2002.
- [9] J. W. M. Lenders, Q-Y. Duh, G. Eisenhofer, A-P. Gimenez-Roqueplo, S. K. G. Grebe, M. H. Murad, et al, "Pheochromocytoma and Paraganglioma: An Endocrine Society Clinical Practice Guideline," *The Journal of Endocrinology and Metabolism*, vol. 99, pp. 1915-42, 2014.
- [10] A. K. Lam, "Update on Adrenal Tumours in 2017 World Health Organization (WHO) of Endocrine Tumours," *Endocrine Pathology*, pp. 1-15, 2017.