

## The Evaluation of Variations of The Hyoid Bone with Multidetector Computerized Tomography

\*Gunes Bolatli<sup>1</sup>, Nadire Unver Dogan<sup>2</sup>, Zeliha Fazliogullari<sup>2</sup>, Ali Sami Kivrak<sup>3</sup>,  
Ismihan Ilknur Uysal<sup>4</sup>, Ahmet Kagan Karabulut<sup>2</sup>, Yahya Paksoy<sup>5</sup>

<sup>1</sup>Department of Anatomy, Siirt University, Medical Faculty, İstanbul, Turkey.

<sup>2</sup>Department of Anatomy, Selcuk University, Medical Faculty, Konya, Turkey.

<sup>3</sup>Department of Radiology, Medova Hospital, Konya, Turkey. <sup>4</sup>Department of Anatomy, Necmettin Erbakan University, Meram Medical Faculty, Konya, Turkey. <sup>5</sup>Department of Radiology, Selcuk University, Medical Faculty, Konya, Turkey.

\*Email: [gunesbolatli83@gmail.com](mailto:gunesbolatli83@gmail.com)

**Abstract:** The hyoid is a U shaped bone with a backward concavity. Locates at the lower edge of the mandible and lies parallel to the floor — functions as an attachment point for muscles and soft tissues of head and neck. The aim is to examine the variations and ossification of the hyoid. This study was performed retrospectively in 2010 - 2013 on 200 CT images. 3D volume rendering images of pure hyoid bone created from the axial CT images in 1 mm slice thickness. The morphological variation count was 23; ossification variations were 9 cases. No difference observed by gender, but there are differences between the age groups for ossification. Ossification rates were found as; partial 34 %, unilateral 33%, complete 22%, early 11%. Most of the morphologic variation were belong to minor horn (57%), variations of major horn were 30%. The clinical importance of hyoid bone has realized in recent years. Due to the close relationship of this bone with the muscles, ligaments, fascias, sternum, clavicles, its dysfunction can lead to general problems. Studies about the variations of hyoid bone found to be quite low, and we believe that our research will contribute to the content of literature.

**Keywords:** hyoid; multi detector computed tomography; ossification; variation

### INTRODUCTION

The hyoid is a U shaped bone with a backward concavity which locates at the lower edge of the mandible and lies parallel to the floor. As an active and highly mobile bone, its function is to be an attachment point for muscles and soft tissues of head and neck<sup>1</sup>.

Hyoid ossified from six ossification centers, four of these centers located in the four horns and other two centers located in the body, the ossification starts; at the ends of intrauterine life in the significant horn, immediately after that in the body and in the 1-2 years old in the minor horns<sup>1</sup>. The ossification will be complete in the course of life. The clinical importance of hyoid bone has to realize in recent years. Due to the close relationship with the muscles, ligaments, fascias, sternum, and clavicles, its dysfunction

**Corresponding Author:** Gunes Bolatli

Siirt Universty Medical Fakulty, Center campus, Güres street 56100 Siirt/Türkiye.

Email: [gunesbolatli83@gmail.com](mailto:gunesbolatli83@gmail.com)

instead of only local problems leads to general issues<sup>1,2</sup>. Its dysfunction also affects the physiology of swallowing and speech because of its close relationship with the structures associated with swallowing and breathing. Therefore the association of hyoid bone with vital functions such as drinking and breathing, several; functional, positional, and conditional studies of hyoid bone have been performed in recent years<sup>3-9</sup>.

Science technology developed with the current method of bringing by Multidetector computed tomography (MDCT), the observation of anatomy, ossification, functions, variations, relationship with other structures, and several other well-known measurements of the hyoid bone, could be done.

Studies about the variations of hyoid bone are scanty in the literature. Therefore, in this study, the shape, ossification, and changes of hyoid bone were investigated in the patients without any problem in the mentioned region. The patients divided according to age and sex groups. Our primary aim put forth a variety of variational to examine the variations and to emphasize the clinical importance of hyoid.

## MATERIALS AND METHODS

This retrospective study was performed in Selcuk University Faculty of Medicine, with Medical Ethics Committee approval number 2012/91, from January 2010 to June 2013, on 200 patients CT images. The patients have not had any history of neck trauma or surgery. Observable axial CT images in 1 mm slice thickness transferred to the workstation (Virtual Place Advance Plus Azer, Tokyo, Japan). At the workstation in addition to axial, sagittal and coronal reformatted images also were obtained. Also the necessary procedures for cutting and removing of the surrounding muscles, bones and soft tissues were performed and the 3D volume rendering images of pure hyoid bone were created.

Sagittal and coronal images were evaluated for morphological and ossification variations. Morphologically; anatomical and articulation variations examined. Ossification levels of hyoid bone were classified and studied in four different groups. This four group are; corpus and major horn of the no ossification, there is partial ossification and complete ossification.

## RESULT AND DISCUSSION

All cases were grouped by gender and seven separated ranges of age (Table 1). The position of the hyoid bone was evaluated according to age and gender.

Table 1. Distribution of patients by age and gender

Age	0-9	10-19	20-29	30-39	40-49	50-60	Above 60	Total
Male	8	16	17	13	15	15	22	106
Female	12	12	10	14	15	12	19	94

The morphological variation observed in 23 out of 200 (11.5%) patients and ossification variations observed in 9 out of 200 (4.5%) patients. Changes associated with the ossification evaluated firstly. After that, all ossification related variation cases

removed, and images evaluated for gender and age differences. No significant difference by gender observed, but differences between the age groups were determined. In the 0-9 age group, no ossification found, the increase of calcification with the increasing age observed. In the over 60 age group, there was complete ossification in 34 people and partial hardening in 3 people (8.8%) (Fig. 1).

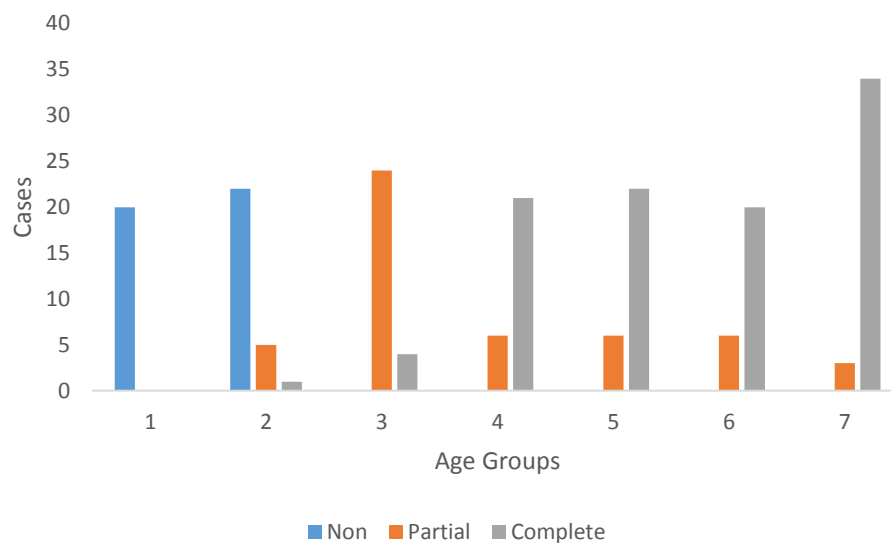
The hyoid bone evaluated anatomically too. Different parts of bone showed various morphological variations in the 23 (11.5%) patients. In some patients either in the body or horns, besides the deformities, absences were observed too.

Most of the variation was belong to minor horns (13 patient, 56.5%) include; absences of small horns, deformities, and variations of its articulations (Fig. 2). These include minor horn absence (Fig. 2 a, b, c), changes in shape (Fig. 2 d,e), and articulates the variations (Fig. 2 f) was determined.

Variations of first horn detected in 30% (7 patients) of cases. These variations were only deformities — all of them (Fig. 3) the central horn affecting changes. Varieties of body detected in 13% of total variation cases. These variations were deformities, too (Fig. 4), the body shape that differs from the normal os hyoid.

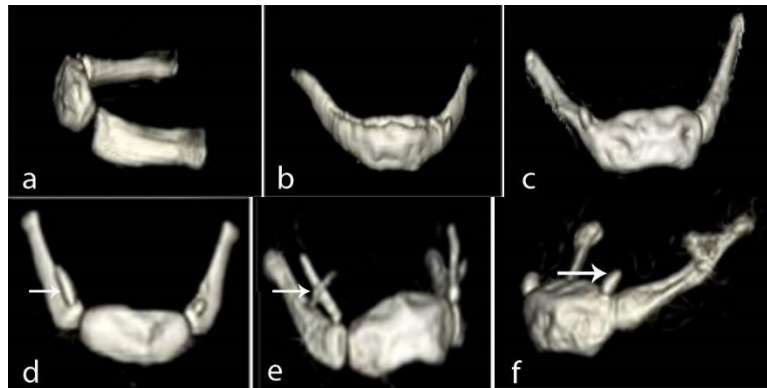The ossification between the body and horns were determined in 9 cases. All ossification percentages were; partial ossification 33% (45,47,52 years in three patients) (Fig. 5 a), unilateral ossification 33% (60,62,70 years in three patients) (Fig. 5 b,c), incomplete ossification 22% (63,73 years in two patients) (Fig. 5 d,e) and early ossification 11% (16-year-old patient) (Fig. 5 f).

Considered the position, we also found that there were no differences by gender in the place of the hyoid.



(1: 0-9 age, 2: 10-19 age, 3: 20-29 age, 4: 30-39 age, 5: 40-49 age, 6: 50-59 age, 7: over 60 years)

Figure 1. Distribution of ossification according to intervals of age group.



- a. Bilateral absence of minor horn thicker and consists of the usual major horn
- b. Bilateral minor horn absence
- c. Unilateral (right) sided minor horn absence
- d. Unilateral minor horn is longer than the other side
- e. To be longer than usual minor horn
- f. Making joint body with minor horn

Figure 2. Variations of minor horn

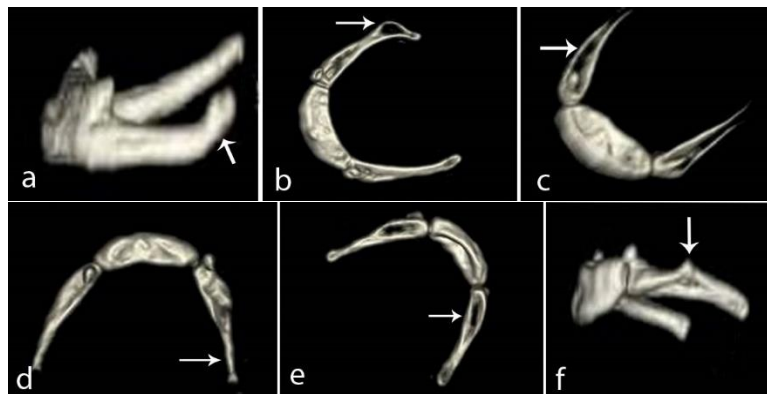
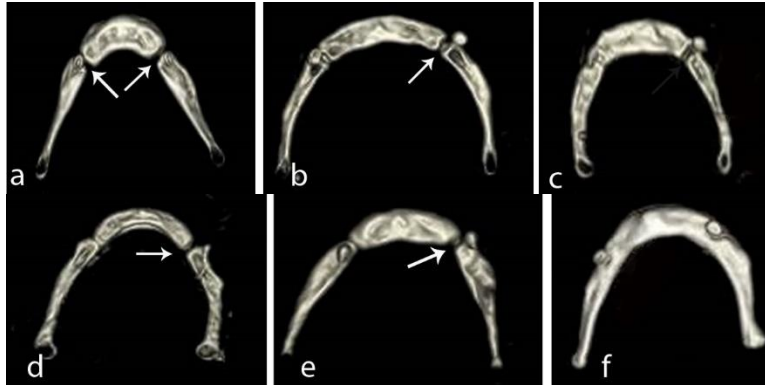


Figure 3. Variations of major horn; major horn deformity

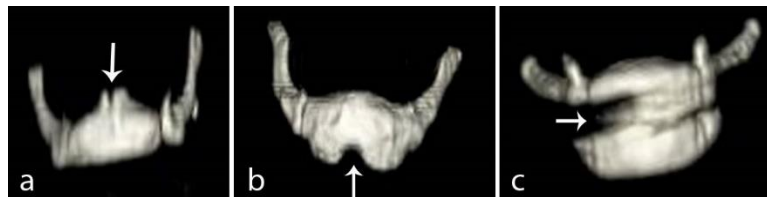

Figure 4. Variations of the body; body shape that differs from the normal os hyoid



- a. Partial ossification
- b. Unilateral ossification
- c. Unilateral ossification
- d. Incomplete ossification
- e. Incomplete ossification
- f. The early completion of the ossification

Figure 5. Variations of ossification major horn and body

In most studies, shape, ossification, and positional variations of hyoid bone have been evaluated relative to a particular disease. Generally, these studies have been performed as autopsy study methods and rarely have been performed with MDCT. Besides that, the reviews have been performed in patients with a variety of respiratory and swallowing problems even had undergone surgical procedures in this region<sup>5-13</sup>.

Morphological, ossification, and the extra ossification of body, variations have been described in the literature<sup>14-16</sup>. In our study on 200 patients, morphologic changes determined in 23 (11.5%) cases and exceptions associated with ossification determined in 9 (4.5%) cases. Reported studies have already shown; there are no differences in hardening by gender, but it increases by increasing age and continues between 21 and 30 years of age<sup>17</sup>. Gupta et al.<sup>18</sup> have observed that ossification completes five years earlier in females, and calcification of entire bones completes after 60 years old. Some studies have suggested the completion of hardening under 30 years old, some others under 40 years old<sup>19-21</sup>. Reed<sup>22</sup>, in his research, observed that ossification starts in the 6th month of life, continues in adolescence, and there are no differences by gender in the ossification. In increased ages, calcification has been observed additionally during the hardening<sup>16,23,24</sup>. We also determined that ossification starts after 16 years old, continues in adolescence, moving fast up to 39 years old, and there are no gender differences in ossification. Unlike ours, another study stated 20 years old as the completion time of hardening<sup>25</sup> as in the Gupta et al.<sup>18</sup> studies, in our research, either the complete ossification observed in above 60 years old.

In the studies on the ossification, unilateral ossification was determined in the later ages (after 70 years)<sup>15,18</sup>. We identified one case early and eight instances in late ossification cases among all patients. There was no any bilateral ossification among the new ossification cases.

Miller et al. 15 in their study have determined the shape differences by gender as the distal tip of the first horn is higher in the male than which is in the female. Some other authors have reported that there are no differences by gender in the position of

hyoid bone<sup>26</sup>. In our study, we found no differences by gender in the shape of the hyoid bone.

The position of the hyoid bone could determine through the muscles and ligaments which attached it from the top and the bottom. The area of hyoid bone could change by courtesy of tongue and mandible movements, and attachment points of mentioned muscles and ligaments<sup>2,6,7</sup>. Tsai<sup>27</sup> has determined no difference by gender in the hyoid position. As well as in this study, we also found that there were no differences by gender in the area of the hyoid.

The involvement of hyoid is significant in the staging determination of larynx cancer. Metastatic involvement may be confused by variations in radiological examinations. The lack of knowledge about the morphology and differences of hyoid bone can lead to confusion in the diagnosis of certain diseases. Therefore, learning about hyoid bone is very important for radiologists and in terms of dealing with surgery of the region. Mainly, a broken hyoid bone in a suspicious death considered as strong evidence for suffocation.

Our study is a retrospective study, and since all images obtained in the supine position, personal characteristics such as height, weight, deformity, and posture disorder could not look. For this reason, we think that it would be beneficial to support it with prospective studies by knowing personal positions (height, weight, thorax diameter) in different areas (standing, sitting) and such.

## CONCLUSION

In an evaluation of literature, studies about the variations of hyoid bone found to be quite low, and we believe that our research on the variety and ossification of the hyoid bone in the 200 individuals will contribute to the content of literature.

## CONFLICT OF INTEREST

There were no conflicts of interest with related parties in this study.

## REFERENCES

1. Drake R, Vogl W, Mitchell A. *Gray's Anatomy for Students*: Gunes; 2007.
2. Molfenter SM, Steele CM. Use of an Anatomical Scalar to Control for Sex-Based Size Differences in Measures of Hyoid Excursion During Swallowing. *J Speech Lang Hear R*. Jun 2014;57(3):768-778.
3. Daly P, Preston CB, Evans WG. Postural response of the head to bite opening in adult males. *Am J Orthod*. Aug 1982;82(2):157-160.
4. Terk AR, Leder SB, Burrell MI. Hyoid bone and laryngeal movement dependent upon presence of a tracheotomy tube. *Dysphagia*. Apr 2007;22(2):89-93.
5. Eggensperger N, Smolka W, Iizuka T. Long-term changes of hyoid bone position and pharyngeal airway size following mandibular setback by sagittal split ramus osteotomy. *J Craniomaxillofac Surg*. Apr 2005;33(2):111-117.
6. Deljo E, Filipovic M, Babacic R, Grabus J. Correlation analysis of the hyoid bone position in relation to the cranial base, mandible and cervical part of vertebra with particular reference to bimaxillary relations / teleroentgenogram analysis. *Acta Inform Med*. Mar 2012;20(1):25-31.

7. Amayeri M, Saleh F, Saleh M. The position of hyoid bone in different Facial patterns: a lateral Cephalometric study. *European Scientific Journal*. 2014 (10):1857-1881.
8. Adamidis IP, Spyropoulos MN. Hyoid bone position and orientation in Class I and Class III malocclusions. *Am J Orthod Dentofacial Orthop*. Apr 1992;101(4):308-312.
9. Gnanadev R, Iwanaga J, Loukas M, Tubbs RS. An Unusual Finding of the Hyoid Bone. *Cureus*. Sep 26 2018;10(9):e3365.
10. Gale A, Kilpelainen PV, Laine-Alava MT. Hyoid bone position after surgical mandibular advancement. *Eur J Orthod*. Dec 2001;23(6):695-701.
11. Guven O, Saracoglu U. Changes in pharyngeal airway space and hyoid bone positions after body osteotomies and sagittal split ramus osteotomies. *J Craniofac Surg*. Jan 2005;16(1):23-30.
12. Kim MA, Kim BR, Choi JY, Youn JK, Kim YJ, Park YH. Three-dimensional changes of the hyoid bone and airway volumes related to its relationship with horizontal anatomic planes after bimaxillary surgery in skeletal Class III patients. *Angle Orthod*. Jul 2013;83(4):623-629.
13. Inanir N, Eren B, Cetin S, Eren F, Gundogmus U. Anatomical variation of hyoid bone. *Maedica (Buchar)*. 2014;9(3):272-274.
14. Gok E, Kafa IM, Fedakar R. Unusual variation of the hyoid bone: bilateral absence of lesser cornua and abnormal bone attachment to the corpus. *Surg Radiol Anat*. Aug 2012;34(6):567-569.
15. Miller KW, Walker PL, O'Halloran RL. Age and sex-related variation in hyoid bone morphology. *J Forensic Sci*. Nov 1998;43(6):1138-1143.
16. Naimo P, O'Donnell C, Bassed R, Briggs C. The use of computed tomography in determining development, anomalies, and trauma of the hyoid bone. *Forensic Sci Med Pat*. Jun 2015;11(2):177-185.
17. Harun WARW, Rajion ZA, Aziz IA, Samsudin AR. 3D Modelling and Evaluation of the Morphology of Hyoid Bone. *Ifmbe Proc*. 2007;14:2320-+.
18. Gupta A, Kohli A, Aggarwal NK, Banerjee KK. Study of age of fusion of hyoid bone. *Leg Med (Tokyo)*. Sep 2008;10(5):253-256.
19. Doual A, Leger JL, Doual JM, Hadjiat F. [The hyoid bone and vertical dimension]. *Orthod Fr*. Sep 2003;74(3):333-363.
20. D'Souza DH, Harish SS, Kiran J. Fusion in the hyoid bone: usefulness and implications. *Med Sci Law*. Oct 2010;50(4):197-199.
21. Leksan I, Marcikic M, Nikolic V, Radic R, Selthofer R. Morphological classification and sexual dimorphism of hyoid bone: new approach. *Coll Antropol*. Jun 2005;29(1):237-242.
22. Reed MH. Ossification of the hyoid bone during childhood. *Can Assoc Radiol J*. Aug 1993;44(4):273-276.
23. Shimizu Y, Kanetaka H, Kim YH, Okayama K, Kano M, Kikuchi M. Age-related morphological changes in the human hyoid bone. *Cells Tissues Organs*. 2005;180(3):185-192.
24. Kanetaka H, Shimizu Y, Kano M, Kikuchi M. Synostosis of the Joint Between the Body and Greater Cornu of the Human Hyoid Bone. *Clin Anat*. Oct 2011;24(7):837-842.

25. Parsons FG. The Topography and Morphology of the Human Hyoid Bone. *J Anat Physiol.* Jul 1909;43(Pt 4):279-290.
26. Bibby RE. The hyoid bone position in mouth breathers and tongue-thrusters. *Am J Orthod.* May 1984;85(5):431-433.
27. Tsai HH. The positional changes of hyoid bone in children. *J Clin Pediatr Dent.* Fall 2002;27(1):29-34.