

## Z Plasty Single Center Results in The Treatment of Pilonidal Sinus Disease in Children

Yusuf Atakan Baltrak, Seniha Esin Sogut, Onursal Varlikli

Department of Pediatric Surgery, Kocaeli Derince Education and Research Hospital  
Kocaeli, Turkey

Email: [dratakanbaltrak@gmail.com](mailto:dratakanbaltrak@gmail.com)

**Abstract:** Pilonidal sinus is a common chronic disease of the sacrococcygeal region. Treatment varies according to the clinical presentation of the disease. Although many surgical methods have proposed, the ideal approach is still lacking due to high recurrence rates. This study aimed to evaluate the role of Z-plasty in achieving primary recovery in pilonidal disease and morbidity and recurrence. Twenty-four patients (15 males and nine females) who underwent sinus excision and Z-plasty closure for the sacrococcygeal pilonidal sinus included in this study. Follow-up ranged from 6 to 12 months. There were 15 males and nine females with a median age of 16 years. The mean hospital stay was two days. There was no recurrence, and all patients were satisfied with the cosmetics. Two patients (5%) had numbness on the flap. No flap necrosis observed in any patient. Only three patients had a wound infection (7.5%). Wound seroma developed in five patients (12.5%). Although some technical expertise is required, excision of sinus and Z-plasty provides superior results in terms of recurrence and hospitalization of pilonidal sinus patients during hospitalization.

**Keywords:** pilonidal sinus; sacrococcygeal region; Z-plasty; seroma

### INTRODUCTION

Pilonidal sinus disease is a common problem, but treatment is often inadequate<sup>1</sup>. According to Monro and McDermott<sup>2,3</sup>, the factors responsible for the development of pilonidal sinus appear to be deep labor cleft in most patients with the presence of a large number of hairs surrounding the surrounding areas. Depth. Various case reports, II. In World War II, he described the formation of pilonidal cysts in jeep drivers. Many soldiers were affected by a pilonidal disease called "jeep disease. These findings led to the belief that pilonidal cysts could be acquired by excessive repetitive trauma to the sacrococcygeal site<sup>4</sup>. Management has been controversial for more than 100 years, and many reports<sup>5,6</sup> advocate a variety of different approaches. In this study, the results of the Z-plasty procedure were evaluated for the elimination of the disease, since it did not fulfill any methods necessary for ideal treatment. Z-plasty is a plastic surgery technique used to improve the functional and cosmetic appearance of scars. It involves the creation of two triangular flaps of equal dimensions that then transposed. For a basic z-plasty, the triangular flaps created using an angle of 60 degrees. Theoretically, this angle can lengthen a contracted scar by about 75 percent and reorient the direction of

the central wound by 90 degrees. In practice, the lengthening and reorientation will be less, owing to increased wound tension<sup>7</sup> (Figure 1).

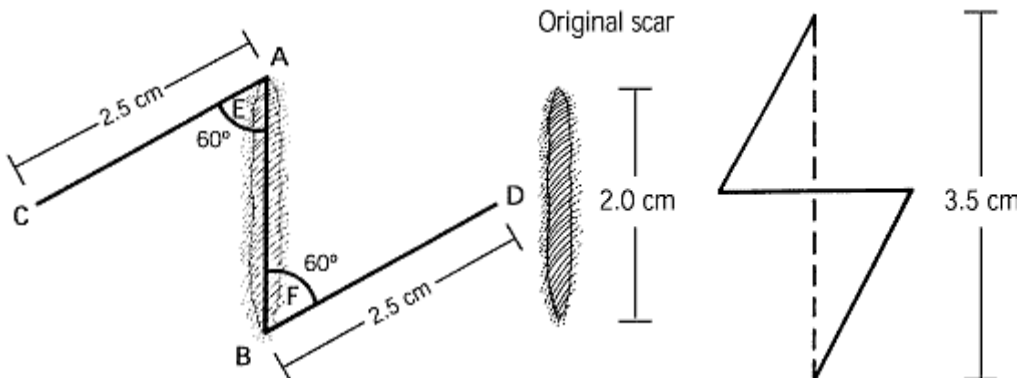


Figure 1 :The Basic Z-plasty Technique.

## MATERIALS AND METHODS

This research was a two-year study conducted between June 2016 and April 2018. The population consisted of 24 patients (15 males and nine females, median age 16 (14-17 years)) with pilonidal sinus disease. An approval no. 2019-91 dated 26.09.2019 obtained from the SBÜ Kocaeli Derince Training and Research Hospital Ethics Committee for this retrospective study. The patients were accepted one day before the operation, and laboratory tests take. They bathed the night before surgery, and the surgical area shaved carefully. On the morning of surgery, patients were transferred to the operating room and given spinal anesthesia. The anesthetized patient placed on two rolls (one under the chest and the other under the pelvis) in a prone position. The patient's head placed on a 45° lateral angle roll. The operation area was draped and prepared with Betadine (Figure 2).

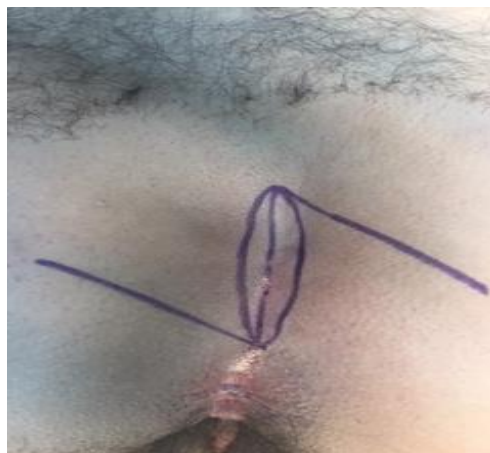

Figure 2 : Z plasty Incision

The scars excised with a narrow elliptical skin. The incision then deepened to remove the entire birth raphe and reach the aponeurosis on the erector spinal behind

the sacrum. If there was any deep granulation tissue area, it excised after removing the sinus canal. The length of the primary wound was 2-6 cm. The limbs of Z cut to form an angle of 60° with the long axis of the injury. The length of each leg was equal to the length of the primary wound. The wings then transferred without stretching (Figure 3).

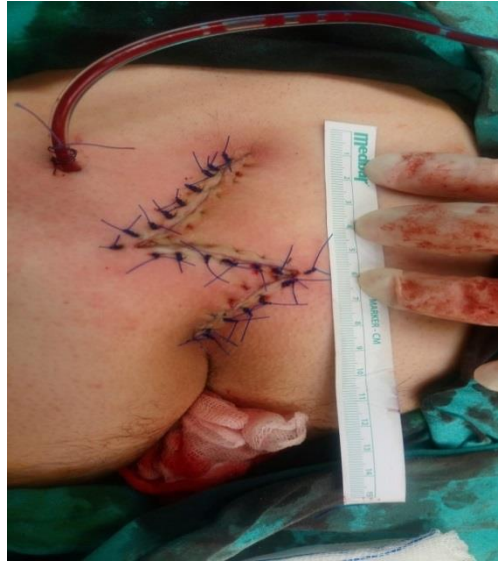

Figure 3: Z plasty Incision Line After an Operation

Transposition flaps were then approached and sutured with 3/0 nylon for subcutaneous and 3/0 nylon for skin closure. Simple suction drainage from the stab wound used. The wound then covered with a dressing cloth.

## RESULT AND DISCUSSION

There were 15 males and nine females (ages 14-17) with a median age of 16 to 15 years. The mean hospital stay was two days (1-5 days). Postoperative morbidity included superficial wound infection in two patients (8.3%) managed by skin suture removal, regular saline dressing, and secondary intent healing. The dissolution of this infectious process resulted in shell formation. Two patients (8.3%) had numbness on the flap. No flap necrosis observed in any patient. There was no recurrence, and all patients were satisfied with the cosmesis (Figure 4).

Sacroccygeal pilonidal sinus has been surgically managed for many years, but the ideal surgical technique remains controversial. Pilonidal disease is a painful condition that usually occurs in the intergluteal region. It is a problem full of controversial issues, including who first described the disease, etiology, and optimal treatment<sup>8</sup>. The situation was probably first described by Mayo in 1833<sup>9</sup>. In 1880, Hodges first used the term "pilonidal"; it means hair, which means Latin, and nidus, meaning nest<sup>10</sup>. Z-plastic increases the transverse length by taking lateral tissue and thus obliterates the birth cleft, the leading cause of pilonidal sinus formation<sup>8</sup>. Z-plasty has three primary uses. It increases the length of the skin in the desired direction, changes the scar direction so that it stays in the same direction as the skin lines and rotates the axis of tissue in the Z-plasty flaps<sup>11</sup>. Dickson<sup>11</sup> used this technique in 120 patients. Complications included

three abscesses and two hematomas. There were only two relapses (1.6%) at 1 to 9 years follow-up.

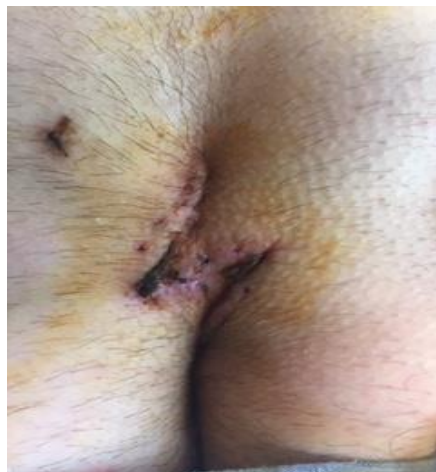

Figure 4: Cosmetic Result After The Operation

The discharge was the first post-operative day, and the patients returned to work two weeks later. Toubanakis<sup>12</sup> used this procedure in 110 patients. There was no recurrence at 1-10 years follow-up. Bose et al.<sup>13</sup> found 20% necrosis and 10% wound infection, and one patient had a post-Z-plasty hematoma. Hodgson et al.<sup>14</sup> compared incision with Z-plasty and externalization with drainage or excision in pilonidal sinuses. They showed that traditional surgical approaches resulted in high recurrence rates. They found that no other surgical treatment was necessary for the Z-plasty group. Behdad et al.<sup>15</sup> reported a 12%, 3.3%, and 3.6% incidence of seroma, infection, and relapse after Z-plasty, respectively.

Our study demonstrates that the cosmetic evaluation, post-operative midline incision length increase, complication, and recurrence rates of ZP. It identified that the ZP group had a lower aesthetic evaluation, midline incision length increase, complexity, and recurrence rates. While two (8.3 %) of the 24 patients that had undergone ZP surgery developed wound site infection and two other patients (8.3 %) developed a hematoma, no recurrence observed in the ZP group throughout the follow-up period. The results of the ZP patients were similar to those found in the literature. Praveen et al. where Z-plasty technique was employed noted 5% recurrence and Tolba et al. noted recurrence in one patient when open technique was employed<sup>16</sup>.

## CONCLUSION

Compared to the previous case series, ours showed an improved outcome in terms of recurrence, cosmic, and overall length of stay. Z-plasty is, therefore, effective treatment for pilonidal sinus disease, which provides faster healing and better aesthetic results.

## CONFLICT OF INTEREST

There were no conflicts of interest with related parties in this study.

**REFERENCES**

1. Mueller X, Rothenbuchler JM. Sacrococcygeal cysts. *J Chir Paris*. 1991;128:487–490
2. FuzunM, Bakir H. Which technique for treatment of pilonidal sinus-open or closed? *Dis Colon Rectum*. 1994;37:1148–1150
3. Monro R, McDermott F. The elimination of causal factors in pilonidal sinus treatment by Z-plasty. *Br J Surg*. 1965;52: 177–181
4. Karydakis GE. New approach to the problem of pilonidal sinus. *Lancet*. 1973;103:1414–15
5. Price ML, GriffithsW. Normal body hair: A review. *Clin Exp Dermatol*. 1985;10:87–97
6. Senapati A, Cripps NP, Thompson NR. Bascom's operation in the day-surgical management of symptomatic pilonidal sinus. *Br J Surg*. 2000;87:1067–76
7. Burke M. Z-plasty. How, when and why. *Aust Fam Physician*. 1997; 26:1027–1029
8. Hull TL. *J Wu Surg Clin N Am*. 2002;82: 1169–1185
9. Mayo OH. Observations on injuries and diseases of the rectum. London; Burgess and Hill: 1833, pp 45–46
10. Hodges RM. Pilo-nidal sinus. *Boston Med Surg J*. 1880;103:485–486
11. Mansoor A, Dickson D. Z-plasty for treatment of disease of the pilonidal sinus. *Surg Gynecol Obstet*. 1982;155:409–411
12. Toubanakis G. Treatment of pilonidal sinus disease with Z-plasty procedure (modified). *Am Surg*. 1986;52:611–612
13. Bose B, Candy J. Radical cure of pilonidal sinus by Z-plasty. *Am J Surg*. 1970; 120:783-786
14. HodgsonWY, Greenstein RJ. A comparative study between Z-plasty and incision and drainage or excision with marsupialization for pilonidal sinuses. *Surg Gynecol Obstet*. 1981;153:842–844
15. Behdad A, Hosseinpour M. Z-plasty for the treatment of residual cavity after pilonidal sinus excision. *MJIRL*. 2000;14:317–319
16. Tolba AM, El-Wahsh M, Abd-Elpaset A.,A prospective randomized study comparing open technique with closed technique using different type of flap coverage in chronic pilonidal disease. *ZUMJ*. 2012;18:527-530.