

Circumcision With Plastic Clamb In Newborn Infants

Yusuf Atakan Baltrak

KocaeliDerince Education and Research Hospital

Department of Pediatric Surgery. Turkey

Email: dratakanbaltrak@gmail.com

Abstract: Various devices were used to carry circumcision operation out. It noted that these devices, especially the Plastic Clamp method, significantly decrease complications as long as basic surgical rules, are followed. This study aims to examine the application of Plastic Clamp circumcision in infants. Children whose physical examinations revealed circumcision contradictions excluded from the study. During the study period, a total of 485 children was circumcised using the plastic clamp method under sedated anesthesia and by a single pediatric surgeon. Measurements take before operations and plastic clamps with diameters ranging from 1.2 to 1.6 cm used. The duration of the surgical procedure, early and late period post-operative complications, the separation duration of the plastic clamp, and problems evaluated. Study Results, the average length of the surgical operation was determined to be 5.5 minutes. The average hospital stay duration of the patients was 2 hours. During the follow-ups, edemas were observed in mucosal areas of 24 (4.9%) patients, 48 hours after the clamp placed and edema and swelling recovered seven days after the circumcision at the latest. On average, it observed that plastic clamp separated on its own in 7.1 days. It noted that in 4 (0.8%) patients, the plastic clamp separated prematurely during 6 hours following the operation due to pulling. Conclusion study plastic Clamp (Alisklamp) is starting to gain popularity because it falls off on its own and that it can be applied quickly under local anesthesia

Keywords: circumcision; newborn; plastic clamp.

INTRODUCTION

Circumcision is one of the oldest, most common, and most controversial surgical procedures around the world¹. Its origins filled with mystery as it believed that it has emerged in Ancient Egypt more than 15.000 years ago and spread among world cultures with prehistoric migrations. It thought that the operation of circumcision is so widespread due to medical, religious, and cultural reasons². Egyptian mummies and reliefs demonstrate to us that the first circumcision was carried out at least 6000 years ago³. Circumcision is a religious ritual for Muslims and Jews. Ritual circumcision has practiced in the Middle East for more than 3000 years. Later, in the 19th Century, this old ritual was transformed into a medical procedure, and it was applied using various devices. The ratio of complications recorded in some studies after applying Plastic Clamp ranged from 2.0 to 3.0%⁴.

In this study, we have evaluated, through various parameters, the method and results of the plastic clamp, which aims to shorten the duration of the circumcision operation and create more aesthetically pleasing results, in newborn infants.

MATERIALS AND METHODS

The approval took for the study from the hospital's ethical committee dated and numbered 12.08.2018/6021134. The survey carried out according to the Helsinki declaration. Healthy male newborn children with no clinical symptoms included in the research. Before the operation, approval forms were signed by the parents after they were informed about the method to be applied and possible complications.

Children whose physical examinations revealed circumcision contradictions such as hypospadias, ventral cord, and buried penis, patients under 3 kilograms. And children who have undergone circumcision with methods other than plastic clamp excluded from the study. During the study period, a total of 485 children was circumcised under sedated anesthesia by a single pediatric surgeon using the plastic clamp method. Measurements take before operations and plastic clamps with diameters ranging from 1.2 to 1.6 cm used. Cream with 5% Prilocaine and Lidocaine HCL applied to the preputium skins of all patients 1 hour before the operation. Simultaneously, suppositories comprised of 120 mg paracetamol used rectally.

The operation was carried out under penile block, which was formed around the penis using one cc 2% lidocaine and bupivacaine solution applied with a 21G insulin injector. The patients were fed immediately after the operation. Following approximately 2 hours of observation, the patients discharged. After the discharge, suppository paracetamol and 0.2% nitrofurazone to be applied around the plastic clamp at home prescribed to the patients. Sitting bath, used twice a day at home for 20 minutes, was also a recommendation. Four days after the application of plastic clamp, the patients called for a follow-up to remove the outer ring of the clamp. The internal apparatus of the plastic clamp was expected to fall off on its own. 2 weeks after the operation, the patients examined for a second time.

Circumcision Method

After achieving local anesthesia and penile block, preputium was retracted from the surface of the gland and dissected until the coronal sulcus of the organ was visible (Figure 1a,1b). Following this, epithelial residues and debris (smegma) cleaned from the area (Figure 1c). After covering the cleaned area, a plastic clamp case that is suitable with the size of the gland was selected using clamp's scale, and it was placed upon the gland while preputium was retracted to protect it (Figure 2a,2b). After this, retracted preputium pulled over the plastic clamp case. Following this, the clipping element of the clamp was used to stabilize the skin. Then, using the number 15 scalpel, preputium was excised and separated from the penis (Figure 3). Later, the patient discharged while the plastic clamp was still on the penis. The final status was examined on the follow-up call performed four days after the operation (Figure 4).

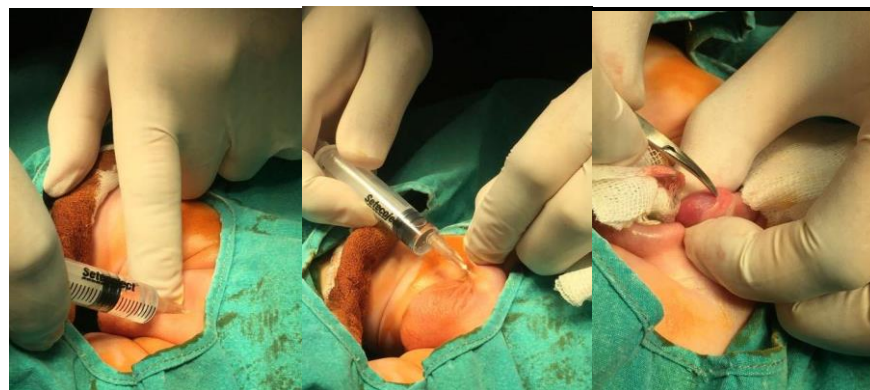


Figure 1a Figure 1b Figure 1c

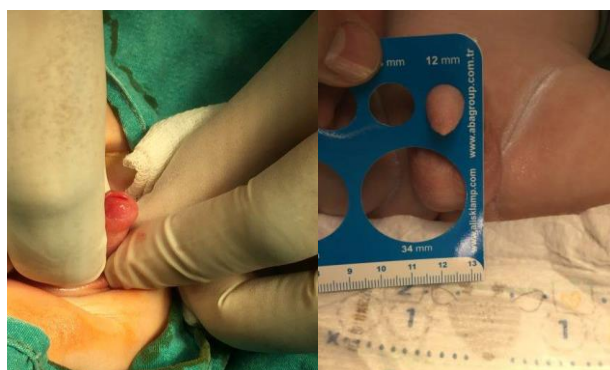


Figure 2a Figure 2b

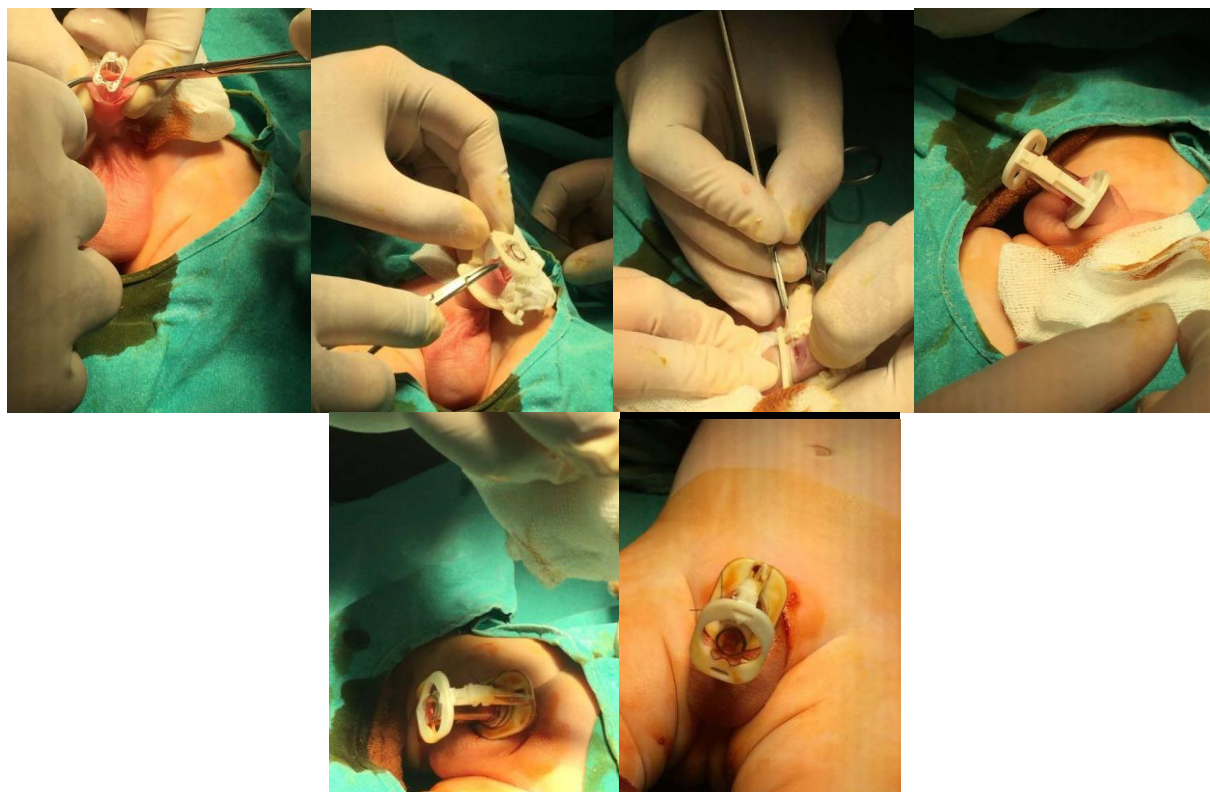


Figure 3

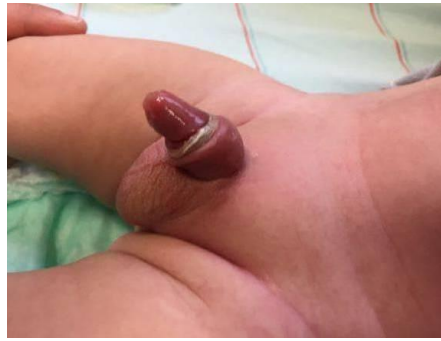

Figure 4

RESULTS AND DISCUSSION

Four hundred eighty-five healthy male children under 30 days of age included in the study. Laboratory examinations were carried out on all patients before the operation, and findings were in normal limits in regards to their age limits. The recorded local anesthesia application for circumcision was 4 minutes at a minimum and 9 minutes at maximum. The average duration of the surgical operation was determined to be 5.5 minutes. The average hospital stay duration of the patients was 2 hours. Vital signs of the patients were stable during their observation in the hospital, and none needed additional analgesic medicine. Patients who were fed, observed to have no problems, and have urinated were discharged 2 hours after their operation, and some recommendations made during the process.

During the follow-ups, edemas observed in mucosal areas of 24 (4.9%) patients 48 hours after the clamp placed and edema and swelling recovered seven days after the circumcision at the latest. On average, it observed that plastic clamp separated on its own in 7.1 days. It noted that in 4 (0.8%) patients, the plastic clamp separated prematurely during 6 hours following the operation due to pulling. After bleeding control established on patients whose plastic clamps separated due to stretching, the first restoration was carried out. It noted that mucosa and skin incisions of patients whose plastic clamps separated prematurely were proper and sufficient.

There were 12 (2.4%) complaints of bleeding which had occurred in the first 24 hours after plastic clamp component removed during the first follow-up on the 4th day after the circumcision. 2 of the 12 patients, who had applied with the complaint of bleeding, were applied separate surgical operations under local anesthesia to control the bleeding. The bleedings of the other ten patients stopped by using medical dressing. The mucosal stricture detected in seven (6.1%) patients and inadequate circumcisions performed on patients. When steroid cream applied to seven patients who had developed mucosal stricture, it noted that the condition of 5 of these patients had recessed and revisions were applied to the other two patients using the classical dorsal slit method due to mucosal stricture. Circumcisions of the two patients, who had undergone inadequate circumcisions were revised.

Circumcision is perhaps the most common and most neglected pediatric surgical procedure. This situation has caused circumcision to be carried out by any qualified or unqualified medical personnel and using a wide variety of technical approaches. Since 1935, 11 different devices explicitly designed for circumcision, and the techniques

regarding circumcision developed alongside these devices⁵. Among these techniques, Plastic Clamp technique is thought to be the most suitable, especially for infants⁶. Circumcision generally regarded as a procedure which can accomplish without knowing the basic surgical principles. This situation has resulted in many deaths and long-term complications^{7,8}. Many infants lost to sepsis due to unsuitable conditions and techniques⁷. Cosmetically, the plastic clamp method provides excellent results; however, if the proper technique is not employed, complications may emerge⁸. This method may be preferable as the foreskin is thinner during infancy, and it can be excised relatively easily, both factors leading to a smaller amount of complications.

Application of the circumcision procedure at a younger age is always the better option. It is possible to use bipolar diathermy for circumcision; however, due to the gangrene prevalence of penis stated in the literature, it is not used under any circumstances⁹. The duration after which the Plastic Clamp separates on its own is also not examined in any researches. The period which was necessary for Plastic Clamp to fall off on its own in a newborn infant was on average 6.7 days in this study, and this compared to a study which has determined that bell separation occurs in 10 days¹⁰.

In comparison to the 2.4% of complication rate stated in 205 studies on newborn babies, this study has recorded a 7.4% total complication rate. Similarly, in another study which focused on 386 infants, a 3% rate of minor and recoverable complications were reported¹¹. It believed that Plastic Clamp caused edema is the second most common complication, the first being the complications caused by the circumcision operation itself^{12,13}. It thought that this might cause by the selection of improperly sized Plastic Clamps and over-tightening of the skin to circumcised. Edema and swelling caused by Plastic Clamp was the most common complication observed in this study, and its rate in infants was 4.9%. Some international and local studies regarding newborn infants have stated this rate as between 2.6% to 7.08%^{14,15,16,17}.

This rate was 4.9% in our research. It stated that this effect is more common in circumcisions made on children of older age groups. Another study has noted that temporary edema and swelling seen with the Plastic Clamp is not as common in children older than one year in comparison to children who are younger than one year. Another common complication with Plastic Clamp circumcision is bleeding¹⁸. Urinary retention with this device reported in infection and sepsis literature in low percentages^{19,20}.

Application of Plastic Clamp to the circumcision of older age groups is a controversial issue. The discussion regarding this issue is ongoing due to temporary edema and swelling that occurs after the application of the Plastic Clamp and bleeding that happens after the Clamp removed. However, these issues can disregard as they are temporary, and they are not long-term complications.

CONCLUSION

Early application for circumcision should be encouraged. This allows the operation to be carried out under anesthesia, which will shorten its duration and decrease the number of complications. Plastic Clamp is starting to gain popularity because it falls off on its own and that it can be applied quickly under local anesthesia.

Considering its lack of long-term complications, applicability under local anesthesia and its ease of application, this procedure is recommendable for all children, who are under one year old. However, its use for older children is debatable.

REFERENCES

1. Alanis, M.C., Lucidi, R.S. (2004). Neonatal circumcision: a review of the world's oldest and most controversial operation. *ObstetGynecolSurv.* 2004(59):379-395.
2. Dunsmuir, W.D., Gordon, E.M. (1999). The history of circumcision. *BJU Int*, 1999(83), 1-12
3. Rizvi, S.A.H., Naqvi, S.A.A., Hussain, M., Hasan, A.S. (1993). Religious circumcision: a Muslim view. *BJU Int*, 1993(83),13-16.
4. ManjiK.P. (2000). Circumcision of the young infant in a developing country using the Plastibell™. *Ann Trop Paediatr*, 20(2),101-104
5. Grossman, E., Posner, N.A. (1981). Surgical circumcision of neonates: a history of its development. *ObstetGynecol*, 52(6), 241-6.
6. Elder, J.S. (2007). Circumcision. *BJU Int*. 2007, (99), 1553-64.
7. Suleman, O. (1982). Mortality from tetanus neonatorum in Punjab (Pakistan). *Pak Pediatr J*, 6(2-3), 152-83.
8. Ozdemir, E. (1997). Significantly increased complication risks with mass circumcisions. *Br J Urol*, 80(9), 136-9.
9. Gearhart, J.P., Rock, J.A. (1989). Total ablation of the penis after circumcision with electrocautery: a method of management and long term follow up. *J Urol*, 1989(142), 799-801.
10. Duncan, N.D., Dundas, S.E., Brown, B., Pinnock-Ramsaran, C., Badal, G. (2004). Newborn circumcision using the PlastikKlembll device: an audit of practice. *West Indian Med J*, 53(6), 23.
11. Manji, K.P. (2000). Circumcision of the young infant in a developing country using the PlastikKlembll. *Ann Trop Paediatr*, 20(4), 101.
12. Clinto, B.G., Homes, N.M., Canning, D.A. (1999). PlastikKlembll complications revisited. *ClinPediatr*, 38(42), 239.
13. Mihssin, N., Moorthy, K., Houghton, P.W.J. (1999). Retention of urine: an unusual complication of the PlastikKlembll device. *BJU Int*, 1999(84), 745.
14. Shah, T., Raistrick, J., Taylor, I., Young, M., Menebhi, D., Stevens, R.A.(1999). Circumcision service for religious reasons. *BJU Int*, 83(9), 807.
15. Palit, V., Menebhi, D.K., Taylor, I., Young, M., Elmasry, Y., Shah, T.A.(2007). Unique service in UK delivering PlastikKlembll circumcision: review of 9-year results. *PediatrSurgInt*, 23(8), 45.
16. Jan IA. (2004). Circumcision in babies and children with PlastikKlembll technique: an easy procedure with minimal complications e experience of 316 cases. *Pak J Med Sci*, 2004(20), 175e80.
17. Mousavi, S.A., Salehifar, E. (2008). Circumcision complications associated with the PlastikKlembll device and conventional dissection surgery: a trial of 586 infants of ages up to 12 months. *AdvUrol*, 2008, 606123.
18. Lazarus, J., Alexander, A., Rode,H. (2007). Circumcision complications associated with the Plastibell device SAMJ. *S Afr Med J*, 97(3), 192

19. Gee, W.F., Ansell, J.S. (1976). Neonatal circumcision: a ten-year overview with comparison of the Gomco clamp and the PlastikKlembll device. *Pediatrics*, 58(7), 824.
20. Kirkpatrick, B.V., Eitzman, D.V. (1974). Neonatal septicemia after circumcision. *ClinPediatr*, 13(8), 767.