

**PHOTOGRAPHIC ASSESSMENT OF SMILES:  
PRE AND POST-ORTHODONTIC TREATMENT  
(PENILAIAN FOTOGRAFI SENYUMAN: PERAWATAN PRA  
DAN PASCA-ORTODONTIK)**

*Jhds.fkg.unjani.ac.id*  
*DOI:10.54052/jhds.v1n1.p1-10*

**Article History**

*Received: 01/02/2021*  
*Accepted: 01/03/2021*

Noviaranny IY<sup>1,2\*</sup>, Ramlan H<sup>1,2</sup>, Mat Saad J<sup>1</sup>

<sup>1</sup>Faculty of Dentistry, Universiti Teknologi MARA (UiTM) Malaysia

<sup>2</sup>Centre of Paediatric Dentistry & Orthodontics Studies, Faculty of Dentistry, Universiti Teknologi MARA(UiTM) Malaysia

\*Corresponding author

[indahyuri@uitm.edu.my](mailto:indahyuri@uitm.edu.my)

**ABSTRACT**

This study aims for the smile assessment and comparison between pre and post-orthodontic treatment to induce patients' interest and awareness towards orthodontic treatment. Orthodontists are in benefit from improving the treatment plan. Methods research were photographs of 59 subjects taken from postgraduate students in an orthodontic clinic using a standardised technique. Patients' smile will be evaluated, including the smile line, midline of the dental arch and relationship of the smile arch to the lower lip curvature, by observing the patients' frontal smile photographs. The smile lines are classified into four types, with type three (average smile line: gingival embrasures only visible) is the most desirable smile. The results showed that for patients' smile line, the total number of patients that have achieved Type 3 post orthodontic treatment is 40.4%. As for the relationship of the smile arch to the lower lip curvature, 96.6% of the patients had their maxillary incisor edges in light contact or slightly apart from the lower lip. 61% of subjects showed no deviation from the midline. Based on the survey conducted regarding patients' perception of the smile, most patients preferred the type three smile line, 86% rather than type 2 (10%), type 4 (4%), and none on type 1. Regardless of the age group and gender, type 3 is the most preferable among the participants. It can be concluded that orthodontic treatment can improve patients' appearance and impact the smile aesthetically, thus aiding orthodontists to achieve

a comprehensive treatment plan to enhance the smile aesthetic, patient's compliance, and motivation towards treatment.

**Keywords:** smile assessment; orthodontic treatment

### **ABSTRAK**

Tujuan penelitian adalah untuk penilaian senyum dan perbandingan antara perawatan sebelum dan sesudah perawatan ortodontik akan membangkitkan minat dan kesadaran pasien terhadap perawatan ortodontik. Ortodontis mendapatkan keuntungan dalam meningkatkan rencana perawatan. Metode penelitian yaitu Foto dari 59 subjek diambil dari mahasiswa profesi di klinik ortodontik dengan menggunakan teknik standar. Senyuman pasien akan dievaluasi termasuk garis senyum, garis tengah lengkung gigi dan hubungan lengkung senyum dengan kelengkungan bibir bawah dengan mengamati foto senyum frontal pasien. Garis senyum diklasifikasikan menjadi 4 jenis, dengan tipe 3 (garis senyum rata-rata: hanya cengkeraman gingiva yang terlihat) adalah senyuman yang paling diinginkan. Hasil penelitian menunjukkan garis senyum pasien, jumlah total pasien yang telah mencapai perawatan pasca ortodontik tipe 3 adalah 40,4%. Hubungan lengkung senyum dengan kelengkungan bibir bawah, 96,6% pasien memiliki tepi gigi seri rahang atas dalam kontak ringan atau sedikit terpisah dengan bibir bawah. 61% subjek tidak menunjukkan deviasi dari garis tengah. Berdasarkan survey yang dilakukan mengenai persepsi pasien terhadap senyuman, sebagian besar pasien lebih menyukai garis senyum tipe 3 yaitu 86,0% dibandingkan tipe 2 (10,0%), tipe 4 (4,0%) dan tidak ada pada tipe 1. Terlepas dari kelompok umur dan jenis kelamin, tipe 3 adalah yang paling disukai di antara peserta. Kesimpulan adalah perawatan ortodontik dapat memperbaiki penampilan pasien dan berdampak pada estetika senyuman, sehingga akan membantu ortodontis untuk mencapai rencana perawatan yang komprehensif untuk meningkatkan estetika senyuman, kepatuhan pasien dan motivasi terhadap perawatan.

**Kata kunci:** penilaian senyum; perawatan ortodontik

## INTRODUCTION

The objective of orthodontic treatment is to improve aesthetic function and stability. A smile plays a big role in aesthetic. After all, the smile's beauty will make the difference between an acceptable or pleasing aesthetic result for any given treatment.<sup>1</sup> Most of the patients' demands on orthodontic treatment increases from physiologically and mechanically sound to aesthetically pleasing smile.<sup>2</sup> Generally, the smile assessment is evaluated by the relationship of the smile arch to the upper border of the lower lip, the midline of the dental arch and the amount of visible gingiva during the smile. The smile lines were analysed using the classification used by Liebert et al.<sup>4</sup>

The changes between pre-and post-orthodontic treatment were analysed by the components of smile assessment which include the smile lines standardised by Liebert et al., the relationship of the smile arch to the upper border of the lower lip, the midline of the dental arch. Guzmán M.M et al. considered a smile without midline deviation as a very aesthetic smile. However, specialists' dentists thought an aesthetic smile for gingival exposure was 0mm (Type 3) gingival exposure. At the same time, patients preferred it to be 2mm of marginal and attached gingiva visible (Type 2). In this study, dental specialists' opinion is selected due to the higher percentage of specialists' preferred Type three smile (59.7%) than patients' preferred Type two smile (37.1%).<sup>11</sup>

According to Priya K. et al., the patients whose lower lips touched or did not touch the incisal edges had a higher aesthetic score than those whose incisal edges were slightly covered. This study aims to assess and compare pre and post-orthodontic treatment to induce patients' interest and awareness of orthodontic treatment.

## METHOD

The samples consist of 59 patients were obtained and collected from the Orthodontic Postgraduate Clinic in Faculty of Dentistry, UiTM Malaysia. The inclusion criteria for this study are based on the following: patient with permanent dentition, complete set of orthodontic records, wearing fixed orthodontic appliances, orthodontically recruited as a patient since 2013. The exclusion criteria for this study are based on the following: wearing prosthesis, poor periodontal health, poor quality of frontal smile photograph. The following criteria will be documented: Gender (male & female), Age. [Classification by Erik Erikson's (1959) theory of psychosocial development]; Adolescent: 12–18 years old; Young Adult: 18–35 years old; Middle-aged Adult: 35–55 years old. Extraoral photograph - smile frontal photograph of patients for both pre-and post-fixed orthodontic treatment.

The photograph taken by postgraduate students has a standardised technique which includes a natural head position where Frankfurt horizontal plane is parallel to the floor. (Sreesan,

2016). Guidelines in taking patients' extraoral photograph according to Sreesan N. S. et al.<sup>5</sup>:

#### Positioning of patient

Both patient and the clinician need to be positioned correctly in a standardised manner. If there is a height difference between the patient and the clinician, the platform can raise them to the appropriate camera level in the face's middle. In extra-oral photography, an attempt should be made to focus on the patient's lower eyelid to ensure that the tip of the nose to ear falls within the depth of field.

#### Frontal View

Portrait view with the frame extending to just above the top of the head and lower frame line around the larynx. The photograph should be symmetrical with the interpupillary line parallel to the floor. A focusing screen with the grid is very useful. The patient is in a natural head position and looks straight ahead into the camera. The camera position is in the middle of the face and portrait format.

Space should be left on all sides of the photograph. The light should come diagonally from the front, leaving the patient shadow out of view of the camera. The frontal smile photograph then cropped and monochromatised to be analysed.

#### Frontal Dynamic Smile

The smiling picture demonstrates the amount of incisor smile (percentage of maxillary incisor display on smile) as well as excessive gingival display.

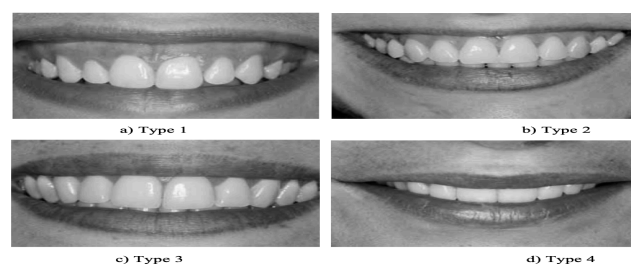#### Extra- Oral Photographs

JHDS 2021

As for the American Board of Orthodontics, quality, standardised facial photographs are either in black and white or colour. Patient head oriented accurately in Frankfort horizontal plane. One anterior view, smiling. Background free of distractions. Quality lighting revealing no shadows in the background. Ear exposed for orientation. Eyes open and looking straight ahead, glasses removed.

The frontal smile photographs of patients were taken during pre and also post orthodontic treatment. The photographs taken were cropped only to include the upper and lower lip, lateral commissures of the mouth, the teeth, gingiva, and the upper lip's philtrum. Camera specifications: Model name: Canon EOS70D, Lens model: EF 100 mm f/2.8L Macro IS USM, Flash model: Canon Macro Ring Lite MR-14EX Flash

The smile lines were analysed using the classification used by Liebert et al.<sup>4</sup> (Figure 1) :



**Figure 1.** Classification of smile line by Liebert et al.

**Type 1** - Very high smile line

2 mm or more of marginal and attached gingiva visible or more than 2 mm of root or gingiva apical to the cement to enamel junction visible for the healthy but reduced periodontium. This smile is classified as a "gummy smile".

**Type 2** - High smile line

Between 0 and 2 mm of marginal and attached gingiva visible or between 0 and 2 mm visibility of root and gingiva apical to the cement to-enamel junction visible for the reduced and healthy periodontium.

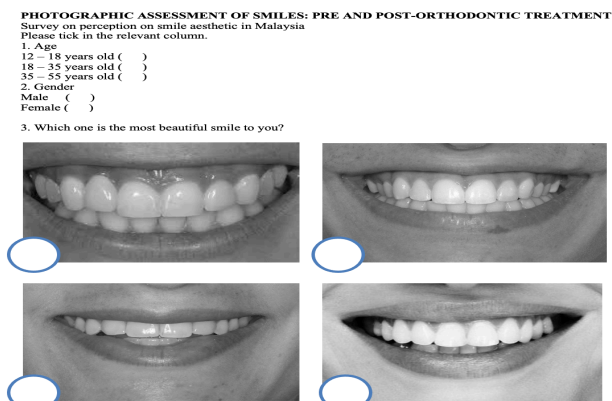
**Type 3 - Average smile line**

Gingival embrasures only visible.

**Type 4 - Low smile line**

Gingival embrasure and cemento-enamel junction not visible.

The patients' smile perception questionnaire was distributed randomly to the patients in UiTM Dental Centre with age ranging from 12 to 55 years old (Figure 2).

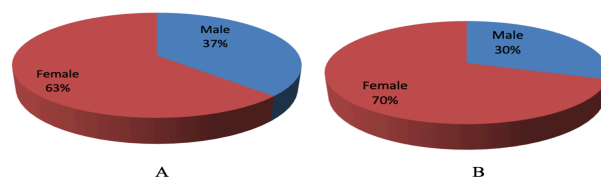


**Figure 2.** Sample of a survey on perception on smile aesthetic among patients.

**RESULT**

The sample consisted of 59 subjects, of which 22 were males, and 37 were females (Figure 3.a). The age of the subjects ranged from 15 years old to 32 years old. As for the survey on patients' perception of the smile, the participants composed of 15 males and 35 females (Figure 3.b) that split into adolescent (12–18 years old), young adult (18–

35 years old) and middle-aged adult (35–55 years old).



**Figure 3.** A. Pie chart showing gender distribution of samples. B. Pie chart showing gender distribution for the survey on patients' perception of smile

Smile line

During pre-orthodontic treatment, most patients have a Type 3 smile line, which is 30.5%, and the least is 1.7% with Type 1 smile line. Meanwhile, 20.3% and 47.5% are having Type 2 and Type 4, respectively. As for post orthodontic treatment, Type 3 also has the highest percentage, 42.4% and Type 1 is the least, 10.2%. As for the Type 2 and Type 4 smile line, the rates of each type are 25.4% and 22.0%. For patients that have Type 1 smile line, all of the patients are still sustained Type 1, and none of them is changing into Type 2, 3 or 4. As for patients with the Type 2 smile line are retained to Type 2, 58.3%. The patients' Type 2 to Type 1 were the same as those who changed to Type 3, 16.7%. Concurrently, 8.3% of the patients are switching to Type 4 after the orthodontic treatment. Of the total patients that have Type 3 smile line, most of them are unaffected after the orthodontic treatment, which is 66.7%, while 11.1% are transformed into Type 1 smile line. In addition, 16.7% of them are altered into Type 2 smile line along with 5.6% that have converted into Type 4 smile

line. Concerning patients with Type 4 smile line, the percentages of patients that have either modified into Type 3 or remain fixed with Type 4 smile line are equal which both of them are 39.3%. For patients that have replaced with Type 1, the percentages are 3.6%, and 17.9% are replaced with Type 4 smile line (Table 1)

**Table 1.** Smile line pre- and post-cross tabulation

			Smile Line (Post)				Total
			Type 1	Type 2	Type 3	Type 4	
Smile Line (Pre)	Type 1	Count	1	0	0	0	1
		Percentage	100.0%	0.0%	0.0%	0.0%	100.0%
	Type 2	Count	2	7	2	1	12
		Percentage	16.7%	58.3%	16.7%	8.3%	100.0%
	Type 3	Count	2	3	12	1	18
		Percentage	11.1%	16.7%	66.7%	5.6%	100.0%
	Type 4	Count	1	5	11	11	28
		Percentage	3.6%	17.9%	39.3%	39.3%	100.0%
	Total	Count	6	15	25	13	59
		Percentage	10.2%	25.4%	42.4%	22.0%	100.0%

Respecting the preferable smile line, which is Type 3, 52.5% are still preserved their smile line regardless of which type and 10.2% worsen after the treatment. However, 22 % showed improvement after the orthodontic treatment, and 15.3% undergo changes in their smile line after the treatment but did not achieve the preferable smile.

**Relationship of the Smile Arch to the Lower Lip Curvature**

94.9 % of the patients had their maxillary incisor edges in light contact during pre-orthodontic treatment or slightly apart with the lower lip. In JHDS 2021

comparison, 5.1% had the lower lip slightly covers their maxillary incisor edges. Also, during post-orthodontic treatment, most of the patients (96.6%) had their maxillary incisor edges in light contact or slightly apart with lower lip, with the remaining 3.4% had the maxillary incisor edges slightly covered lower lip No significant difference can be found between the two genders. 1.7% of the patients have improved from their maxillary incisor edges are slightly covered by lower lip to their maxillary incisor edges in light contact or slightly apart from the lower lip. Most of the patients (98.3%) have no changes regarding their relationship of the smile arch to the lower lip curvature from pre to post-orthodontic treatment. None of the patients has their condition worsen from maxillary incisor edges in light contact or slightly apart with lower lip to maxillary incisor edges are slightly covered by lower lip after orthodontic treatment. (Table 2)

**Table 2.** Relationship of the smile arch to the lower lip curvature pre and post-cross-tabulation

			Relationship of the smile arch to the lower lip curvature (Post)		Total
			Yes	No	
Relationship of the smile arch to the lower lip curvature (Pre)	Yes	Count	56	0	56
		Percentage	100.0%	0.0%	100.0%
	No	Count	1	2	56
		Percentage	33.3%	66.7%	100.0%
	Total	Count	57	2	59
		Percentage	96.6%	3.4%	100.0%

The midline of the Dental Arch

During pre-orthodontic treatment, 30.5% of the patients have no deviation of the midline, with the remaining 69.5% have a deviation of the midline either left or right. 61.0% of the patients showed no deviation from the midline, while 39 % showed a midline either left or right post-orthodontic treatment.

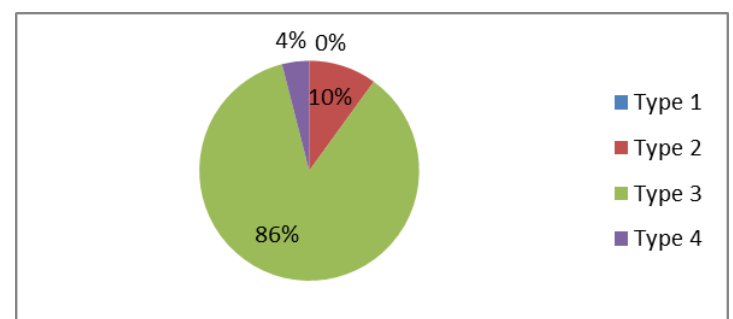
Patients who have no changes in their midline deviation from pre to post-orthodontic treatment are 30.5%. In comparison, patients who have improved their midline from having deviation during pre-orthodontic treatment to no deviation post-orthodontic treatment are 39.0%. 8.5% of the patients who have no deviation of the midline before orthodontic treatment have a deviation of the midline either left or right after orthodontic treatment. 22 % has no changes, which is no deviation from the midline from pre to post-orthodontic treatment. The percentage of the patients who have shown improvement from having a midline deviation to no deviation of the midline is 52.5%. Patients who have their condition worsen from no deviation to having deviation after orthodontic treatment is 8.5%. 52.5% showed no changes in their condition from pre to post-orthodontic treatment, either having or not having a midline deviation. (Table 3)

**Table 3.** The midline of the dental arch pre and post-cross-tabulation

		The midline of the dental arch (Post)				Total
				Yes	No	
		Yes	No	Count	Percent	
The midline of the dental arch (Pre)	Yes	Count	13	5	18	
		Percent	72.2%	27.8%	100.0%	
	No	Count	23	18	41	
		Percent	56.1%	43.9%	100.0%	
Total	Count	36	23	59		
	Percent	61.0%	39.0%	100.0%		

Patients' Perception of Smile

Based on the survey conducted regarding patients' perception of a smile (Figure 4), most of the patients preferred the type 3 smile line, which is 86.0% rather than type 2 (10.0%) and type 4 (4 %). Due to none of the patients chose the type 1 smile line, there is no significant difference between the two genders. Regardless of the age group, type 3 is the most preferable among the participants.



**Figure 4.** Pie chart showing the survey on patients' smile perception.

**DISCUSSION**

The smile aesthetic can be evaluated by assessing from diverse aspects. The present study showed a various pattern of changes from pre to post-orthodontic treatment. The smile line is a valid and commonly used tool for evaluating the aesthetic appearance of a smile as clinicians and laypersons have similar perceptions.<sup>13</sup> 52.5% maintain their smile line pattern after the treatment regardless of their types of smile line. It is also found that 10.2% of the patients had their condition worsen from type 3 during pre-orthodontic treatment to type 1, type 2 or type 4 during post orthodontic treatment. However, a higher percentage of the patients (22 %) showed improved smile lines from type 1, 2 and 4 ahead of their orthodontic treatment and achieved type 3 past the orthodontic treatment. Other than that, 15.3% showed that formerly they do not have an ideal smile line, which is type 3, yet they still failed to achieve type 3 following the orthodontic treatment.

The results vary between the individuals as the visibility of gingiva differ in every patient. The work shows that the orthodontic treatment cannot alter every individual's smile line in most cases, as a higher percentage of them maintaining their type of smile line during post-orthodontic treatment. Nevertheless, the patients that achieve the perfect smile line, which is type 3, after orthodontic treatment is 42.4% which is the highest percentage compared to type 1, 2 and 4.

The curvatures of the incisal edge of anterior maxillary teeth should be harmonious with the lower lip. When the dental and labial structures are in the

central position, the preferable smile arch can be obtained: the incisal edges are parallel to the upper border of the lower lip and softly touching or apart from the lower lip by only a few millimetres.<sup>6</sup> Factors such as mouth opening and muscle contraction of the lower lip affect the relationship between smile arch and lower lip curvature. The contraction and the degree of participation of facial muscles of the lip will influence the position of the lower lip during smiling.<sup>15</sup>

As for the relationship between smile arch and lower lip curvature, most patients (98.3%) sustained it even after doing the orthodontic treatment; the maxillary incisor edges are either light contact, slightly apart, or barely covered lower lip. The other 1.7% showed improvement from covered somewhat with the lower lip before the orthodontic treatment to a preferable position: the maxillary incisor edges are either light contact or slightly apart with the lower lip. It is identified that none of the patients has their relationship between smile arch and lower lip curvature in a worse position.

A pleasant smile is established when there is no deviation of the dental arch midline to the facial midline.<sup>8</sup> Based on this study, 52.5% of the patients are still retained their midline type, although it is deviated or not during pre-and post-orthodontic treatment. On the other hand, the least percentage (8.5%) appeared that they failed in maintaining centralised dental midline after the orthodontic treatment and showed deviation either to the right or left. Nonetheless, a better percentage of patients have acquired centralised dental midline from a



deviated midline during pre-orthodontic treatment (39.0%).

Regarding the survey on patients' perception of the smile, it is found that the majority of the patients chose type 3 smile line (86.0%), followed by type 2 (10.0%), type 4 (4.0%) and lastly, none of them preferred type 1 (0.0%). Silva E. et al., gender and level of education influenced in choosing the best smile type according to their preferences.<sup>14</sup> In each adolescent age group, young adult and adult, type 3 smile line is the most perceived by them.

## CONCLUSION

In conclusion, comparing the frontal smile photograph of patients between pre-and post-orthodontic treatment will help to motivate the patients' concern of smile aesthetic in orthodontic treatment. It evaluated each patient's smile by using the component of smile assessment to aid the orthodontists in planning a better orthodontic treatment plan towards improving the smile aesthetically and implementing an interdisciplinary approach to treat gummy or asymmetrical smile according to its etiology.

## CONFLICT OF INTEREST

We declare that there is no conflict of interest in the scientific articles.

## ACKNOWLEDGEMENT

Our gratitude goes to the professionals in Universiti Teknologi MARA(UiTM) Malaysia who have helped research and draft papers.

## REFERENCES

1. Câmara C. Aesthetics in Orthodontics: six horizontal smile lines. *Dental Press Journal of Orthodontics*. 2010;15(1).
2. Calamia JWolff M. The Components of Smile Design. *Dental Clinics of North America*. 2015;59(3):529-546.
3. Lombardi RE. The principles of visual perception and their clinical application to denture esthetics. *J Prosthet Dent* 1973;29:358-82.
4. Liebert MF, Fouque Dervelle C, Santani A, Dilier FL, Monnet Corti V, Glise JM, *et al.* Smile line and periodontal visibility. *Perio* 2004;1:17-25.
5. Sreesan NS, Purushothaman B, Rahul CS, Shafanath T, Fawaz V. Clinical Photography in Orthodontics. *Int J Oral Health Med Res* 2016;3(2):71-75.
6. Dayakar MM, Shipilova A, Rekha M. Evaluation of smile esthetics by photographic assessment of the dento-labio-gingival complex. *J Dent Allied Sci* 2015;4:65-8.
7. Sepolia S, Sepolia G, Kaur R, Gautam DK, Jindal V, Gupta SC. Visibility of gingiva - An important determinant for an esthetic smile. *J Indian Soc Periodontol* 2014;18:488-92
8. Cavalcante LM, Pimenta L. Aesthetic principles for a harmonic smile. *Rev ABO Nac* 2005;13:81-5
9. Walder J, Freeman K, Lipp M, Nicolay O, Cisneros G. Photographic and videographic assessment of the smile: Objective and subjective evaluations of posed and spontaneous smiles. *American Journal of Orthodontics and Dentofacial Orthopedics*. 2013;144(6):793-801.

10. Van der Geld P, Oosterveld P, Schols J, Kuijpers-Jagtman A. Smile line assessment comparing quantitative measurement and visual estimation. *American Journal of Orthodontics and Dentofacial Orthopedics*. 2011;139(2):174-180.
11. Mora M, Serna M, Ledesma A. Perception of smile aesthetics by dental specialists and patients. *Revista Mexicana de Ortodoncia*. 2015;3(1):e13-e21.
12. Priya K, Rahul D P, Varma S, Namitha R. Norms for Crafting a Beautiful Smile. *Amrita Journal of Medicine*. 2013;9(2):1-44.
13. Passia N, Blatz M, Strub JR. Is the smile line a valid parameter for esthetic evaluation? A systematic literature review. *Eur J Esthet Dent* 2011;6:314-27.
14. Flores-Mir C, Silva E, Barriga MI, Lagravère MO, Major PW. Lay person's perception of smile aesthetics in dental and facial views. *Journal of Orthodontics*. 2004;31(3):204–9.
15. Rubin LR. The anatomy of a smile: Its importance in the treatment of facial paralysis. *Plast Reconstruct Surg* 1974;53:384-7.